# THE MICROSCOPIC ANATOMY OF THE SMALL INTESTINES OF DOMESTIC ANIMALS

Thesis for the Degree of M. S.

MICHIGAN STATE COLLEGE

Charles W. Titkemeyer

1951

THESIS

This is to certify that the

thesis entitled

The microscopic anatomy of the small
intestines of domestic animals

presented by

Charles W. Titkemeyer

has been accepted towards fulfillment
of the requirements for

M.S. degree in Anatomy

Lois Calhoun
Major professor

Date August 10, 1951

O-169

50 301

011

# THE MICROSCOPIC ANATOMY OF THE SMALL INTESTINES OF DOMESTIC ANIMALS

By

Charles W. Titkemeyer

A Thesis

Submitted to the School of Graduate Studies of
Michigan State College of Agriculture and
Applied Science in partial fulfillment
of the requirements for the degree
of

MASTER OF SCIENCE

Department of Anatomy

1951

## ACKNOWLEDGMENTS

The author wishes to express his sincere appreciation to Dr. M. Lois Calhoun under whose supervision this project was conducted. Her unfailing interest and constant encouragement were an inspiration and a challenge. Thanks are extended also to Miss Esther Smith and Mr. William Youatt for their assistance in photography.

Grateful acknowledgment is due to Mr. Robert Kader for technical assistance; to Dr. Frederick Smithcors and Dr. Frank Thorpe, Jr. for helpful assistance; and to Mrs. Titkemeyer for proof-reading and typing.

A vote of thanks is expressed to all the scientists and workers of the past who perfected the materials and methods used on this project.

# TABLE OF CONTENTS

# INTRODUCTION

Scientific literature is filled with descriptions of the digestive tract of man. Anatomists, histologists, pathologists and cytologists have written much concerning the structure of this very important segment of man's body. Strangely enough, very little has been written about the intestinal tracts of domestic animals. It is true that many authors have mentioned certain peculiarities in animal digestive tracts but few have made an actual comparative study. Ellenberger (1911) and Trautman and Fiebiger (1931) have published excellent German texts concerning microscopic anatomy of animals, but there is no English translation.

Most histological research workers have been content with describing only certain features of the digestive tract. In this category is Hans Elias (1947) who has written the article "Comparison of Duodenal Glands in Domestic Animals." Others have satisfied themselves with a gross description of the tract and have done little more than give comparative lengths and capacities of the various segments.

This paper is an attempt at correlating the data already written on the subject and at giving a description of a study made on the microscopic anatomy of the small intestines of certain domestic animals. For this problem the horse, cow, sheep, pig, dog, goat, and cat were the species studied.

# REVIEW OF LITERATURE

No textbook on microscopic anatomy is complete without a section on the intestinal tract. However, the majority of such books describe only the intestinal tract of the human species. A good histology text for veterinary students in English is difficult to find. Those of Maximow and Bloom (1948) Bailey (1948) or Ham (1950) are used by most veterinary colleges. These books are all well written but are primarily discussions of human anatomy. Therefore, in spite of the abundance of material on the digestive tract, not much has been written comparing the digestive tracts of domestic animals.

## General Plan of the Gastro-Intestinal Tract

The digestive apparatus consists of the organs directly concerned in the reception and digestion of food, its passage through the body, and the expulsion of the unabsorbed portion. The components of the digestive tube of animals include the oral cavity, pharynx, esophagus, stomach, small intestine, large intestine, and the rectum. Ruminants differ somewhat in that the stomach is divided into four compartments.

The general structure of the digestive tube follows a definite pattern. From the lumen of the canal outward, there are mucous, submucous, muscular and serous coats. In the stomach and intestines, this plan is followed throughout. In the esophagus the serous coat is replaced with a fibrous one, and in the pharynx the submucous coat is absent and a fibrous coat replaces the serous. In the mouth this definite pattern is not followed at all, although the mucous membrane is intact and continuous with the mucous covering of the contiguous parts of the canal.

Except for a difference in nomenclature Williams (1926), Davidson (1937), Sisson and Grossman (1938), Bailey (1948), Maximow and Bloom (1948), Nonidez and Windle (1949), Francis and Knowlton (1950), and Ham (1950) are agreed on the anatomical concepts outlined above.

## The Small Intestine

The small intestine is subdivided into three segments. The first portion, attached to the pylorus of the stomach, occupies a fixed position and is termed the duodenum. It received its name, according to M'Fadyean (1884) because in man its length was about equal to the breadth of 12 fingers. The remainder of the small intestine has a comparatively loose mode of suspension. It is arbitrarily divided into jejunum and ileum, the former succeeding the duodenum and the latter comprising the remainder of the tube. These terms were also borrowed from human anatomy where the term jejunum was applied because that portion of the intestine was generally found empty in the dead body, while the ileum was so designated because of its convoluted disposition. The small intestine, as its name implies, is of smaller caliber than the large intestine. Moreover, it is distinguished from nearly every part of the large intestine by having a smooth and regular contour when distended.

## Length and Capacity of Small Intestine

Kingsley (1926) found that the length of the intestine was roughly related to the food, being longer in the plant-eating than in the carnivorous species. This was strikingly shown in frogs, where the tadpole (larva) had a very long intestine correlated with the vegetable food, while the adult flesh-eating frog had a tract hardly longer than that of a tadpole of half the size.

Among the domesticated animals, ruminants have the longest intestinal tract. Paton and Orr (1920) found that the small intestine of the ox had an average length of about 130 feet and a diameter of about two inches. This was corroborated by Sisson and Grossman (1938). The latter workers stated that the duodenum occupied three or four feet of this length. The same authors found that the small intestine of the sheep was about eighty feet long; its average diameter was about an inch, the caliber increasing in its terminal part.

The horse has the next longest intestinal tract. Sisson and Grossman (1938) observed that the average length was about seventy feet and when distended, its diameter varied from three to four inches. Its capacity was about 12 gallons.

The duodenum was about three to four feet long. The average diameter of the jejuno-ileum was about two and one-half to three inches. The last three or four feet were usually tightly contracted resembling somewhat the terminal part of the esophagus. This part was termed the ileum. M'Fadyean (1884) gave the length of the small intestine of the horse as 72 feet. This was in very close agreement with measurements of Ellenberger (1911).

Sisson and Grossman (1938) found that the small intestine of the pig was about 50 to 65 feet in length. The first two feet were firmly attached by mesentery and were termed duodenum.

Jordan (1940) found the small intestine of man to be 24 feet long. He broke down the three segments as follows: duodenum, about 11 inches; the jejunum, about nine feet; and the ileum about 14 feet. The duodenum lacked a mesentery; it was only partially enveloped by a serosa, and it had the greatest diameter, about two inches. Below the duodenum the caliber of the small intestine gradually decreased until the diameter was a little over an inch at the end of the ileum. Cunningham (1931) agreed that the length of the duodenum was 11 inches. He stated that the diameter varied considerably and averaged about one and one-half inches when empty but was two inches or more in diameter when distended.

The intestines of the carnivores are remarkable for their shortness and small volume. Chauveau (1872) stated that in a dog of ordinary size the entire intestinal tract measured scarcely more than 14 feet of which 24 to 28 inches were for the large intestine. The capacity of the small intestine was given as one quart. Sisson and Grossman (1938) gave the average length in the dog as 13 feet. Vever (1948) found the length to be six times that of the length of the body.

The cat had an even shorter tract. Chauveau (1872) gave the length as six feet and the capacity as one-fourth pint. Reighard and Jennings (1923) gave the length of the duodenum as five inches. Strangeways (1888) found that the length of the duodenum of the cat was 14 to 16 centimeters. This figure was in agreement with that given by Reighard and Jennings (1923). Vever (1948) found that the ratio of body length to intestinal length of the cat was four to one.

## Macroscopic Features

Plicae circulares. The surface area of the small intestine is greatly increased through the formation of circular folds. These folds are called valves of Kirkring, plicae circulares, or valvulae conniventes. They are constant structures and do not disappear even when the intestinal wall is distended. Maximow and Bloom (1948) found in man that they began at a distance of 2 to 5 cm. from the pylorus and reached their maximal development in the distal half of the duodenum and the proximal part of the jejunum.

In the ileum they became smaller and less numerous and disappeared in its middle. In the lower duodenum, they reached a height of 8 mm. and usually extended over two-thirds of the circumference. These folds were formed by all the layers of the mucosa including the muscularis mucosa; their core was submucosa.

Lambert (1948) found that the plicae circulares were low and broad where they first appeared near the middle portion of the duodenum and became taller and narrower toward its lower end. In the jejunum, they reached their greatest development where they were tall, thin structures with secondary and tertiary folds which gave them the appearance of being branched. They became lower and less complicated in the ileum where they seldom showed secondary or tertiary folds.

Williams (1926) stated that the valvulae conniventes began about two inches beyond the pylorus at which place the mucous coat showed numerous transverse folds that ran about halfway around the inside of the tube. They became fewer and lower as they approached the cecum, so that in the lower ileum they occurred only as isolated sickle-shaped folds. These were similar to those found in the stomach, but differed in the permanence of their form. When the stomach was distended the rugae disappeared; the valvulae conniventes were permanent structures. This was confirmed by the observation of Hewer (1947). She found that the whole mucous coat and muscularis mucosae were thrown up into folds, the valvulae conniventes, which did not disappear when the wall was stretched.

Foust (1947) stated that the plicae circulares were absent in the horse and dog but were present in the ox. Sisson and Grossman (1938) confirmed that there were permanent transverse folds of the mucous membrane (plicae circulares) in the ox. These investigators made no mention of this structure in their description of the intestinal tracts of the horse, pig, and dog.

Peyer's patches. Other macroscopic features are the Peyer's patches. According to Dorland (1951) they are aggregations of lymphatic tissue found chiefly in the ileum. Cowdry (1944) found that these masses of nodules were within the tunica propria and were usually on the side of the intestine opposite the mesentery. Bailey (1948) in his description of Peyer's patches in human anatomy described them as being aggregations of solitary follicles or groups of lymph nodules found mainly in the ileum especially near its junction with the jejunum. He found that they always occurred on the side of the gut opposite the attachment of the mesentery. Each patch consisted of from ten to seventy nodules, which lay side by side and were so arranged that the entire patch had a generally oval shape, its long diameter lying lengthwise of the intestine.

Bailey (1948) also found that the pear-shaped apices of the follicle were directed toward the lumen and projected almost through the mucosa. They were not covered by villi; a single layer of columnar epithelium alone separated them from the lumen of the gut, where their smooth surfaces could readily be seen in gross dissection. The bases of the nodules were not confined to the lamina propria but extended into the submucosa. The relation of the patch to the mucosa and submucosa could be appreciated best by following the course of the muscularis mucosae. This was seen to stop abruptly at the circumference of the patch. It appeared throughout the patch as isolated groups of smooth muscle cells. Sometimes the individual nodules which make up a Peyer's patch were quite discrete and well defined. More frequently, however, the nodules tended to coalesce except at their apices, so that the individual nodules could be outlined definitely only at their apices and to some extent be identified by their germinal centers.

In the horse, Sisson and Grossman (1938) observed that the patches were situated chiefly along the surface opposite the mesenteric attachment and began about three or four feet from the pylorus. According to Ellenberger (1911) they numbered one to two hundred, and were usually one or two inches long and one-quarter to one-half inch wide. Larger ones occurred in the terminal part, where one patch had a length of seven to fifteen inches and a width of one-half to one inch. They varied much in number, size, and distribution in different individuals and underwent atrophy in old subjects. These observations confirmed the work of Strangeways (1888) in which he found that the Peyer's patches in the horse were oval or circular groups of solitary nodules located in the jejunum and ileum, and were most numerous near the termination of the ileum.

In the ox, Sisson and Grossman (1938) reported that the Peyer's patches were larger and more prominent and distinct than in the horse. They varied greatly in size and number. In adult cattle there were 18 to 40; in calves 20 to 58. They usually formed narrow bands. There was a patch close to the ileo-cecal valve.

Chauveau (1872) found that the Peyer's patches were less numerous in the ox than in solipeds but were larger in size. A rather extensive Peyer's patch was found near the terminal portion of the small intestine of the sheep. Chauveau (1872) found that in both the sheep and the goat, they were often more than eight inches in length and extended to the ileocecal valve.

In the pig the patches were numerous, very distinct, and band-like. Sisson and Grossman (1938) counted from 16 to 38. They found that they began eight to twenty inches from the pylorus and extended intermittently to the cecum. Chauveau (1872) found an immense "Peyerian gland" in the latter portion of the small intestine, a band measuring from five to six and one-half feet in length.

The dog had about twenty Peyer's patches according to Sisson and Grossman (1938) and Chauveau (1872). Chauveau found five or six in the cat. Ellenberger (1911) found that they were usually elliptical in outline but the last one was band-like, reached to the end of the ileum, and was four to sixteen inches long in young dogs.

## Microscopic Features

Villi--size, shape and number. One of the outstanding features of the microscopic anatomy of the intestinal tract is the presence of villi thickly distributed over the entire mucous surface of the small intestine. Their purpose is absorption. The villi are small, finger-like processes consisting of vascular loops, chyle vessels, fine muscular fibers, and a covering of columnar epithelium. Since they are projections of mucous membrane, they have cores of lamina propria. The muscularis mucosae and the submucosa do not extend into them as they do in the plicae circulares. They are barely visible to the unaided eye and impart a characteristic velvety appearance to the inner surface of the small intestine.

In the duodenum, Piersol (1910) observed that they appeared close to the pylorus, but were better developed farther distally, where they were low and broad and measured

0.2 to 0.5 mm. in height and 0.3 to 1.0 mm. in width in man. He further observed that in the jejunum the villi were conical and somewhat laterally compressed, while in the ileum, their shape was cylindrical, filiform or wedge-like and their height was from 0.5 to 1.0 mm.

Cunningham (1931) also investigated the villi of the human intestine and obtained approximately the same results. He found that beginning at the edge of the pyloric valve, the villi were broad but short in the duodenum, and grew narrower distally to the valvulae coli, at the edge of which they ceased. They were found not only on the general surface of the mucous membrane, but also upon the plicae circulares. While they were not present over the solitary lymph nodules, they were found in the intervals between the individual nodes of the aggregated nodules. This work was corroborated by Lewis and Bremer (1930).

Hill (1934) determined that villi were the most numerous in the upper part of the intestine where they numbered fifty to eighty to the square inch. They were larger but more slender and less numerous in the ileum where they numbered forty to sixty to the linear inch. Their total number in the small intestine was estimated at four million.

Kendall (1947) found that the shapes of the villi varied from leaf-like through finger-like to broadly club-shaped. Bremer and Weatherford (1944) stated that in the duodenum the villi were low, leaf-like folds 0.2 to 0.5 mm.

in height while those in the jejunum and ileum were rounded, finger-like projections from 0.2 to 1.0 mm. in height. They also maintained that their shape could not be determined from inspecting single sections. Lambert (1948) found that villi were broad and leaf-like in the duodenum, club-shaped but smaller and fewer in number in the ileum.

One of the few references made to the villi of mammals other than man was made by Jordan (1940). He stated that they varied much in form in different mammals and in different portions of the canal in the same individual. He found that they were the most highly developed in the dog, where they formed long projections with expanded or clubbed extremities and a constricted base or neck.

Hartman and Straus (1933) in describing the villi of the monkey stated that in the duodenum they had the form of small flanges and were dispersed in a transverse axis to the tube. Those in the distal portion, the lower ileum, were true villi appearing as pile on a plush fabric. In the mid-region there was found a mixture of both types. Foust (1947) found that the villi were long and slender in the carnivores, short and plump in ruminants, and intermediate in horses and swine. Calhoun (1933) found that the villi of the chicken were branched.

The villi, as Hambleton (1914) and King and Arnold (1922) pointed out are capable of various movements. Wells and

Johnson (1934) described three types of movements: (1) the tonic retraction associated with contraction of the muscularis mucosae, (2) the swaying movements of individual villi without shortening, and (3) the rhythmic retractions in which the villi shorten as much as half of their total length. The epithelium is able to adapt itself to these changes by the adjusting of the individual cells and by the folding of the epithelial coat. The cells appear to be able to undergo considerable amounts of compression and stretching without injury.

The covering epithelium. Most workers regarded the entire epithelial complex as originating from entoderm. Arey (1946) stated that villi begin to appear in the human embryo at eight weeks after fertilization as independent rounded elevations of epithelium. The intestinal epithelium forms an unbroken layer of cells lining the small and large intestine and composes the smaller glands and ducts which empty into these tubes.

The columnar absorbing cells are by far the most numerous, characteristic and important elements of the villus epithelium. Kahn (1946) found that each villus was covered with about three thousand of these cells. Their form is variable. The individual differences result from pressure or tension from adjoining cells, fluctuations in functional state and position on the villus.

Cowdry (1932) found that the height of these cells ranged from 20 to 26 microns, and varied with the degree of extension or contraction of the villus, the cells in the shortened villus being longer and thinner. The width of the free end of the cell averaged about nine microns, while that of the base was quite variable and averaged six microns or less.

Most histologists are agreed that these cells have striated, cuticular free borders. Smithcors (1949) stated that the striated cuticular border affords protection from abrasion of food particles and attack by digestive enzymes, and that the borders of adjacent cells are joined by the cuticle thus preventing penetration between the cells.

Goblet cells. Cowdry (1932) found that goblet cells were quite numerous in the small intestine but not as abundant as in the large intestine. According to him they arose from a primitive form of cell, elaborated mucigen in a process similar to that of other acinous cell glands, and discharged this material directly into the crypt or lumen of the intestine. Neal and Rand (1926) found that the secretion of these glands stimulated peristalsis and lubricated the surface of the intestine.

Crypts of Lieberkühn. Crypts of Lieberkühn are simple tubular glands of the mucous membrane itself. Ham (1950) found that the cells in the deepest part of the crypts secrete many enzymes. He stated that they secrete a complement of proteolytic ones, particularly erepsin, which act in the later stages of protein digestion to produce amino acids. Other enzymes secreted are those that convert disaccharides into monosaccharides and special enzymes which act upon the nucleic acid of nucleoproteins.

Martin and Banks (1940) observed that 166 grams of the mucous membrane of a dog's small intestine produced 1,000 to 2,000 cc. of glandular secretion every 24 hours. Volborth (1925) proved that the mucous membrane of the duodenum and jejunum secreted the succus entericus which contained in addition to secretin at least seven different enzymes.

Piersol (1910) reported that the crypts of Lieberkühn were very closely set and penetrated the tunica propria as far as the muscularis mucosae. In length, he found that they varied from 0.2 to 0.4 mm., and in diameter from 60 to 80 microns.

Johnson (1913) found that in strongly distended intestines both villi and crypts became much less conspicuous and in some cases were obliterated. He also found that the crypts of the large intestine were considerably longer than those of the small and reached a length of 0.7 mm. in the rectum.

Among the cell types covering the crypts are the columnar absorbing cells and goblet cells similar to those on the villi, and the cells of Paneth. Cowdry (1932) found that these cells of Paneth were characterized by their very conspicuous granules. He cited the work of numerous German workers who had found these cells in various species. Among those cited by him were Möller (1899) who failed to find them in the pig, cat and dog, Trautman (1910) who found them in the latter two, Martin (1910) and Hamperl (1923) who reported them in the large intestine of domestic animals and Kawamura (1930) who found them totally absent in the duodenum of the rabbit but two to five per section present in the rest of the small intestine. Ham (1950) found that these cells were probably responsible for producing most of the enzymes formed in the intestine itself.

Other cells in the crypts of Lieberkühn are the argentaffine (enterochromaffine) cells. Ham (1950) found that they were dispersed in a solitary fashion between the other cells of the region. Their shapes varied in relation to their position. On the villi, they were columnar, but in the crypts they tended to be triangular. In the crypts, moreover, their apices tended to be withdrawn slightly from the surface and their bases crowded between the bases of adjacent cells and the basement membrane. He suggested that these cells were concerned in the production of the anti-anemic factor (of Castle).

<u>The muscularis mucosae.</u> The muscularis mucosae is the third and outermost layer of the mucous membrane. Ham (1950) found that it consisted of two thin layers of smooth muscle fibers together with varying amounts of elastic tissue and

that the fibers of the inner layer were circularly disposed, the outer, longitudinally. King and Robinson (1945) found that the muscularis mucosae was well developed in the gastro-intestinal tract of all mammals and birds, although its thickness was not the same for all species. Maximow and Bloom (1948) stated that its thickness in the human intestine was 38 microns. King _et al_. (1947) found that the muscularis mucosae of the dog's small intestine contained both longitudinal and circular layers of muscle at all levels.

_Brunner's glands_. Brunner's glands are of the branched tubulo-alveolar type. They appear in the region of the sphincter of the pylorus with the first glands of Lieberkühn. Sometimes they extend into the pyloric region for several centimeters. The glands are located for the most part in the submucosa while the ducts pierce the muscularis mucosae. The cells are of the mucous type, cuboidal glandular cells containing fine granules. In the distal two-thirds, the glands gradually diminish in size and finally disappear. In some cases they extend well into the upper part of the jejunum.

Elias (1947) made a comprehensive comparison of the duodenal glands of domestic animals and found that in the hog the Brunner's glands formed large continuous masses which filled the entire submucosa of the proximal duodenum. They were interrupted only by groups of fat cells. These glandular masses appeared very much like oral, mucous salivary glands. They consisted of very long and very much twisted tubules. The lumina of the tubules were very narrow, just as narrow as those of the acini of the oral salivary glands. As in those, the nuclei of the glandular cells were slightly flattened, deeply staining, and located at the basal periphery of the cells. The ducts were lined by the same kind of cells which were found in the tubules.

In the horse, the duodenal glands formed small, distinct lobules consisting of twisted tubules, essentially shorter than those of the hog (Elias 1947). Each lobule was provided with a duct. The end pieces were similar to those of the hog. The lumina were extremely narrow and the cells which lined them were pyramidal to cuboidal. Their nuclei were definitely flattened and pressed toward the basal boundaries of the cells where they caused a slight outbulging. The lumina of the ducts were wide and their lining was a layer of low cuboidal cells.

Brunner's glands in the cat also formed lobules but they were less distinct than those in the horse (Elias 1947). The end pieces were tubulo-alveolar; branching occurred in peripheral districts. The lumina of the end pieces were small, but easily distinguishable. The glandular cells were much smaller than in the horse. Their nuclei were spherical, and they did not stain as heavily as those of the pig and the horse. Frequently, a large nucleolus could be distinguished. On the whole, the nuclei resembled those of pancreatic cells. The lumina of the ducts were as large as those of the largest alveoli. The ducts were lined by the same kind of cells that lined the end pieces.

Elias (1947) found that, except for larger lumina, the glands of Brunner in the ox were similar to those of the cat. The glandular cells were small and cuboidal, and were provided with relatively large, light, spherical nuclei. A remarkable feature of the bovine duodenal glands was that the end pieces which were directed upward, i.e., those which approached the muscularis mucosae from below, were serous in character. The glands emptied frequently into the crypts of Lieberkühn.

In the dog, Elias (1947) found that the glands of Brunner had relatively large lumina and resembled flattened pouches. They were lined by most characteristic, very tall, columnar cells which were provided with distinct striated distal borders. The nuclei were found near the periphery of the glands. They were either flattened, slightly compressed, or tall and oval. The ducts were lined by the same type of cells that was found in the end pieces.

The ovine glands of Brunner had still larger lumina. Their general shape was somewhat intermediate between the branched, alveolar type of the ox and the flattened pouch type of the dog. The glandular cells were columnar, but not as tall as those of the dog. The distal border of the cells was at some places provided with thin protoplasmic projections deeply staining at their bases. The nuclei were light staining.

According to Elias (1947) the largest lumina among the glands of Brunner in domestic animals were possessed by the goat. Brunner's glands in this species consisted of large, thin-walled, branched alveoli which very much resembled hypoactive thyroid follicles. The alveoli were lined by low columnar to low cuboidal epithelium. The epithelium of some alveoli was provided with a deeply staining border. The nuclei varied in shape from flattened to erect oval. A few of the end pieces, however, were narrow tubules.

Elias (1947) concluded that there was a great difference in the size of the lumina in the glands of Brunner ranging from approximately two microns in the pig to one hundred microns in the goat with the horse, cat, ox, dog and sheep falling between the two in that order. He also found that the lowest cells were five microns in height and the tallest were thirty microns in the following succession (low to high): cat, ox, horse, pig, sheep, and dog. Foust (1943), Winters and Funk (1946) and Calhoun (1933) found that there were no Brunner's glands in the chicken.

Dukes (1943) made a fistula about 5 cm. long in the duodenum of a goat and obtained 4 cc. of intestinal juice per hour indicating a secretion of nearly 100 cc. daily from the small portion of the intestine containing duodenal glands. He found that the duodenal-gland-containing part of the intestine was the only part which gave an abundant secretion. Florey and Harding (1934) made an extensive study of the secretion of the duodenal glands in the goat, pig, dog, cat, and rabbit. They theorized that the function of the duodenal glands was to protect the mucosa from stomach acid injury. This protection was effected by the alkaline secretion of these glands.

Muscle layer. The muscular coat consists of two well-formed layers of smooth muscle separated by a thin layer of fibrous connective tissue. The inner layer is circular, the outer one is longitudinal. In the connective tissue between the two layers is the prominent myenteric plexus. Among the histologists in agreement with these facts are Marshall and Lazier (1946), Maximow and Bloom (1948), Bailey (1948), Romer (1949), and Ham (1950).

Cunningham (1931) found that in the small intestines of many mammals the layers were not truly circular or longitudinal, but were both spiral, the inner coat forming a close spiral and the outer, a long spiral. In the inner coat he found one complete turn made in every 0.5 to 1.0 mm. or less while those of the outer coat made a complete turn in every 200 to 500 mm. or more. Arey and Elsen (1950) disputed this claim. They conducted experiments on the small intestines of the cat, dog, hog, and human by pulling free relatively narrow ribbands of muscle and allowing these stripped bands to follow their natural courses of separation from the main muscle layer. The divergence from straight directions were then measured and their trends determined. The results showed that the longitudinal layer of muscle was truly longitudinal with respect to the mesentery and the circular layer was likewise truly circular. Neither layer spiraled significantly.

Physiologists are agreed that the circular layer constricts the tube and the longitudinal one shortens it. The combined action of constriction and shortening gives rise to a movement known as the peristaltic wave which results in forcing the food ahead of the constricted segments.

Vever (1948) stated that compared to the intestines of other animals, those of carnivores have thicker and stronger walls. This enables the animal to deal with the large pieces of relatively indigestible flesh and bone which form its diet.

Serosa. All histologists are agreed that the small intestine is covered by a thin layer of fibrous connective tissue upon which rests a layer of mesothelium. This visceral peritoneum is reflected onto the mesentery along the line of attachment to the intestine. Most of the human duodenum lacks a mesentery and has only a partial serous coat.

## Factors Affecting the Appearance of the Intestinal Mucosa

Effects of distention of the intestine. Johnson (1913) cited the work of Heitzmann (1868) who discovered that the shapes of villi varied with the distention of the intestine. Heitzmann found that a piece of intestine of a freshly killed guinea-pig possessed alternating contracted and distended portions, and that if the piece were thrown into a chromic acid mixture, the contracted portions remained permanently contracted and the distended portions permanently distended. His examination of the villi of the contracted portion showed them to be long and cylindrical; of the distended portion, flat and conical. Moreover, he observed that artificial distention, produced by filling a tied-off piece of intestine with chromic acid mixture beyond the limits of ordinary normal expansion, or extreme distention caused by the formation of gas in the intestine, almost entirely obliterated the villi. This he found was true not only for the villi of the guinea-pig, but to a less extent for those of the rabbit and cat. He concluded, therefore, that there was no fixed form for the villi, but that their shapes were dependent upon the contraction of the intestinal tube. He believed that during the movements of normal peristalsis there was a continual changing in the form of the villi. He also noted that the intrinsic muscle fibers of the villi acted as the antagonists of those of the muscularis of the intestinal wall.

In a study of intestinal contraction, Mall (1896) found that the injection of oil into tied-off pieces of intestine of the dog brought about a shortening of both villi and glands and that up to a certain limit, the shortening varied directly with the amount of distention.

Harvey (1908) studied the large intestines of the dog and man and found that the length and breadth of the intestinal glands varied with distention and contraction of the intestinal tube. From a limited number of observations he concluded that the glands of the transverse colon were subject normally to greater changes in length and breadth, and those of the ascending colon to smaller changes, than the glands of other parts of the large intestine. He made no mention of the effects of distention upon the villi and glands of the small intestine.

The work of Bujard (1909) cited by Johnson (1913) indicated the following results: In herbivorous mammals, where a large residuum of food material was found in the intestine, the intestine was long and the villi small and few. In insectivores, frugivores, and omnivores, where there was only a moderate amount of food material present, the length of the intestine was medium and the villi large and numerous. In the carnivores, where a minimum residuum of food was left, the intestine was shorter and the villi were narrow, long and pointed, and very numerous. However, Bujard (1909) made no mention of the fact that it was the amount of residuum which determined the amount of distention of the intestine, and that it was this in turn which determined the shape of the villi. He believed, rather, that it was the nature of the food material itself which was the active factor in producing different shapes. To substantiate this view he performed experiments on the intestines of white rats, in which he found that after the continued feeding (140 to 380 days) of milk and meat diets, the villi became long and narrow, while on vegetarian diets, the villi became broader and shorter. Unfortunately, in his descriptions of villi, he did not state whether the pieces of intestine he examined were in the contracted, partially contracted, or in a distended state.

Johnson (1913) made an extensive study of the effects of distention of the intestine. He made numerous measurements showing the effects of the distention of the small intestine upon the shape of the villi and glands when the intestine was normally contracted, normally distended and experimentally distended. For his work he used such animals as the rat, guinea-pig, cat and the dog. He enumerated the effects of distention of the intestines as follows:
(1) The outer intestinal coats became reduced in thickness.
(2) The mucosa became reduced in thickness. (3) The villi became shorter and broader. (4) Glands became shorter and broader. In the guinea-pig and mouse they

entirely disappeared if the intestine was strongly distended. (5) In the intestine of the guinea-pig the epithelium became flattened upon strong distention.

Johnson (1913) further stated that it was evident from the foregoing results that the shapes of villi and glands were to a great extent dependent upon the condition of distention or contraction of the intestine. This was true not only for marked distention produced experimentally, but for the smaller amounts of distention which took place under normal conditions. It seemed probable, therefore, that with each dilation and contraction of normal peristalsis and of the rhythmical movements of the intestine, the villi changed their shape, and in this way brought about a more thorough mixing of the intestinal contents. Because of the variety of shapes presented by the gland cavities it was not possible by ordinary methods to determine their exact capacities, but it was probable that the capacities of the glands were decreased upon strong distention, and their contents were then partially emptied into the lumen of the intestines.

Effects of agonal and post-mortem changes. Guyer (1943) found that the intestinal tract was one of the first tissues to be affected by post-mortem changes. He stated that inasmuch as the intestinal lining began to digest itself promptly, tissues from the alimentary tract should be the first to be removed and placed in the fixing fluid. In a personal discussion of this problem, Dr. Hans Elias (1951) stated that he was convinced that the lining epithelium of the intestinal tract was affected by digestive processes within a very few moments following death. It was his opinion that any detailed study of the epithelium of the intestinal tract should be done with tissues taken from animals embalmed immediately upon the onset of death.

Sohn and Arey (1951) found that certain cells of the intestinal tract did not deteriorate rapidly. They maintained that, contrary to the usual opinion that argentaffine cells are extremely labile, it can be shown that they persist in the intestine for an astonishing length of time. In a demonstration of this phenomenon at the Sixty-fourth Annual Session of the American Association of Anatomists, these workers showed that the argentaffine cells remained normal for about 24 hours after death. Between 48 and 96 hours there was deterioration until not more than one-half of all the argentaffine cells still appeared essentially normal. Between 96 and 168 hours there was further deterioration and, although perhaps one-third were then undemonstrable, the remainder still stained even though they were more or less atypical. The persistence was better in the duodenum of the dog than in the rabbit; in the sigmoid-rectum region, the reverse was true. In view of the prompt degeneration of the mucosa as a whole, the long continued persistence of recognizable argentaffine cells was remarkable.

Macklin and Macklin (1926) found that the epithelium of the villi underwent agonal and post-mortem changes very rapidly. A few minutes after the cessation of the circulation in the intestinal wall, the epithelial cap of the villus usually separated from the underlying core, and soon disintegrated. Frequently the core was pulled out of the cap like a finger from a glove. Sections of these detached collapsed caps, such as are often seen in autopsy material, looked like irregular and frequently broken epithelial rings. This curious "ballooning" of the cap seemed to be due to the asphyxially induced contraction of the smooth muscle of the villus core, with squeezing of the tissue fluid from the core underneath the epithelial layer, which became broken away as a consequence.

Effects of inanition. The appearance of the epithelium depends to a large extent upon the state of nutrition of the animal. Rats which had been underfed for varying periods revealed to Miller (1927) that the villi and glands were atrophic or degenerated completely. Sun (1926) found that the length of time necessary to bring about this alteration with malnutrition was much less in winter than in summer, one day of starvation in the winter months being sufficient to reduce the epithelium of the intestine of the mouse to a mass of debris. With refeeding, the appearance became normal if the starvation had not been too prolonged.

Miscellaneous effects. Parasitism affects the mucosa of the intestinal tract principally through irritation and hemorrhage. It sometimes causes a diarrhea which affects the epithelial lining of the tract.

X-radiation is another factor which has a pronounced effect upon the mucosa. Warren and Whipple (1922) found that histological changes could be noted on the first day after exposure, even before the appearance of clinical manifestations. The cells showed definite nuclear changes. Degeneration of the crypt epithelium was evident before any alterations were visible in the villus cells. This finding is in the reverse of that in autolysis of normal intestines after death.

From the above discussion of factors affecting the normal histology of the digestive tract it is evident that any true picture of this segment can be obtained only by careful selection of the animals to be studied and by the elimination of as many variables as possible. The effects of distention are the only ones that are difficult to eliminate. Much of the variation in results obtained by different workers can probably be attributed to this cause.

# MATERIALS AND METHODS

For this study the intestinal tracts from 39 animals were used. Included in this group were twelve dogs, seven cows, seven horses, seven pigs, two sheep, two cats, and two goats. The intestinal tracts were fixed as soon after death as possible. The intestines of the cows and pigs were obtained from a slaughter house where it was impractical to remove them immediately upon the death of the animal. They were, however, fixed upon their removal from the carcasses, usually within one-half hour after death. The intestinal tracts of the dogs, cats, and horses were fixed within a very few moments after death. Those of the sheep and goats were obtained from specimens embalmed upon death and were in good condition.

A gross examination of the tract was made before fixation to determine gross appearance of the villi and the number of Peyer's patches. Sections were then taken from the tract every tenth distance irrespective of the over-all length. The first section was taken as near the pylorus of the stomach as possible and the last one was taken next to the ileo-cecal junction. The other eight sections were taken equidistant between them. These sections were then fixed either in Bouin's solution or in F. A. A. (Lavdowsky's) mixture (Guyer 1943). After proper fixation, they were dehydrated in dioxane, embedded in paraffin and sectioned at 8 microns thickness.

Two different staining techniques were used. Hematoxylin and eosin (Guyer 1943) were used on one set of slides to facilitate the study of the villi and the glands. Weigert's and Van Giesen's stains (Guyer 1943) were used on another set as an aid for studying the connective tissue and muscle layers.

## RESULTS AND DISCUSSION

### Macroscopic Features

Villi. The gross examination of the intestinal tracts revealed that the villi of the cat were much longer than those of the other species studied. Villi of the dog were next in length, followed in order by those of the goat, sheep, pig, horse, and cow. No attempt was made at measuring the villi macroscopically. Plate I shows a macroscopic view of the villi in the duodenum of a dog.

Peyer's patches. The presence of Peyer's patches varied considerably in the various species. In the cat, none were found grossly, but they were found microscopically. In the horse, the first patch was found only about four feet from the pylorus indicating that Peyer's patches were located throughout the jejunum and ileum. As the duodenum of the horse extended for the first three to four feet according to the findings of Sisson and Grossman (1938), Peyer's patches began just subsequent to the terminal end of the duodenum. From this point on they were scattered intermittently throughout the rest of the tract. They were always on the side opposite the mesentery and varied greatly in size and number. In the horses studied they ranged from one-half inch to eight inches in length and numbered approximately 85 per animal. This is somewhat less than the one hundred to two hundred found by Ellenberger (1911). Some of the smaller ones probably were overlooked.

In the cow, Peyer's patches were much larger and more prominent than they were in the horse, but they were less numerous. Upon gross examination an average of 18 per animal was found. These ranged from two to twelve inches in length and were scattered throughout the jejunum and ileum. The sheep and goats had a few scattered Peyer's patches throughout the jejunum and ileum. In one sheep a Peyer's patch was found extending from the ileum for a short distance into the cecum.

The pigs had about twenty Peyer's patches each. They were prominent and easily distinguishable. The large terminal patch mentioned by Chauveau (1872) was not seen.

In the dog, Peyer's patches were easily counted from the exterior surface. They appeared as circumscribed elevations about three-fourths inch long and one-half inch wide. As a rule they were not directly opposite the mesentery but appeared on either side of it. The number of patches ranged from 17 to 26 with an average number of 22. They were more numerous in the anterior part of the small intestine than in the ileum. Several patches were found in the duodenum partially covered by the pancreas.

They formed a distinct elevation on the interior surface of the tract. Plates II and III show macroscopic views of typical Peyer's patches in the pig and dog.

Plicae circulares. Plicae circulares were found only in the ruminants. The horse, dog, cat and pig had no circular folds although they did have longitudinal ones running intermittently throughout the intestinal tract. The longitudinal folds of the horse were very prominent but did not assume a circular direction at any level. This is in accordance with the views of Foust (1947) that plicae circulares are absent in the horse and dog but are present in the ox.

## Microscopic Findings

A microscopic survey of histological sections prepared from various levels of the intestinal tracts revealed numerous variations. Measurements included the height of the villi, the height of the epithelium of the villi, the thickness of the muscularis mucosae, the width of the lumen of the Brunner's glands, the height of the epithelium of Brunner's glands and the thickness of the muscle layers. A review of the results follows.

Height of the villi. Piersol (1910), Robinson (1931), and Hill (1934) found in the human that the height of the villi tended to increase progressively toward the terminal end of the small intestine. This phenomenon was not confirmed in the tracts of domestic animals in this investigation. There was no significant difference in the lengths of the villi in the three segments of the tract. This held true for all animals studied.

The greatest height was found in the intestine of the cat (Plate IV) where the villi had an average height of 963 microns. They were very close together, quite slender and somewhat constricted at their bases. There was some branching. They were also more numerous than in the other species. The epithelial cells covering the villi were lower in the cat than in any of the other animals studied and reached a height of only 16 microns.

In the dog (Plate V), the height of the villi was next in magnitude and reached an average height of 645 microns. The villi were numerous and showed some branching. The distal ends were expanded and club-shaped. The height of the covering epithelium was greater than in any other species and reached a height of 32 microns.

The goat had the next tallest villi. They averaged 615 microns in height and were wider at the base than those of the carnivores. They were somewhat expanded at both ends with a slight constriction in between. The epithelial layer reached a height of 28 microns.

The villi of the sheep (Plate VI) and swine (Plate VII) were next in length and were nearly equal. Sheep averages totaled 483 microns while those of the hogs totaled 470 microns. In both cases the villi were cylindrical and were arranged in rows. Those of the swine were less numerous than in the other species studied. The height of the epithelial covering was 25 microns in sheep and 29 microns in swine.

The horse (Plate VIII) had large, broad villi that were well-rounded on their distal ends. The bases were much wider than those of other species. The height averaged 405 microns and the height of the epithelium was 31 microns. In appearance they resembled cylindrical haystacks with a well-formed dome.

The shortest villi were found in the ox (Plate IX). They measured only 363 microns in height and had an epithelial cell covering which measured 22 microns. They were slender and markedly constricted at their bases. They were more numerous than they were in the horse and hog.

These results disagreed somewhat with those of Ellenberger (1911). In order of decreasing height of villi he listed the above animals in the following succession: cat, dog, horse, pig, sheep, goat, and ox. The findings of this experiment indicated that although there was little difference in the height of the villi of the sheep, hog, and horse, the order of succession was cat, dog, goat, sheep, swine, horse and ox. Table 1 indicates the average measurements.

TABLE 1

COMPARISON OF VILLI

| Species | Average Height of Villi (in microns) | Average Height of Epithelium (in microns) |
|---|---|---|
| Cat | 963 | 16 |
| Dog | 645 | 32 |
| Goat | 615 | 28 |
| Sheep | 483 | 25 |
| Hog | 470 | 29 |
| Horse | 405 | 31 |
| Ox | 363 | 22 |

Thickness of the muscularis mucosae. In all cases the muscularis mucosae was in two layers, an inner circular and an outer longitudinal one. Except in the dog, these layers were so narrow and incomplete it was impractical to measure them separately. The combined layers ranged in thickness from a low of 15 microns in the cat and goat to a high of 26 microns in the horse. In the dog, the muscularis mucosae was markedly different. (Plate X) It was in two layers either of which was thicker than the combined layers in the other species. The inner circular layer averaged

27 microns in thickness; the outer longitudinal layer averaged 44 microns. The two layers totaled 71 microns which is over three times wider than that of the average of other animals. (Pig, Plate XI)

These findings disagreed somewhat with those of Ellenberger (1911). He found that the muscularis mucosae of the horse was thicker than that of the dog. In order of decreasing thickness, his measurements in microns were as follows: horse, 120; dog, 95.8; ox, 31.2; cat, 28.9; hog, 24.2; sheep, 22.1; and goat, 20.

Brunner's glands. Brunner's glands were found in all species but they were much more extensive in some than in others. In the horse they were found in the first four sections in all cases, and in one animal they were identified in the fifth section. As these sections were taken at every tenth segment of the tract, this indicated that the duodenal glands extended down the tract as far as 32 feet from the pylorus.

In the dog, the opposite extreme was found. In six of seven dogs, no Brunner's glands were found in the sections examined. An eighth dog was used and sections from various segments of the duodenum were examined specifically for these glands. They were found only in the very proximal part of the duodenum.

In an attempt at finding the exact location of these glands, longitudinal sections were taken beginning at the pylorus and extending a short distance along the duodenum. It was found that on the left side of the digestive tube, the glands extended 2 mm. into the pylorus and 2½ mm. into the duodenum. On the right side they extended 3/4 mm. into the pylorus and 1½ mm. into the duodenum. The total extent of these glands was 4½ mm. or .18 inch on the left side and 2¼ mm. or .09 inch on the right side. This is somewhat less than the 15 to 20 mm. found by Ellenberger (1911).

In the ox, difficulty was also experienced in locating Brunner's glands. None were found in the sections of the first six cow intestinal tracts examined. A seventh cow was sacrificed and glands were located about one foot from the pylorus. As these glands were found scattered throughout the first 12 to 15 feet of the duodenum by Sisson and Grossman (1938), it is probable that they were present but were dispersed thinly enough to be missed when sections were taken only every tenth distance.

In the other species, duodenal glands were readily found. In the pig they extended at least 14 feet from the pylorus. In the cat, goat, and sheep they were found only in the first section near the pylorus.

Two measurements were made on the Brunner's glands--the diameter of the lumen and the height of the epithelium.

The Brunner's glands of the goat had the greatest lumen diameter while those of the hog had the smallest. (Plate XII) The glands of the goat and the dog showed the highest epithelium while those of the cat had the lowest. (Plate XIII) Complete measurements are shown in Table 2.

TABLE 2

BRUNNER'S GLANDS

| Species | Lumen Diameter (in microns) | Height of Epithelium (in microns) |
|---|---|---|
| Goat | 50 | 35 |
| Sheep | 40 | 20 |
| Dog | 35 | 35 |
| Ox | 25 | 12 |
| Cat | 20 | 10 |
| Horse | 7 | 15 |
| Swine | 3 | 25 |

The tunica muscularis. The outstanding difference in the muscle layers of the various animals was an extra oblique layer in the carnivores. In the other species, there were distinct inner circular and outer longitudinal layers with an Auerbach's plexus between them. The carnivores had these same two layers plus an oblique layer between the submucosa and the circular layer. In the dog, this layer averaged

47 microns in thickness and was easily identifiable in all sections. (Plate XIV) In the cat, this oblique layer was only 16 microns in thickness and was difficult to locate in some sections.

The tunica muscularis was the thickest in the horse where it reached an average thickness of 1153 microns. The longitudinal layer of muscle was nearly as thick as the circular layer. This differed from the other species where the circular layer was much the largest of the two. (Pig, Plate XV) Table 3 shows the average width of the muscularis mucosae and the layers of the tunica muscularis.

TABLE 3

COMPARISON OF MUSCLE

| Species | Muscularis Mucosae | Tunica Muscularis | | | |
|---|---|---|---|---|---|
| | | Oblique Layer | Circular Layer | Longitudinal Layer | Total |
| Horse | 26 | -- | 625 | 528 | 1153 |
| Dog | 71 | 47 | 427 | 227 | 701 |
| Ox | 19 | -- | 368 | 220 | 588 |
| Cat | 15 | 16 | 414 | 125 | 555 |
| Hog | 23 | -- | 332 | 188 | 520 |
| Sheep | 24 | -- | 175 | 112 | 287 |
| Goat | 15 | -- | 100 | 75 | 175 |

The measurements in Table 3 are in fairly close agreement with those of Ellenberger (1911). He gave the following measurements in microns for the thickness of the tunica muscularis of the jejunum: horse, 2070; dog, 1579; cat, 1433; ox, 659; pig, 263; sheep, 191; and goat, 157. The discrepancy between his measurements and those in Table 3 is probably due to the state of distention of the intestines at the time of the death of the animal.

Special connective tissue layer. In the dog, an extra connective tissue layer was observed between the muscularis mucosae and the crypts of Lieberkühn. (Plate X) This zone of connective tissue was about 30 microns in thickness and completely encircled the intestine. It was not observed in any of the other animals studied.

Plate I Villi in the duodenum of a dog. 100X

## Plate I

Plate II    The flat Peyer's patch of the pig. 8X

## Plate II

Plate III The elevated Peyer's patch of the dog. 8X

Plate III

Plate IV    Tall, narrow villi of the cat. Hematoxylin and eosin. 250X

## Plate IV

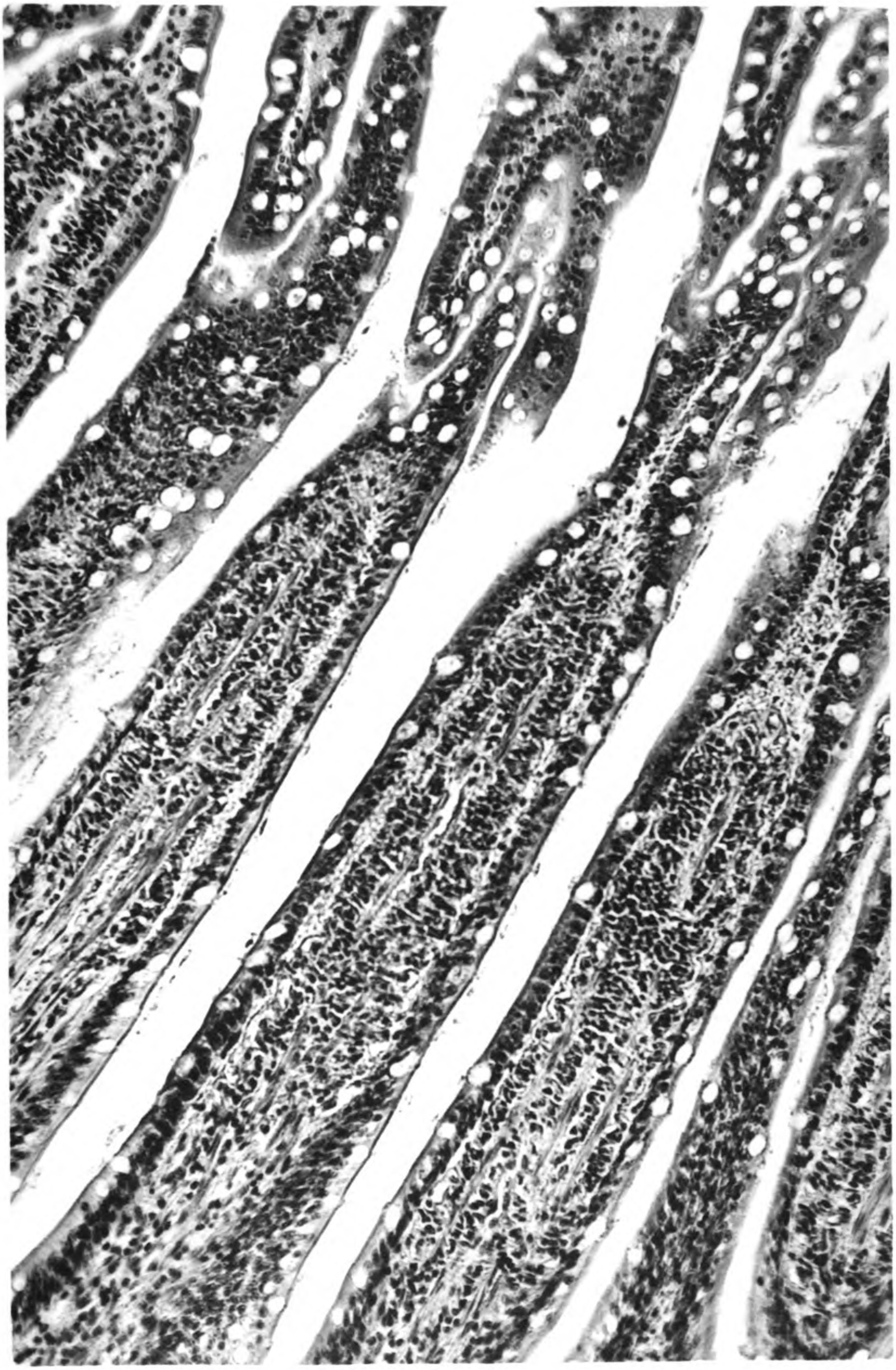

Plate V Constricted, club-shaped villi of the dog.
Hematoxylin and eosin. 250X

The serrations along their borders are caused by their partly contracted state.

Plate V

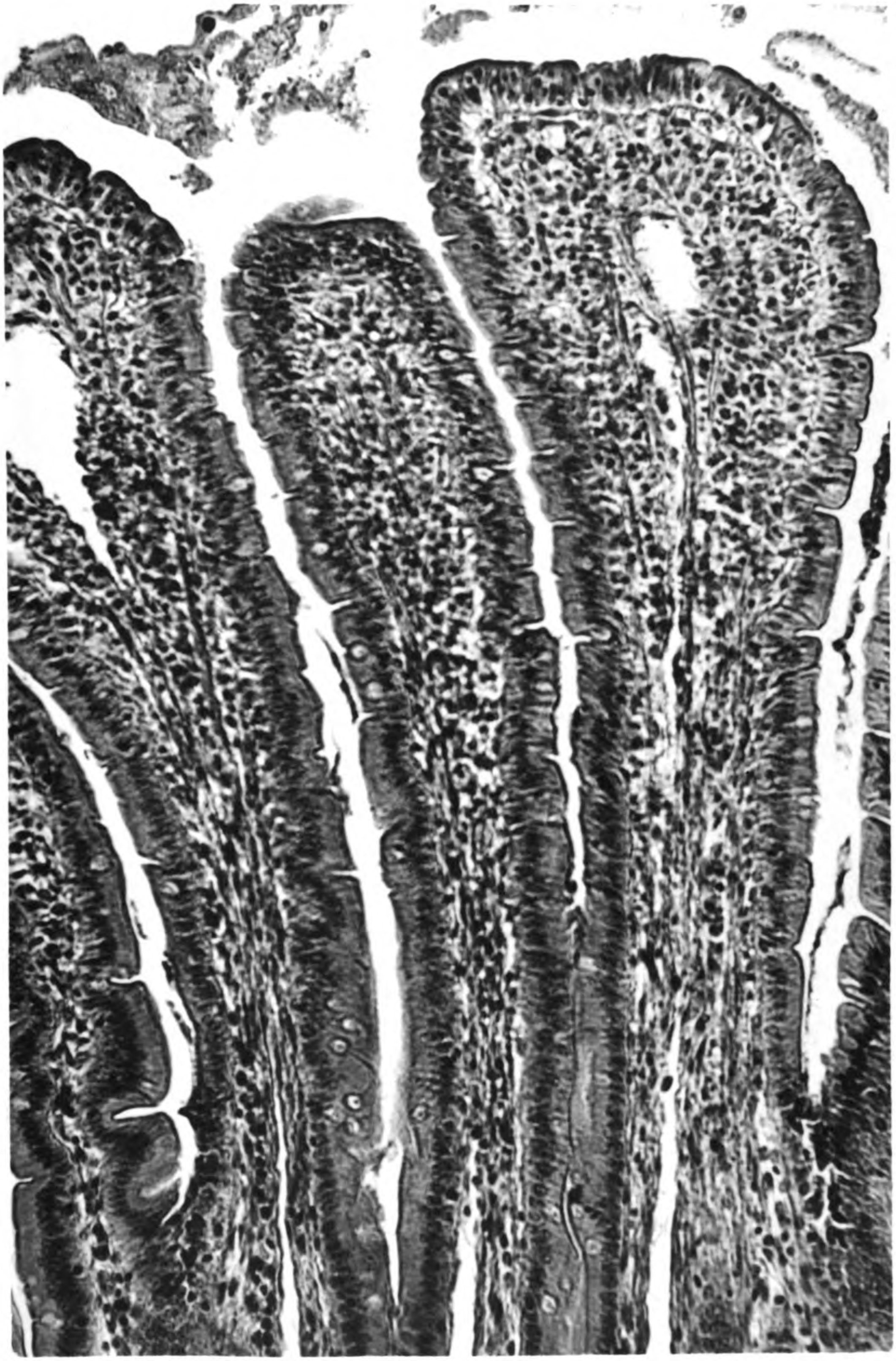

Plate VI    Tall, constricted villi of the sheep.
Hematoxylin and eosin. 250X

## Plate VI

Plate VII Widely spaced villi of the pig. Hematoxylin and eosin. 250X

Plate VII

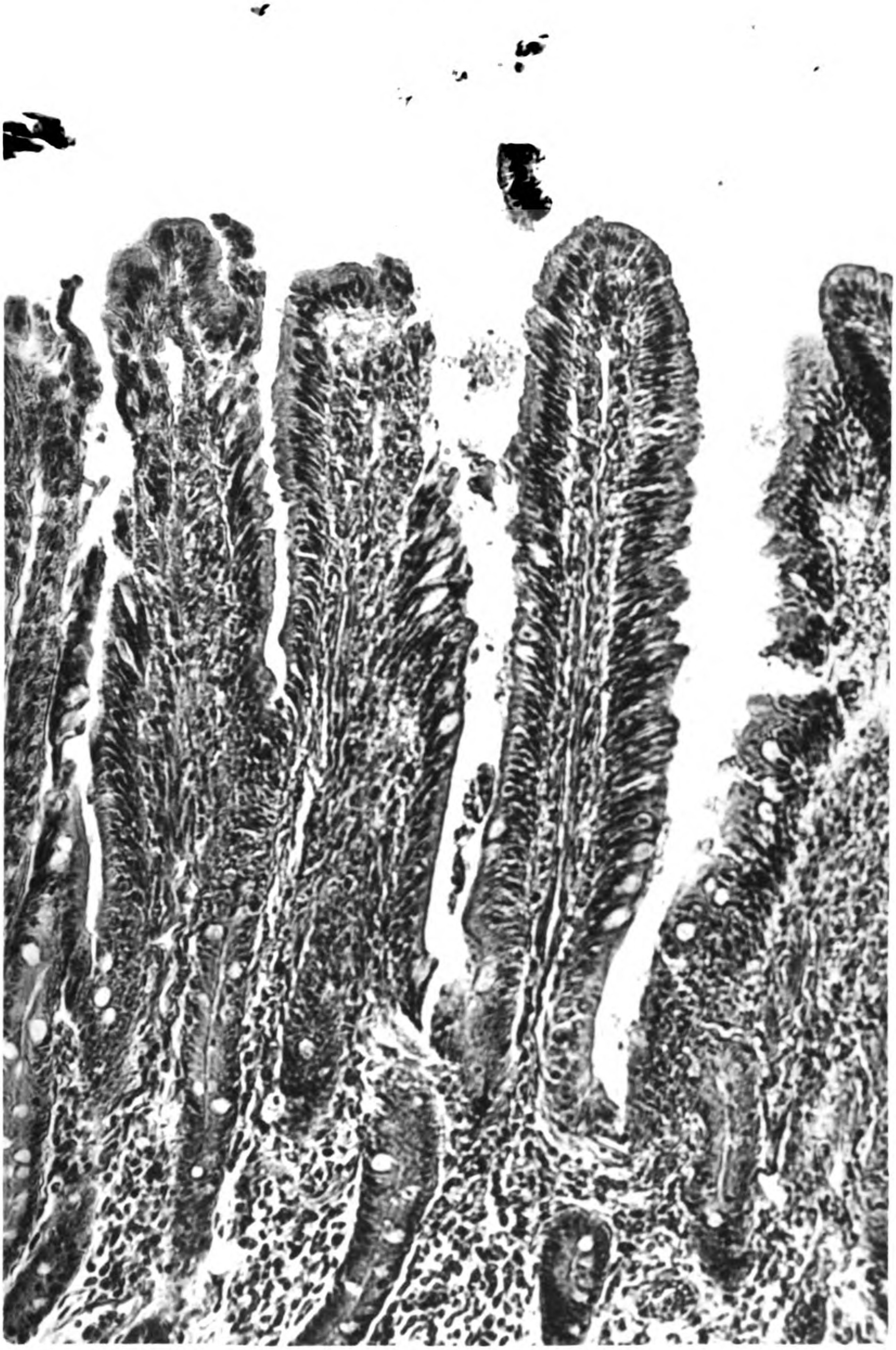

Plate VIII Broad based, rounded villi of the horse.
Hematoxylin and eosin. 250X

## Plate VIII

Plate IX Short villi of the cow. Hematoxylin and eosin. 250X

Some of the villi show a branching.

Plate IX

Plate X Muscularis mucosae of the dog. Hematoxylin and eosin. 760X

Note that it is composed of an inner circular and an outer longitudinal layer. To the right of the inner circular layer is the extra connective tissue layer peculiar to the dog.

Plate X

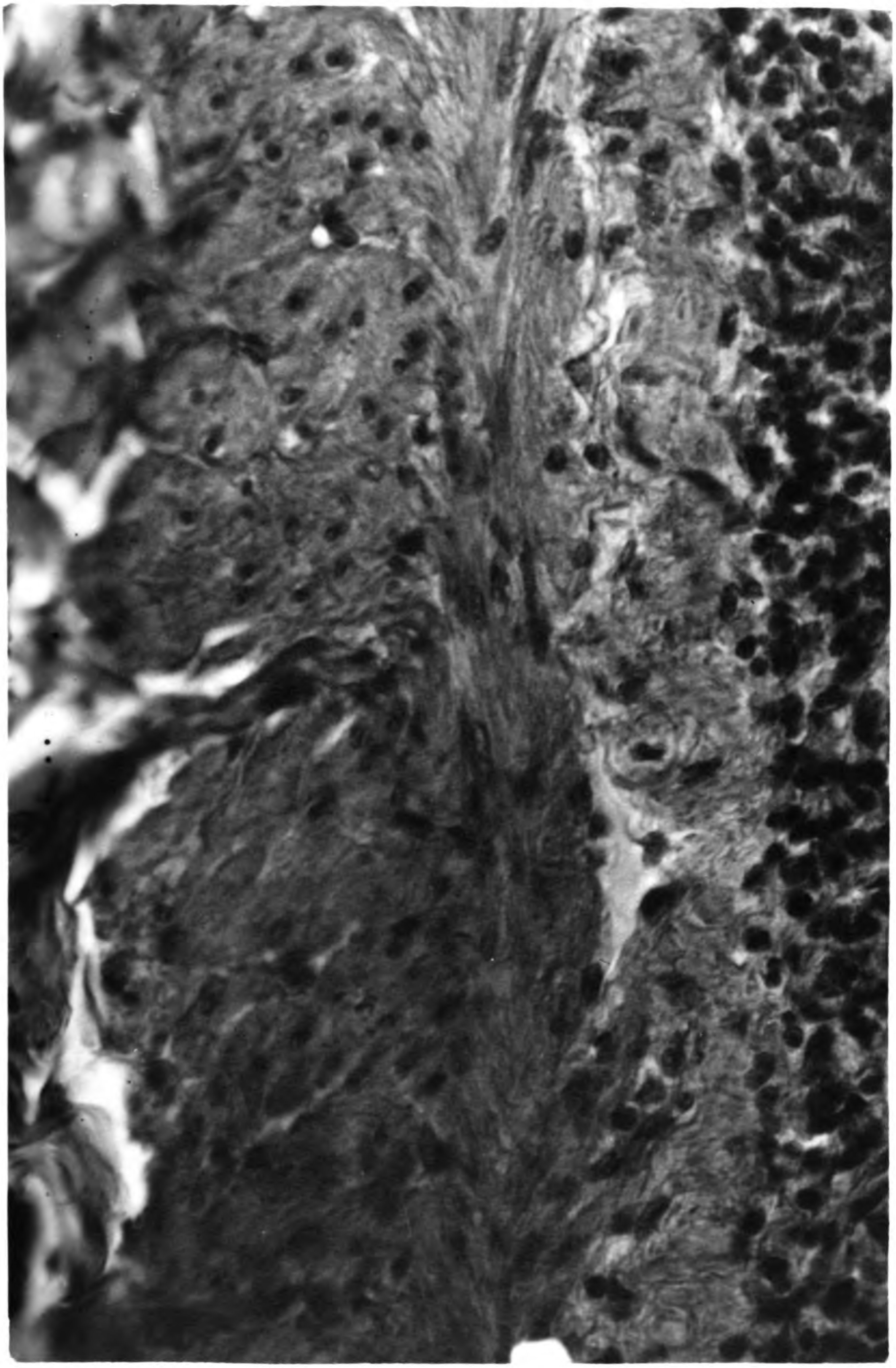

Plate XI Muscularis Mucosae of the pig. Hematoxylin and eosin. 760X

Note that it is a single narrow layer.

Plate XI

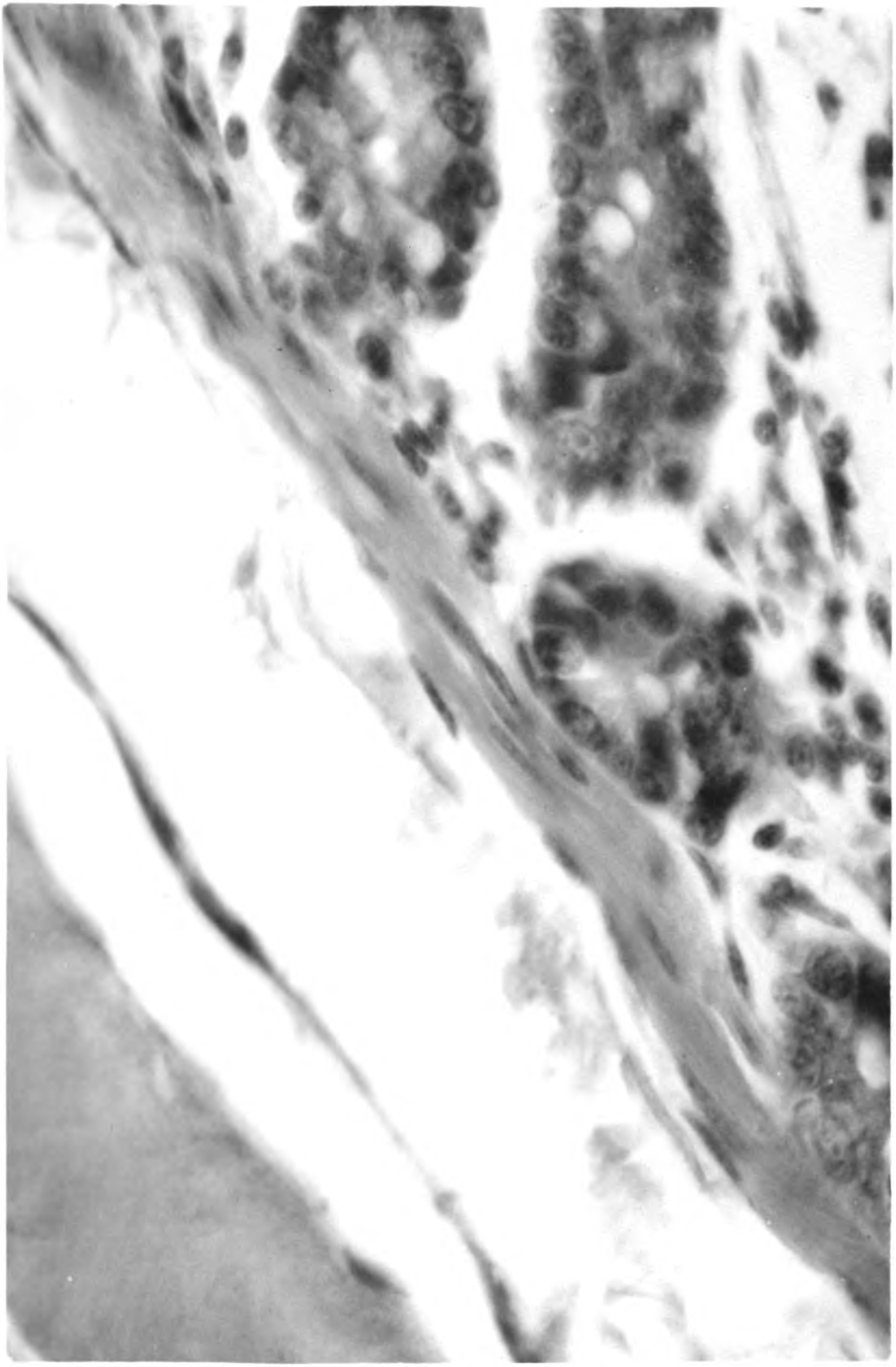

Plate XII Brunner's glands. Hematoxylin and eosin.
150X

Fig. 1 Hog. Note the narrow lumen diameter.

Fig. 2 Goat. Note the very wide lumen diameter.

Plate XII

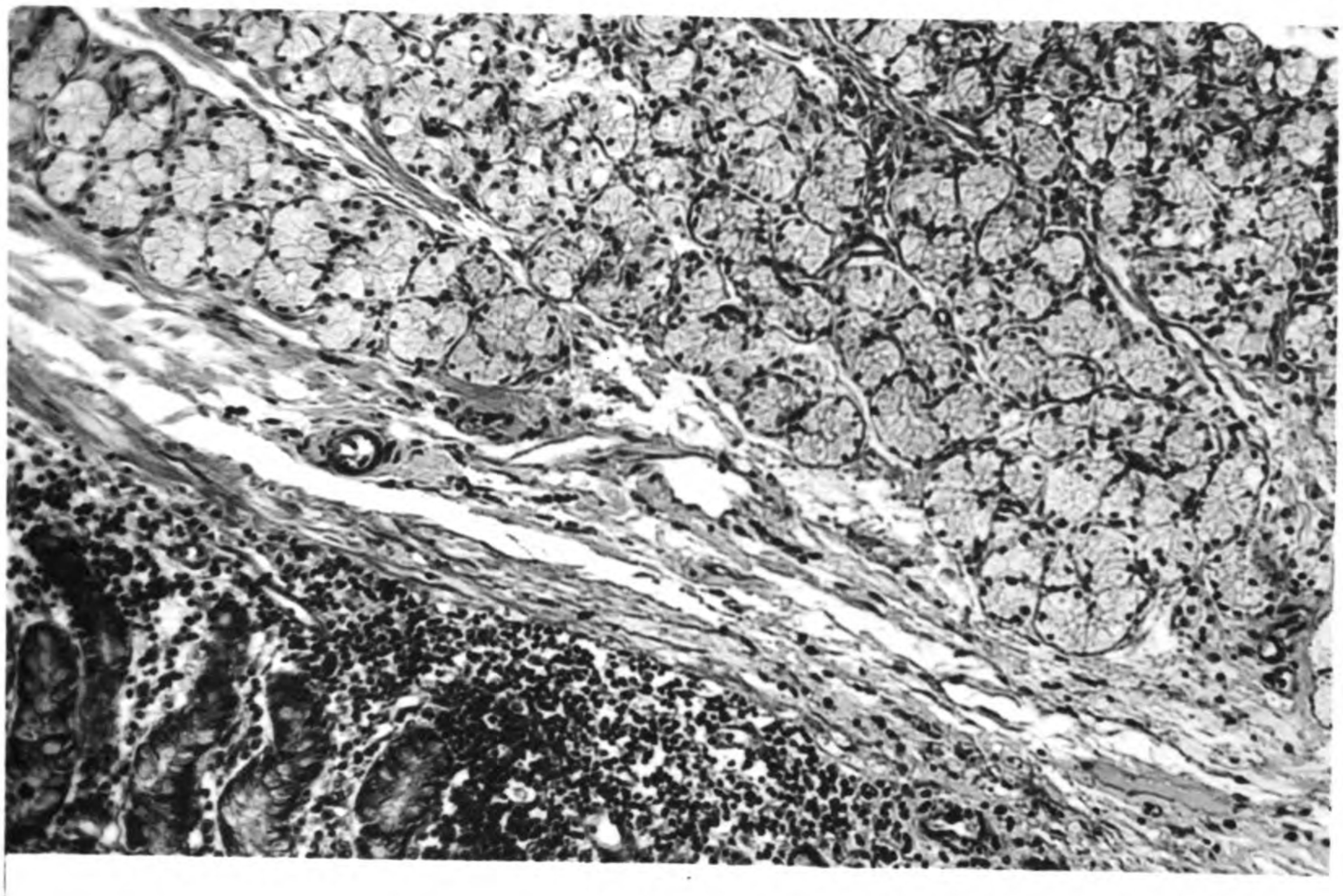

Fig. 1

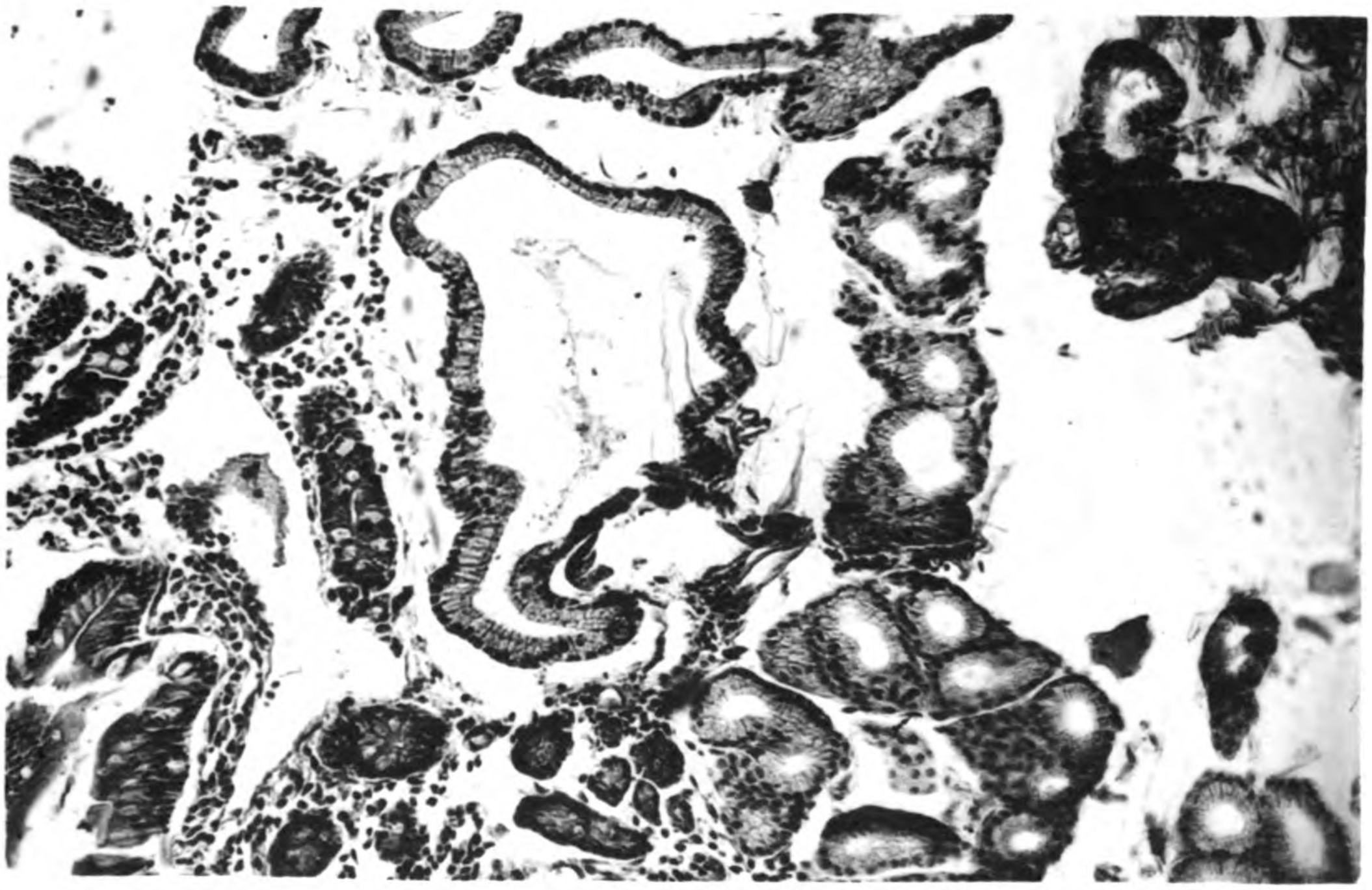

Fig. 2

Plate XIII Brunner's glands. Hematoxylin and eosin. 750X

Fig. 1 Cat. Very low epithelium.

Fig. 2 Goat. Very high epithelium.

## Plate XIII

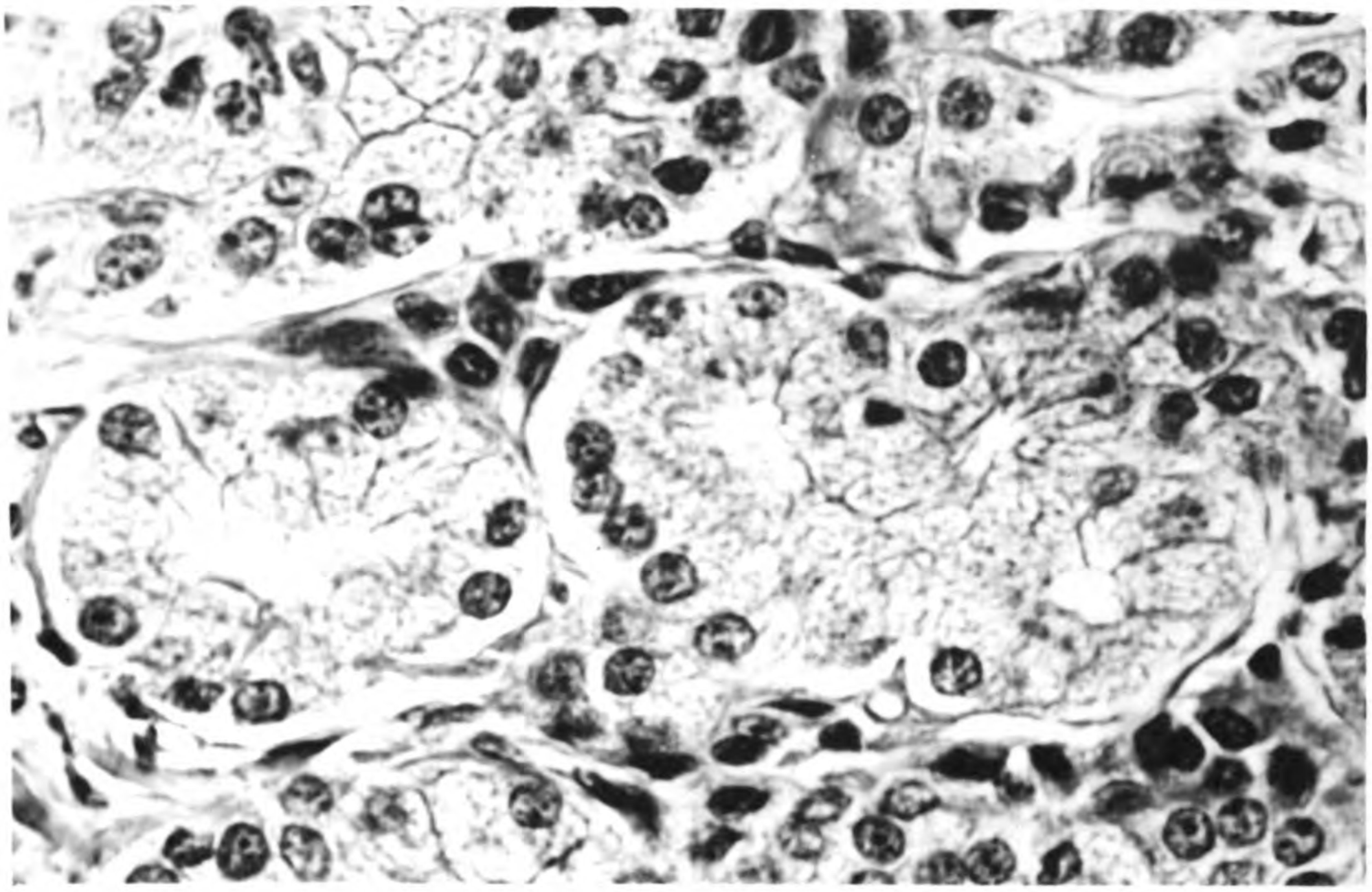

Fig. 1

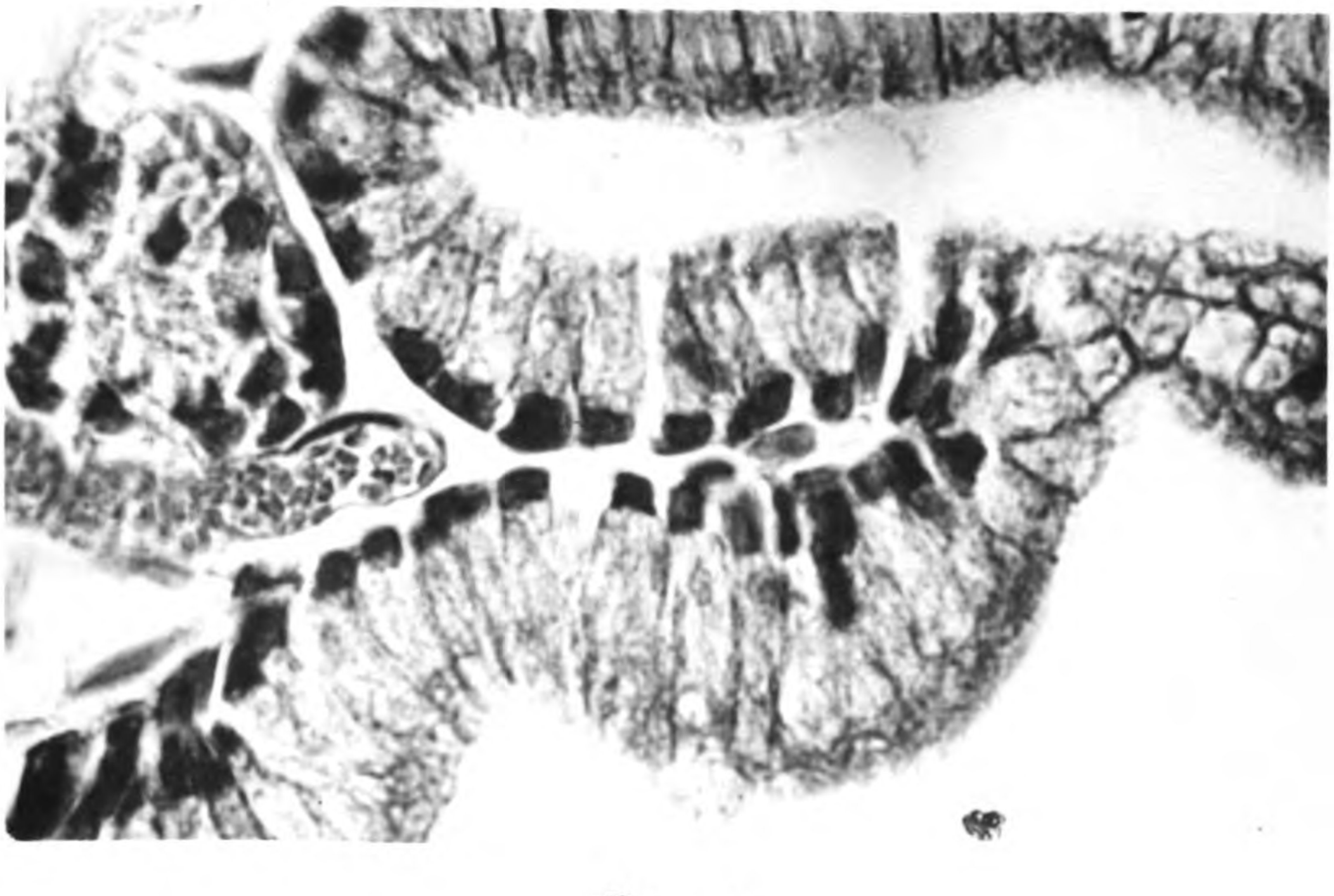

Fig. 2

Plate XIV    Tunica muscularis of dog. Hematoxylin and eosin. 140X

Note the narrow oblique muscle layer next to the submucosa.

## Plate XIV

Plate XV Tunica muscularis of pig. Hematoxylin and eosin. 140X

Typical inner circular and outer longitudinal muscle layers.

## Plate XV



## SUMMARY AND CONCLUSIONS

The small intestines of 39 animals representing seven different species were compared grossly and microscopically. A gross examination revealed that the small intestine of the horse contained the greatest number of Peyer's patches, approximately 85 per animal. The Peyer's patches of the cat were too small to be seen grossly but were found in microscopic section. Those of the dog were the easiest to identify for they were quite evident as thickened elevations even on the exterior of the intestinal tract. Patches in other animals were flat and could be seen only on the interior surface. Most patches were located opposite the mesentery except in the dog where they usually assumed a position on the lateral and medial sides of the gut tube. They were found in the jejunum and ileum of all species studied, and in the dog, were found in the duodenum as well. Most histology texts used by veterinary students are written from a study of human subjects and infer that Peyer's patches are found only in the ileum. This is not true as far as domestic animals are concerned.

Intestinal villi were longest in the cat. Measurements revealed that they averaged 963 microns in height in the cat as compared to 645 in the dog, 615 in the goat, 483 in the sheep, 470 in the hog, 405 in the horse, and 363 in the ox. The height of the epithelial cells on the villi was greatest in the dog (32 microns) and least in the cat (16 microns). No significant difference in the villi height was noted at different levels of the tract.

Shapes of villi ranged from broad and rounded in the horse to very tall and narrow in the cat. All species except the horse showed a distinct narrowing of the villi at their bases. Villi of the carnivores were expanded on their distal ends. No differences in the shapes of the villi at different levels of the tract were noted.

The muscularis mucosae was very narrow in all the species studied except in the dog where it was found to be in two distinct layers either of which was thicker than the muscularis mucosae in the other species. It was approximately three times thicker than the general over-all average of the other animals studied.

Brunner's glands differed widely both as to extent and form. They were very rare in the dog and, in the sections studied, were found at the pyloric-duodenal junction extending over an area of less than 1/5 inch. In the sections taken they were found in only one cow of seven studied. Sisson and Grossman (1938) found that they were scattered throughout the first 12 to 15 feet of the intestine of this species. In the light of this knowledge, it is thought probable that Brunner's glands are rather thinly dispersed in the cow and are easily missed upon microscopic section.

They were found in the jejunum as far as 32 feet from the pylorus in the horse and were rather extensive in all sections in the first 25 feet. In the cat, sheep, goat, and pig, they were readily identified in the proximal part of the intestine. Human histology texts describe Brunner's glands only in the duodenum.

The lumen of the Brunner's glands varied from a high of fifty microns in the goat to a low of three microns in the hog with the sheep, dog, ox, cat, and horse falling between them in that succession. Epithelial cell height on the glands was highest in the dog and goat and lowest in the cat.

The muscle layer varied considerably. It was thickest in the horse where it averaged 1153 microns in width and thinnest in the goat with an average of 175 microns. The carnivores had an extra oblique layer of muscle between the submucosae and the circular layer. In order of decreasing width of tunica muscularis, the succession of animals was found to be horse, dog, ox, cat, hog, sheep, and goat. Table 4 shows various comparisons in the species studied.

## TABLE 4

## COMPARISONS

| Species | Horse | Cow | Sheep | Goat | Pig | Dog | Cat |
|---|---|---|---|---|---|---|---|
| Number of Peyer's patches | 85 | 18 | 25 | 25 | 20 | 22 | None grossly |
| Location of Peyer's patches | Jejunum & ileum | Jejunum & ileum | Jejunum & ileum | Jejunum & ileum | Jejunum & ileum | Duodenum<br>Jejunum & ileum | Jejunum & ileum |
| Plicae circulares | No | Yes | Yes | Yes | No | No | No |
| Height of villi | 405 | 363 | 483 | 615 | 470 | 645 | 963 |
| Height of epith. of villi | 31 | 22 | 25 | 28 | 29 | 32 | 16 |
| Thickness of muscularis mucosae | 26 | 19 | 24 | 15 | 23 | 71 | 15 |
| Location of Brunner's glands | Proximal 32 feet | Proximal 15 feet | Duodenum | Duodenum | Proximal 14 feet | Pyloric-Duodenal Junction | Duodenum |
| Lumen diameter of Brunner's glands | 7 | 25 | 40 | 50 | 3 | 35 | 20 |
| Height of epith. of Brunner's glands | 15 | 12 | 20 | 35 | 25 | 35 | 10 |
| Number of layers in tunica muscularis | 2 | 2 | 2 | 2 | 2 | 3 | 3 |
| Thickness of tunica muscularis | 1153 | 588 | 287 | 175 | 520 | 701 | 555 |

# LITERATURE CITED

Arey, L. B., 1946. Developmental Anatomy. W. B. Saunders Company, Philadelphia.

Arey, L. B. and John Elsen, 1950. On the alleged spiral organization of the wall of the intestine. Anat. Rec., 106:170. Seen in abstract only.

Bailey, Frederick R., 1948. Bailey's Textbook of Histology. Edited by Philip Smith and Wilfred Copenhaver. The Williams and Wilkins Company, Baltimore.

Bremer, J. Lewis and Harold Weatherford, 1944. Textbook of Histology. The Blakiston Company, Philadelphia.

Bujard, E., 1909. Etude des types appendiciels de la muqueuse intestinale, en rapport avec des regimes alimentarres. Inter. Monatschr. f. Anat. U. Phys. 26:1194-1197. Cited by F. P. Johnson (1913).

Calhoun, M. Lois, 1933. The microscopic anatomy of the digestive tract of Gallus domesticus. Iowa State College J. of Science 3:261-382.

Chauveau, A., 1872. The Comparative Anatomy of the Domesticated Animals. Translated and edited by George Fleming. W. R. Jenkins, New York.

Cowdry, E. V., 1932. Special Cytology. Paul B. Hoeber, New York.

Cowdry, E. V., 1944. A Textbook of Histology. Lea and Febiger, Philadelphia.

Cunningham, Daniel, 1931. Cunningham's Textbook of Histology. Edited by Arthur Robinson. Oxford University Press, New York.

Davidson, Alvin, 1937. Davidson's Mammalian Anatomy with Special Reference to the Cat. Edited by Frank A. Stromsten. The Blakiston Company, Philadelphia.

Dorland, W. Newman, 1951. The American Illustrated Medical Dictionary. W. B. Saunders Company, Philadelphia.

Dukes, H. H., 1943. The Physiology of Domestic Animals. The Comstock Publishing Company, Inc., Ithaca.

Elias, Hans, 1947. Duodenal glands in domestic animals. Am. J. Vet. Res. 8:311-313.

Elias, Hans, 1951. Oral Communication. Anatomy Department, Chicago Medical School, Chicago.

Ellenberger, W., 1911. Handbuch der Vergleichenden Mikroskopischen Anatomie der Haustiere. Paul Parey, Berlin.

Florey, H. W. and H. E. Harding, 1934. Secretion of the duodenal glands. J. Path. and Bact. 39:255-276.

Foust, H. L., 1943. Diseases of Poultry. Chapter 1. Edited by H. E. Biester and Louis Devries. The Iowa State College Press, Ames.

Foust, H. L., 1947. Veterinary Microscopic Anatomy and Embryology. Burgess Publishing Company, Minneapolis.

Francis, Carl C. and G. Clinton Knowlton, 1950. Textbook of Anatomy and Physiology. The C. V. Mosby Company, St. Louis.

Guyer, Michael F., 1943. Animal Micrology. The University of Chicago Press, Chicago.

Ham, Arthur Worth, 1950. Histology. J. B. Lippincott Company, Philadelphia.

Hambleton, B. F., 1914. Note upon the movements of intestinal villi. Am. J. Phys. 34:446-447.

Hamperl, H., 1923. Ein Beitrag zur Kenntnis des Dünn-und Dickdarmes der Insektivoren und Chiropteren. Wien. Akad. Anz., 14. Cited by E. V. Cowdry (1932).

Hartman, Carl G. and William Straus, 1933. The Anatomy of the Rhesus Monkey. The Williams and Wilkins Company, Baltimore.

Harvey, R. W., 1908. Variations in the wall of the large intestine and in the number and staining properties of goblet cells. Anat. Rec. 2:129-142.

Heitzmann, C., 1868. Zur Kenntnis der Dünndarmzotten. Sitz. d. k. Akad. Wien, Bd. 58, Abth. 2, S. 253-268. Cited by F. P. Johnson (1913).

Hewer, Evelyn E., 1947. Textbook of Histology for Medical Students. Grune and Stratton, New York.

Hill, Charles, 1934. A Manual of Normal Histology and Organography. W. B. Saunders Company, Philadelphia.

Johnson, Franklin P., 1913. The effects of distention of the intestine upon the shape of villi and glands. Am. J. Anat. 14:235-246.

Jordan, Harvey E., 1940. A Textbook of Histology. D. Appleton-Century Company, New York.

Kahn, Fritz, 1946. Man in Structure and Function. Translated and edited by George Rosen, Alfred A. Knopf, New York.

Kawamura, T., 1930. Ueber die Verteilung der Panethschen Zellen in jedem Abschnitt des Dünndarmes bei einigen Nagern. Abstract, Anat. Bericht. 18:41. Cited by E. V. Cowdry (1932).

Kendall, James I., 1947. Microscopic Anatomy of Vertebrates. Lea and Febiger, Philadelphia.

King, C. E., and L. Arnold, 1922. The activities of the intestinal mucosal motor mechanisms. Am. J. Phys. 59:97-121.

King, C. E., L. C. Glass, and S. E. Townsend, 1947. The circular component of the muscularis mucosae of the small intestine of the dog. Am. J. Phys. 148:667-674.

King, C. E. and Miles H. Robinson, 1945. The nervous mechanism of the muscularis mucosae. Am. J. Phys. 143:325-335.

Kingsley, J. S., 1926. Comparative Anatomy of Vertebrates. P. Blakiston, Son and Company, Philadelphia.

Krogh, August, 1929. The Anatomy and Physiology of Capillaries. Yale University Press, New Haven.

Lambert, Avery E., 1948. Lambert's Histology. Edited by Helen Dawson. The Blakiston Company, Philadelphia.

Lewis, F. T. and J. L. Bremer, 1930. A Textbook of Histology. P. Blakiston, Son and Company, Philadelphia.

Macklin, C. C. and M. T. Macklin, 1926. Is the Mingazzini phenomenon in the villus of the small intestine an evidence of absorption? J. Anat. 61:144-150.

Mall, F. P., 1896. A study of intestinal contraction. John Hopkins Hospital Reports. 1:35-37.

Marshall, Clyde and Edgar L. Lazier, 1946. An Introduction to Human Anatomy. W. B. Saunders Company, Philadelphia.

Martin, C. P. and J. Banks, 1940. The amount of mucosal tissue in the small intestine. J. Anat. 75:135-136.

Martin, F. P., 1910. Vergleichende histologische Untersuchungen über das Oberflächenund Drüsenepithel der Darmschleimbaut der Haussäugetiere. Inaug. Diss. Leipzig. Cited by E. V. Cowdry (1932).

Maximow, Alexander A. and William Bloom, 1948. A Textbook of Histology. W. B. Saunders Company, Philadelphia.

M'Fadyean, J., 1884. The Anatomy of the Horse. William R. Jenkins, New York.

Miller, S., 1927. Effects of inanition on the stomach and intestines of the albino rat underfed from birth for various periods. Arch. of Path. and Lab. Med. 3:26-41.

Möller, W. 1899. Anatomische Beiträge zur Frage von der Sekretion und Resorption in der Darmschleimhaut. Ztschr. f. wiss. Zool., 66:69. Cited by E. V. Cowdry (1932).

Neal, Herbert V. and Herbert W. Rand, 1926. Comparative Anatomy. The Blakiston Company, Philadelphia.

Nonidez, Jose F. and William Windle, 1949. Textbook of Histology. McGraw Hill Book Company, New York.

Paton, Noel D. and John B. Orr, 1920. Essentials of Veterinary Physiology. William Wood and Company, New York.

Piersol, George A., 1910. Normal Histology. J. P. Lippincott Company, Philadelphia.

Reighard, Jacob and H. S. Jennings, 1923. Anatomy of the Cat. Henry Holt and Company, New York.

Romer, Alfred S., 1949. The Vertebrate Body. W. B. Saunders Company, Philadelphia.

Sisson, Septimus and James Daniels Grossman, 1938. The Anatomy of Domestic Animals. W. B. Saunders Company, Philadelphia.

Smithcors, J. Frederick, 1949. Functional Animal Morphology. Unpublished manuscript. Michigan State College, East Lansing.

Sohn, W. T. and L. B. Arey, 1951. The persistence of argentaffine cells in the excised intestine of the dog and rabbit. Anat. Rec. 109:408. Seen in abstract only.

Strangeways, Thomas, 1888. Strangeways Veterinary Anatomy. Edited by I. Vaughn. William R. Jenkins, New York.

Sun, T. P., 1926. Histophysiological study of the epithelial changes in the small intestine of the albino mouse after starvation and refeeding. Anat. Rec. 34:341-349.

Trautman, A., 1910. Zur Kenntnis der Panethschen Körnchenzellen bei den Säugetieren. Arch. f. mikr. Anat., 76:288. Cited by E. V. Cowdry (1932).

Trautman, A and J. Fiebiger, 1931. Lehrbuch der Histologie und Vergleichenden mikroskopischen anatomie der Haussaugetiere. Paul Parey, Berlin.

Vever, G. M., 1948. The Book of the Dog. Chapter 1. Edited by B. Vesey-Fitzgerald. Nicholson and Watson, London.

Volborth, G. W., 1925. The presence of secretin in the intestinal juice. Am. J. Phys. 72:331-336.

Warren, S. L. and G. H. Whipple, 1922. Roentgen ray intoxication, a study of the sequence of clinical, anatomical and histological changes following a unit dose of X-rays. J. Exp. Med. 35:203-224.

Wells, Herbert S. and Ralph Johnson, 1934. The intestinal villi and their circulation in relation to absorption and secretion of fluid. Am. J. Phys. 109:390-391.

Williams, J. F., 1926. Textbook of Anatomy and Physiology. W. B. Saunders Company, Philadelphia.

Winters, A. R. and E. M. Funk, 1946. Poultry Science and Practice. J. B. Lippincott, Philadelphia.