THE MICROSCOPIC ANATOMY OF THE SKIN OF MUS NORVEGICUS ALBINUS

Thesis for the Degree of M. S.

MICHIGAN STATE UNIVERSITY

Robert A. Holmes

1960

MICHIGAN STATE UNIVERSITY

OVERDUE FINES:
25¢ per day per item

RETURNING LIBRARY MATERIALS:
Place in book return to remove
charge from circulation records

6 FEB 8 1982 034

THE MICROSCOPIC ANATOMY OF THE SKIN OF MUS NORVEGICUS ALBINUS

by

Robert A. Holmes

A THESIS

Submitted to the College of Veterinary Medicine
Michigan State University of Agriculture and
Applied Science in partial fulfillment of
the requirements for the degree of

MASTER OF SCIENCE

Department of Anatomy

1960

S 1117
2 14 60

ACKNOWLEDGEMENTS

The author wishes to express his sincere appreciation to Dr. M. Lois Calhoun, Professor and Head of the Department of Anatomy, for her unfailing supervision, direction, and understanding of the problems involved. He is also grateful to Dr. Esther M. Smith for her assistance in the preparation of the plates and the microscopic sections. Thanks are certainly due to those members of the faculty and staff who so graciously contributed suggestions and their excellent assistance. To his wife, for her constant help and inspiring words, the author is deeply indebted and grateful. The author wishes to make grateful acknowledgement to The Upjohn Company for the support of this study.

TABLE OF CONTENTS

	PAGE
INTRODUCTION	1
REVIEW OF LITERATURE	2
Epidermis	3
Dermis	6
Hair	7
Sebaceous Glands	8
Sweat Glands	9
MATERIALS AND METHODS	10
RESULTS AND DISCUSSION	12
Skin Thickness	12
Epidermis	14
Stratum Corneum	14
Stratum Granulosum	14
Stratum Germinativum	15
Basement Membrane	16
Dermis	16
Stratum Papillare	16
Stratum Reticulare	17
Collagenous Tissue	17
Elastic Tissue	17
Mast Cells	18
Hair Follicles	19
Follicular Folds	20
Tactile Hairs	20
Mm. Arrectores Pilorum	21

PAGE

Sebaceous Glands..... 21

Sweat Glands..... 21

Special Body Areas..... 22

Pinnae..... 22

Eyelids..... 23

Lips..... 23

Planum Nasale..... 24

Foot Pads..... 24

Teats..... 24

Scrotum..... 25

Tail..... 25

Perianal Region..... 25

Anus..... 26

Prepuce..... 26

Labia..... 27

Body Areas From Which Tissues Were Taken..... 28

SUMMARY AND CONCLUSIONS..... 32

LITERATURE CITED..... 40

LIST OF TABLES

TABLE PAGE

1. Measurements of Epidermal Thickness of Albino Rat in Microns 29
2. Measurements of Dermal Thickness of Albino Rat in Microns 30
3. Measurements of Total Skin Thickness of Albino Rat in Microns 31

LIST OF PLATES

PLATE		PAGE
I.	Longitudinal section of ventral abdomen showing folds....	45
II.	Longitudinal section from tail root showing folds.....	46
III.	Longitudinal section of fore leg medial surface showing folds.....	47
IV.	Longitudinal section of lumbar region.....	48
V.	Longitudinal section through metacarpal foot pad showing epidermal pegs.....	49
VI.	Section through the metacarpal foot pad.....	50
VII.	Section through the planum nasale.....	51
VIII.	Cross section through the distal tail showing hair grouping	52
IX.	Longitudinal section of anorectal junction.....	53
X.	Cross section through anus.....	54
XI.	Longitudinal section through pinnal tip.....	55
XII.	Longitudinal section through center section of pinna.....	56
XIII.	Longitudinal section through the digital pad and claw.....	57
XIV.	Longitudinal section of teat.....	58
XV.	Section of tail root showing well developed stratum granulosum	59
XVI.	Longitudinal section through lower eyelid and portion of palpebral conjunctiva, with characteristic epithelium....	60
XVII.	Section of palpebral conjunctiva showing goblet cells and clear cells.....	61
XVIII.	Section of tail showing the basement membrane.....	62

PLATE PAGE

XIX. Section of tail showing reticular fibers of basement membrane..... 63

XX. Medial surface of fore leg showing elastic tissue..... 64

XXI. Frontal section of the tail root showing cross section of hair pattern..... 65

XXII. Frontal section of the shoulder showing linear hair pattern..... 66

XXIII. Longitudinal section of lateral abdomen showing follicular folds..... 67

XXIV. Longitudinal section of eyelash in upper eyelid..... 68

XXV. Cross section of tactile hair in the nose..... 69

XXVI. Sebaceous gland opening into follicle..... 70

XXVII. Sweat glands in the metacarpal pad..... 71

XXVIII. Longitudinal section of upper eyelid..... 72

XXIX. Longitudinal section of lower lip..... 73

XXX. Cross section of prepuce..... 74

XXXI. Cross section of labium..... 75

XXXII. Longitudinal section of scrotum..... 76

INTRODUCTION

This study resulted from the lack of a detailed histological description of the normal albino rat skin. A histological study of all other organ systems is being carried on by Dr. M. Lois Calhoun and Dr. Esther M. Smith of the Department of Anatomy, Michigan State University, East Lansing, Michigan, and supported by The Upjohn Company, Kalamazoo, Michigan.

Upon completion, it is hoped that this information will serve as a comparative histological reference for the scientist and the research worker.

REVIEW OF LITERATURE

A careful search of the literature revealed comparatively little work on the histology of skin, particularly that of the rat.

Montagna (1956), who has made notable contributions to the study of mammalian skin, stated that the main reason so little work has been done in this field is because skin is a difficult tissue to prepare for histological and cytological study. The cytologist has usually avoided it because it is hard to make preparations of skin which are well oriented and free from tears, folds, and compression.

Bailey (1958), Arey (1957), Maximow and Bloom (1957), Ham (1957), and Stiles (1956), described the human integument; and Sisson and Grossman (1956), and Trautmann and Fiebiger (1957) recorded a comparable description for domestic animals.

Andrew (1951) studied age changes in the skin of the albino rat with particular reference to the epidermis. He found no evidence of a consistent atrophy or thinning of the epidermis in old age, or degeneration of collagenous or elastic fibers, but found an increase in amount of elastic tissue.

Andrew and Andrew (1956) stated that the rat abdominal skin has a configuration considerably different from that of the back. The latter surface is smooth, while on the abdomen a series of overlapping units are present. Trautmann and Fiebiger (1957) wrote that displacing and folding of skin is dependent on the development of the hypodermis.

According to Sisson and Grossman (1956) the thickness and color of the skin varies with age, sex, species, and body region.

Frazer (1928) studied in detail the skin development of the back of the albino rat until the eruption of the first hairs.

EPIDERMIS

The mammalian epidermis consists of a four layered stratified squamous epithelium. The most superficial layer is the stratum corneum consisting of several layers of cornified cells without nuclei. Very little cornification is present on ordinary skin, but on the palms and soles, the cornified layers make a very thick stratum (Arey, 1957). Beneath the corneum lies the stratum lucidum, consisting of a layer of clear flattened cells with few nuclei. The stratum granulosum is composed of nucleated, less flattened granulated cells approximating the lucidum. The stratum germinativum or Malpighian layer is composed of two cell layers. The basal layer consists of columnar or cuboidal elements with processes attaching it to the basement membrane. The next higher cells are polygonal in shape and are surrounded by "intercellular bridges" which appear like projecting spines, accounting for their being named "prickle cells" (Arey, 1957; Bailey, 1958; Maximow and Bloom, 1957; Stiles, 1956). Horstmann and Knoop (1958) demonstrated tonofibrils, which are composed of tonofilaments, combined in strands of different thickness, present in the epidermis. Trautmann and Fiebiger (1957) divided the epidermis into two main layers: the succulent deep layer (stratum germinativum or Malpighi), and the superficial horny layer. These are further subdivided -- the deep layer into two, the superficial layer into three, secondary layers. Starting from the corium they named the layers: the stratum cylindricum, the stratum spinosum, the stratum granulosum, the stratum lucidum, and the stratum corneum proper.

According to Thuringer (1924) the term stratum germinativum should include the single basal layer of cells, the stratum cylindricum, and the entire stratum spinosum; in other words, the rete Malpighi or rete mucosum. He further stated that new cells not only reproduced in the lower layers of the stratum germinativum, but throughout the entire stratum spinosum.

It was concluded by Butcher (1957) that the normal rat epidermis consists of a layer of basal cells which are usually columnar in shape and are arranged in a single layer; the cells superficial to this layer have their long axis in a horizontal position and contain small granules. He stated that a single layered granulosum is usually present but that no lucidum is found and that four or five layers of nonadherent cells make up the stratum corneum. Frazer (1928), in describing the back skin of a 150-day-old rat, gave the measurements of the four epidermal strata with a description of each. Hanson (1947) defined the epidermal strata of both the rat and mouse, with a corresponding description.

The investigations of the albino rat's dorsal skin by Ebling (1953) showed the stratum germinativum to reach its greatest thickness during pro-estrus and to be considerably reduced in size during estrus.

Erickson (1931), in his studies of the postnatal rat epidermis, learned that the microscopic structure of the adult rat is similar to that of a fourteen-day-old rat except that the stratum corneum attains a much greater thickness. The germinativum is only half as thick as it is in the newborn rat. The growth of the epidermis is greater in younger than in older rats. Spain (1915) found the thickness of the rat epidermis to be directly proportional to the number of mitoses and the proliferative power of epithelium.

Storey and Leblond (1951) estimated the complete cycle of epidermal cell regeneration to be 19.1 days for the plantar epidermis of adult rats. Medawar (1953) stated that the epidermal epithelium does not present a plane surface to its substratum, the dermis or corium, but is thrown into a pattern of "hills and valleys" that are exactly complementary in structure to the dermal papillae. The thicker the epithelium, the bolder are these inequalities of depth. In the general body skin of a hair-bearing mammal, the "hills" are low and rounded, and the "valleys" correspondingly broad and shallow.

Andrew and Andrew (1949), in a detailed study of lymphocytes in the normal epidermis of the white rat, stated that lymphocytes make up about 1-4% of the stratum germinativum cells, with most of these being located in the basal layer. They reported the lymphocytes to be the precursors of the "clear cells", with the intermediate cells being the transitional stage between the two. The cytoplasm of the "clear cells" differentiates into ordinary epidermal cells. Similar studies made by Andrew and Andrew (1956) revealed a significantly smaller number of lymphocytes in comparison to the epidermal cells on the abdomen than on the back of young and middle-aged rats. The lymphocyte count in the abdominal epidermis is considerably smaller in twenty-one-day-old rats than in older rats.

It was further found by Andrew and Andrew (1954) that the stratum germinativum of young and middle-aged rats has prominent large vesicular nuclei presenting a crowded appearance. The stratum granulosum is lacking and the stratum corneum is loosely adherent in the same age group. In aged rats the stratum granulosum is always present and well developed showing large basophilic masses. The

corneum in the aged group proved to have closely compact lamellae.

The presence or absence of a basement membrane between the epidermis and dermis has been a topic of much discussion. The orthodox view has been that there is no basement membrane but that the dermis and epidermis are held together by foot processes of the basal epidermal cells interlocking with the reticular fibers of the dermis. Cooper (1958) discovered that by using proper staining methods a basement membrane and reticulum can be distinguished. Porter (1954), using the electron microscope, demonstrated the presence of a basement membrane in the tail epidermis of Amblystoma larvae. Odland (1950) believed the basement membrane to be a complex argyrophilic reticulum, the meshes of which contain the cytoplasmic processes of the basal epidermal cells.

DERMIS

The dermis of the rat is composed largely of collagenous and elastic connective tissue in which are found sweat glands, sebaceous glands, blood vessels, lymphatics, nerves, and hair follicles. The dermis has two layers, an outermost papillary layer named from its papillae which penetrate the stratum cylindricum of the epidermis, and a deeper reticular layer which has a network of reticular fibers as well as fibrous and elastic elements (Trautmann and Fiebiger, 1957). According to Erickson (1931) the dermis of the newborn rat is distinguished from the underlying subcutaneous tissue by being more cellular and less fibrous. Lovell and Getty (1957) expressed the view that the blood vessels and nerve trunks in the dog are larger in the deeper layer of the dermis than in the superficial, and the connective

tissue and reticular fibers are more numerous just beneath the epidermis. Robb-Smith (1945) observed collagenous bundles of variable coarseness arranged in different directions in the dermal stroma. Among these bundles are elastic fibers, reticulum, muscles, nerves, arteries, histiocytes, and undifferentiated mesenchymal cells.

HAIR

According to Butcher (1934) and Storey and Leblond (1951), hair growth in the young albino rat is cyclic, occurring approximately every thirty-five days. At the turn of the century, Calef (1900) described what he called the epithelial appendage in the white rat. He showed that the sebaceous gland and the epithelial appendage arise from a zone of proliferating cells in the external hair sheath, on the side of the hair making the greater angle with the epidermis. From this appendage arise one or more accessory hairs whose follicles and sheaths are adherent to those of the principal hair making a composite follicle, also described by de Meijere (1894). Becker (1952) reported that periodic hair growth begins in six-week-old rats. According to Dieke (1947) the phenomena of hair growth in rodents was extensively studied by Dry in 1928. According to Jackson and Lowrey (1912) the hair coat does not become well developed until the second or third week. Rice and Jackson (1934) discovered well developed hair follicles in newborn rats even though the hairs are not visible. Schamberg and Saleeby (1930) observed that hair growth in animal life is most rapid the first eighteen days postpartum. Johnson (1958) reported the hair growth wave in female albino rats to be slower than in males. Lobitz (1957) proved that hair follicle development is divided into three main

growth stages. Durward and Rudall (1949) stated that inactive hair follicles lie quiet in the dermis whereas active hairs extend down as far as the panniculus carnosus. Erickson (1931) supplied a microscopic description of the hair and follicles of different-aged rats.

De Meijere (1894) concluded that the final arrangement of hair pattern in the gray rat is not reached until forty days after birth. Donaldson (1924), in his work with rats, learned that the hairs of white rats are arranged in groups of nine.

Davidson and Hardy (1952) determined that all vibrissae follicles in the mouse are distinguished from pelage hair follicles by possessing blood sinuses and abundant nerve endings. According to Vincent (1913) and Greene (1959) the principal tactile hairs of the white rat are innervated by branches of the maxillary division of the trigeminal nerve.

Kiil (1949) and Trotter and Dawson (1932) presented evidence that hair slope is caused mainly by the differentiation of growth in surrounding skin layers and factors of tension during the period of follicle development.

SEBACEOUS GLANDS

Sebaceous glands were first described in 1826 by Eichorn. They are true holocrine glands and are present in the skin of all mammals and function even before birth. Most sebaceous glands are attached to hair follicles and open into pilosebaceous canals. The gland size usually varies inversely with the diameter of the associated hair (Lobitz, 1957). According to Montagna and Noback (1947) the sebaceous glands of the rat are small, holocrine, acinar glands which lie in the

connective tissue of the dermis and are surrounded by areolar tissue rich in fibroblasts and mast cells.

Parnell (1949) observed a progressive increase in the size of sebaceous glands in the rat from birth to sexual maturity due to proliferation of new sebum-filled sebaceous cells. Ebling (1953) reported the sebaceous glands in the dorsal skin of albino rats to reach their maximum size during proestrus.

SWEAT GLANDS

According to Way and Memesheimer (1936), Steno in 1683 was the first to mention the cutaneous openings of the sudoriparous glands and a year later, Grew observed them. Sweat glands were described by Breschet and de Vauzeme in 1834 and Gurlt in 1835. Robin in 1845 published valuable contributions on the subject.

Winkelmann (1956) credited the early histologists such as Kolliker in 1854, with recognizing the epidermal portion of the duct of the eccrine gland as being a separate entity from the epidermis proper. Ring and Randall (1946) observed the ducts to be tightly-spiralled tunnels through the epidermis.

Marzulli and Callahan (1957) reported that certain laboratory animals did not sweat in the hairy skin but observed active sweat glands on the foot pads of the dog, cat, and rat. Nielsen (1953) disproved the erroneous belief that dogs have sudoriferous glands only on the foot pads, but that they are distributed over the entire body skin and extremities.

Pinkus (1939) reported that most investigators of the epidermis and sweat duct believe the duct to lose its own lining epithelium when it enters the epidermis and that sweat flows through the epidermis in a channel formed by compression of prickle cells.

MATERIALS AND METHODS

Skin for this study was taken from five female and five male normal albino Wistar strain rats, five to six weeks of age, weighing from 115-131 grams. The animals were obtained from The Upjohn Company rat colony, Kalamazoo, Michigan.

The rats were sacrificed by electrocution. The skins were removed, fixed in 10% neutral formalin for seventy-two hours, then transferred to 70% alcohol until used.

Frontal specimens ranging from 3-6 mm square and longitudinal specimens from 3-6 mm long were taken from thirty-four skin areas as indicated in Figure A. After dehydration and infiltration by the method of Johnson, et al. (1943), tissues were imbedded in Tissuemat* and sections cut at six microns.

Two slides of each section were stained with Harris' hematoxylin and eosin (Malewitz and Smith modification, 1955), Weigert's and Van Gieson's connective tissue stain, Wilder's reticulum stain, Wright's stain, and by the P.A.S. (Periodic Acid-Schiff) reaction. Certain sections were stained with toluidine blue to determine the presence of mucus-secreting glands.

Epidermal and dermal measurements were made with a calibrated ocular micrometer. The thickness of each area was calculated by obtaining the average of five different observations. The averages

ventral, agreeing with the findings of Strickland (1958) for the cat, and Goldsberry and Calhoun (1959) for cattle.

The average epidermal thickness in males is 23.1 microns and 22 microns in females (Table I). Lovell and Getty (1957) reported the average epidermal thickness in mongrel dogs to be thirty to forty microns. According to Strickland (1958), the average epidermal thickness of the cat is 25 microns. Webb and Calhoun (1954) reported the thinnest epidermis of mongrel dogs to be 26.5 microns in the sternal region.

The thickest epidermal areas in the rat are in the metacarpal pads measuring 457 microns (Plates V and VI), the planum nasale 96 microns (Plate VII), the tail 77 microns (Plate VIII), and the anus 56 microns (Plates IX and X). Because of this greater than average thickness, these areas are referred to as special and thus excluded from average skin measurements. The thickest epidermal measurements of the digital pads and planum nasale measured 900 microns in the cat (Strickland, 1958) and 1800 microns in mongrel dogs (Lovell and Getty, 1957).

The thickest epidermis of the average hairy skin areas is in the lateral abdomen and tail root (Plate II) measuring 27.3 and 25.6 microns respectively. The thinnest epidermis is located in the pinna (Plates XI and XII) and measures 17.1 microns (Table I).

The dermal thickness averages 342 microns in the male and 331 microns in the female. The dermal thickness varies from 81.9 microns in the pinna to 733 microns in the lumbar region (Tables III and IV). A thick dermis is accompanied by a thick epidermis in the lumbar area

(Plate IV) and a thin dermis with a thin epidermis in the pinna (Plates XI and XII) and medial fore leg (Plate III).

EPIDERMIS

The epidermis consists of three layers: a superficial stratum corneum composed of lamellae which separate readily in preparation, a stratum granulosum which varies in appearance, and a stratum germinativum only a few cells thick. A stratum lucidum could not be found.

Stratum Corneum

A stratum corneum is present in all body areas. The corneum varies from three to thirteen microns in thickness in the hairy skin, but measures 329 microns at the widest point in the digital pad of the hind foot (Plate XIII). The corneum is also well developed in the planum nasale and tail (Plates VII and VIII). In the thin cornified areas it is always basophilic, but in those thicker areas of cornification, the deeper layers are eosinophilic. These findings agree with those of Andrew (1951).

Stratum Granulosum

A conspicuous stratum granulosum is present in all of the areas studied. In the lumbar region (Plate IV), planum nasale (Plate VII), foot pads (Plate XIII), teats (Plate XIV), tail root (Plate XV), and the scrotum (Plate XXXII), the granulosum is several cell layers thick. The cytoplasm contains keratohyalin granules which vary in size (Plate XV). The remaining areas consist of a single layer of cells.

Stratum Germinativum

The stratum germinativum consists of a lower basal and a more superficial spinous layer. It varies in thickness from two to four cell layers in the hairy skin (Plates I, II, III, and IV), to many in the foot pads and planum nasale (Plates V, VI, and VII). The basal cells are usually arranged in a single row, being large cuboidal or columnar in shape and perpendicular to the surface. The nuclei appear crowded and contain basophilic granules and deeply staining nucleoli in light basophilic karyoplasm, as described by Andrew (1951). The cells in the spinosum have flattened nuclei which lie parallel to the surface, more cytoplasm and are less crowded than in the basal layer.

The epidermis consists of four types of cells. The ordinary epidermal cells have been mentioned and are most abundant. The "clear cells" (Andrew and Andrew, 1954) (Plates XV, XVI, and XVII), which approximate the epidermal cells in size, have clear cytoplasm and distinctive vesicular nuclei lacking nucleoli. They are the most abundant cell next to the ordinary epidermal cell. The "clear cells" constitute over 8.9% of the cells in the stratum germinativum, according to Andrew and Andrew (1954). Lymphocytes are also present in very small numbers and possess the typical round basophilic nuclei. The greatest number of "clear cells" and lymphocytes are found throughout the palpebral conjunctivae (Plates XVI and XVII), which are a continuation of the lid margin. The epithelium in the lid changes from stratified squamous to layers of cylindrical "clear cells" and surface goblet cells. Goblet cells are P.A.S. positive and

toluidine blue stain reveals them to be mucus-secreting. The "clear cells" are neither P.A.S. positive nor mucus-secreting. The nuclei of the "clear cells" become somewhat flattened as they approach the surface. The basal layer is the most common location of the lymphocytes and "clear cells" but they may be found in the spinous layer.

BASEMENT MEMBRANE

By histochemical methods, a basement membrane can be demonstrated in the rat skin. The tail shows a P.A.S. positive dermal-epidermal basement membrane (Plate XVIII). A reticulum stained tail section reveals the membrane to be composed of many reticular fibers (Plate XIX).

DERMIS

The dermis of the rat is richly cellular and its stroma is formed of collagenous bundles and intermingled elastic and reticular fibers. The dermis contains muscles, nerves, blood vessels, histiocytes, lymphocytes, mast cells, and fibroblasts. It is separated into a superficial stratum papillare and a deeper stratum reticulare, a division which is difficult to identify (Plates I, XX).

Stratum Papillare

The stratum papillare is composed of many spindle-shaped fibroblasts with clear nuclei and smaller dermal cells with densely staining nuclei. The collagenous fibers are relatively fine, vary in

looseness in the different body areas, and are usually parallel to the epidermis. The elastic connective tissue branches freely, forms no particular pattern, and runs both parallel and perpendicular to the surface (Plate XX).

Stratum Reticulare

The stratum reticulare has fewer fibroblasts and the collagenous and elastic fibers are thicker than those of the papillary layer. The elastic fibers in this area run more parallel to the epidermis than those of the papillary layer and are in abundance about the sebaceous glands, hair follicles, and in the vessel walls.

COLLAGENOUS TISSUE

The collagenous fibers display varying degrees of looseness and compactness in the body regions studied. The fibers of the back (Plate IV) and medial surface of the fore leg (Plate III) are loosely arranged; while those of the foot pad (Plates V and VI), planum nasale (Plate VII), and tail (Plate VIII) are more dense. The ventral abdomen (Plate I) and ear (Plate XII) are intermediate in degree of denseness. The superficial fibers usually are more parallel to the surface and are finer than those of the deeper layers.

ELASTIC TISSUE

The elastic tissue of the integument ramifies between the collagenous bundles and presents a network of branching fibers. In most of the hairy areas, the coarser fibers are found deep in the dermis and hypodermis, and tend to run parallel to the surface. The

finer fibers which are located just beneath the epidermis are less uniform in pattern and fibers reach out toward the basal layer of the germinativum (Plate XX). Andrew (1951) reported similar findings. There is an absence of elastic fibers in the tail, except in the immediate vicinity of the hair follicles. Increased amounts of thick elastic fibers are seen in the medial surface of the fore leg. The elastic fibers in the lip region are perpendicular to the surface while those in the eyelid are thicker and lie parallel to the lid surface. The tarsus is heavily infiltrated with elastic fibers which enclose the Meibomian glands of the eyelid. Just above the palpebral conjunctivae and in the ear are numerous minute fibers which are perpendicular to the surface. The ear cartilage is enveloped by dense elastic as well as collagenous fibers.

MAST CELLS

Mast cells are seen throughout the dermis and hypodermis (Plate XX). The greatest numbers approximate the blood vessels and hair bulbs in the hypodermis and stratum reticulare of the dermis. The characteristic mast cells of the dermis are approximately eight microns in diameter. The mast cells are of two types, the first are found just below the epidermis and are quite small and polymorphous. They possess small nuclei and cell cytoplasm containing fine granulations with conspicuous metachromasia. Those cells deeper in the dermis and hypodermis are larger, have more cytoplasm and larger nuclei. The increased number of granules may fill the cells and obscure

the nuclei. These are the cells found approximating the blood vessels. These findings were reported by Hellstrom and Holmgren (1950), who observed them in the human skin and heart. There are no mast cells in the dermis of the tail, but they are present enveloping the large hair follicles in the panniculus adiposus. The dermis of the nonhairy digital pad has only an occasional mast cell, but greater numbers may be seen in the hypodermis. The nonhairy planum nasale has almost as many mast cells as are found in the hairy skin.

HAIR FOLLICLES

The general body hair of the rat is arranged in well defined groups of follicles. The central follicles appear in linear form but alternate position from row to row producing a cobblestone appearance. These large central follicles may or may not be present in each cluster. The groups are separated by connective tissue and usually contain from three to nine secondary follicles (Plates XXI and XXII).

Examination of the hairy skin reveals hairs in various stages of development. The roots of active hairs may extend down to the panniculus carnosus and often parallel it for some distance. The inactive hairs lie dormant and are found only in the dermis.

The hair shaft tapers from within the follicle toward its tip. It is covered with a scale-like cornified cuticle which flares outward toward its tip but which does not completely encircle the cortex. The thickness of the shaft as it emerges from the epidermis is approximately ten microns. Pigmentation is absent in the hair of the albino rat. These findings agree with those of Frazer (1928).

There is no apparent sex difference in hair density or pattern.

Follicular Folds

Follicular folds in the epithelial sheaths of the guard hairs observed by Goldsberry and Calhoun (1959) in cattle and Strickland (1958) in cats are also present in the rat (Plate XXIII). The folds are located just below the opening of the sebaceous duct into the hair follicle and are more prominent and prevalent on the side of the follicle making the least angle with the surface of the integument. The nuclei of the cells forming the epithelial sheaths are in a horizontal position but in the region of the folds are drawn into a perpendicular position. The function of these folds has not been determined but are probably formed by the relaxed position of the hair follicle.

Tactile Hairs

The tactile hairs are located on the upper and lower lips, the cheeks, above the eyes, and on the carpal joints of the fore limbs. They are enclosed in thick connective tissue sheaths within which are blood sinuses. The sinuses are crossed by connective tissue fibers in the lower portion of the follicles, but these are absent more superficially. Large nerve fibers penetrate the dermal sheaths and striated muscle fibers are attached to the sheaths to move the follicles (Plates XXIV and XXV). Medullae are not visible in the shafts in cross or longitudinal sections. The average widest diameter of the oval follicle measures approximately 635 microns.

Mm. Arrectores Pilorum

The arrectores pilorum muscles are composed of smooth muscle fibers which connect to elastic fibers of the dermal papillary layer. They insert just below the sebaceous glands in collagenous and elastic connective tissue of the follicles. These smooth muscles are attached to the follicles near their midpoints and control the movement of the hair shafts. They are seen in most hairy skin but are best developed in the lumbar (Plate IV) and tail root sections. The arrectores muscles are not found in connection with the eyelashes, hairs of eyebrows, and tactile hairs.

SEBACEOUS GLANDS

The sebaceous glands of the rat vary in size, are both single and lobed and are imbedded in the connective tissue of the dermis. The glands are usually associated with pelage and tactile hair follicles, but some are free and open directly onto the skin surface. Those related to the hairs are located about midway down the follicles in the angles formed by the follicles and the arrectores pilorum muscle bundles. The ducts of the glands open into the necks of the follicles, and their squamous epithelium is continuous with that of the epidermis. The sebaceous glands are holocrine in type and contain enlarged degenerating glandular cells filled with lipid droplets (Plate XXVI). The acini contain varying amounts of sebum.

SWEAT GLANDS

In this study, the sweat glands are not observed in any hairy skin but are found only in the palmar and plantar surfaces (Plate XXVII).

The glands are of the eccrine type and consist of a tightly coiled secretory end piece located in the dermis, a slightly coiled duct, and a more tightly spiralled opening through the epidermis. The glands are surrounded by loose collagenous fibers, elastic fibers, and fat, and empty their watery fluid mainly onto the pads of the feet. The glands are one cell thick. These cells are prism shaped and contain prominent nuclei located at their apex. The area immediately surrounding the glands is quite vascular and well supplied with nerve bundles.

SPECIAL BODY AREAS

Pinnae

The pinnae are covered with an epidermis four to six cells thick. As it approaches the pinnal tip, the epidermis doubles in thickness and measures forty-two microns. The medial or inner pinnal surface possesses a thicker epidermis than the lateral or outer surface. This is probably a result of the natural ear contour which produces a relaxed medial epithelium and a slightly stretched lateral epithelium.

The dermis on the lateral surface is slightly thinner than that of the medial surface. Within the dermis of both surfaces are sebaceous glands and follicles. Sebaceous units are equally prevalent on both surfaces microscopically but hair shafts are not always visible. A single gland is usually associated with each follicle and is located about the same level as the bulb. There is no visible panniculus carnosus, but adipose tissue is present on both sides of the elastic cartilage.

The auricular skeletal muscle approximates the lateral surface of the elastic cartilage for two-thirds the length of the pinna (Plates XI and XII).

The continuity of the auricular cartilage is interrupted by perforations. These perforations serve as channels for the passage of blood vessels and connective tissue elements (Plate XII).

Eyelids

The eyelids are moveable folds of skin which protect the cornea from injury and the retina from excessive light stimulation. Covering the outer surface of the lid is a narrow epithelium which becomes a thickened, stratified squamous epithelium at its tip, measuring between fifty and fifty-five microns. The stratified squamous epithelium is continuous with that of the palpebral conjunctiva which lines the inner side of the lid. Arrectores pilorum muscles are not seen with the follicles in this area.

The sebaceous glands of the upper eyelid are large and enclosed within the tarsal plates. The glands are arranged in a row and their ducts open onto the lid margin (Plate XXVIII).

The lower lids are similar but the tarsal plates are smaller and the sebaceous glands are fewer and smaller (Plate XVI).

Lips

The lips possess a hairy surface including tactile hairs and various sized sebaceous glands and a nonhairy oral surface with a thickened epidermis. This hairy skin thickens as it approaches the oral surface, which is composed of stratified squamous epithelium measuring 78 to 104 microns (Plate XXIX).

Planum Nasale

The planum nasale is composed of a thick stratum corneum covering a prominent stratum granulosum. The thicker germinativum sends pegs into the dermis and has a basal layer of darkly staining crowded cells. The dermis has a stratum papillare of rather fine fibers but a reticulare of dense well-developed fibers (Plate VII).

Foot Pads

The metacarpal and metatarsal pads have a thick stratum corneum that ranges from 85 to 182 microns. The germinativum measures from 167 to 326 microns. The dermis of the pads ranges from being very thin in one area to a maximum thickness of 436 microns in another area. Sweat glands and Meissner's corpuscles are seen within the dermis (Plates V, VI, and XIII).

Teats

The teats of the immature female rat are completely devoid of hair and sebaceous glands. The epidermis is four or five cells thick, ranging from thirty-five to forty-two microns except in the epidermal pegs, which are considerably thicker. The stratum corneum is from five to six microns thick and appears more closely adherent to the granulosum than in other skin areas. The stratum granulosum ranges from one to five deeply staining layers.

The dermis is composed of elastic and rather dense collagenous fibers. Papillae are seen between the epidermal pegs. The teat canal is lined with stratified squamous epithelium (Plate XIV).

The teats cannot be demonstrated in five-week-old males even by depilation and skin clearing.

Scrotum

The scrotal skin is characteristically folded. The epidermal thickness of the scrotum consists of one or two cells and ranges between twenty and twenty-six microns. The stratum corneum is thin and loosely lamellated. The stratum granulosum consists of one to three prominent layers. The dermal connective tissue is loose and the collagenous fibers are comparatively fine. Many pilosebaceous units are seen but sweat glands are absent. A thick panniculus adiposus is present, covering a somewhat discontinuous panniculus carnosus (Plate XXXII).

Tail

The tail skin is characterized by a thick dermis which decreases in thickness from its proximal to distal end and ranges in thickness from 221 to 512 microns. Conversely, the germinativum appears to increase in thickness from proximal to distal and ranges between forty and fifty-seven microns. The corneum of the tail ranges from thirty-one to forty-three microns. Groups of three thick, short hairs appear from beneath the scaly epidermis (Plate VIII).

Perianal Region

The perianal epithelium measures twenty-six to thirty-seven microns, six to seven microns of this being the stratum corneum. In

this area, tufts of fine hairs and large, spherical, perianal glands are observed. These glands contain a copious amount of sebum and open into the anal canal by means of central ducts (Plate IX). A similar description of the anal glands was given by Montagna and Noback (1947).

Anus

The anus (Plates IX and X) is covered with a stratified squamous epithelium ranging from forty-one to seventy-three microns. The stratum corneum makes up only seven to eight microns of this epithelium. A prominent stratum granulosum is seen. The stratum spinosum is sparsely inhabited with cells, but the basal layer is prominent and darkly staining. The dermis is composed of a loose network of collagenous fibers in which are imbedded groups of macroscopic perianal glands described above.

Prepuce

The preputial skin is thrown into multiple undulating folds. The epidermis averages twenty-six microns and is pegged in some areas. The thickened stratum corneum is composed of loosely adherent lamellae. The stratum granulosum is prominent and ranges from two to four layers in thickness. The dermis is dense and thickened, containing large sebaceous glands associated with hair follicles. The hypodermis contains loose connective tissue fibers and extensive adipose tissue (Plate XXX).

Labia

The labial skin is characterized by folds containing pilosebaceous units. The epidermis measures twenty-six microns and contains a prominent stratum granulosum. The connective tissue of the dermis is loosely arranged and the thickened hypodermis is composed of large fat cells (Plate XXXI). As the labium approaches the vagina, the epidermis becomes thickened and there is a gradual loss of hair. The labial glands are enlarged in this area and open directly onto the skin surface.

Figure A

BODY AREAS FROM WHICH TISSUES WERE TAKEN

1. Pinna (outer surface)
2. Pinna (inner surface)
3. Pinna (tip)
4. Eyelid (upper)
5. Eyelid (lower)
6. Mandibular region
7. Planum nasale
8. Occiput
9. Dorsal neck
10. Shoulder
11. Lateral thorax
12. Lumbar region
13. Lateral abdomen
14. Tail root
15. Ventral neck
16. Ventral thorax
17. Medial fore leg
18. Ventral abdomen
19. Teat
20. Mammary gland
21. Scrotum
22. Tail (proximal)
23. Tail (middle)
24. Tail (distal)
25. Metacarpal pad
26. Digit of fore paw
27. Metatarsal pad
28. Digit of hind paw
29. Lip (upper)
30. Lip (lower)
31. Perianal region
32. Anus
33. Prepuce
34. Labium

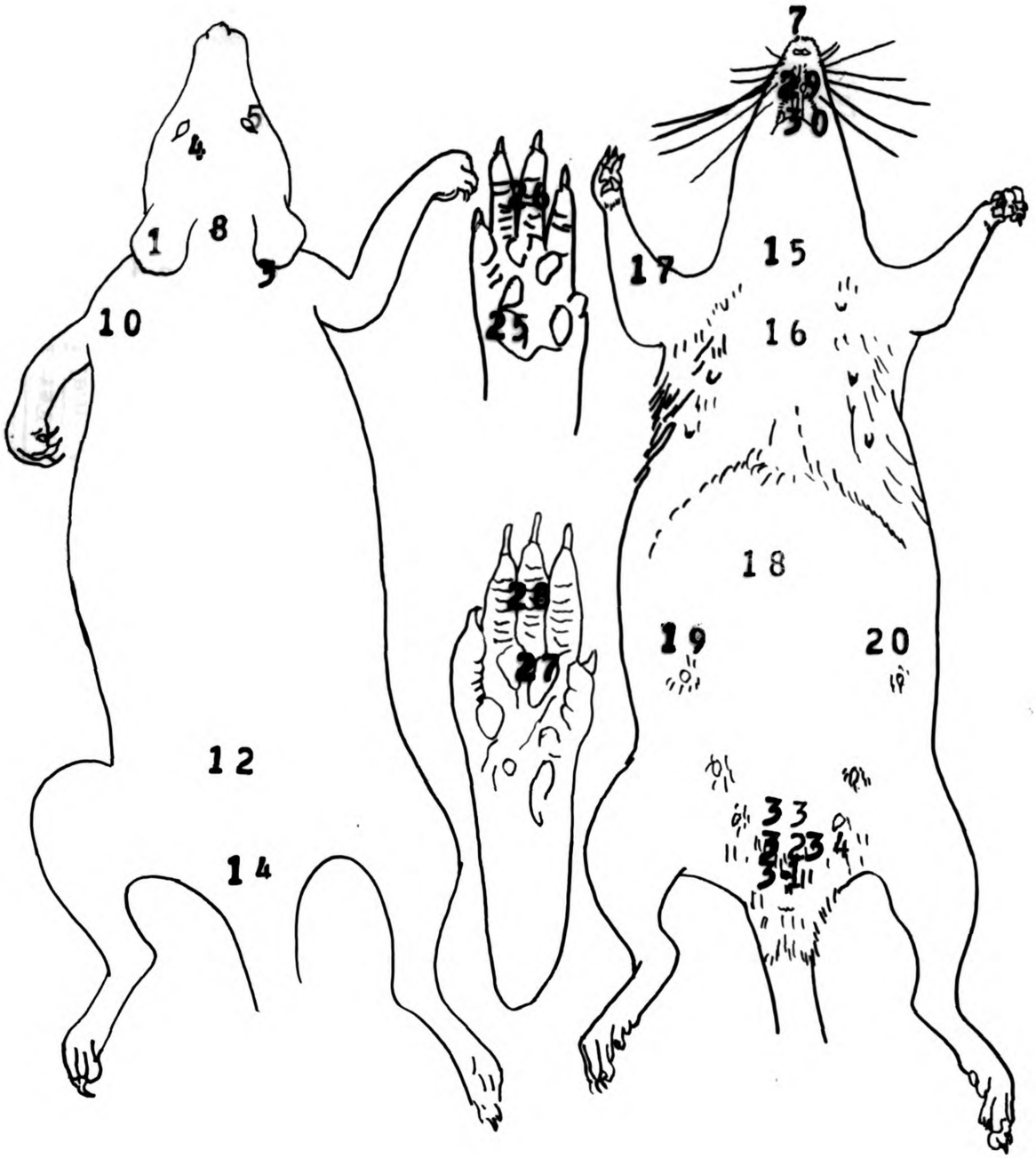
7
4
5
1
8
3
10
25
17
15
16
18
19
20
12
14
33
23
4

9
2
13
22
23
6
11
24

TABLE I. MEASUREMENTS OF EPIDERMAL THICKNESS OF ALBINO RAT IN MICRONS

TABLE I. MEASUREMENTS OF EPIDERMAL THICKNESS OF ALBINO RAT IN MICRONS*

Location	Male Animal Number 19	20	21	22	23	Average	Female Animal Number 24	25	26	27	28	Average
Pinna (outer)	21.4	21.4	20.3	25.4	17.8	21.3	15.0	13.3	20.7	17.6	18.9	17.1
Pinna (inner)	24.5	19.4	23.6	23.2	19.4	22.0	16.1	18.2	21.4	20.5	20.0	19.3
Mandibular region	22.3	21.1	25.7	28.5	23.6	24.2	19.6	23.4	14.6	17.6	25.7	20.2
Poll	21.0	18.7	24.4	18.5	21.8	20.9	20.7	22.7	33.8	22.3	23.2	24.5
Dorsal neck	22.1	24.1	22.1	25.7	22.3	23.3	19.6	24.9	20.3	20.8	17.1	20.5
Shoulder	21.6	20.7	20.9	23.6	20.7	21.5	19.6	22.3	25.0	18.5	21.4	21.4
Lateral thorax	21.9	19.8	21.4	22.7	23.6	21.9	20.7	24.8	22.3	22.7	21.8	22.5
Lumbar region	24.5	24.3	26.1	24.1	28.8	25.6	19.6	23.9	28.8	19.4	22.1	22.8
Lateral abdomen	29.0	26.6	29.7	27.0	24.4	27.3	27.6	22.3	26.6	29.5	20.3	25.3
Tail root	27.8	21.6	24.1	26.6	27.7	25.6	27.6	26.3	28.1	22.7	21.6	25.3
Ventral neck	23.9	21.6	24.3	29.0	20.7	23.9	21.4	21.8	20.3	21.6	20.5	21.1
Ventral thorax	25.7	25.9	24.7	23.9	25.4	25.1	23.0	21.8	24.8	28.4	27.2	25.0
Medial fore leg	18.4	17.1	18.5	18.0	20.3	18.5	20.7	16.0	23.9	19.9	16.2	19.3
Ventral abdomen	18.4	20.9	23.6	22.3	22.7	21.6	21.9	23.0	24.3	25.0	25.2	23.9
Animal average	23.0	21.6	23.5	24.2	22.8	23.1	20.9	21.8	23.9	21.9	21.5	22.0

*Each figure represents an average of five measurements.

THICKNESS OF ALBINO RAT IN MICRONS*

TABLE II. MEASUREMENTS OF DERMAL THICKNESS OF ALBINO RAT IN MICRONS*

Location	Male Animal Number 19	20	21	22	23	Average	Female Animal Number 24	25	26	27	28	Average
Pinna (outer)	95.1	102.8	63.1	79.5	68.8	81.9	75.5	85.4	51.4	79.5	99.9	78.3
Pinna (inner)	99.9	111.6	66.9	70.8	92.2	88.3	70.2	89.2	77.6	78.2	96.0	82.2
Mandibular region	305.6	388.0	280.3	329.8	307.5	322.2	384.4	336.8	277.4	354.1	443.3	359.2
Poll	296.6	291.0	310.4	302.6	282.3	296.6	375.4	296.7	299.8	388.6	208.6	313.8
Dorsal neck	409.3	336.6	336.6	305.6	428.7	363.4	335.8	360.2	275.5	326.9	285.5	316.8
Shoulder	255.5	266.8	249.3	250.3	443.3	293.0	218.6	301.6	223.1	201.8	206.6	230.3
Lateral thorax	320.5	377.3	264.8	318.2	335.6	323.3	450.5	322.7	306.7	323.9	318.2	344.4
Lumbar region	733.7	732.4	730.7	737.2	731.4	733.1	529.6	610.7	751.8	738.1	711.0	688.2
Lateral abdomen	541.1	507.3	621.5	519.4	436.5	525.2	500.6	535.7	679.0	520.9	633.4	573.9
Tail root	627.6	582.0	713.9	601.4	529.6	610.9	447.2	625.4	630.5	631.0	528.7	572.6
Ventral neck	361.8	363.8	215.3	341.4	202.7	297.0	426.8	350.9	269.8	285.3	254.1	317.4
Ventral thorax	312.3	417.1	186.2	363.8	178.5	291.6	206.6	301.6	367.5	270.6	265.8	282.4
Medial fore leg	295.9	243.5	232.4	276.5	184.3	246.5	194.4	230.3	232.4	194.6	234.2	217.2
Ventral abdomen	408.8	382.2	194.0	281.3	285.8	310.4	208.6	315.5	279.5	284.3	289.1	275.4
Animal average	361.7	364.5	319.0	341.3	321.9	341.7	316.0	340.2	337.3	334.1	326.7	330.9

*Each figure represents an average of five measurements.

SKIN THICKNESS OF ALBINO RAT IN MICRONS

TABLE III. MEASUREMENTS OF TOTAL SKIN THICKNESS OF ALBINO RAT IN MICRONS*

Location	Male Animal Number 19	20	21	22	23	Average	Female Animal Number 24	25	26	27	28	Average
Pinna (outer)	116.5	124.2	83.4	104.9	86.6	103.2	90.5	98.7	72.1	97.1	118.8	95.4
Pinna (inner)	124.4	131.0	90.5	94.0	111.6	110,3	86.3	107.4	99.0	98.7	116.0	101.5
Mandibular region	327.9	409.1	306.0	358.3	331.1	346.4	404.0	360.2	292.0	371.7	469.0	379.4
Poll	317.6	309.7	334.8	321.1	304.1	317.5	396.1	319.4	333.6	410.9	231.8	338.3
Dorsal neck	431.4	360.7	358.7	331.3	451.0	386.7	355.4	385.1	295.8	347.7	302.6	337.3
Shoulder	277.1	287.5	270.2	273.9	464.0	314.5	238.2	323.9	248.1	220.3	228.0	251.7
Lateral thorax	342.4	397.1	286.2	340.9	359.2	345.2	471.2	347.5	329.0	346.6	340.0	366.9
Lumbar region	758.2	756.7	756.8	761.3	760.2	758.7	549.2	634.6	780.6	757.5	733.1	691.0
Lateral abdomen	570.1	533.9	651.2	546.4	460.9	552.5	528.2	558.0	705.6	550.4	653.7	599.2
Tail root	655.4	603.6	738.0	628.0	557.3	636.5	474.8	651.7	658.6	653.7	550.3	597.9
Ventral neck	385.7	385.4	239.6	370.4	223.4	320.9	448.2	372.7	290.1	306.9	274.6	338.5
Ventral thorax	338.0	443.0	210.9	387.7	203.9	316.7	229.6	323.4	392.3	299.0	293.0	307.4
Medial fore leg	314.3	260.6	250.9	294.5	204.6	265.0	215.1	246.3	256.3	214.5	250.4	236.5
Ventral abdomen	427.2	403.1	217.6	303.6	308.5	332.0	230.5	338.5	303.8	309.3	314.3	299.3
Animal average	384.7	386.1	342.5	365.5	344.7	364.7	337.0	362.0	361.2	356.0	348.3	352.9

*Each figure represents an average of five measurements.

SUMMARY AND CONCLUSIONS

Skin Thickness

Skin specimens were studied from thirty-two body areas of five female and five male albino rats. No appreciable sex differences were observed.

The rat skin is thrown into transverse folds which are most prominent on the abdomen, tail root, medial foreleg, and lumbar region. The thickest of fourteen representative body areas are the lumbar region, tail root, and lateral abdomen. The thinnest areas are the pinna, medial surface of the foreleg and the shoulder. The maximum skin thickness is 759 microns in the lumbar region with the minimum thickness of 95.4 microns in the pinna. The average skin thickness is 365 microns in the male and 353 microns in the female. The thickness of rat skin decreases from the dorsal body surface to the ventral body surface.

The average epidermal thickness in males is 23.1 microns and in females is 22 microns. The thickest epidermal areas are the metacarpal pads, planum nasale, tail, and anus, measuring 457, 96, 77, and 56 microns, respectively.

The dermal thickness averages 342 microns in the male and 331 microns in the female. The dermal thickness varies from 81.9 microns in the pinna to 733 microns in the lumbar area.

Epidermis

The epidermis consists of only three layers: a stratum corneum, a stratum germinativum, and a stratum granulosum. A stratum lucidum is not seen. The stratum corneum is found in all body areas and varies in thickness from three to thirteen microns in the hairy skin. The digital pad possesses the thickest corneum, measuring 329 microns. The stratum granulosum is present in all of the areas studied, being particularly prominent in the lumbar region, tail root, foot pads, planum nasale, and teats. The stratum germinativum, consisting of a spinous and basal layer, ranges in thickness from two to four cell layers in the hairy skin to many in the foot pads and planum nasale.

The epidermis consists of typical stratified squamous epithelial cells, "clear cells" which have clear cytoplasm and distinctive vesicular nuclei lacking nucleoli, and lymphocytes.

Basement Membrane

A P.A.S. positive basement membrane is demonstrable in the rat skin. The reticulum stain showed the membrane to be composed of reticular fibers.

Dermis

The dermis is richly cellular and formed of collagen, and elastic and reticular fibers. It is composed of a superficial stratum papillare and a deeper stratum reticulare. The former consists of many fine collagenous fibers, which vary in looseness and usually parallel the epidermis. The elastic fibers branch freely and form no

particular pattern. The stratum reticulare has a coarser connective tissue with elastic fibers paralleling the epidermis. The elastic fibers are seen in close proximity to the sebaceous glands and hair follicles and in the vessel walls.

Collagenous Tissue

The collagenous fibers differ in compactness and fineness in the various body regions. The fibers in the skin of the back are loosely arranged; those in the ventral abdomen are intermediate in denseness, while those in the foot pads are compactly arranged.

Elastic Tissue

Coarse elastic tissue fibers are found in the dermis and hypodermis paralleling the surface. Finer fibers are also present, some of which may be perpendicular to the surface. Elastic fibers in the lips are fine and perpendicular to the surface, while those in the eyelids are thicker and parallel the lid surface. The tarsus is heavily infiltrated with elastic tissue. The ear cartilage is enveloped by dense elastic fibers.

Mast Cells

Great numbers of mast cells are observed throughout the dermis and hypodermis, except in the tail dermis where they are absent, and in the digital pad where there are few. The greatest numbers are in the vicinity of the blood vessels and hair bulbs of the stratum reticulare and hypodermis. Mast cells occur in both hairy and nonhairy skin.

Hair Follicles

The central follicles appear in linear form with well-defined groups of three to nine smaller follicles about them. The groups are separated by connective tissue. Roots of active hairs may extend to the panniculus carnosus but inactive hairs lie dormant in the dermis. Hairs are covered with scale-like cuticles which flare outward toward their tips and which do not completely encircle the shafts. There are no apparent sex differences in hair density or pattern. Pigmentation is absent in the hairs of the albino rat.

Tactile hairs are located on the lips, cheeks, above the eyes, and on the carpal joints of the fore limbs. They are enclosed in thick connective tissue sheaths within which are blood sinuses. These sheaths are penetrated by nerve fibers. The hairs are moved by muscle fibers attached to the dermal sheaths.

The arrectores pilorum are composed of smooth muscle fibers which connect to elastic fibers in the dermal papillae. They insert below the sebaceous glands in collagenous and elastic connective tissue of the follicles. They control the movement of the hair shafts but are found lacking in connection with eyelashes, eyebrows, and tactile hairs.

Prominent follicular folds of the epithelial sheath are found just below the opening of the sebaceous duct. The folds appear to be more apparent on the side of the follicle making the least angle with the surface of the integument. The function of these folds has not been determined, but they are probably formed by the relaxed position of the hair follicle.

Sebaceous Glands

Sebaceous glands are usually associated with pelage and tactile hairs. The glands are located about midway down the follicles in the angles formed by the follicles and the arrectores muscles. The glands open into the necks of the follicles, are holocrine in type, and contain varying amounts of sebum.

Sweat Glands

Sweat glands are seen only in the palmar and plantar surfaces. The glands are tightly coiled and are of the eccrine type.

SPECIAL BODY AREAS

Pinnae

The epidermis of the pinna doubles in thickness as it approaches the tip. It possesses a thicker medial or inner surface than the lateral or outer surface. The dermis on the lateral surface is thinner than the medial surface. Pilosebaceous units are found in the dermis but the hair shafts are not always visible. No visible panniculus carnosus is seen in the hypodermis.

Eyelids

The eyelids are covered on the outer surface with a thin hairy epithelium which becomes a hairless, thickened stratified squamous epithelium at the tip. Arrectores pilorum muscles are absent in this area. The squamous epithelium is continuous with the epithelium of the palpebral conjunctiva. The tarsal glands are arranged in a row within the tarsal plates and their ducts open onto the lid margins.

Lips

The lips are composed of a hairy and nonhairy surface. The hairy surface contains tactile hairs and various sized sebaceous glands. The oral surface possesses a thickened stratified squamous epithelium. Hair and sebaceous glands are absent.

Planum Nasale

The planum nasale is composed of a thick stratum corneum which covers a prominent stratum granulosum and a pegged germinativum. The stratum papillare is composed of fine collagenous fibers, and the reticulare of dense, coarser fibers.

Foot Pads

The foot pads have both a thick stratum corneum and germinativum. The dermis ranges from being very thin in one area to very thick in another. The pads contain both Meissner's corpuscles and sweat glands.

Teats

The teats of the immature female are devoid of hair, and sebaceous glands, and are covered with a thickened epidermis containing pegs. The corneum is thin but more adherent than in other body areas, and the granulosum is thickened and prominent. The dermis is composed of dense connective tissue. The teats of the five-week-old male cannot be demonstrated.

Scrotum

The scrotal skin is folded and covered with an ordinary-appearing epidermis ranging between twenty and twenty-six microns.

The corneum is loose and the granulosum is made up of one to three prominent layers. The dermis is composed of loose connective tissue containing pilosebaceous units.

Tail

The tail is covered by a thick dermis and epidermis. The thickness of the dermis decreases and that of the germinativum increases as they approach the tail tip. Short hairs in groups of three emerge from beneath the scaly epidermis.

Perianal region

The perianal region is covered by a thin skin containing both fine hairs and enlarged sebaceous perianal glands. These glands are imbedded in the dermis and contain a copious amount of sebum.

Anus

The anus possesses a thickened stratified squamous epithelium containing a prominent granulosum. The spinosum is sparsely inhabited but the basal layer is crowded. The dermis is composed of a network of loose collagenous fibers.

Prepuce

The prepuce is covered with a thickened, lamellated stratum corneum. Beneath the corneum is a prominent granulosum. The dermis contains dense collagenous and elastic fibers as well as pilosebaceous units.

Labia

The labial epidermis contains a prominent stratum granulosum.

The dermis has a loose arrangement of connective tissue with the hypodermis composed largely of fat. In the immediate vicinity of the vagina, the labium is devoid of hair follicles but contains large labial glands.

LITERATURE CITED

Andrew, W. 1951. Age changes in the skin of Wistar Institute rats with particular reference to the epidermis. Am. J. Anat. 89:283-319.

Andrew, W. and N. V. Andrew. 1949. Lymphocytes in the normal epidermis of the rat and man. Anat. Rec. 104:217-241.

Andrew, W. and N. V. Andrew. 1954. Lymphocytes in normal epidermis of young, middle-aged, and senile rats. J. Geront. 9:412-420.

Andrew, W. and N. V. Andrew. 1956. An age difference in proportion of cell type in the epidermis of abdominal skin of the rat. J. Geront. 11:18-27.

Arey, L. B. 1957. Human Histology A Textbook in Outline Form. W. B. Saunders Co., Philadelphia and London.

Bailey, F. R. 1958. Bailey's Textbook of Histology. Edited by W. M. Copenhaver and D. D. Johnson. The Williams and Wilkins Company, Baltimore.

Becker, K. 1952. Hair growth studies on the Norway rat. Biol. Zentralbl. 71:626-640.

Butcher, E. O. 1934. The hair cycles in the albino rat. Anat. Rec. 61:5-19.

Butcher, E. V. 1957. The effect of several substances on the keratinization of the rat epidermis. J. Invest. Derm. 29:377-381.

Calef, A. 1900. Studio istologico e morfologica di un' appendice epiteliale del pelo nella pelle del Mus decumanus var. albina e del Sus Scropha. Anat. Anz. 17:509-517.

Cooper, J. H. 1958. Microanatomical and histochemical observations on the dermal-epidermal junction. Arch. Derm. 77:18-22.

Davidson, P. and M. H. Hardy. 1952. Development of mouse vibrissae in vivo and in vitro. J. Anat. 86:342-356.

de Meijere, J. C. H. 1894. Uber die Haare der Saugethiere besonders uber ihre Anordnung. Gegenbaur's Morph. Jahrb. 21:312-415.

Dieke, S. H. 1947. Pigmentation and hair growth in black rats. Endocr. 40:123-136.

Donaldson, H. H. 1924. The Rat. The Wistar Institute of Anatomy and Biology, Philadelphia.

Durward, A. and K. M. Rudall. 1949. Studies on hair growth in the rat. J. Anat. 83:325-335.

Ebling, F. J. 1953. Changes in the sebaceous glands and epidermis during the oestrous cycle of the albino rat. J. Endocr. 10:147-154.

Erickson, T. C. 1931. The post-natal development of the caudal integument in the rat. Am. J. Anat. 47:173-194.

Frazer, D. A. 1928. The development of the skin of the back of the albino rat until the eruption of the first hairs. Anat. Rec. 38:203-224.

Goldsberry, S. and M. L. Calhoun. 1959. The Comparative Histology of the Skin of Hereford and Aberdeen Angus Cattle. Am. J. Vet. Res. 20:61-68.

Greene, E. C. 1959. Anatomy of the Rat. Hafner Publishing Co., New York.

Ham, A. W. 1957. Histology. J. B. Lippincott Co., Philadelphia.

Hanson, J. 1947. The histogenesis of the epidermis in the rat and mouse. J. Anat. 81:174-197.

Hellstrom, B. and H. Holmgren. 1950. Numerical distribution of mast cells in human skin and heart. Acta Anat. 10:81-107.

Horstmann, E. and A. Knoop. 1958. Elektronenmikroskopische Studien an der Epidermis I. Rattenpfote (Electron microscopic studies on the epidermis I. Rat paw.) Zschr. Zellforsch. 47:348-362.

Jackson, C. M. and L. G. Lowrey. 1912. On the relative growth of the component parts (head, trunk, and extremities) and systems (skin, skeleton, musculature, and viscera) of the albino rat. Anat. Rec. 6:449-474.

Johnson, E. 1958. Quantitative studies of hair growth in the albino rat. I. Normal males and females. J. Endocr. 16:337-350.

Johnson, E., F. N. Andrews and C. L. Shrewsbury. 1943. The preparation of muscular tissue for histological study. J. Anim. Sc. 2:244-250.

Kiil, V. 1949. Experiments on the hair slope and hair pattern in rats. J. Exp. Zool. 110:397-439.

Lobitz, W. C. Jr. 1957. The structure and function of the sebaceous glands. Arch. Derm. 76:163-171.

Lovell, J. E. and R. Getty. 1957. The hair follicle, epidermis, dermis and skin glands of the dog. Am. J. Vet. Res. 18:873-885.

Maximow, A. A. and W. A. Bloom. 1957. A Textbook of Histology. W. B. Saunders Co., Philadelphia and London.

Malewitz, T. D. and E. M. Smith. 1955. A nuclear stain employing dilute Harris hematoxylin. Stain Tech. 30:311.

Marzulli, F. N. and J. F. Callahan. 1957. The capacity of certain common laboratory animals to sweat. J. Am. Vet. M. Ass. 131:80-81.

Medawar, P. B. 1953. The micro-anatomy of the mammalian epidermis. Quart. J. Micro. Sci. 94:481-506.

Montagna, W. 1956. The Structure and Function of Skin. Academic Press, Inc., New York.

Montagna, W. and C. R. Noback. 1947. Histochemical observations on the sebaceous glands of the rat. Am. J. Anat. 81:39-62.

Nielsen, S. W. 1953. Glands of the canine skin, morphology and distribution. Am. J. Vet. Res. 14:448-454.

Odland, G. F. 1950. The morphology of the attachment between the dermis and the epidermis. Anat. Rec. 108:399-413.

Parnell, J. P. 1949. Postnatal development and functional histology of the sebaceous glands in the rat. Am. J. Anat. 85:41-71.

Pinkus, H. 1939. Notes on the anatomy and pathology of the skin appendages. I. The wall of the intra-epidermal part of the sweat duct. J. Invest. Derm. 2:175-186.

Porter, K. R. 1954. An Abstract of a demonstration given at the American Association of Anatomists, April 7, 8 and 9, 1954, at the University of Texas, Galveston. Anat. Rec. 118:433.

Rice, H. and C. Jackson. 1934. The histological distribution of fats in the liver, kidney, trachea, lung and skin of the rat at various post-natal stages. Anat. Rec. 59:135-151.

Ring, J. R. and W. C. Randall. 1946. Abstract of paper presented for the Forty-second Annual Meeting of the American Society of Zoologists. St. Louis, Missouri, 1946. Anat. Rec. 94:376.

Robb-Smith, A. H. T. 1945. Skin and reticular tissue. Brit. M. Bull. 3:172-175.

Schamberg, J. F. and E. Saleeby. 1930. The growth of hair in newly born albino rats. Arch. Derm. and Syph. 22:34-39.

Sisson, S. and J. D. Grossman. 1956. Anatomy of Domestic Animals. W. B. Saunders Co., Philadelphia.

Spain, K. C. 1915. The relation between the structure of the epidermis of the rat and the guinea pig, and the proliferative power of normal and regenerating epithelial cells of the same species. J. Exp. M. 21:193.

Stiles, K. A. 1956. Handbook of Microscopic Characteristics of Tissues and Organs. The Blakiston Co., Philadelphia.

Storey, W. F. and C. P. Leblond. 1951. Measurement of the rate of proliferation of epidermis and associated structures. Ann. N. York Acad. Sc. 53:537-545.

Strickland, J. H. 1958. The Microscopic Anatomy of the Skin and External Ear of Felis Domesticus. Thesis, Michigan State University.

Thuringer, J. M. 1924. Regeneration of stratified squamous epithelium. Anat. Rec. 28:31-43.

Trautmann, A. and J. Fiebiger. 1957. Fundamentals of Histology of Domestic Animals. Translated and revised by Robert E. Habel and E. L. Biberstein. Comstock Publishing Assoc., Ithaca, New York.

Trotter, M. and H. L. Dawson. 1932. The direction of hair after rotation of skin in the newborn albino rat; A second experiment on hair shape. Anat. Rec. 53:19-30.

Vincent, S. B. 1913. The tactile hair of the white rat. J. Comp. Neur. 23:1-36.

Way, S. C. and A. Memesheimer. 1936. The sudoriparous glands. I. The eccrine glands. Arch. Derm. and Syph. 34:797-808.

Webb, A. J. and M. L. Calhoun. 1954. The microscopic anatomy of the skin of mongrel dogs. Am. J. Vet. Res. 15:274-280.

Winkelmann, R. K. 1956. The epidermal eccrine duct. J. Invest. Derm. 26:169-171.

PLATE I

Longitudinal section of ventral abdomen showing folds.
H. and E. Stain. 286X.

1. Stratum corneum
2. Stratum germinativum
3. Stratum papillare
4. Stratum reticulare
5. Panniculus adiposus
6. Pilose baceous units
7. Portion of hair shaft
8. Mm. Arrectores pilorum

1
2
3
4
5
6
7
8

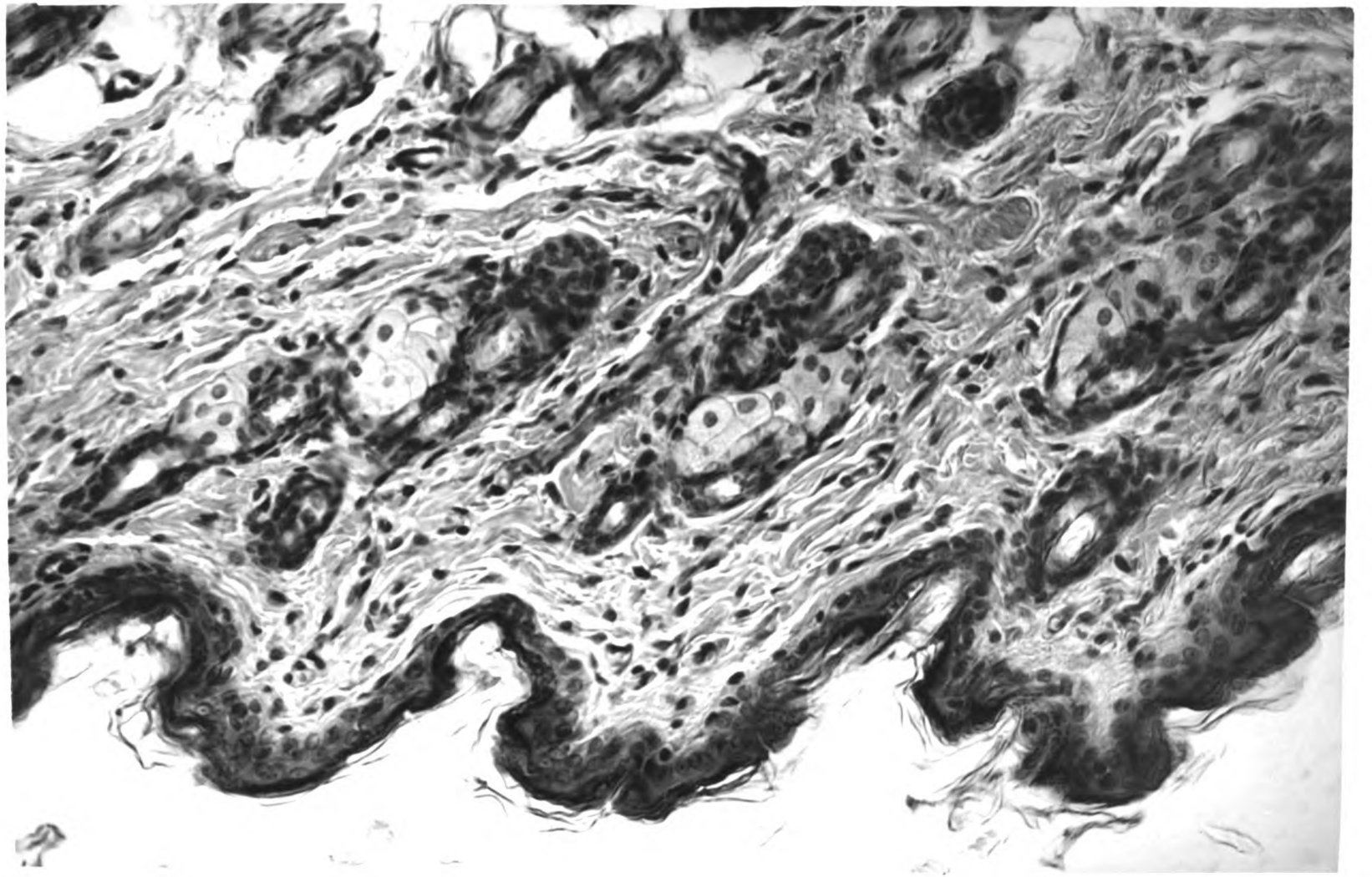

PLATE II

Longitudinal section from tail root showing folds.
H. and E. Stain. 330X

1. Stratum corneum
2. Stratum granulosum
3. Stratum papillare
4. Stratum reticulare
5. Sebaceous glands

1
2
3
4
5

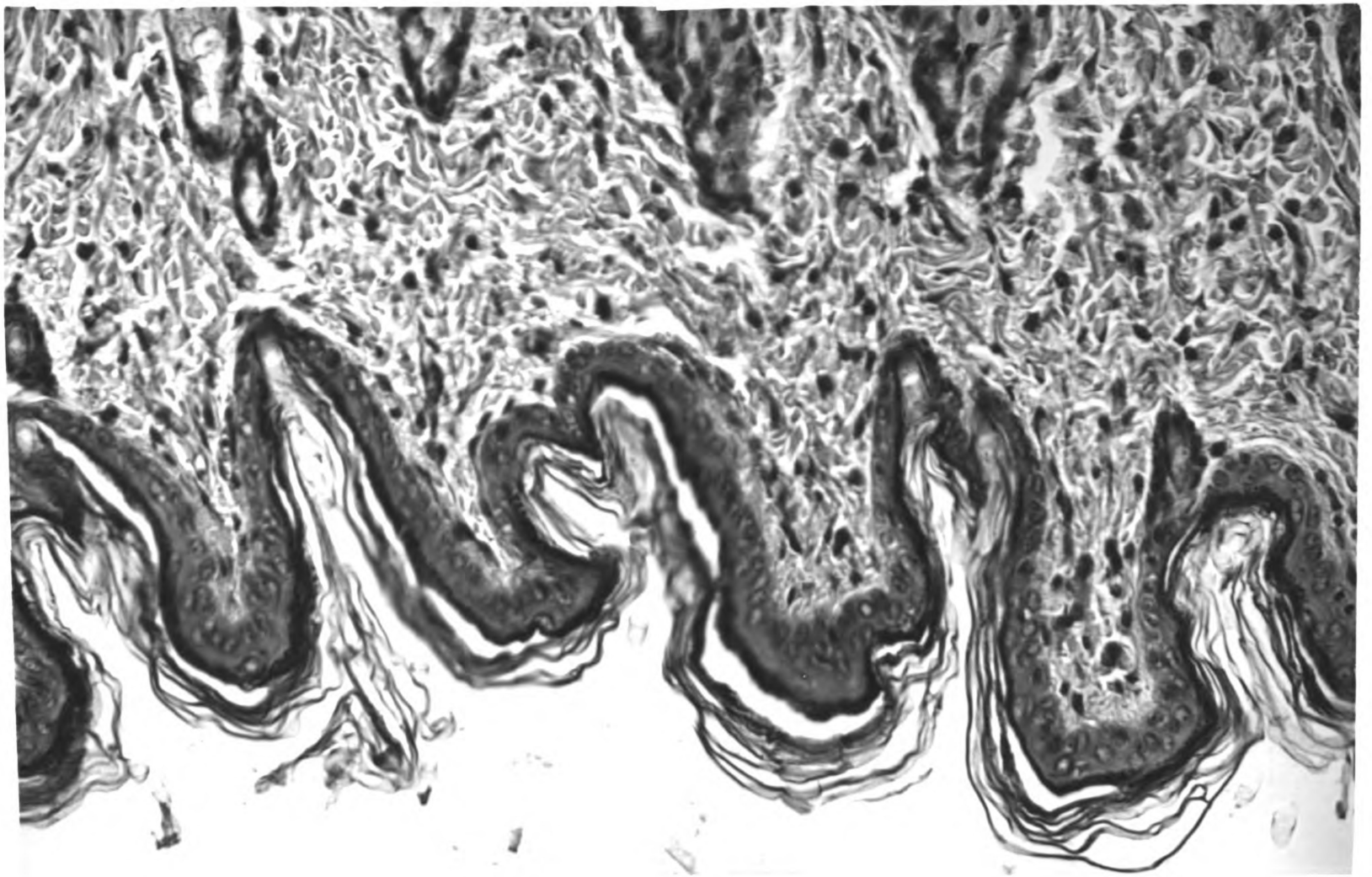

PLATE III

Longitudinal section of fore leg medial surface showing folds.
H. and E. Stain. 283X.

1. Stratum corneum
2. Thin stratum germinativum
3. Stratum papillare
4. Stratum reticulare
5. Sebaceous glands
6. Hair follicles

1
2
3
4
5
6

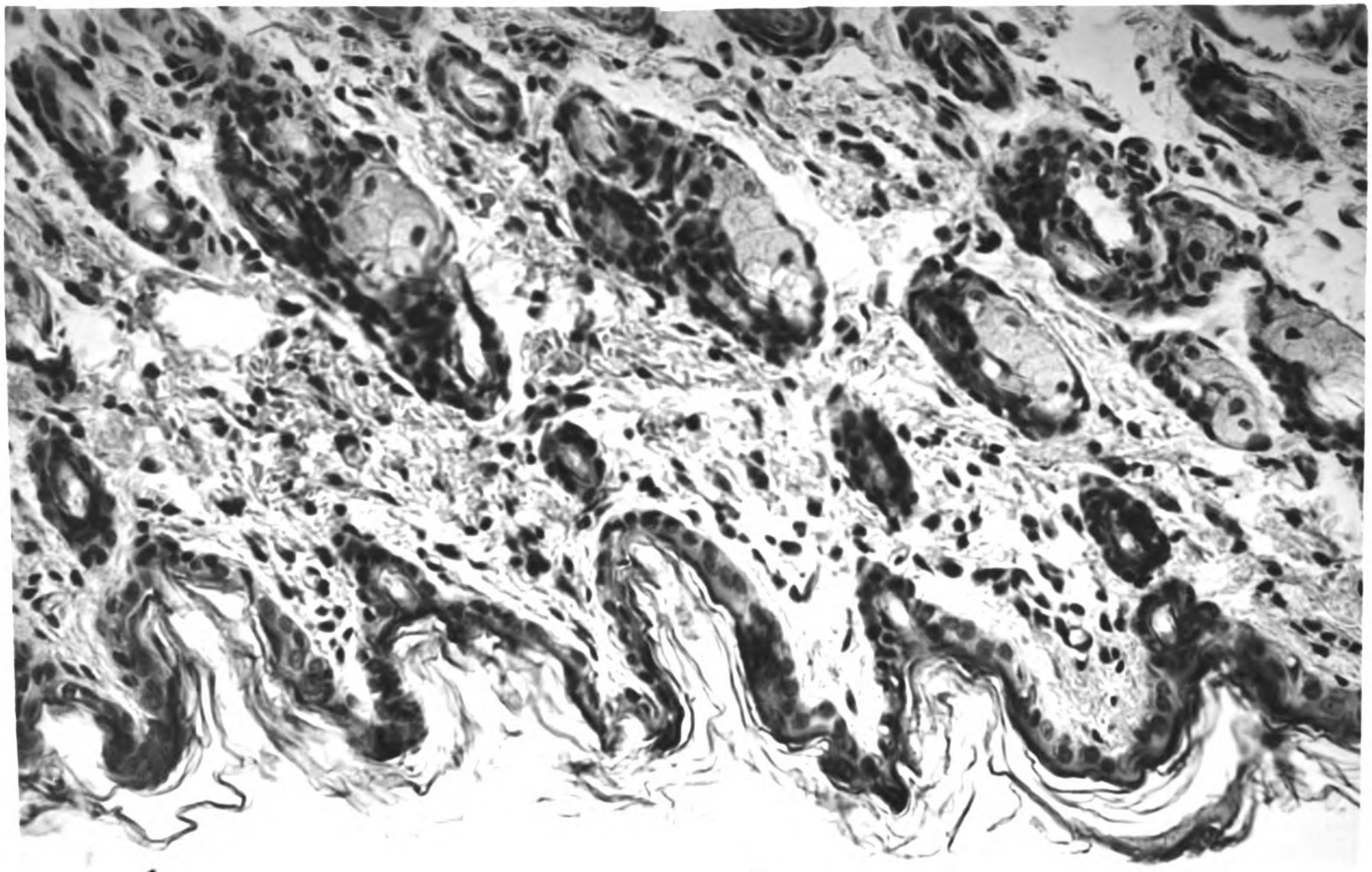

PLATE IV

Longitudinal section of lumbar region
Weigert's and Van Gieson's
Connective Tissue Stain. 250X.

1. Stratum corneum
2. Stratum granulosum
3. Stratum germinativum
4. Stratum papillare
5. Sebaceous glands
6. Hair follicle
7. Mm. Arrectores pilorum

6
7
4
5
3
2
1

PLATE V

Longitudinal section through metacarpal foot pad
showing epidermal pegs.
H. and E. Stain. 286X.

1. Stratum corneum
2. Stratum granulosum
3. Stratum spinosum
4. Basal layer of germinativum
5. Stratum papillare
6. Stratum reticulare
7. Sweat gland
8. Epidermal pegs
9. Dermal papillae
10. Meissner's corpuscles

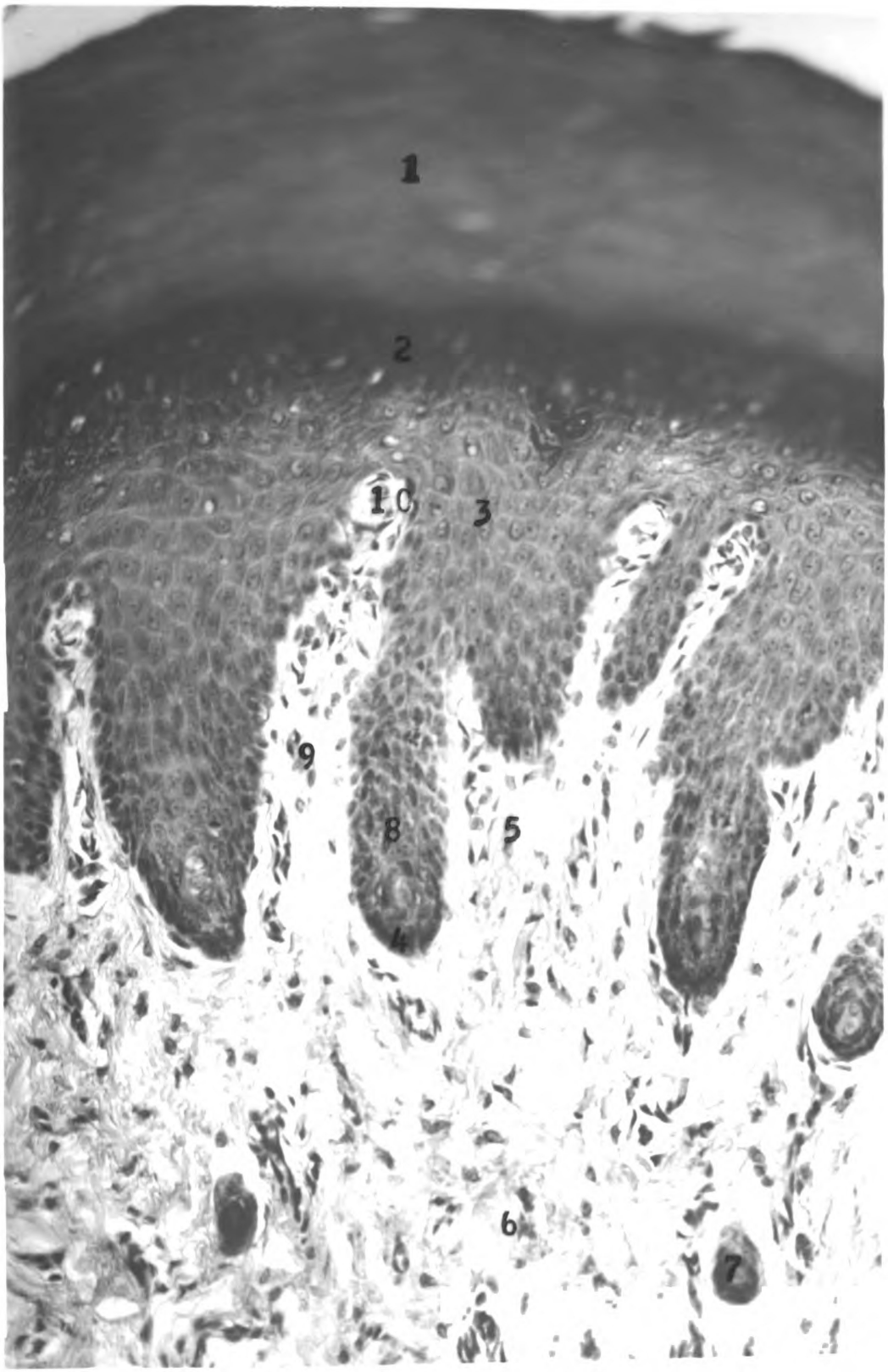
1
2
10
3
9
8
5
4
6
7

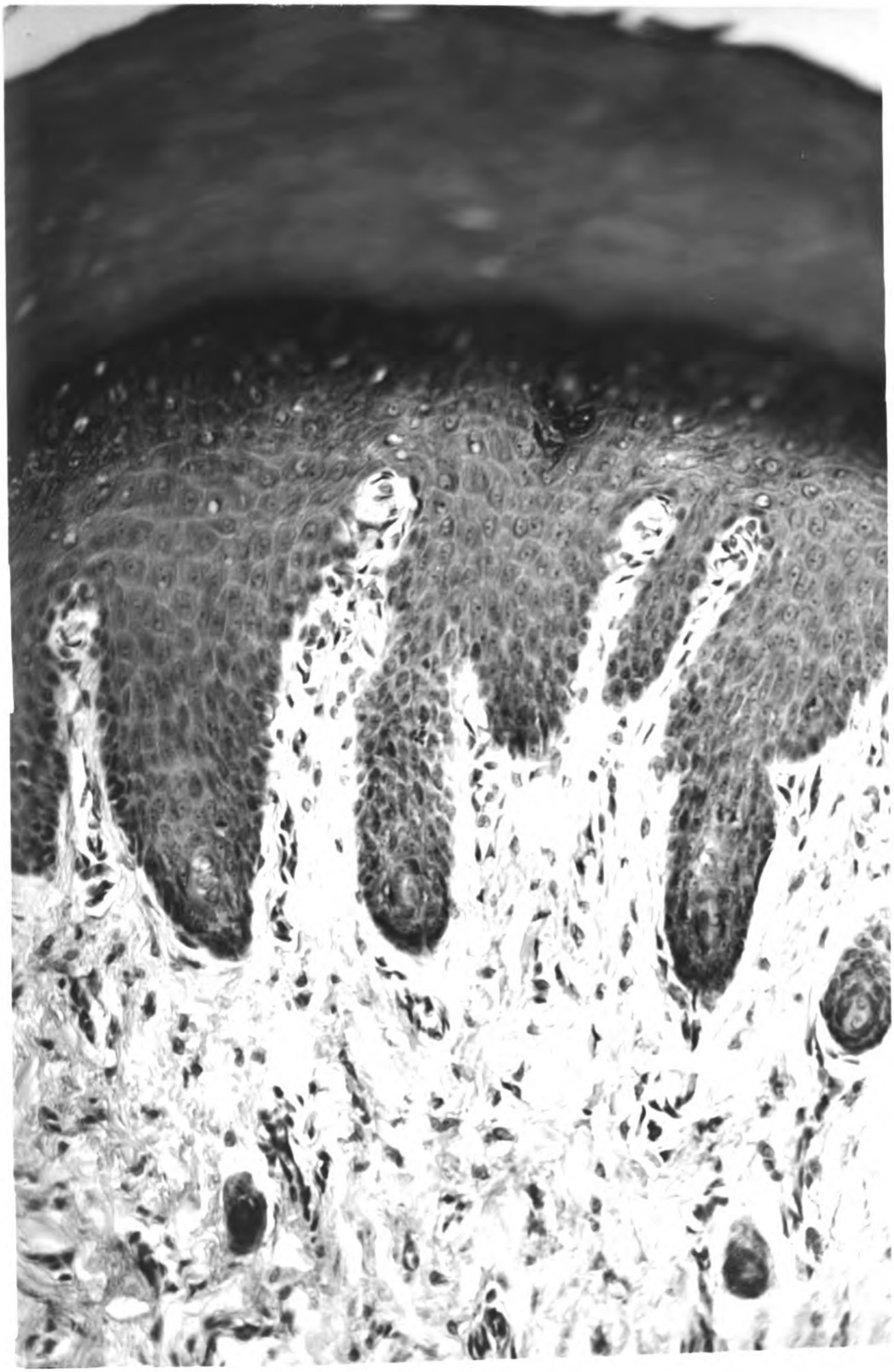

PLATE VI

Section through the metacarpal foot pad.
H. and E. Stain. 516X.

1. Stratum corneum
2. Stratum granulosum
3. Stratum spinosum
4. Basal layer of germinativum
5. Stratum papillare
6. Meissner's corpuscle

1
2
3
4
5
6

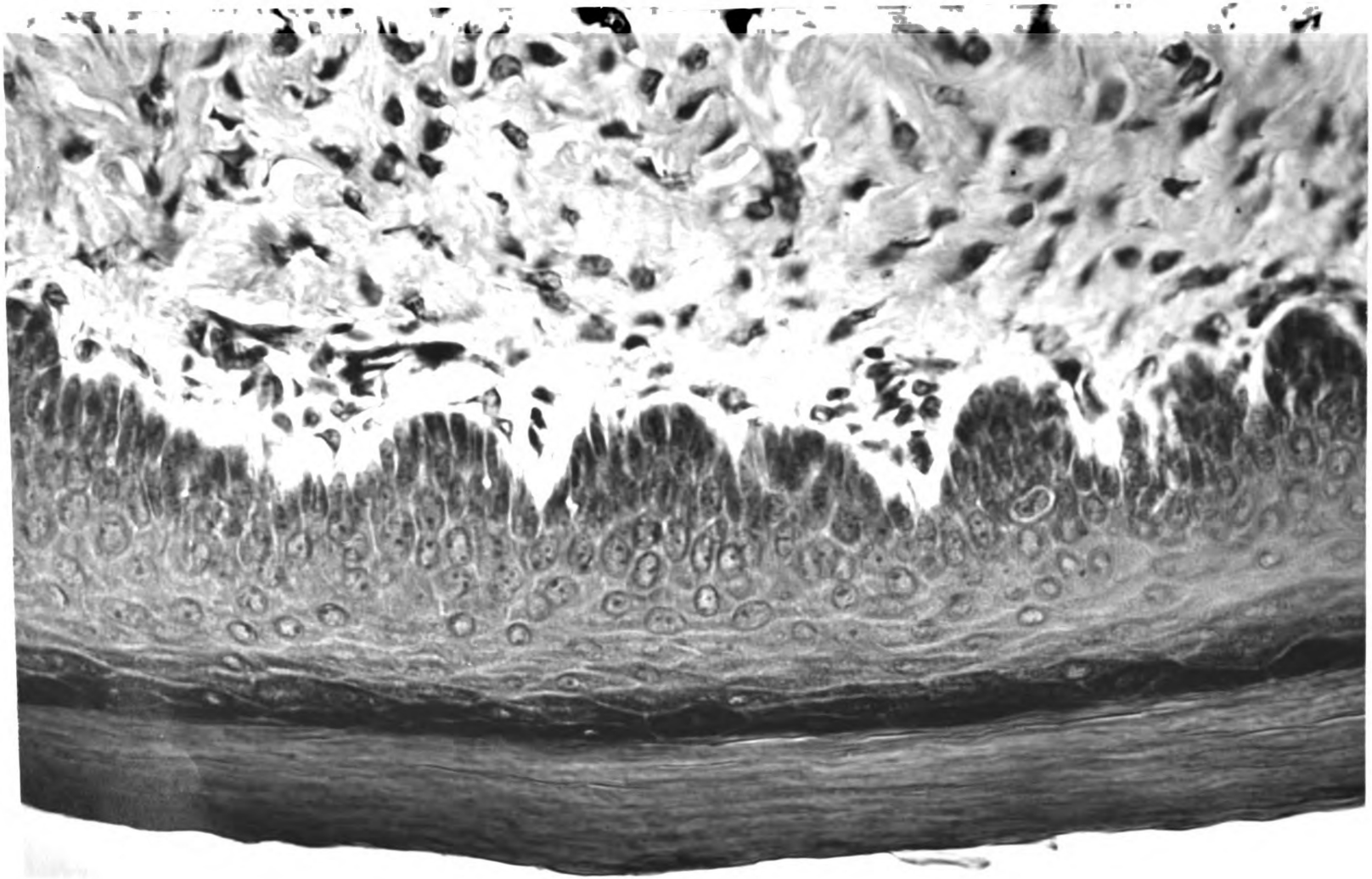

PLATE VII

Section through the planum nasale.
H. and E. Stain. 283X.

1. Stratum corneum
2. Stratum granulosum
3. Stratum spinosum
4. Basal layer of germinativum
5. Stratum papillare

1
2
3
4
5

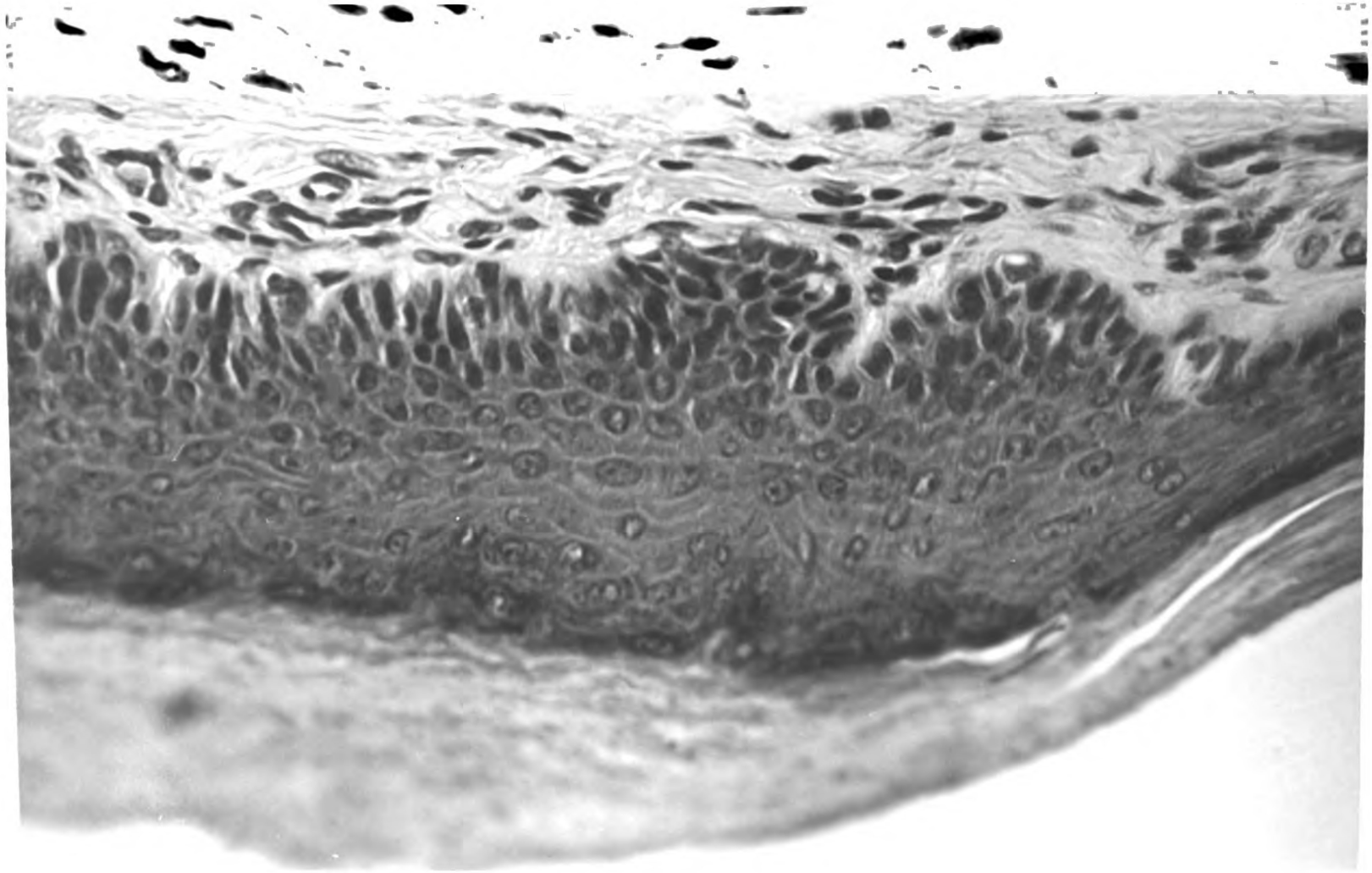

PLATE VIII

Cross section through the distal tail showing hair grouping.
H. and E. Stain. 82X.

1. Stratum corneum
2. Stratum germinativum
3. Dermis surrounding groups of three hair follicles
4. Adipose tissue
5. Sebaceous glands
6. Hair shaft openings in epithelium

6
4
3
2
1
5

PLATE IX

Longitudinal section of anorectal junction.
H. and E. Stain. 50X.

1. Rectal mucosa
2. Anorectal junction
3. Large sebaceous perianal glands
4. Sebaceous duct
5. Hair follicle
6. Anal sphincter
7. Stratified squamous epithelium of the anal mucosa
8. Stratum corneum

1
2
6
7
3
4
8
5

PLATE X

Cross section through anus.
H. and E. Stain. 37X.

1. Stratum corneum
2. Stratum granulosum
3. Stratum spinosum
4. Stratum papillare
5. Basal layer of stratum germinativum
6. Sebaceous glands
7. Sebaceous duct

6
3
2
1
4
5
7

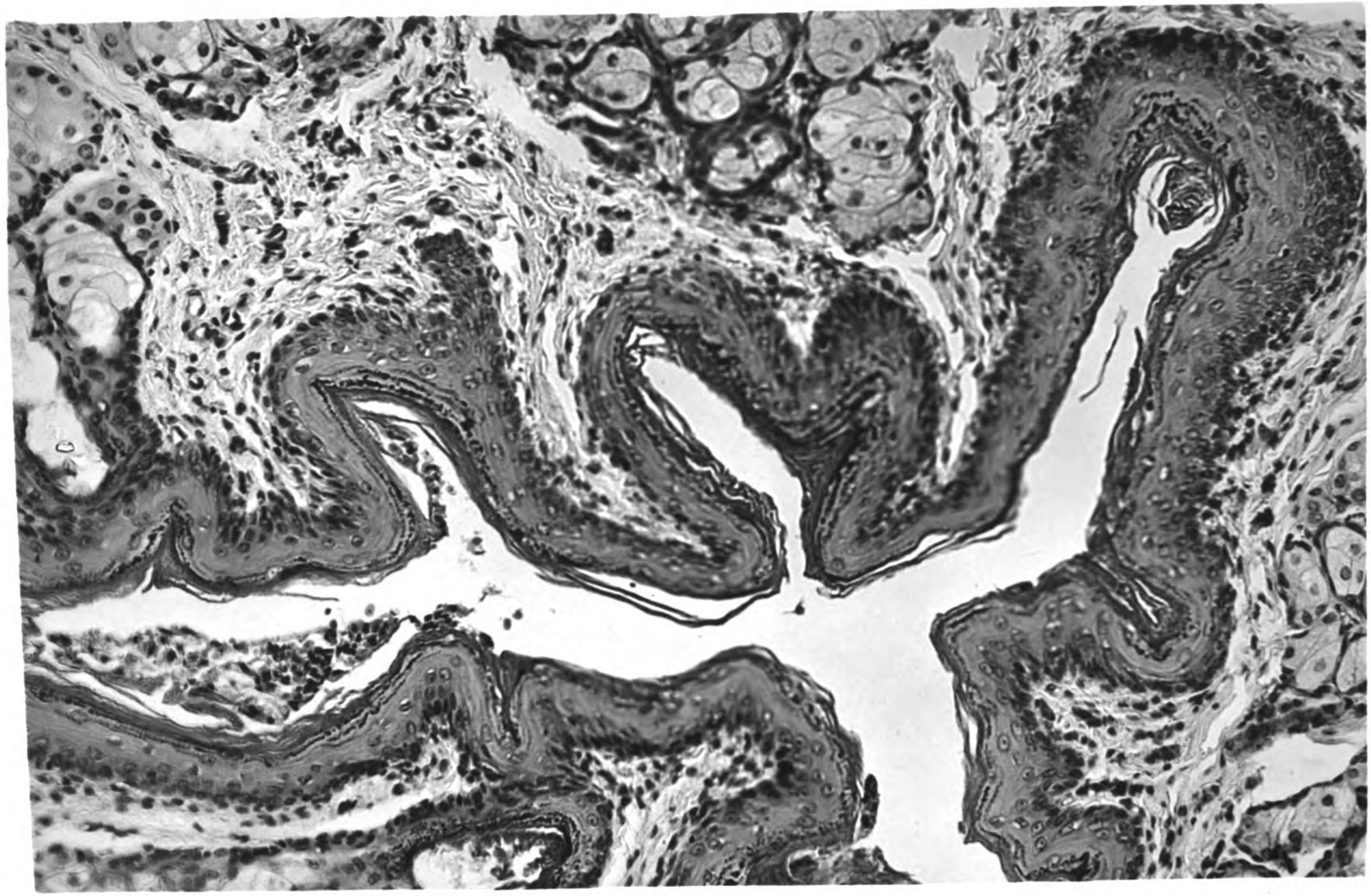

PLATE XI

Longitudinal section through pinnal tip.
H. and E. Stain. 516X.

1. Stratum corneum
2. Stratum granulosum
3. Stratum spinosum
4. Dense collagenous fibers in dermis
5. Elastic cartilage

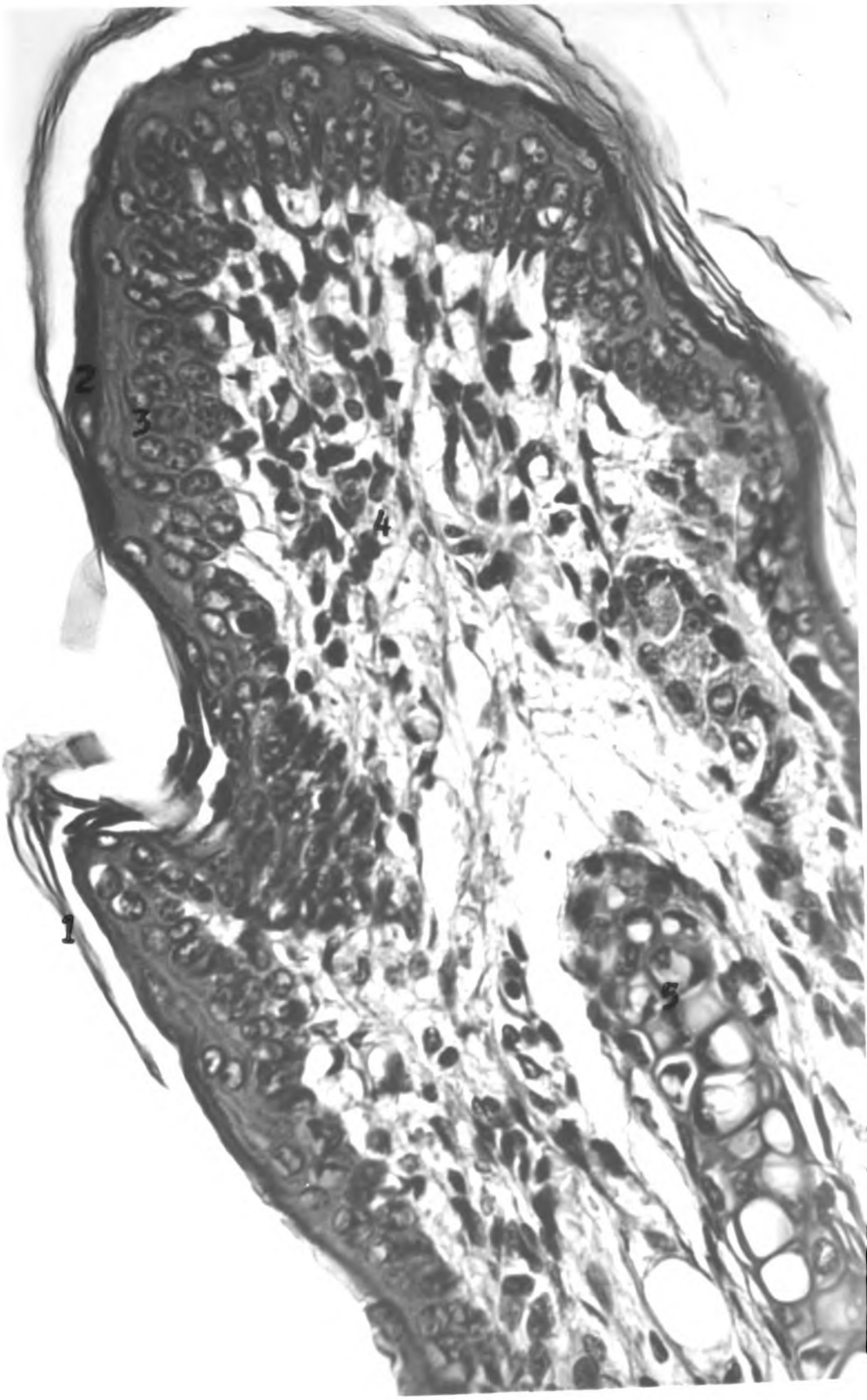
2
3
4
1
5

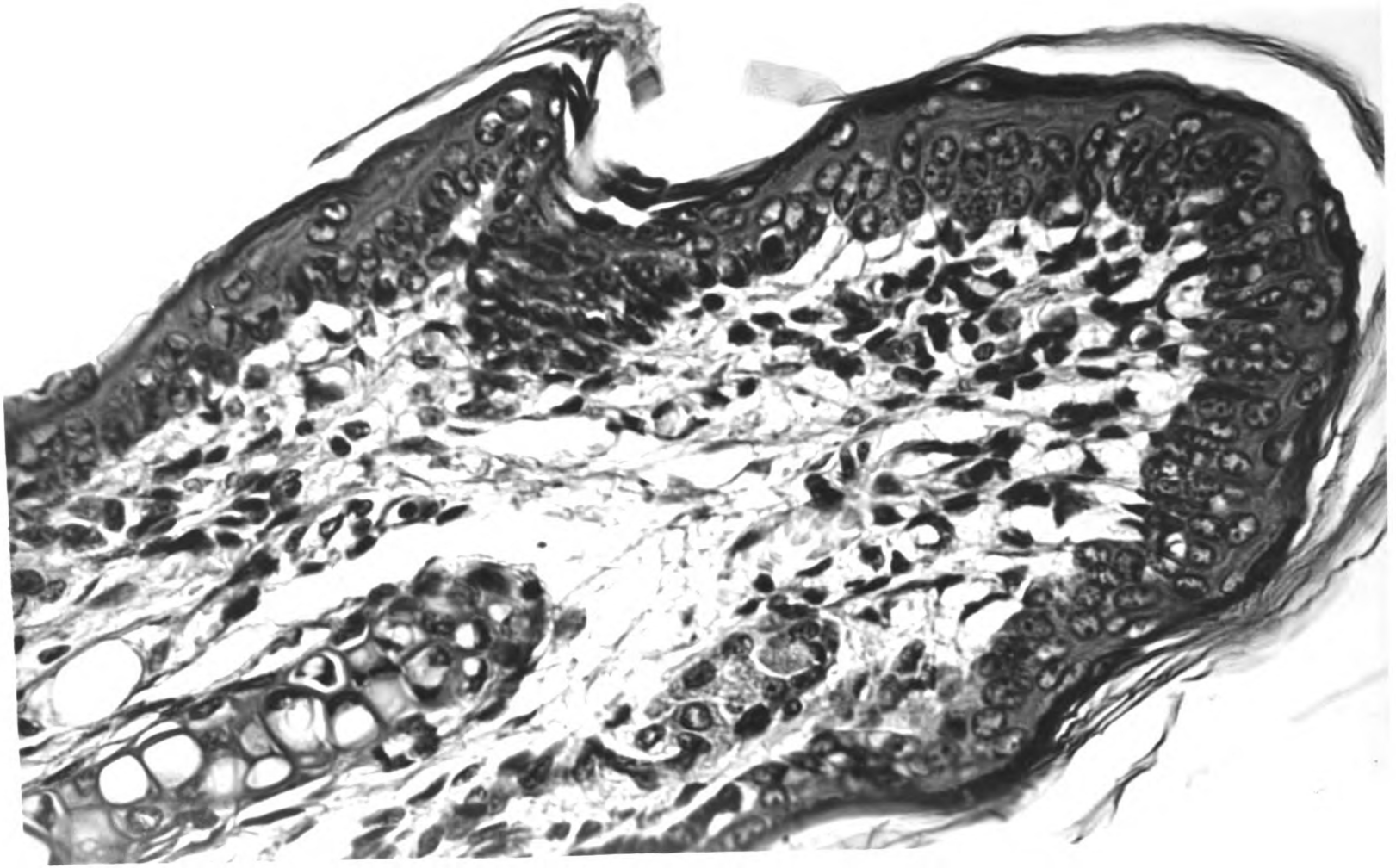

PLATE XII

Longitudinal section through center section of pinna.
H. and E. Stain. 240X.

1. Stratum corneum
2. Stratum germinativum
3. Dermis
4. Hypodermis
5. Auricular skeletal muscle on lateral surface
6. Adipose tissue
7. Pilosebaceous units
8. Elastic cartilage
9. Cartilage perforation

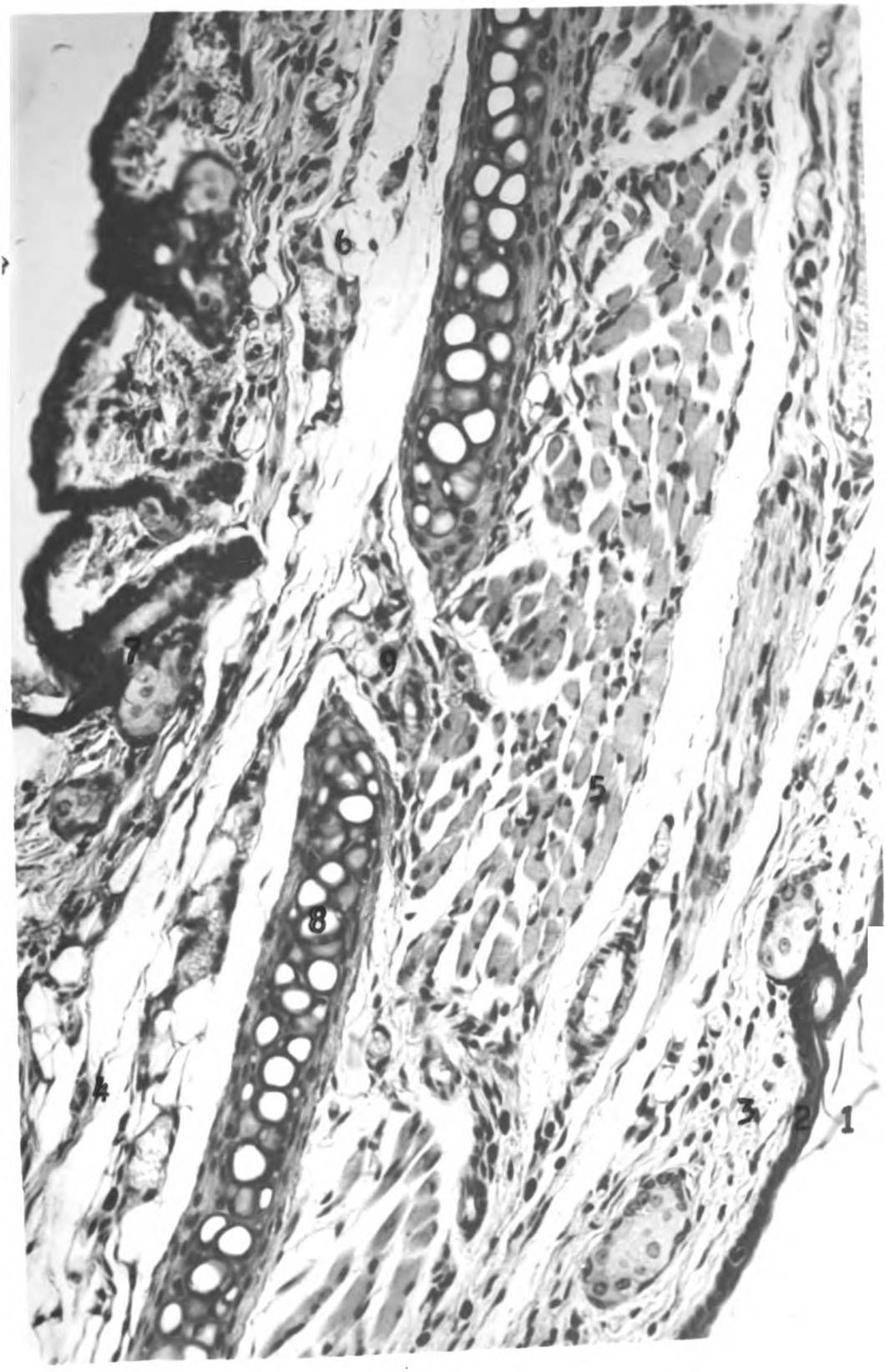
6
7
9
5
8
4
3
2
1

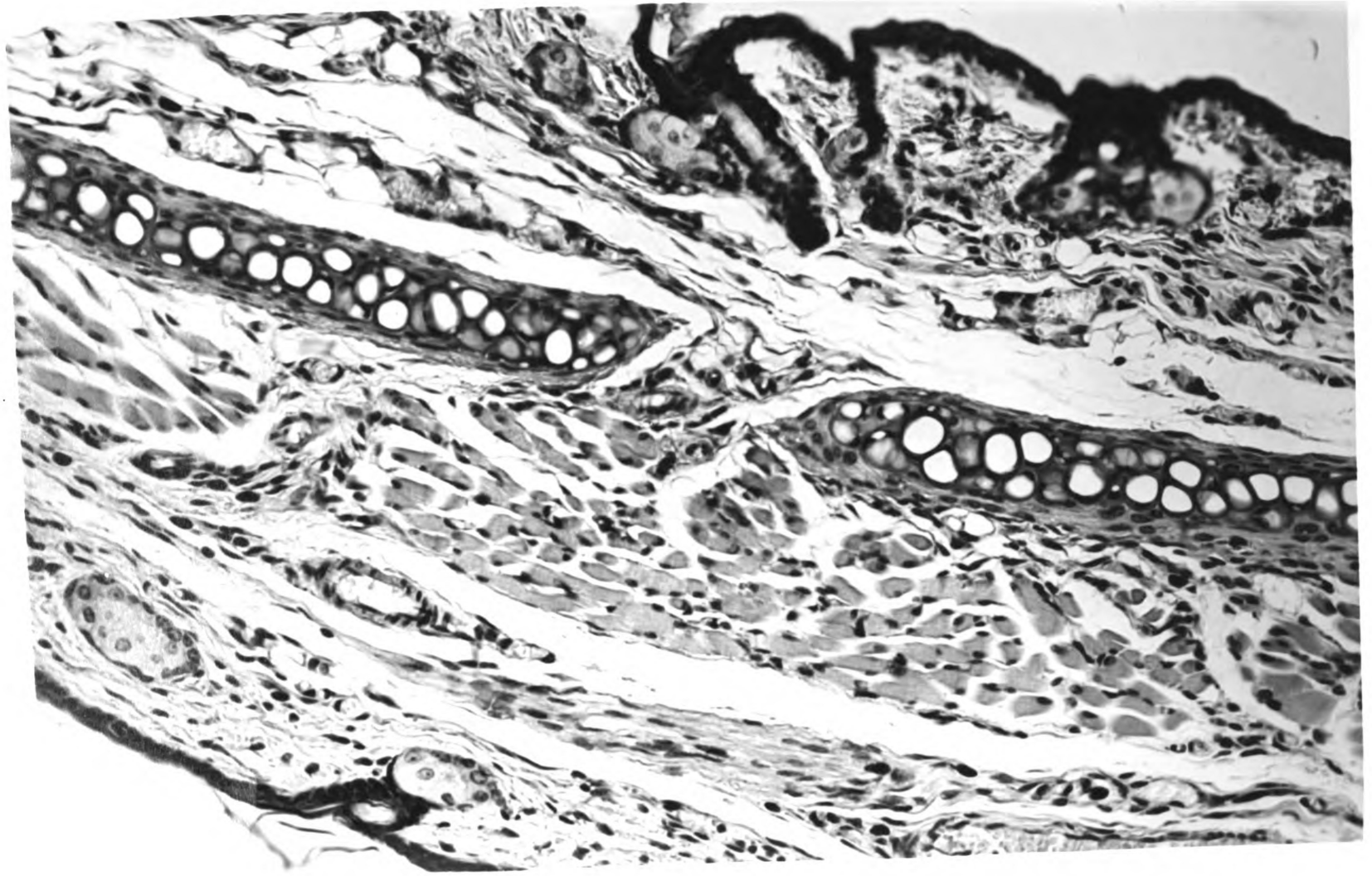

PLATE XIII

Longitudinal section through the digital pad and claw.
H. and E. Stain. 82X.

1. Stratum corneum
2. Stratum granulosum
3. Stratum spinosum
4. Epidermal pegs
5. Dermal papillae
6. Pilosebaceous units
7. Claw
8. Deep non-cornified layers of the claw
9. Corium
10. Claw fold
11. Tubular sweat glands in the digital pad
12. Articular cartilage of third phalanx
13. Second phalanx
14. Tendon insertion on third phalanx
15. Ungual crest
16. Plantar surface
17. Dorsal surface

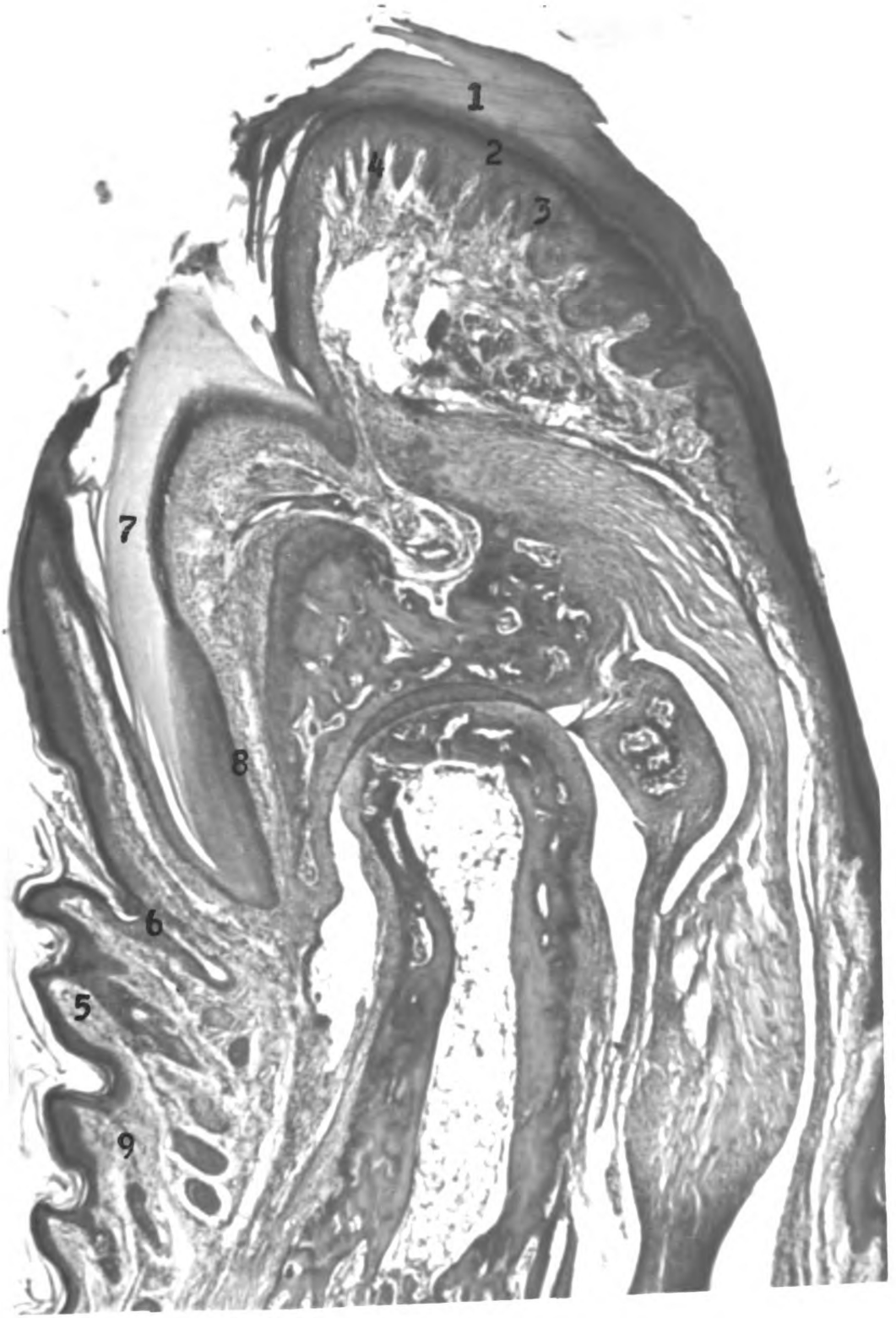
1
2
3
4
5
6
7
8
9

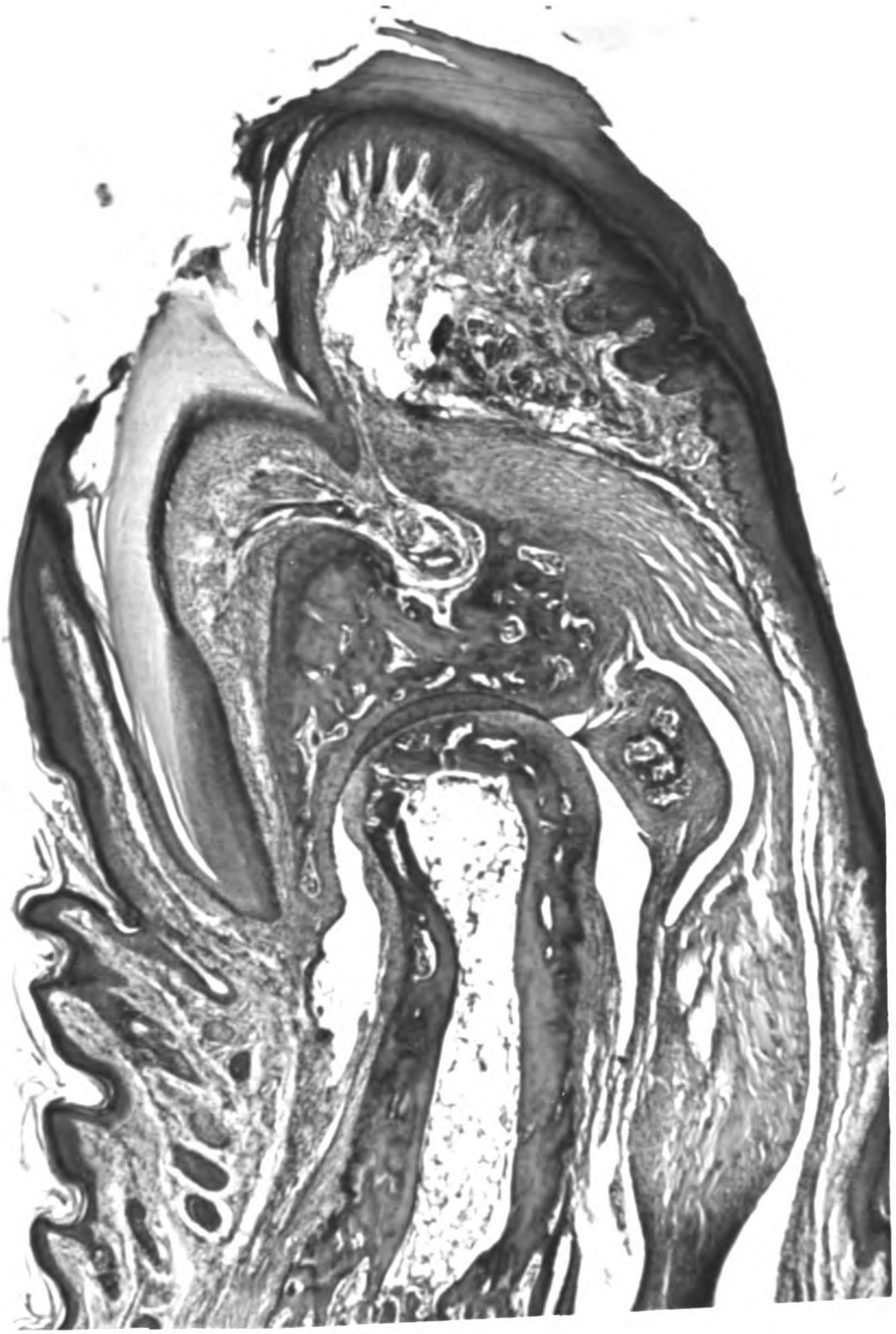

PLATE XIV

Longitudinal section of teat.
H. and E. Stain. 316X.

1. Stratum corneum
2. Stratum granulosum
3. Stratum spinosum
4. Basal layer of germinativum
5. Epidermal pegs
6. Connective tissue
7. Teat canal

1
2
3
4
5

PLATE XV

Section of tail root showing well developed stratum granulosum.
H. and E. Stain. 352X.

1. Stratum corneum
2. Stratum granulosum
3. Clear cell
4. Epidermal cells of germinativum
5. Fibroblasts
6. Stratum papillare

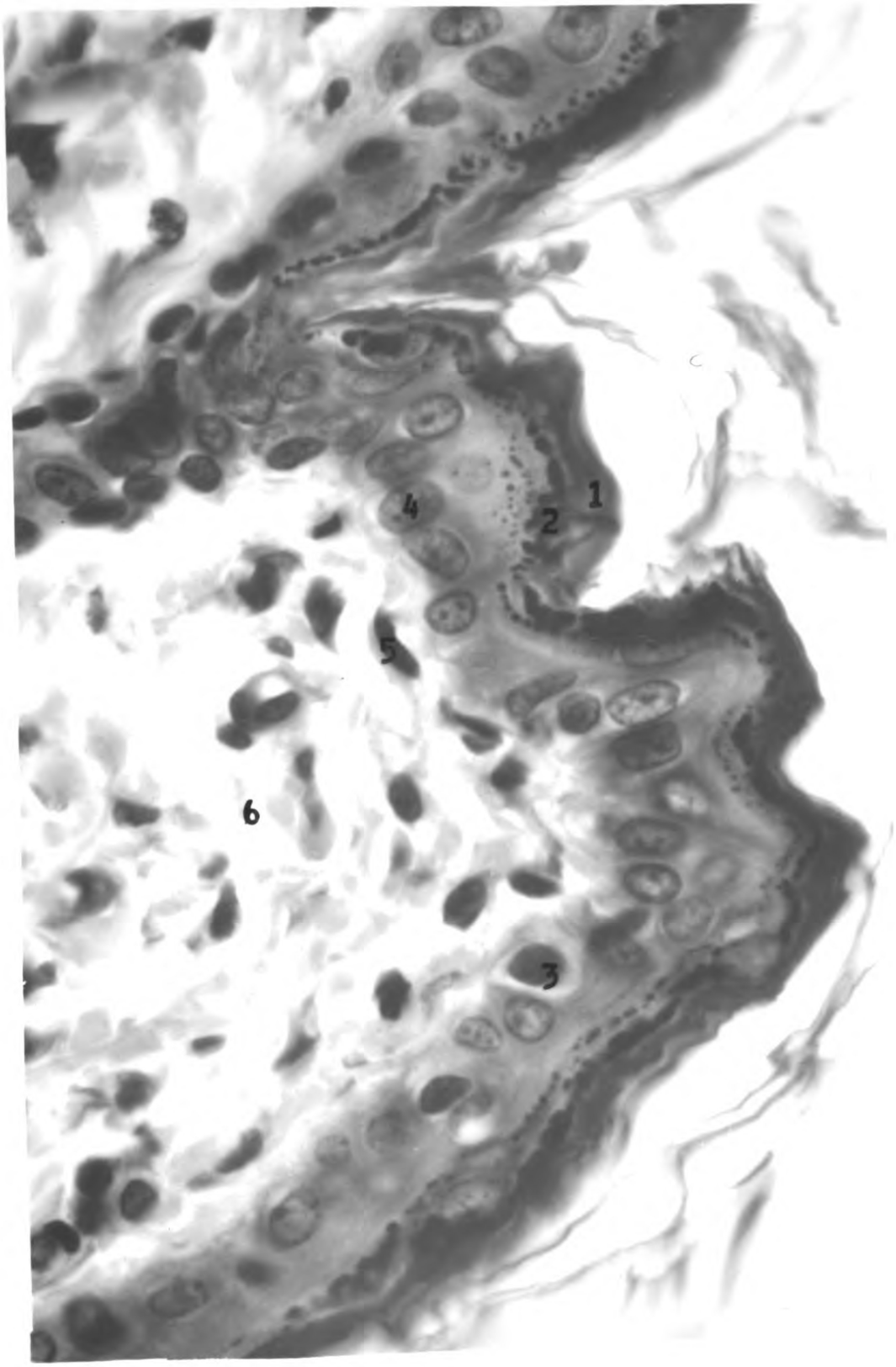
1
2
3
4
5
6

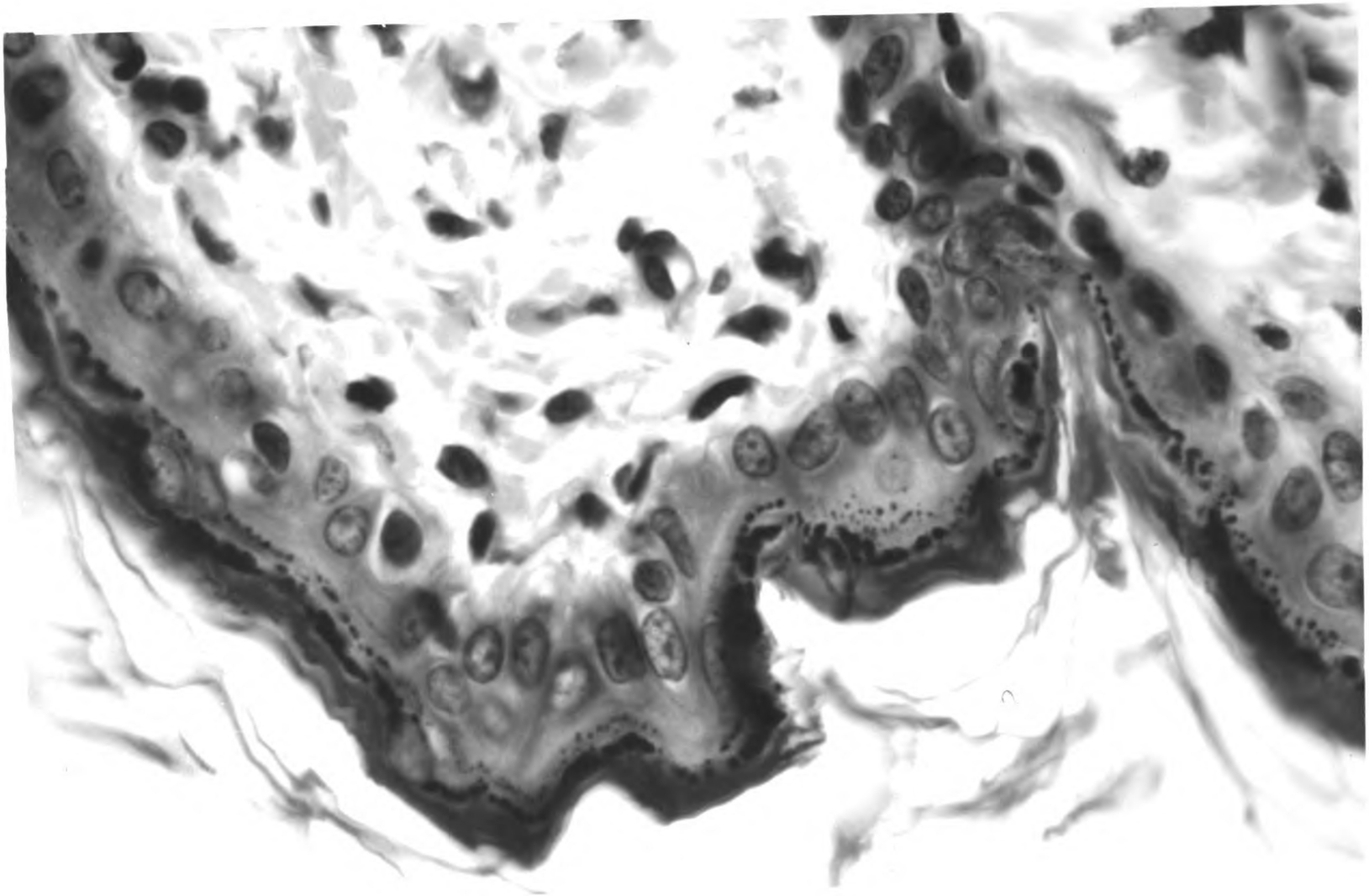

PLATE XVI

Longitudinal section through lower eyelid
and portion of palpebral conjunctiva,
with characteristic epithelium.
H. and E. Stain. 184X.

1. Orbicularis oculi muscle
2. Meibomian glands
3. Tarsal plate
4. Epithelium of palpebral conjunctiva
5. Goblet cells
6. Clear cells
7. Stratified squamous epithelium
8. Hair follicle
9. Hair follicle opening to surface

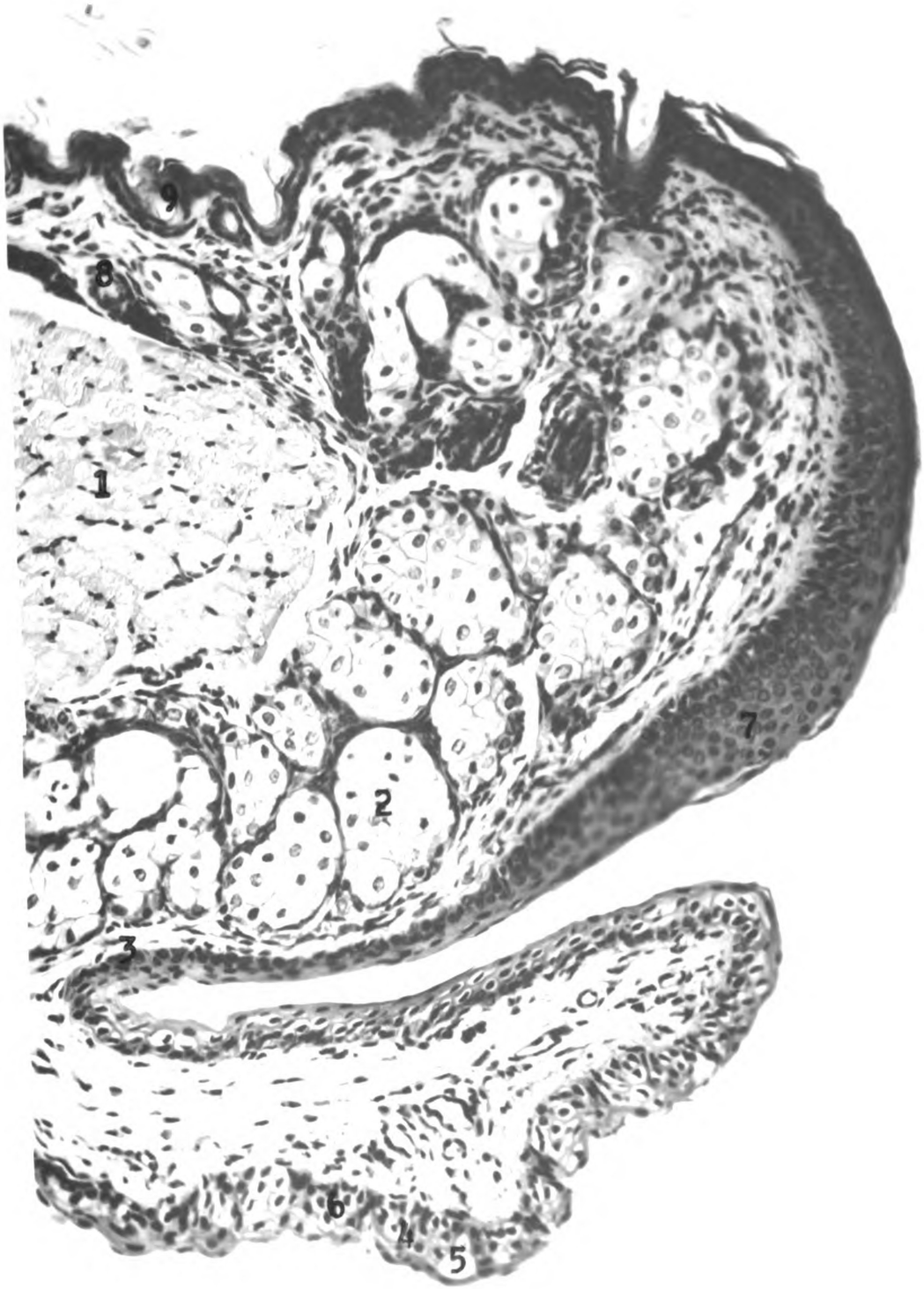
9
8
1
7
2
3
6
4
5

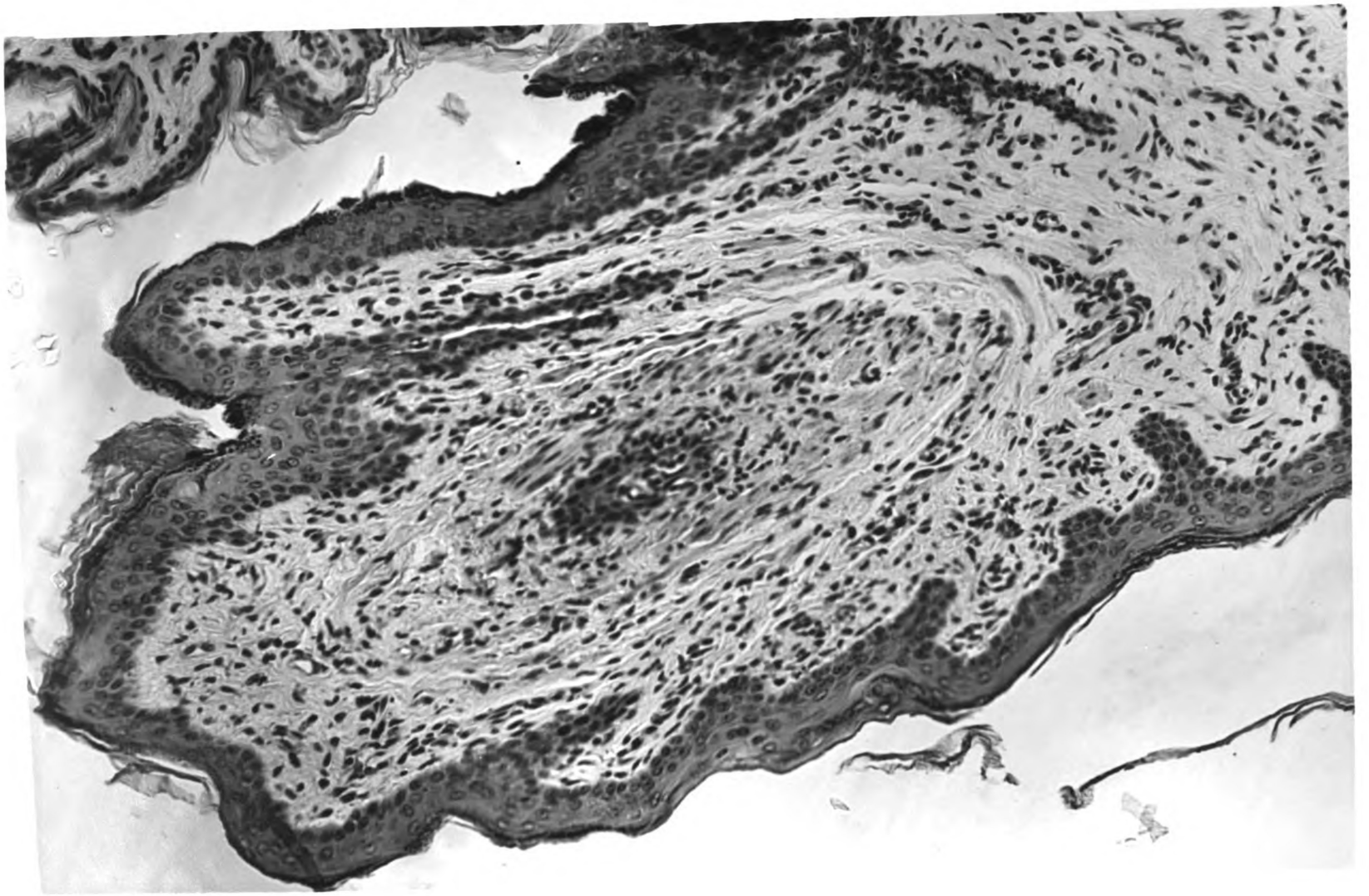

PLATE XVII

Section of palpebral conjunctiva showing goblet cells and clear cells.
H. and E. Stain. 1230X.

1. Goblet cell
2. Clear cells
3. Clear cells showing mitosis
4. Connective tissue with fibroblasts

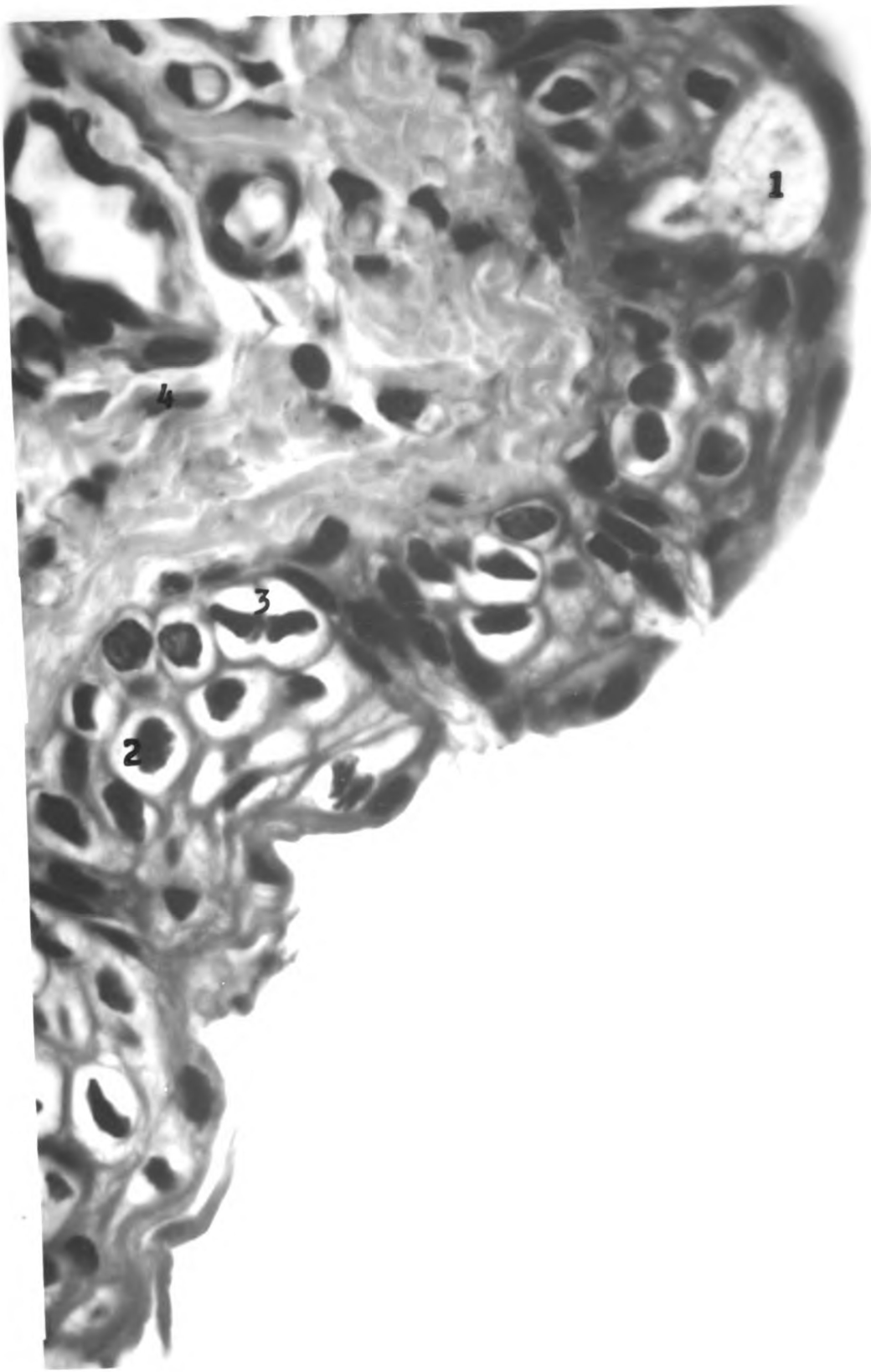
1
2
3
4

PLATE XVIII

Section of tail showing the basement membrane.
Periodic Acid-Schiff. 1168X.

1. Stratum corneum
2. Stratum germinativum
3. Compressed basal cells
4. Basement membrane
5. Dermis
6. Capillary plexuses

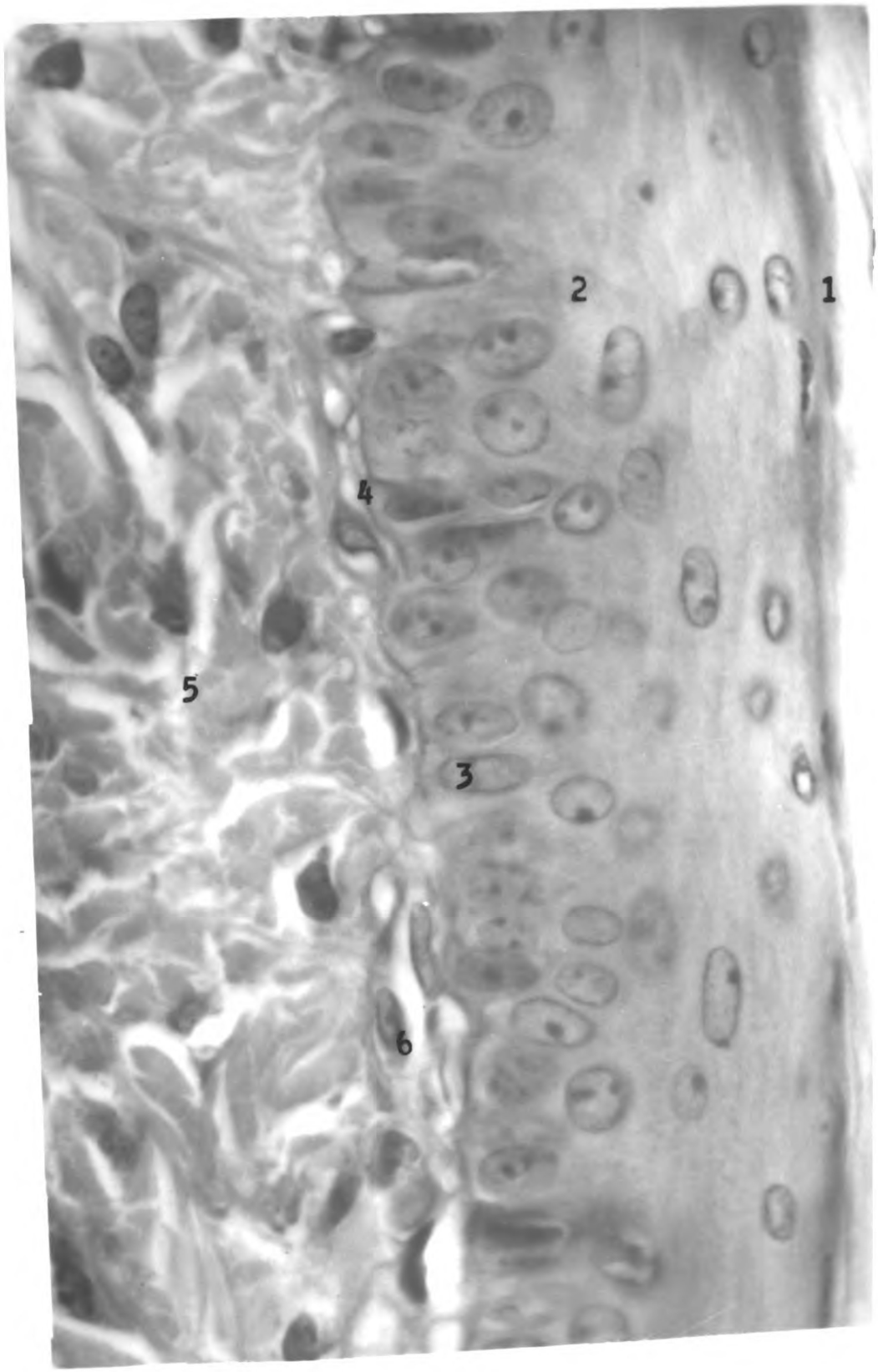
1
2
3
4
5
6

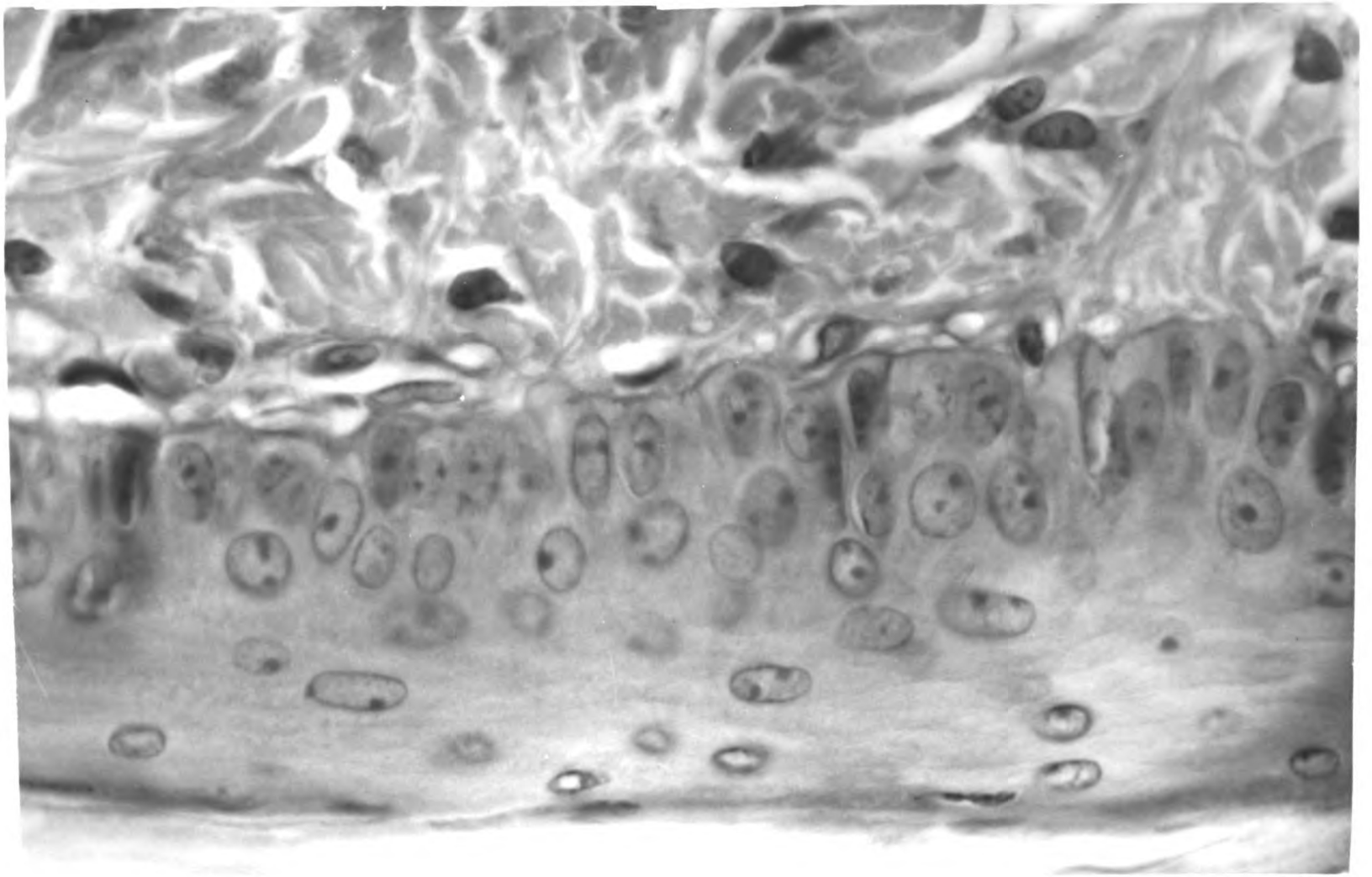

PLATE XIX

Section of tail showing reticular fibers
of basement membrane.
Wilder's Reticulum Stain. 1079X.

1. Stratum corneum

2. Stratum germinativum

3. Fibers of reticulum in
   basement membrane

4. Collagenous fibers of dermis

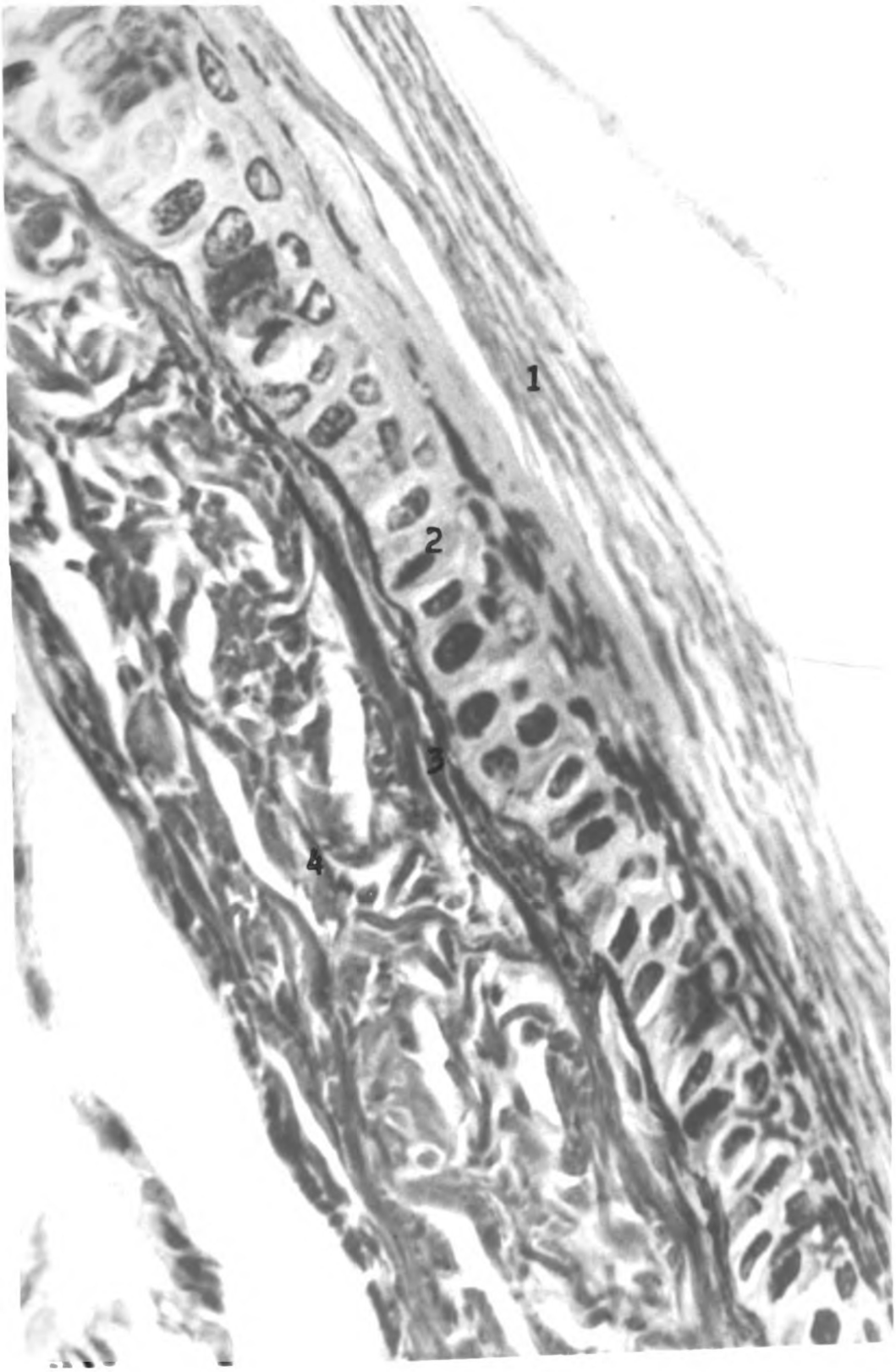
1
2
3
4

PLATE XX

Medial surface of fore leg showing elastic tissue. Weigert's and Van Gieson's Stain. 396X.

1. Stratum corneum
2. Stratum granulosum
3. Stratum germinativum
4. Fine elastic fibers approaching basal layer of germinativum
5. Stratum papillare
6. Coarse elastic fibers in stratum reticulare
7. Hair follicles
8. Sebaceous glands
9. Mast cells

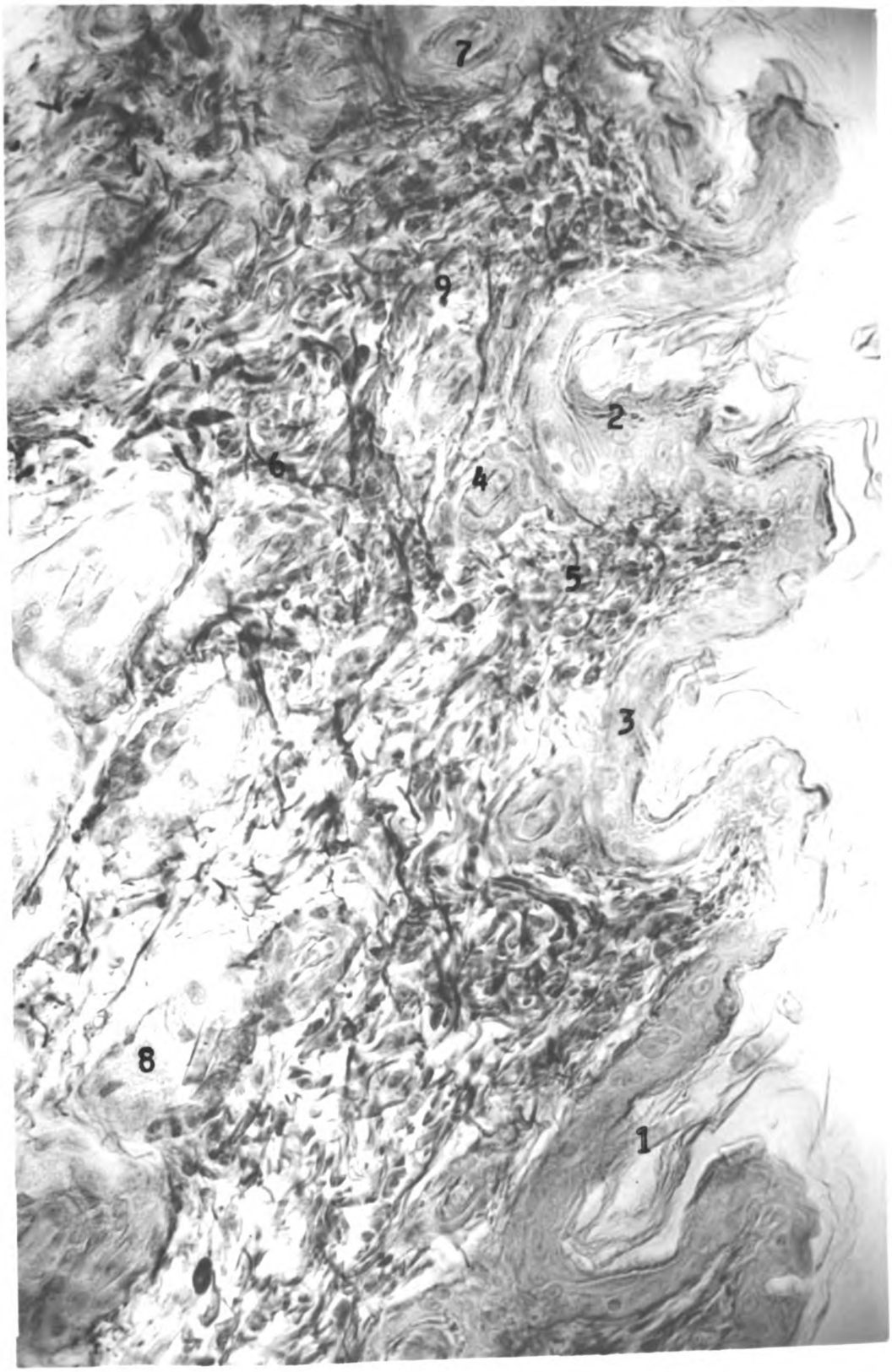
7
9
2
6
4
5
3
8
1

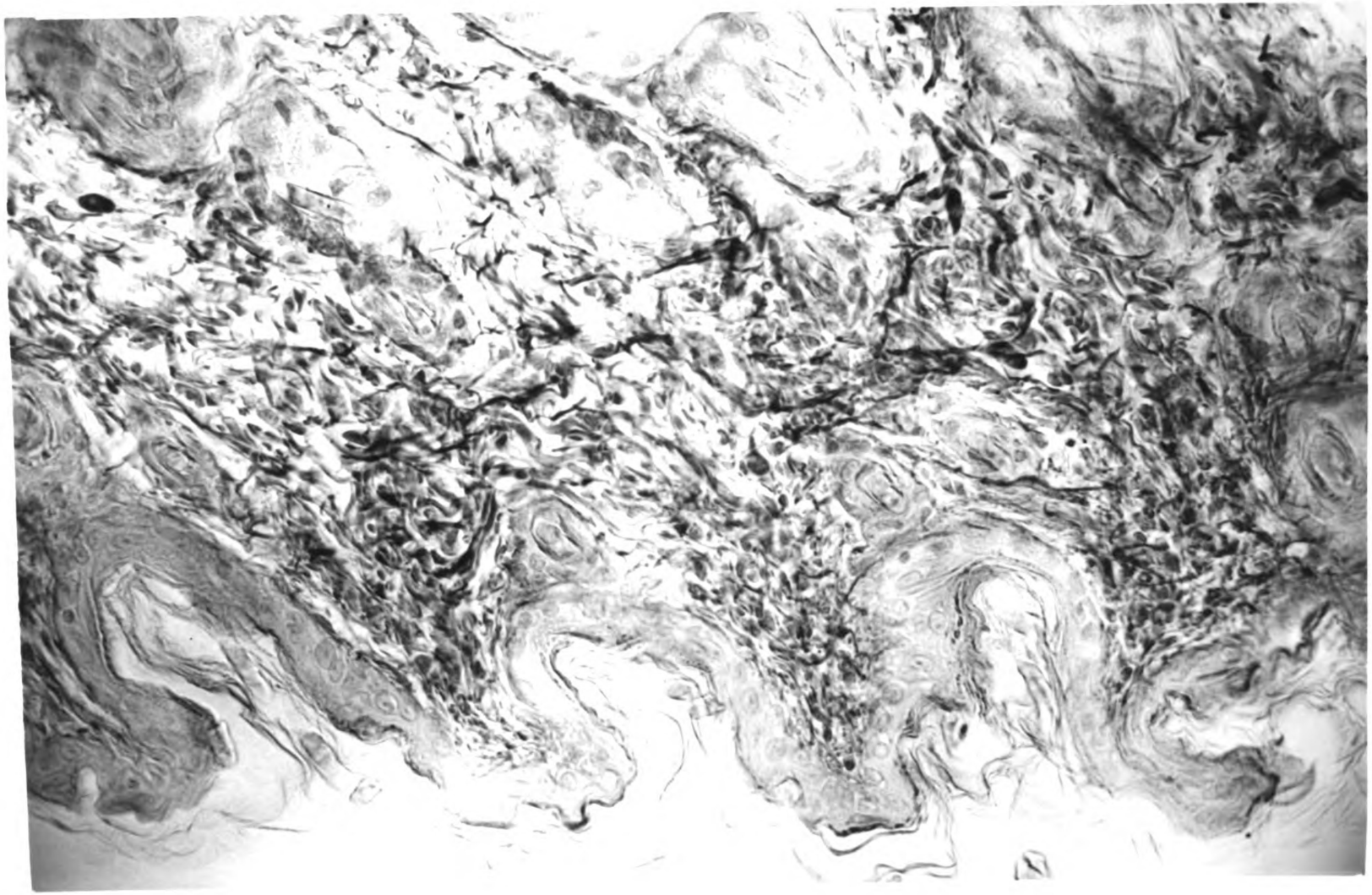

PLATE XXI

Frontal section of the tail root showing cross section of hair pattern.
Weigert's and Van Gieson's Stain. 7X.

1. Large central follicle with smaller secondary follicles

2. Adipose tissue

3. Connective tissue

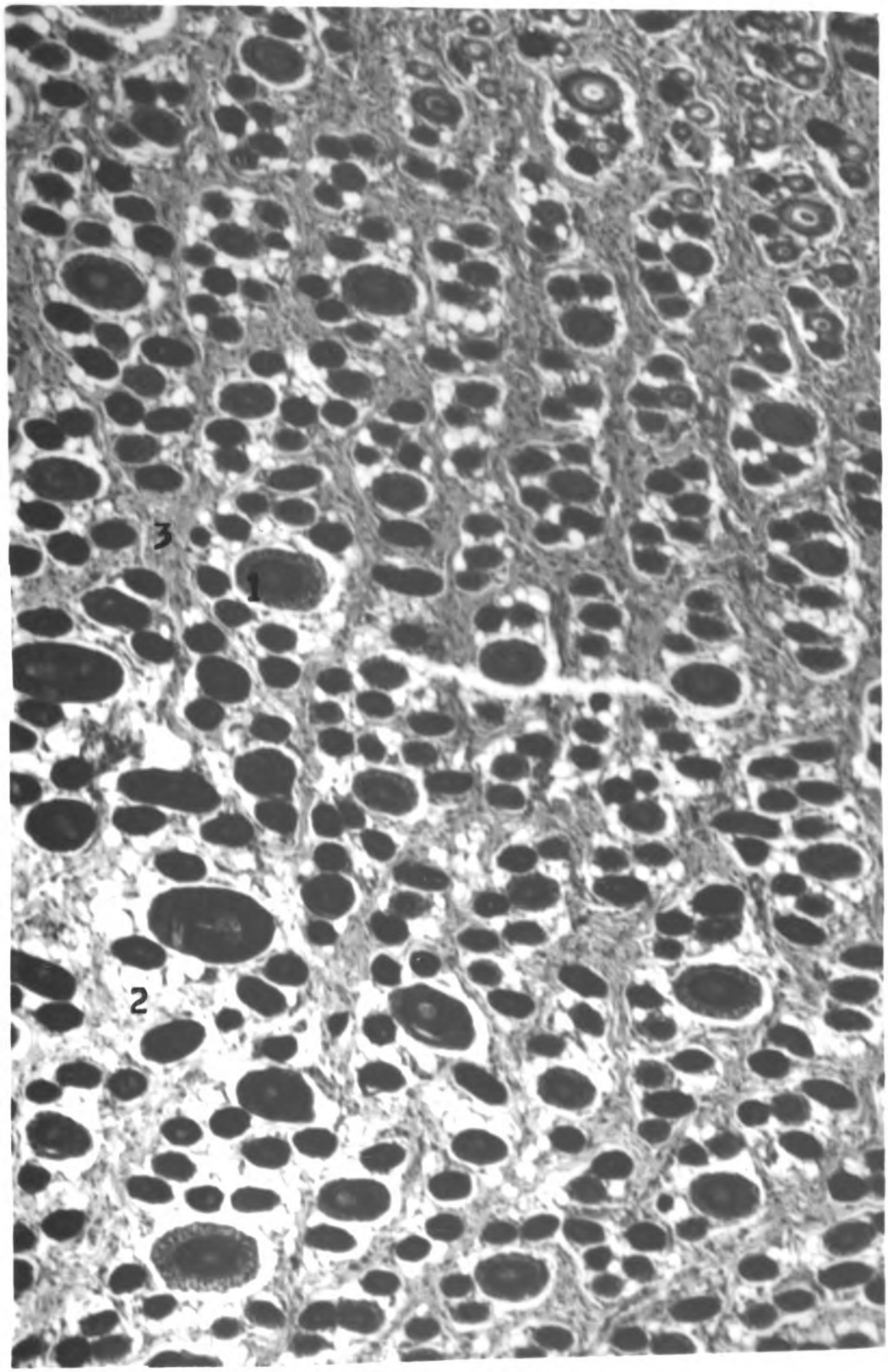
3
1
2

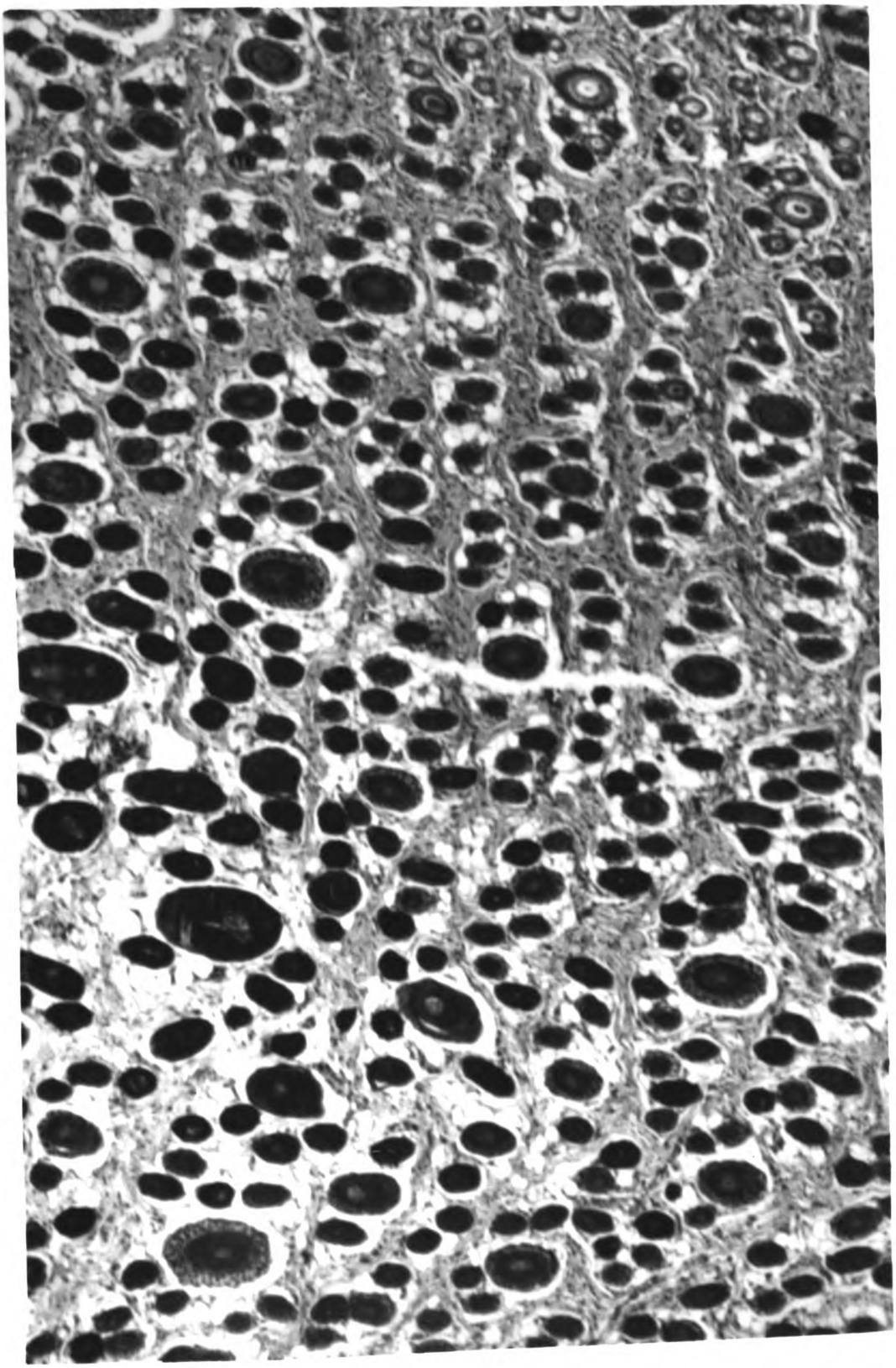

PLATE XXII

Frontal section of the shoulder showing linear hair pattern.
H. and E. Stain. 7X.

1. Large central follicle with smaller secondary follicles

2. Adipose tissue

3. Connective tissue

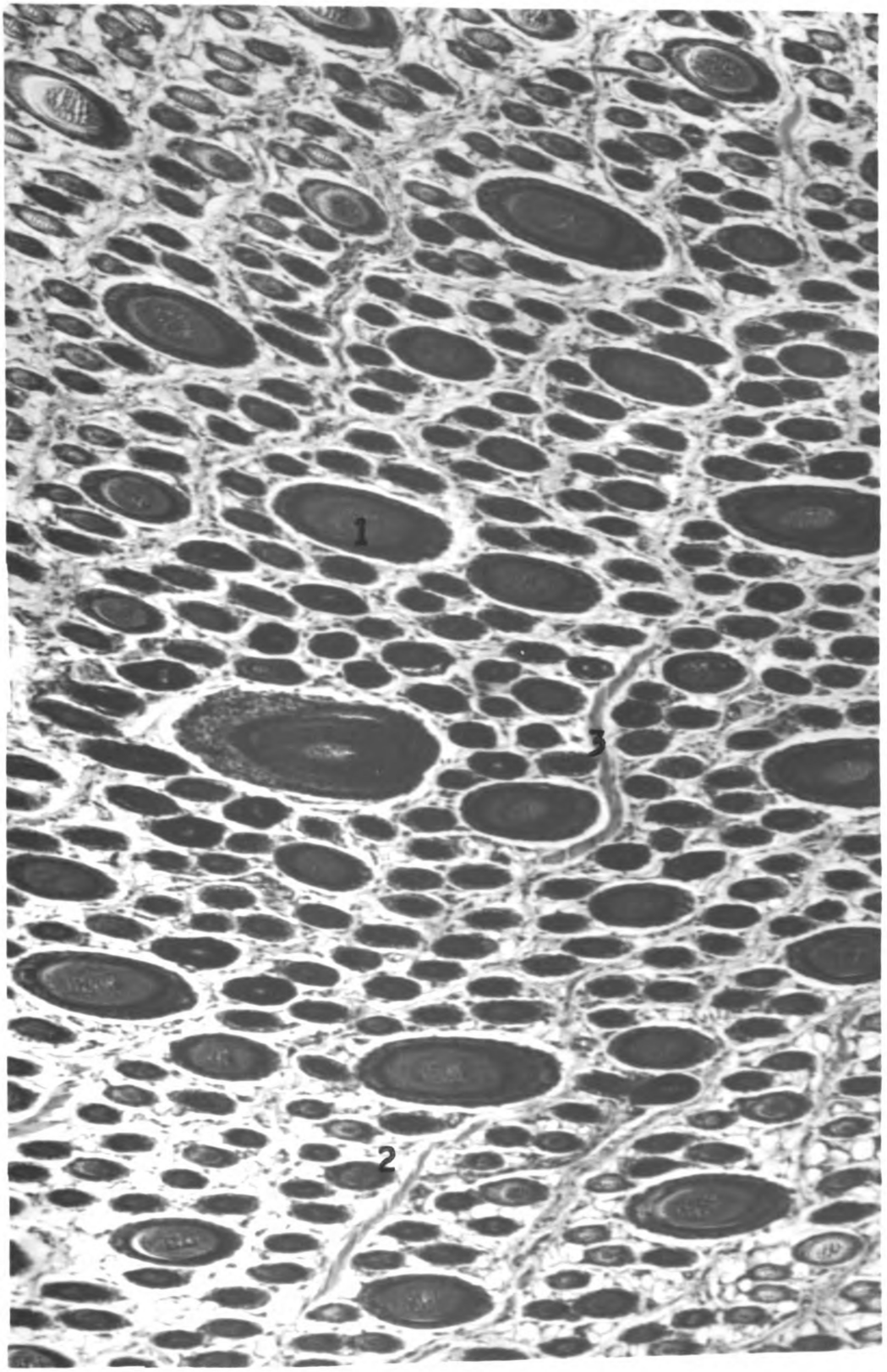
1
3
2

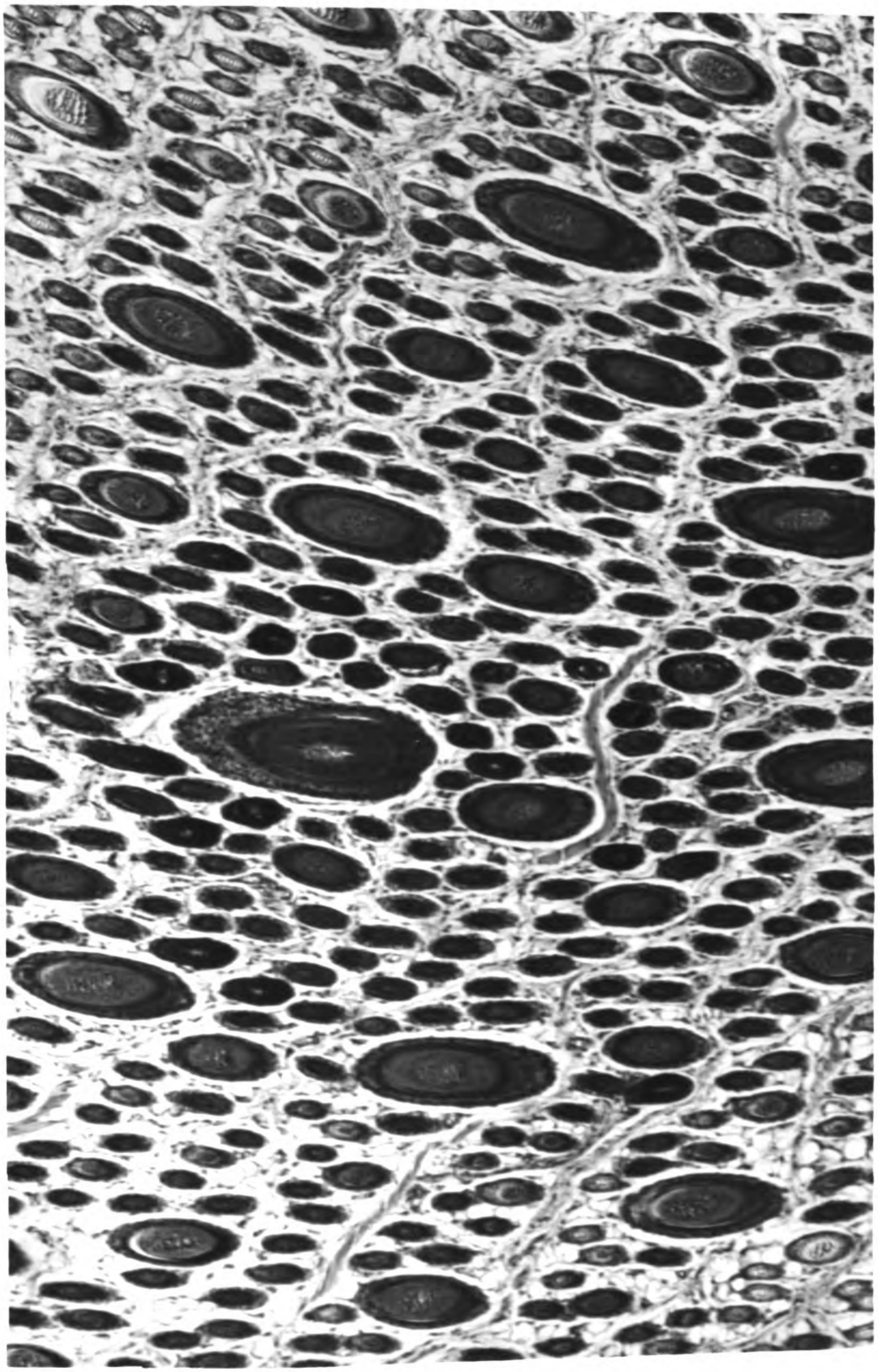

PLATE XXIII

Longitudinal section of lateral abdomen
showing follicular folds.
Reticulum Stain. 289X.

1. Follicular folds in epithelial sheath
2. Sebaceous gland
3. Hair shaft
4. Scale-like cuticle of hair shaft
5. Sebaceous duct opening into neck of follicle

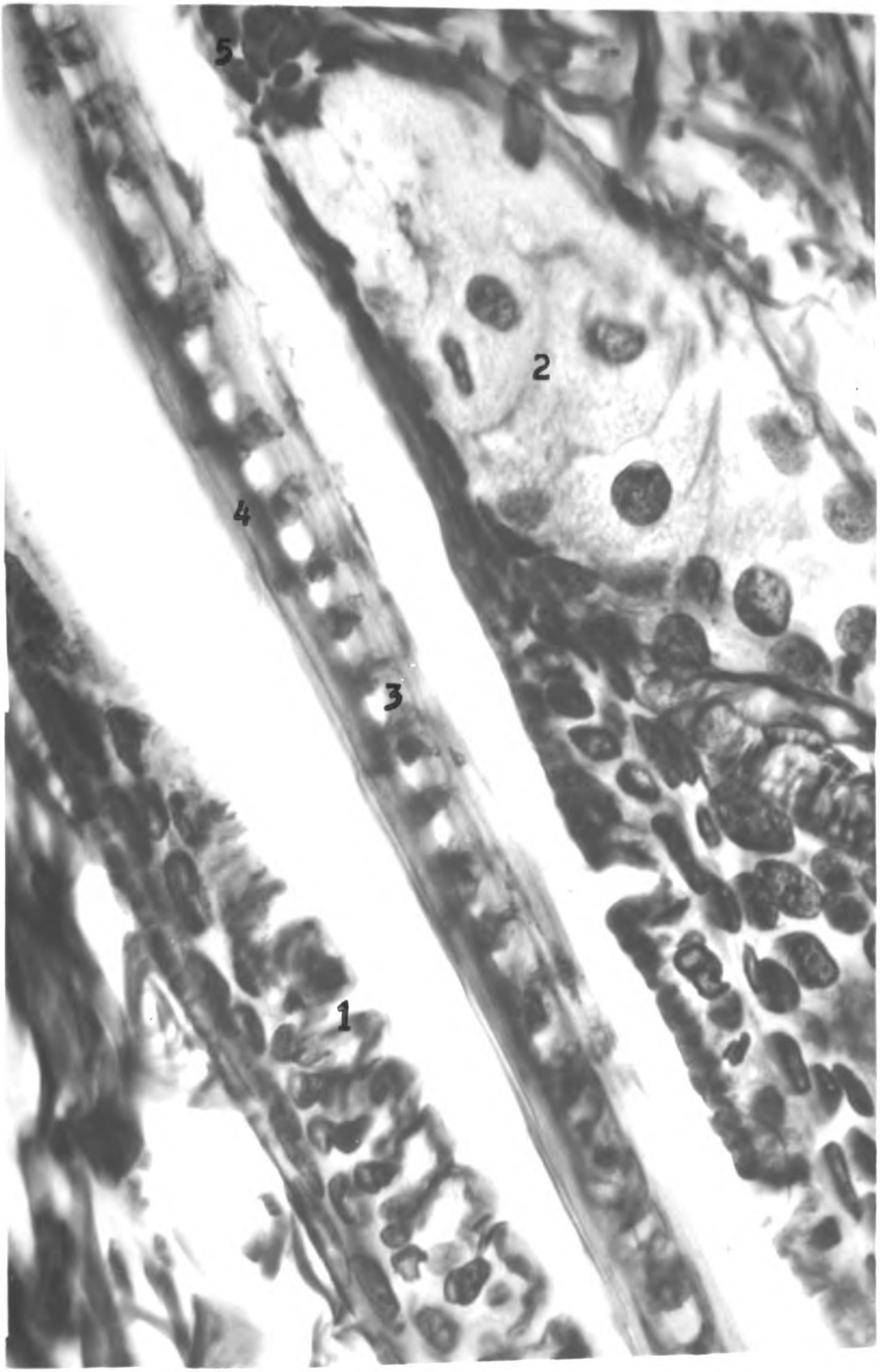
5
2
4
3
1

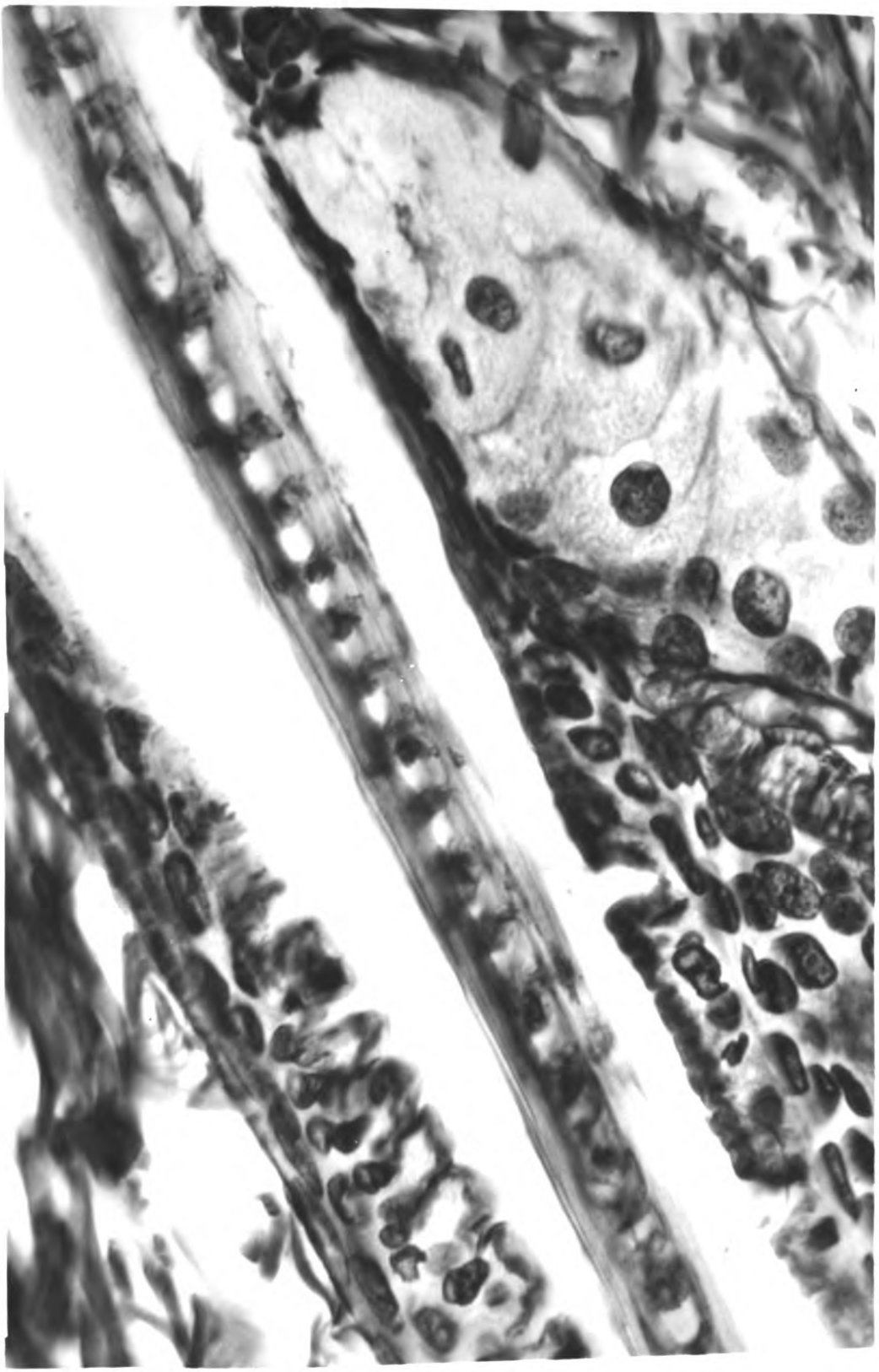

PLATE XXIV

Longitudinal section of eyelash
in upper eyelid.
H. and E. Stain. 230X.

1. Papilla of hair bulb

2. Outer root sheath

3. Inner root sheath

4. Cuticle

5. Cortex

6. Thickened dermal sheath

7. Striated muscle fibers attached to dermal sheath

8. Cross section of nerve bundle

9. Orbicularis oculi muscle fibers

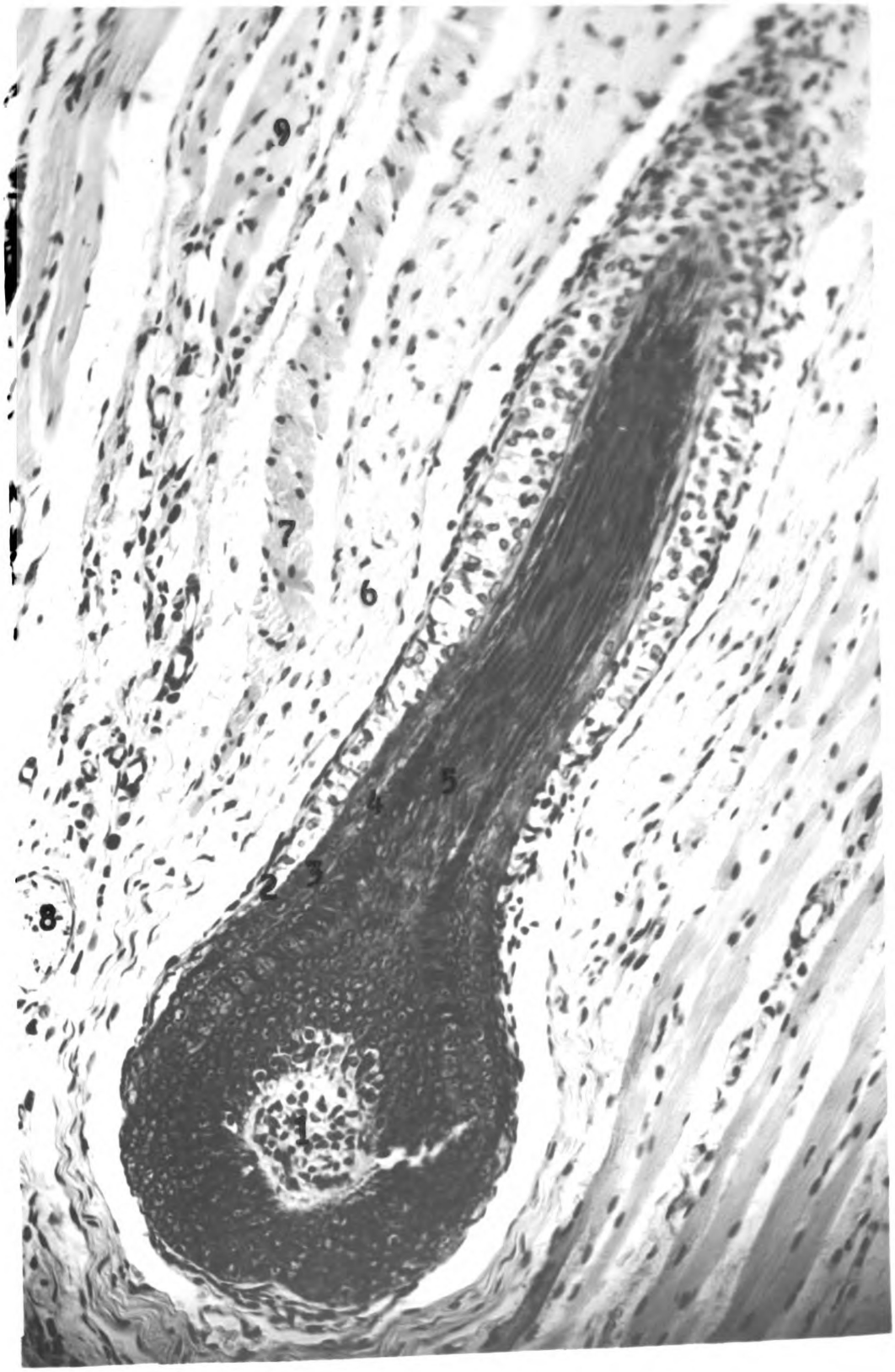
1
2
3
4
5
6
7
8
9

PLATE XXV

Cross section of tactile hair in the nose.
H. and E. Stain. 230X.

1. Cortex
2. Cuticle of hair shaft
3. Inner root sheath
4. Outer root sheath
5. Blood sinus
6. Dermal sheath
7. Striated muscle fibers attached to dermal sheath
8. Large nerve bundles entering dermal sheath

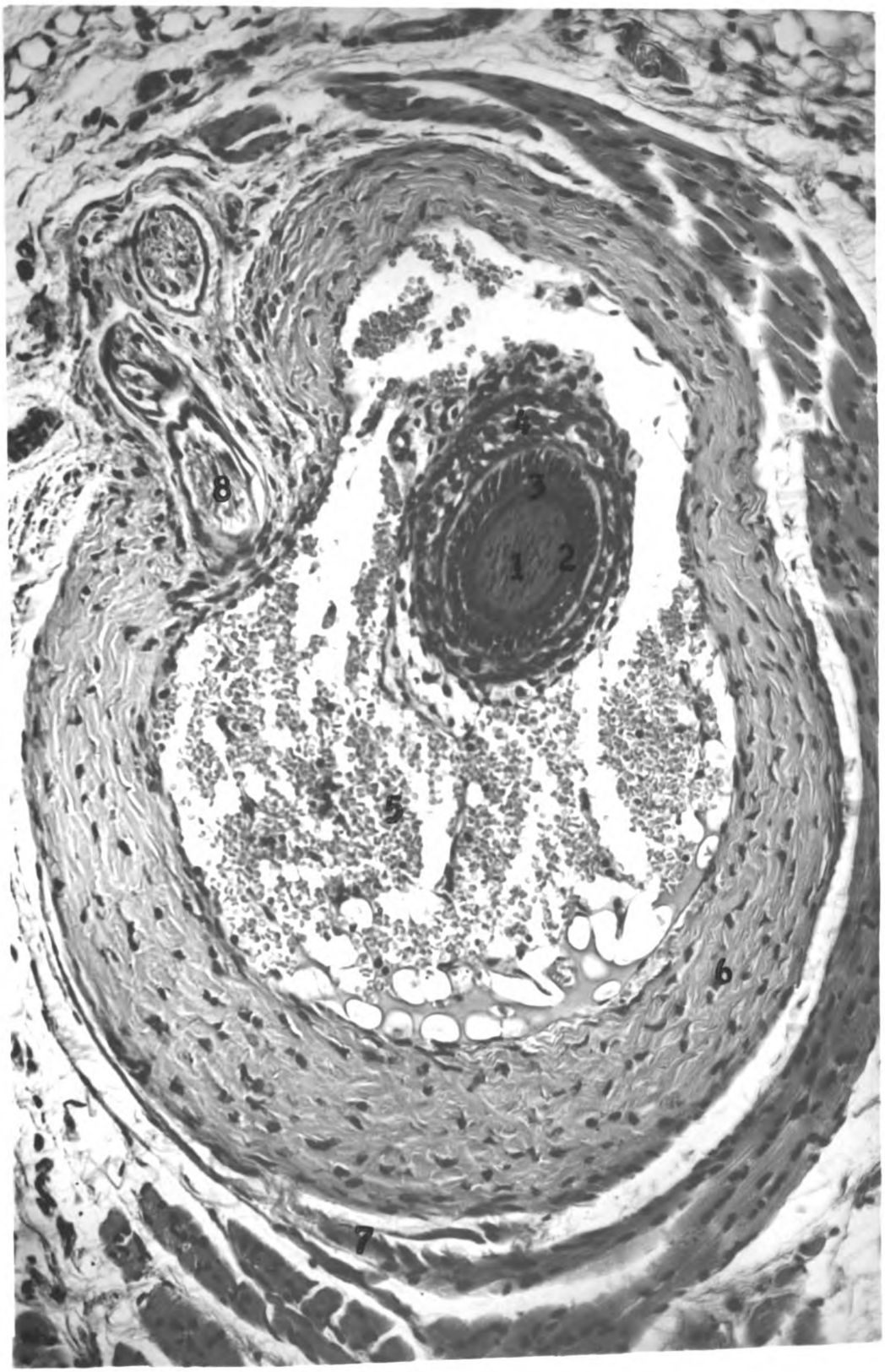
4
3
8
1
2
5
6
7

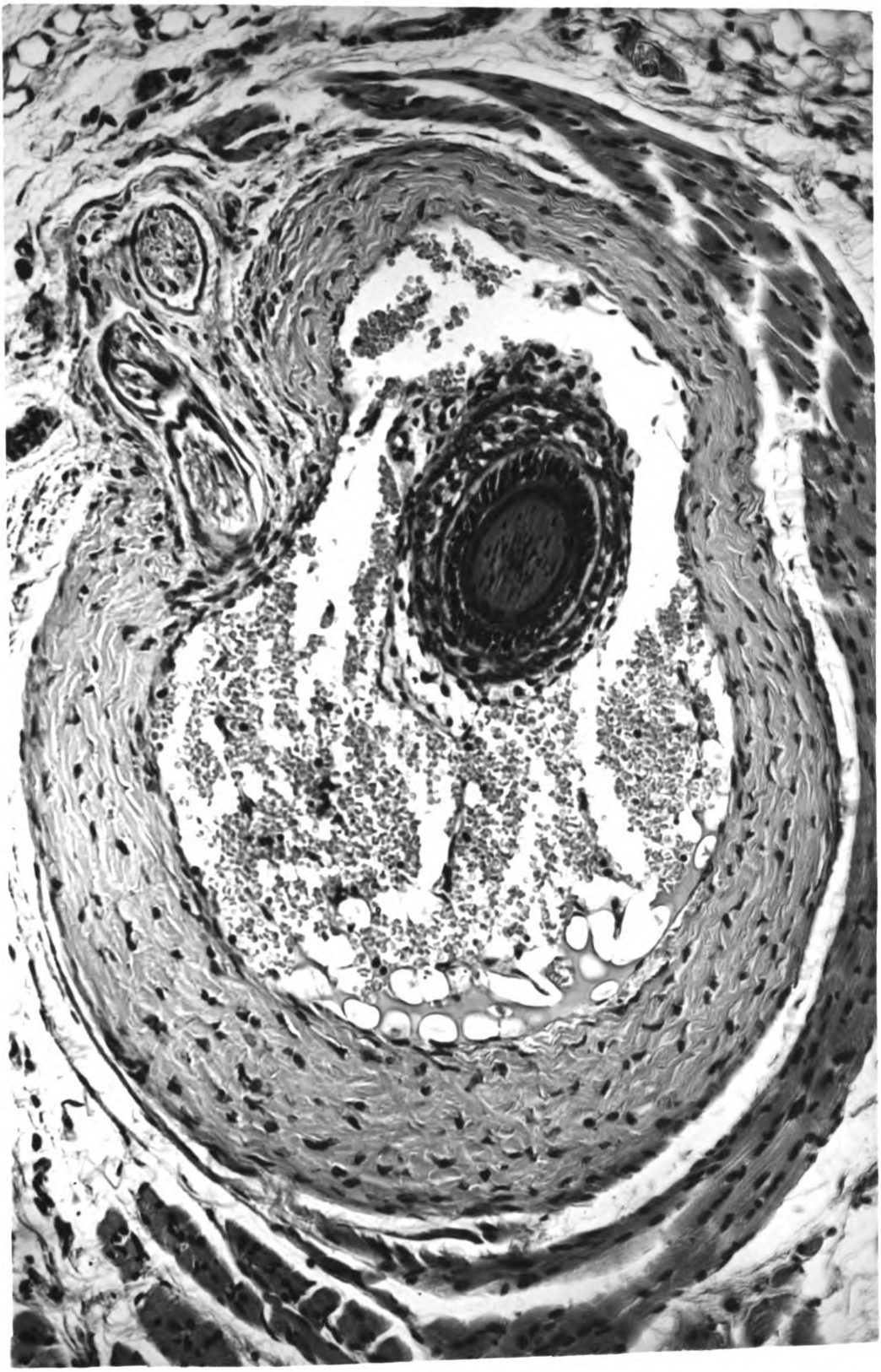

PLATE XXVI

Sebaceous gland opening into follicle.
H. and E. Stain. 654X.

1. Epithelial sheath
2. Hair shaft
3. Sebum
4. Degenerating cells containing lipid droplets

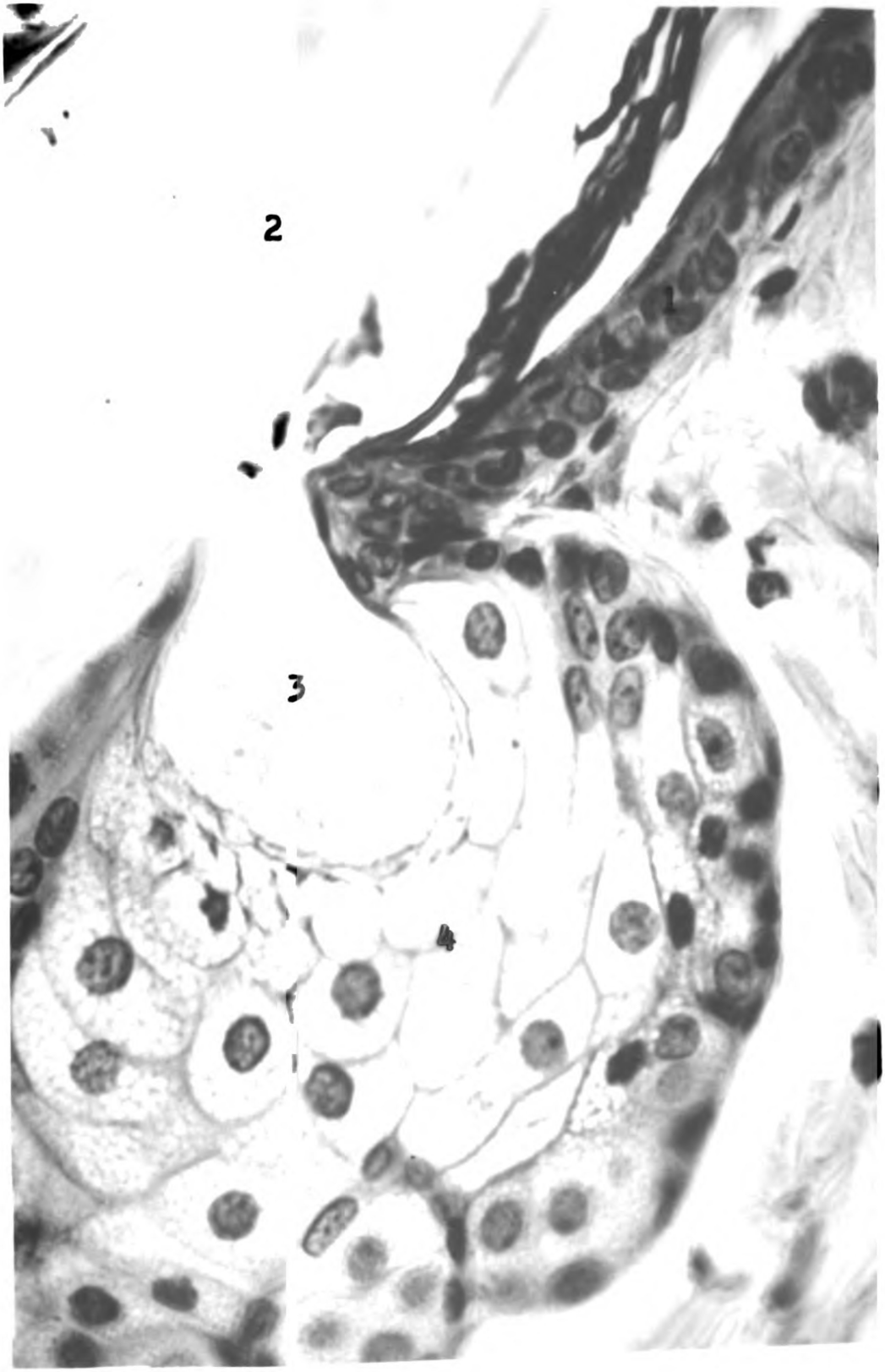
2
1
3
4

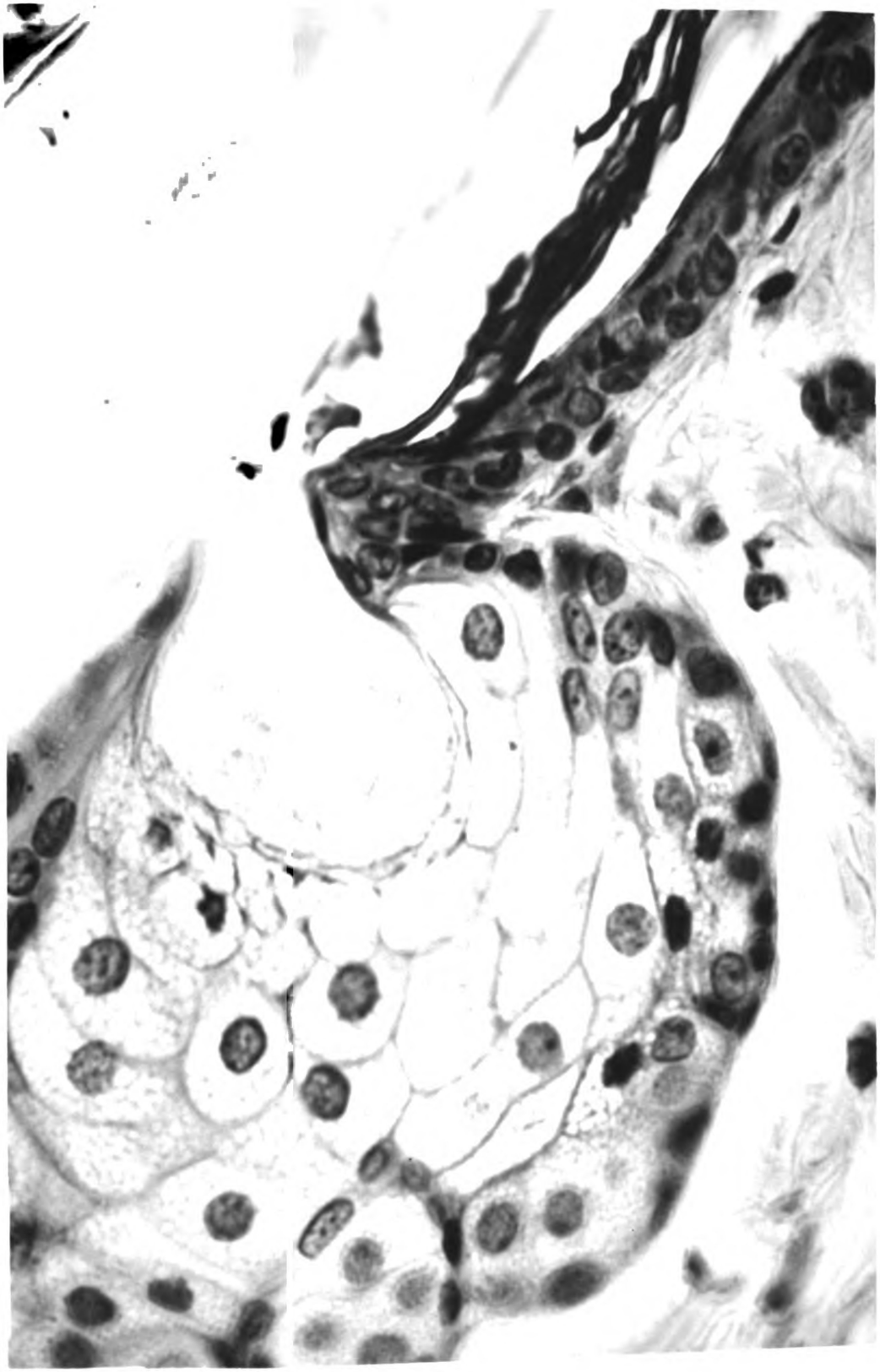

PLATE XXVII

Sweat glands in the metacarpal pad.
H. and E. Stain. 286X.

1. Coiled merocrine sweat glands

2. Loose connective tissue fibers

3. Adipose tissue

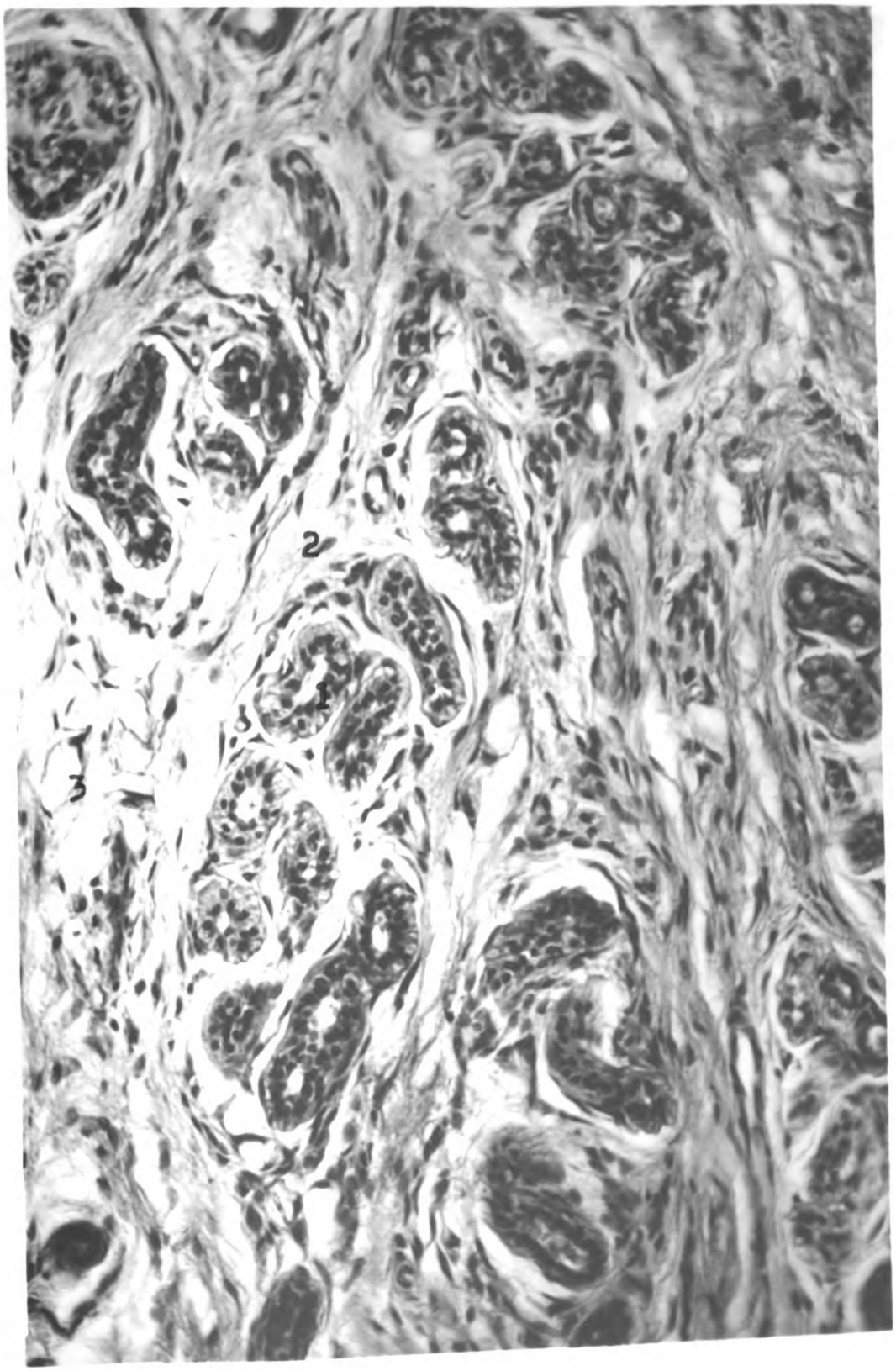
2
1
3

PLATE XXVIII

Longitudinal section of upper eyelid.
H. and E. Stain. 8X.

1. Eyelash
2. Tarsal (Meibomian) glands
3. Tarsal plate
4. Orbicularis oculi muscle
5. Cross section of tactile hair
6. Epithelium of palpebral conjunctiva
7. Hair follicles on outer edge of eyelid
8. Thickened stratified squamous epithelium of lid tip

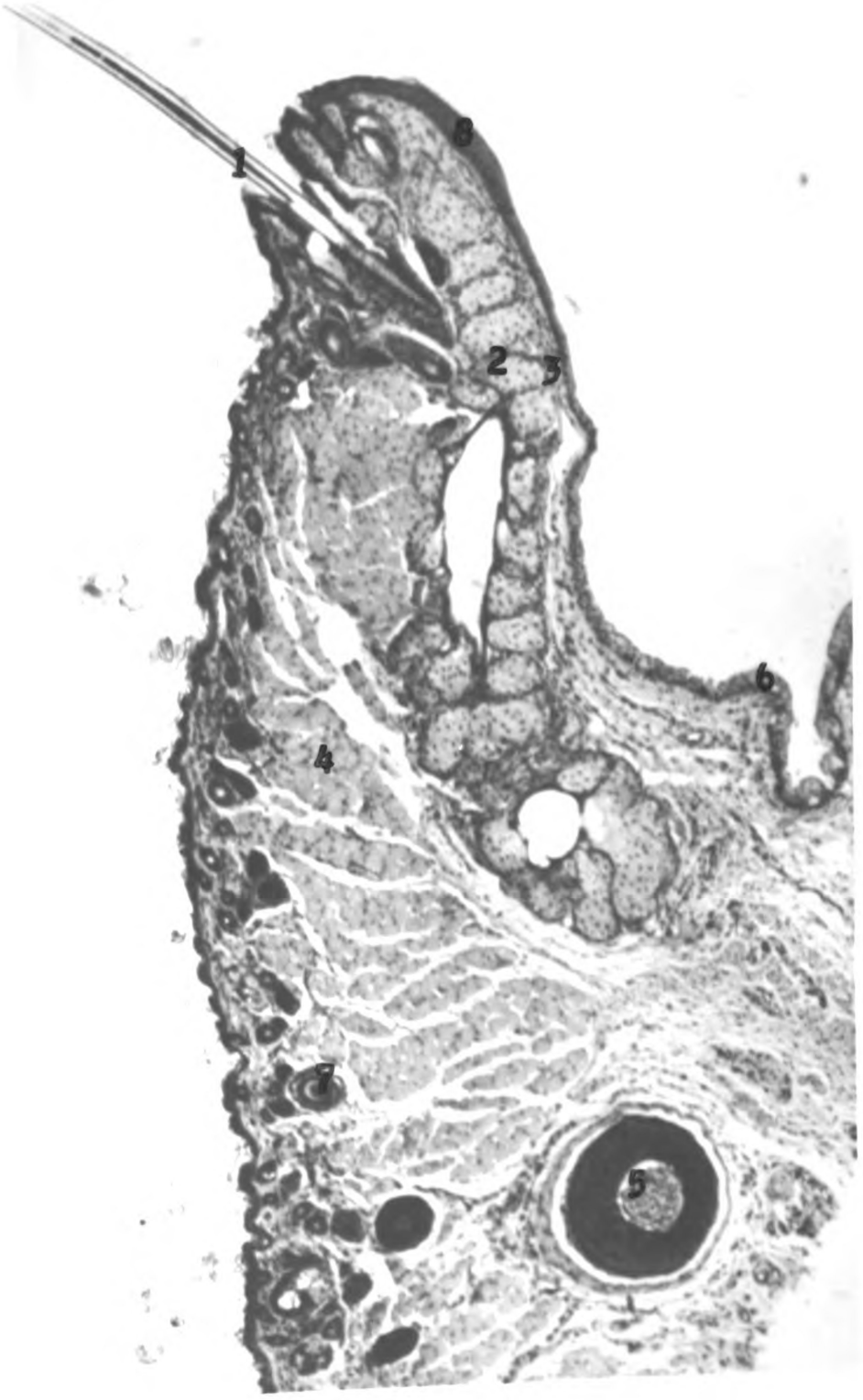
1
8
2
3
6
4
7
5

PLATE XXIX

Longitudinal section of lower lip.
H. and E. Stain. 26X.

1. Pilosebaceous units of the outer lip surface

2. Thickened stratified squamous epithelium of the oral lip surface

3. Muscle fibers

4. Connective tissue fibers

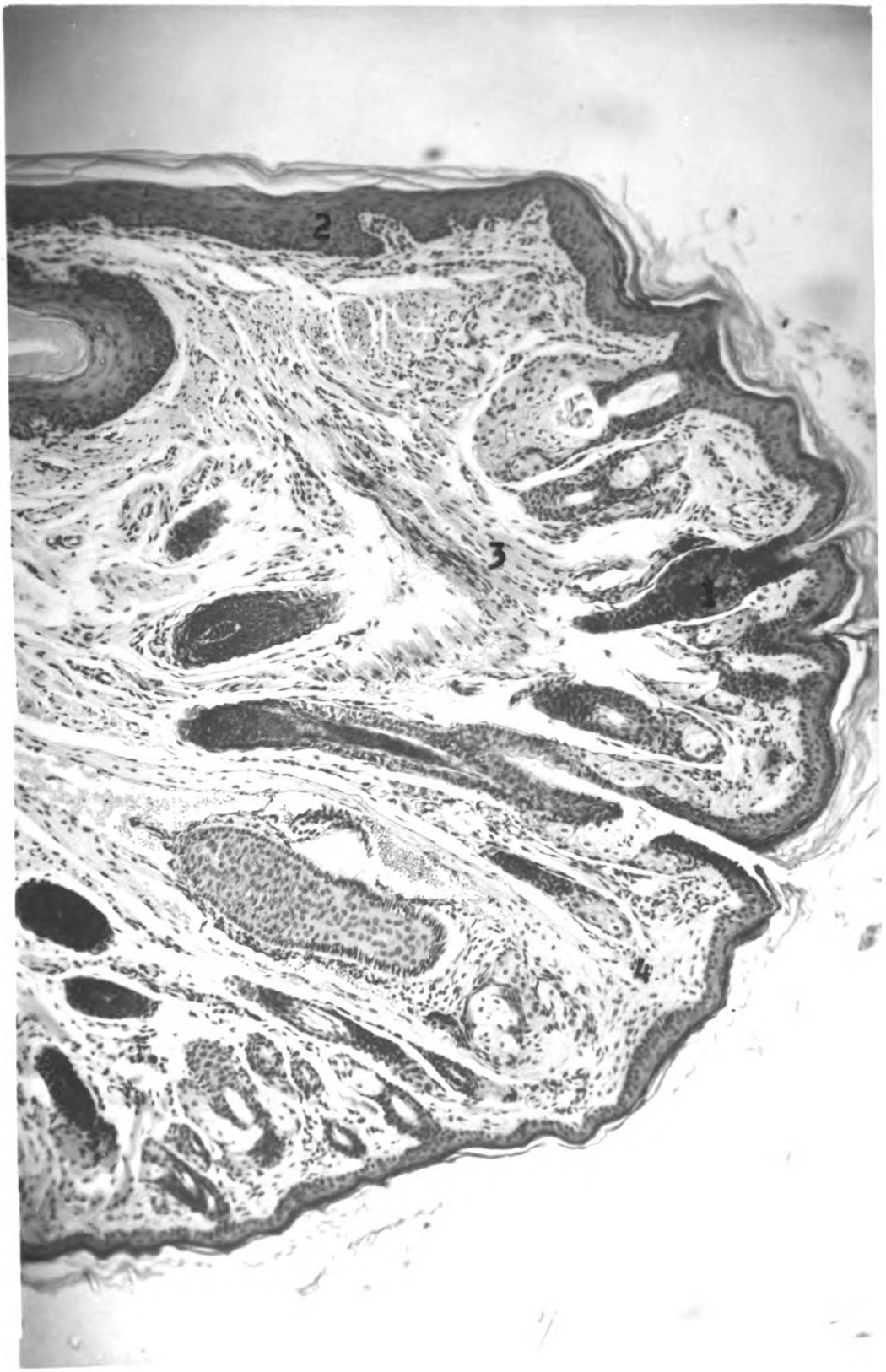
2
3
1
4

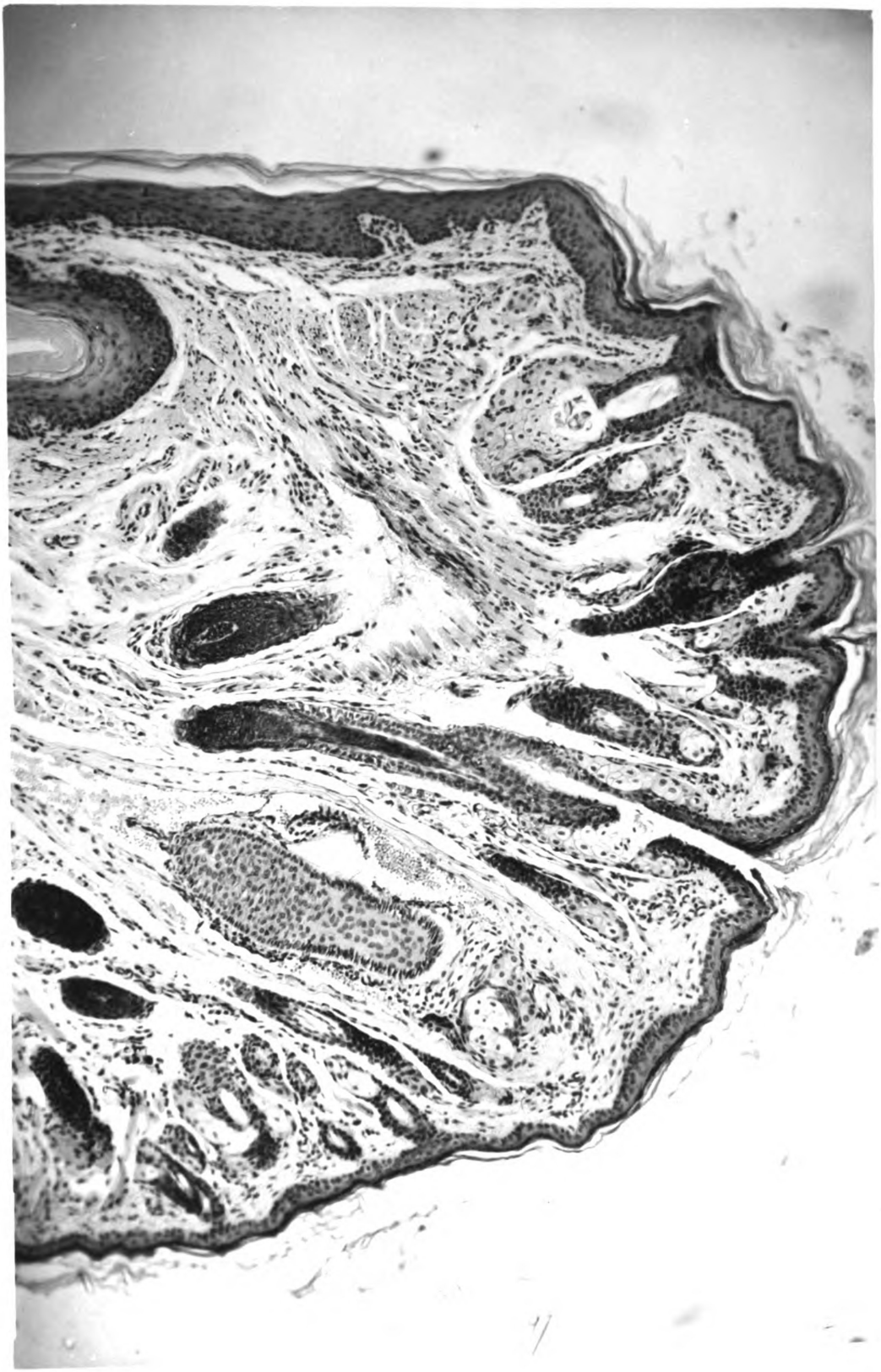

PLATE XXX

Cross section of prepuce
H. and E. Stain. 310X.

1. Stratum corneum
2. Stratum granulosum
3. Stratum germinativum
4. Hair follicles
5. Stratum papillare
6. Stratum reticulare
7. Hypodermis
8. Adipose tissue
9. Inner preputial mucosa
10. Horny papillae of penis

1
2
3
5
6
8
4
7
9
10

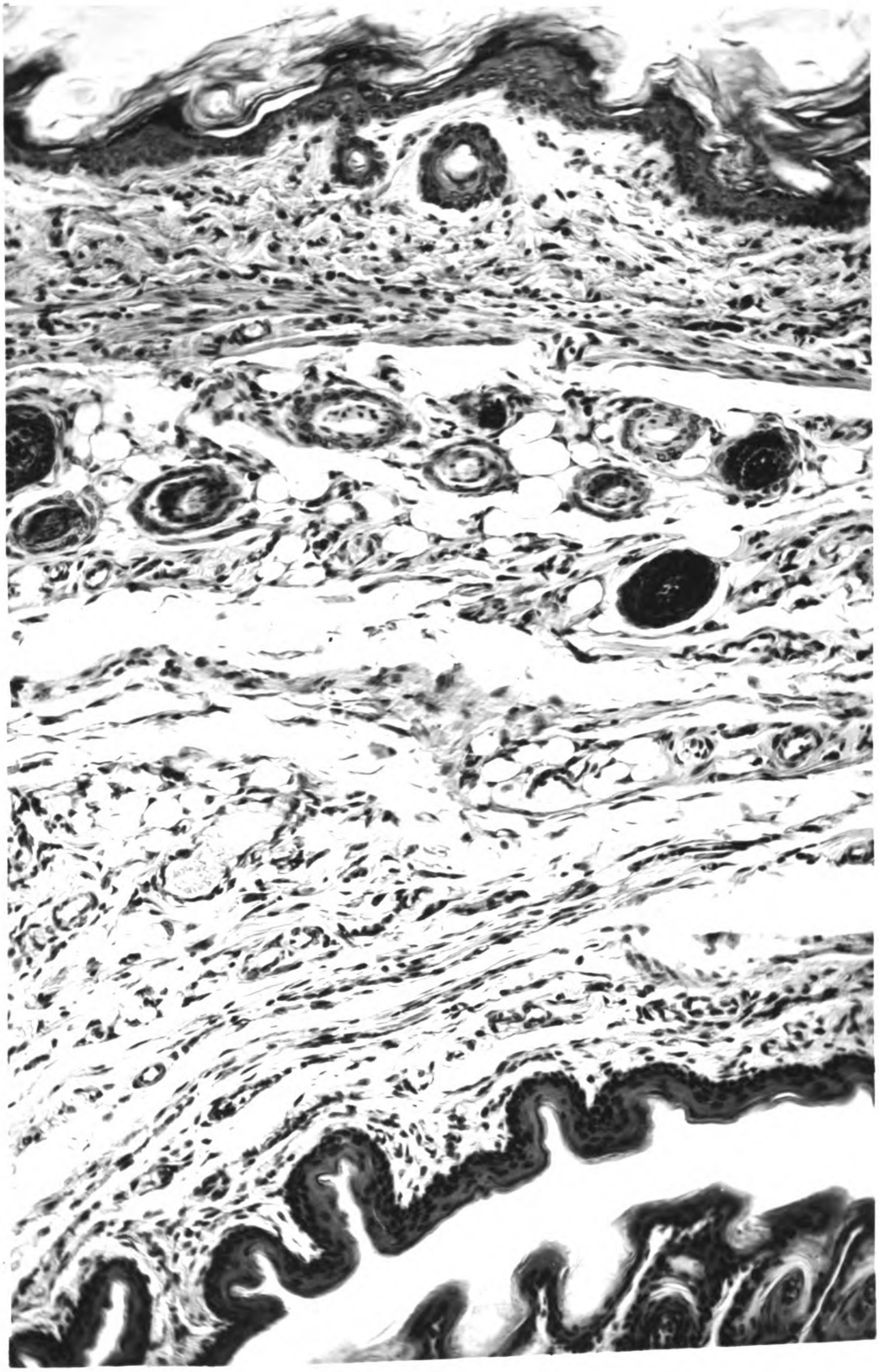

PLATE XXXI

Cross section of labium.
H. and E. Stain. 387X.

1. Stratum corneum
2. Stratum germinativum
3. Hair follicles
4. Sebaceous glands
5. Stratum papillare
6. Stratum reticulare
7. Panniculus adiposus

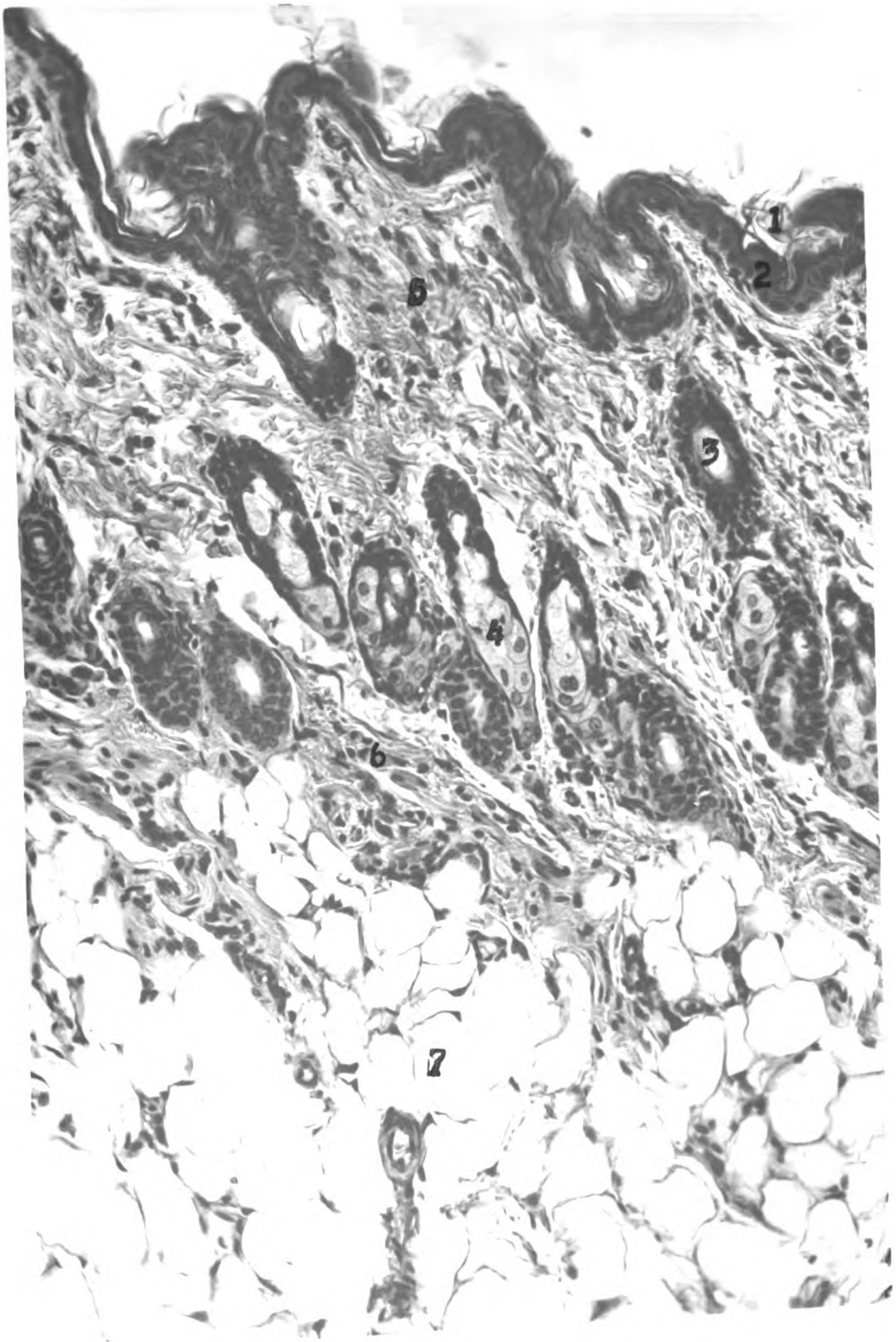
1
2
5
3
4
6
7

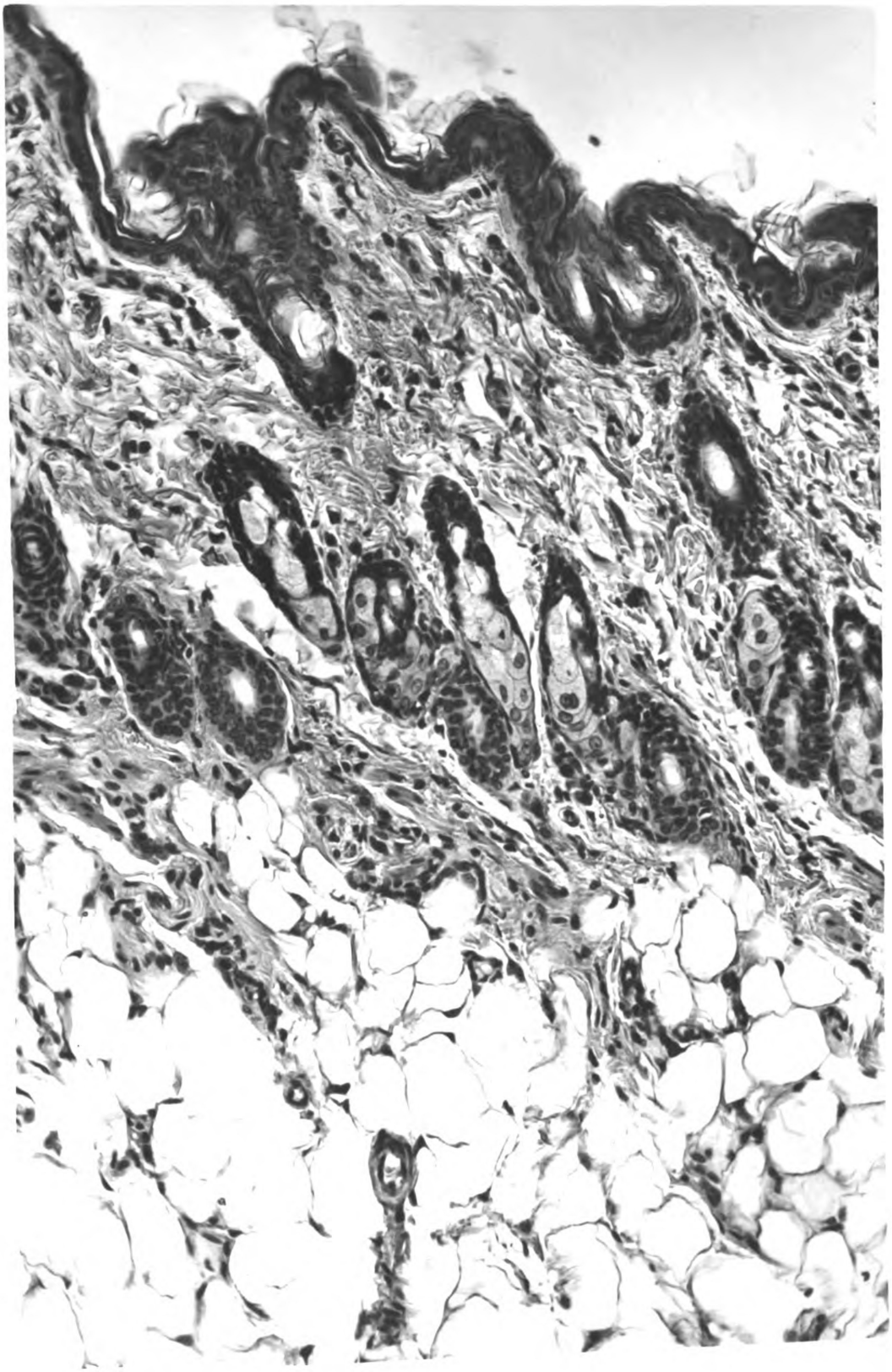

PLATE XXXII

Longitudinal section of scrotum
H. and E. Stain. 366X.

1. Stratum corneum
2. Stratum germinativum
3. Stratum papillare
4. Stratum reticulare
5. Hair follicles
6. Sebaceous glands
7. Adipose tissue

1
2
3
4
5
6
7

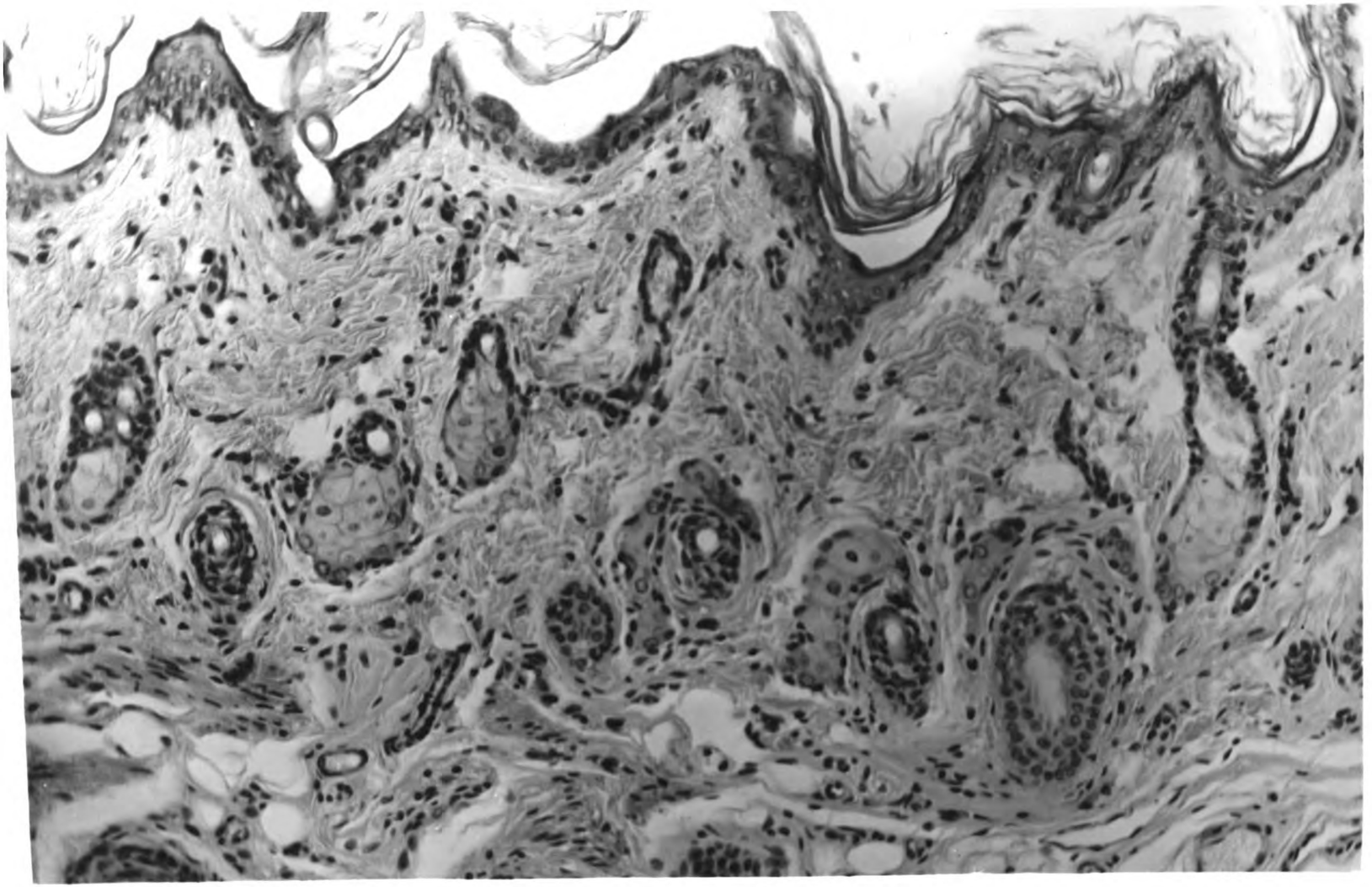

MICHIGAN STATE UNIV. LIBRARIES
31293102521626