

THE STRUCTURAL BASIS OF EQUINE NECK PAIN

By

Nicole Rombach

A DISSERTATION

Submitted to
Michigan State University
in partial fulfillment of the requirements
for the degree of

Large Animal Clinical Sciences –Doctor of Philosophy

2013

ABSTRACT

THE STRUCTURAL BASIS OF EQUINE NECK PAIN

By

Nicole Rombach

To date there are large gaps in the knowledge about the phenomenon of neck pain in the horse. This dissertation, which consists of four studies, aims to elucidate neck pain in the horse based on the concepts of neuromotor control and dynamic stability associated with neck pain in people. The first study describes the anatomy and morphology of two perivertebral muscles, namely, *m. multifidus cervicis* and *m. longus colli*. Both muscles are closely associated with neuromotor control and dynamic stability in people with neck pain. Based on findings in dissection, their anatomy and morphology are similar to those in people. As such, both muscles may play a role in vertebral stability in the neck of the horse. The second study investigated the prevalence and severity of osseous degenerative lesions in the articular process articulations of the equine cervical and cranial thoracic spine. Based on grading of osseous lesions of the articular process articulations in this anatomical region, osseous degeneration is most prevalent in the mid-cervical and cervicothoracic region, and more prevalent in older and larger horses. In the first part of the third study, a technique was developed for repeatability of measurement of the cross-sectional area of *m. multifidus cervicis* and *m. longus colli* in the equine cervical spine, using ultrasound imaging. In the second part of this study, intra- and inter-operator repeatability was determined for measurement of the cross-sectional area of *m. multifidus cervicis* and *m. longus colli* in the equine cervical spine, using the ultrasound imaging technique that was developed in the first part of the study. Evaluation of the size of both muscles is of particular interest in programs of therapeutic rehabilitation, which aim to increase the size of perivertebral muscles to improve

vertebral stability and reduce the recurrence of episodes of neck pain, particularly those associated with osseous degenerative changes in the cervical spine. Results from this study show that US is a repeatable technique for CSA measurement of *m. multifidus cervicis* and *m. longus colli* at specific levels of the equine cervical spine. The fourth study used behavioral responses from horses during a manual examination to develop an ethogram of specific behaviors that may be observed in manual examination of horses with neck pain. Distinct aversive behavioral responses from manual palpatory assessment and mobilization techniques in the cervical spine and cervicothoracic junction of horses were identified in some horses with neck pain. This study also investigated whether manual examination techniques could be applied in the equine cervical spine to identify horses with diagnosed neck pain as compared to control cases. In blinded examination, the manual therapy practitioner who carried out the evaluations was able to correctly place each horse into its respective category of neck pain versus control subject, according to responses from the manual examination techniques that were applied to the subjects.

Together, this series of studies adds to current knowledge in the phenoment of equine neck pain, and widens the base for further investigation into dysfunction of the equine cervical spine.

Copyright by
NICOLE ROMBACH
2013

This dissertation is dedicated to my family and friends who supported me throughout my doctoral program. It is also dedicated to all the horses who formed part of my studies. Debranne Pattillo, thanks to your inspiration I was able to follow my lifelong ambition to make working with horses my career.

ACKNOWLEDGEMENTS

I would like to thank Dr Hilary Clayton for her generous contributions to my doctoral programme. Thank you to Dr Camie Heleski for co-supervision of the programme. Thank you to Dr Raymond Geor for his support during my program. I would also like to thank my committee members, Drs E. Robinson, C. Heleski, E. Carr and A. Pease for their guidance throughout the studies. Thank you to Dr N. Stubbs for her assistance in design and execution of the experiments in the various experiments. Thank you to Dr J. Hauptman for his assistance with the statistical component of my studies. These studies would not have been possible without the help and support of LeeAnn Kaiser, and the students at the McPhail Equine Performance Center. My studies were made possible by generous financial support at Michigan State University from the Mary Anne McPhail Endowment Fund, the Department of Animal Science, the Department of Large Animal Clinical Sciences and the Endowed Research Funds from the College of Veterinary Medicine, and also by the International Society for Equitation Science. My grateful thanks for this financial support.

TABLE OF CONTENTS

LIST OF TABLES	x
LIST OF FIGURES	xii
KEY TO SYMBOLS OR ABBREVIATIONS	xv
INTRODUCTION.....	1
BIBLIOGRAPHY	7
CHAPTER 1: LITERATURE REVIEW	12
1.1 ANATOMY OF THE EQUINE CERVICAL SPINE.....	12
1.1.1 THE HUMAN CERVICAL SPINE	13
1.1.2 THE EQUINE CERVICAL SPINE	15
1.1.3 THE ARTICULAR PROCESS ARTICULATION (APA).....	17
1.1.4 DEEP MUSCULATURE OF THE CERVICAL SPINE: HUMAN STUDIES	22
1.1.5 DEEP MUSCULATURE OF THE CERVICAL SPINE: ANIMALS	25
1.2 BIOMECHANICS OF THE EQUINE CERVICAL SPINE.....	27
1.2.1 MUSCULAR INFLUENCE ON BIOMECHANICS OF THE CERVICAL SPINE ...	27
1.2.2 RANGE OF MOTION OF THE EQUINE CERVICAL SPINE <i>IN VITRO</i>	30
1.2.3 MOTION OF THE CERVICAL SPINE IN THE STANDING HORSE.....	34
1.2.4 MOTION OF THE EQUINE CERVICAL SPINE DURING LOCOMOTION	35
1.2.4.1 NECK MOTION IN WALK	37
1.2.4.2 NECK MOTION IN TROT	39
1.2.4.3 NECK MOTION IN CANTER	40
1.2.4.4 THE EFFECT OF REIN TENSION ON HEAD-NECK POSITION	41
1.3 OSSEOUS LESIONS IN THE CERVICAL SPINE.....	42
1.3.1 LESIONS IN THE HUMAN CERVICAL SPINE	42
1.3.2 OSSEOUS PATHOLOGY IN THE APAS OF THE HUMAN CERVICAL SPINE ..	43
1.3.3 OSSEOUS PATHOLOGY IN THE EQUINE SPINE.....	44
1.3.3.1 OSSEOUS PATHOLOGY IN THE EQUINE THORACOLUMBAR SPINE	44
1.3.3.2 OSSEOUS PATHOLOGY IN THE APAS OF THE EQUINE	
THORACOLUMBAR SPINE	45
1.3.3.3 OSSEOUS PATHOLOGY IN THE EQUINE CERVICAL SPINE	46
1.3.3.4 OSSEOUS PATHOLOGY IN THE APAs OF THE EQUINE CERVICAL	
SPINE	47
1.4 NECK PAIN AND NEUROMOTOR CONTROL	50
1.4.1 PAIN.....	50
1.4.2 NECK PAIN AND NEUROMOTOR CONTROL	52
1.4.2.1 ELECTROMYOGRAPHY FOR ASSESSMENT OF NEUROMOTOR	
CONTROL IN THE CERVICAL SPINE.....	54
1.4.2.2 MAGNETIC RESONANCE IMAGING FOR ASSESSMENT OF	
NEUROMOTOR CONTROL IN THE CERVICAL SPINE	56
1.4.3 STABILIZING MUSCULATURE OF THE CERVICAL SPINE	58

1.4.4 VALIDITY AND RELIABILITY OF ULTRASONOGRAPHY FOR MUSCLE CSA MEASUREMENT IN THE HUMAN CERVICAL SPINE	59
1.4.4.1 VALIDATION AND RELIABILITY OF ULTRASONOGRAPHY FOR MUSCLE CSA MEASUREMENT IN THE PERIVERTEBRAL MUSCULATURE OF THE EQUINE SPINAL COLUMN.....	64
1.4.5 DYNAMIC REHABILITATION FOR EQUINE CERVICAL DYSFUNCTION.....	66
1.5 PAIN AND ITS EFFECT ON BEHAVIOR IN THE HORSE	68
1.5.1 MEASUREMENT OF PAIN IN THE HORSE	69
1.5.2 BEHAVIORAL MANIFESTATIONS OF PAIN IN THE HORSE	72
1.5.2.1 IDENTIFICATION OF SPINAL PAIN IN HORSES.....	77
1.5.2.2 ETHOGRAM USE FOR PAIN EVALUATION IN THE HORSE	80
1.5.2.3 ETHOGRAM USE IN EVALUATION OF PAIN RELATED TO SPINAL DYSFUNCTION IN HORSES.....	83
BIBLIOGRAPHY	85
 CHAPTER 2: GROSS ANATOMY OF THE EQUINE DEEP PERIVERTEBRAL MUSCULATURE, <i>M. MULTIFIDUS CERVICIS</i> AND <i>M. LONGUS COLLI</i>	105
2.1.ABSTRACT	105
2.2 INTRODUCTION.....	106
2.3 MATERIALS AND METHODS	108
2.4 RESULTS.....	111
2.5 DISCUSSION	124
2.6 CONCLUSION	130
BIBLIOGRAPHY	131
 CHAPTER 3: THE PREVALENCE OF OSSEOUS PATHOLOGY IN THE EQUINE CERVICAL AND CRANIAL THORACIC VERTEBRAE	136
3.1 SUMMARY	136
3.1.1 REASONS FOR PERFORMING STUDY	136
3.1.2 OBJECTIVES.....	136
3.1.3 HYPOTHESES.....	136
3.1.4 METHODS.....	136
3.1.5 RESULTS.....	137
3.1.6 CONCLUSIONS AND POTENTIAL RELEVANCE.....	137
3.2 INTRODUCTION.....	137
3.3 METHODS.....	139
3.4 RESULTS.....	141
3.5 DISCUSSION	147
3.6 CONCLUSIONS	152
BIBLIOGRAPHY	154
 CHAPTER 4: THE USE OF ULTRASONOGRAPHY FOR REPEATABLE MEASUREMENT OF MUSCLE CROSS-SECTIONAL AREA OF <i>M. MULTIFIDUS CERVICIS</i> AND <i>M. LONGUS COLLI</i> IN THE EQUINE VERTEBRAL COLUMN.....	159
4.1 SUMMARY	159

4.1.1 REASONS FOR PERFORMING STUDY	159
4.1.2 OBJECTIVE	159
4.1.3 HYPOTHESES	159
4.1.4 METHODS	160
4.1.5 RESULTS	160
4.1.6 CONCLUSIONS AND POTENTIAL RELEVANCE	160
4.2 INTRODUCTION	161
4.3 MATERIALS AND METHODS	165
4.4 RESULTS	171
4.5 DISCUSSION	175
4.6 CONCLUSIONS	182
APPENDICES	183
APPENDIX A: Ultrasound and magnetic resonance images of <i>m. multifidus cervicis</i>	184
APPENDIX B: Ultrasound and magnetic resonance images of <i>m. longus colli</i>	190
APPENDIX C: Results for variability and repeatability of MR and US image acquisition and image digitization across all horses for each spinal level for <i>m. multifidus cervicis</i> and <i>m. longus colli</i> (Study 1)	195
APPENDIX D: Results for variability and repeatability of US image acquisition and image digitization across all horses for each spinal level, within US operators and between US operators for <i>m. multifidus cervicis</i> and <i>m. longus colli</i> (Study 2)	203
BIBLIOGRAPHY	207
 CHAPTER 5: DEVELOPMENT OF AN ETHOGRAM TO ASSIST IN IDENTIFICATION OF EQUINE NECK PAIN DURING MANUAL CLINICAL ASSESSMENT: A PILOT STUDY	213
5.1 ABSTRACT	213
5.2 INTRODUCTION	214
5.3 METHODS	217
5.4 RESULTS	219
5.5 DISCUSSION	222
5.6 LIMITATIONS	224
5.7 CONCLUSIONS	225
APPENDIX	226
BIBLIOGRAPHY	228
 CHAPTER 6: SUMMARY, CONCLUSIONS AND RECOMMENDATIONS FOR FUTURE RESEARCH	232
6.1 SUMMARY	232
6.2 CONCLUSIONS	236
6.3 RECOMMENDATIONS FOR FUTURE RESEARCH	237

LIST OF TABLES

Table 2.1:	Details of the horses used in the study.....	111
Table 4.1:	Mean ICC and CV across all subjects and spinal levels for MR and US CSA measurements of <i>m. multifidus cervicis</i>	171
Table 4.2:	Mean ICC and CV across all subjects and spinal levels for MR and US CSA measurements of <i>m. longus colli</i>	172
Table 4.3:	Mean ICC and CV across all subjects and spinal levels for intra- and inter-operator CSA measurements of <i>m. multifidus cervicis</i>	172
Table 4.4:	Mean ICC and CV across all subjects and spinal levels for intra- and inter-operator CSA measurements of <i>m. longus colli</i>	173
Table C1:	Variability across all horses for magnetic resonance (MR) CSA measurements of <i>m. multifidus cervicis</i> for spinal levels (C3, C4, C5, C6), image acquisition (trial) and image evaluation (repetition).....	195
Table C2:	Repeatability across all horses for magnetic resonance (MR) CSA measurements of <i>m. multifidus cervicis</i> for spinal levels (C3, C4, C5, C6); image acquisition (trial) and image evaluation (repetition).....	196
Table C3:	Variability across all horses for ultrasound (US) CSA measurements of <i>m. multifidus cervicis</i> for spinal levels (C3, C4, C5, C6), image acquisition (trial) and image evaluation (repetition).....	197
Table C4:	Repeatability across all horses for ultrasound (US) CSA measurements of <i>m. multifidus cervicis</i> for spinal levels (C3, C4, C5, C6), image acquisition (trial) and image evaluation (repetition).....	198
Table C5:	Variability across all horses for magnetic resonance (MR) CSA measurements of <i>m. longus colli</i> for spinal levels (C2, C3, C4, C5), image acquisition (trial) and image evaluation (repetition).....	199
Table C6:	Repeatability across all horses for magnetic resonance (MR) CSA measurements of <i>m. longus colli</i> for spinal levels (C2, C3, C4, C5), image acquisition (trial) and image evaluation (repetition).....	200

Table C7:	Variability across all horses for ultrasound (US) CSA measurements of <i>m. longus colli</i> for spinal levels (C2, C3, C4, C5), image acquisition (trial) and image evaluation (repetition).....	201
Table C8:	Repeatability across all horses for ultrasound (US) measurements of <i>m. longus colli</i> for spinal levels (C2, C3, C4, C5), image acquisition (trial) and image evaluation (repetition).....	202
Table D1:	Variability across all horses for ultrasound (US) CSA measurements of <i>m. multifidus cervicis</i> for spinal levels (C3, C4, C5, C6), within operators (operator), image acquisition (trial), between operators (observer) and image evaluation (repetition).....	203
Table D2:	Repeatability across all horses for ultrasound (US) CSA measurements of <i>m. multifidus cervicis</i> for spinal levels (C3, C4, C5, C6), within operators (operator), image acquisition (trial); between operators (observer) and image evaluation (repetition).....	204
Table D3:	Variability across all horses for ultrasound (US) CSA measurements of <i>m. longus colli</i> for spinal levels (C2, C3, C4, C5), within operators (operator), image acquisition (trial), between operators (observer) and repeated image evaluation (repetition).....	205
Table D4:	Repeatability across all horses for ultrasound (US) CSA measurements of <i>m. longus colli</i> for spinal levels (C2, C3, C4, C5), within operators (operator), image acquisition (trial); between operators (observer) and image evaluation (repetition).....	206

LIST OF FIGURES

Figure 1.1:	Image of the 6 th cervical vertebra showing rotations about orthogonal axes in the equine cervical spinal column.....	31
Figure 2.1:	Lateral aspect of cervical spine and cervicothoracic junction demonstrating <i>m. multifidus cervicis</i> and <i>m. longus colli</i> (cranial to T1)	113
Figure 2.2:	Dorsolateral oblique view of lateral layer of <i>m. multifidus cervicis</i> indicating cranial and caudal (superficial and deep fascicle) attachments.....	114
Figure 2.3:	Fibrous band (white arrow) along length vertebral body lamina (between yellow markers) for attachment of <i>m. multifidus cervicis</i> (white markers).....	114
Figure 2.4:	Dorsolateral oblique view of medial layer of <i>m. multifidus cervicis</i> indicating cranial and caudal (short and long fascicle) attachments	115
Figure 2.5:	Dorsolateral oblique view of deep layer of <i>m. multifidus cervicis</i> indicating cranial and caudal fascicle attachments.....	116
Figure 2.6	Ventrolateral oblique view of lateral layer of <i>m. longus colli</i> indicating cranial and caudal (superficial and deep fascicle) attachments.....	118
Figure 2.7:	Ventrolateral oblique view of medial layer of <i>m. longus colli</i> indicating cranial and caudal (short and long fascicle) attachments.....	119
Figure 2.8:	Fibrous band (white arrow) across transverse process (between blue markers) for attachment of <i>m. longus colli</i> (yellow marker). <i>M. intertransversarius</i> (green marker) attaches ventrally over the same fibrous band.....	120
Figure 2.9:	Ventrolateral oblique view of deep layer of <i>m. longus colli</i> indicating cranial and caudal fascicle attachments.....	121
Figure 2.10:	Lateral aspect of <i>m. longus colli</i> in the equine spine detailing the caudal aspect from C6 – T5/T6.....	123
Figure 3.1:	Grading of osseous pathology of the articular processes according to size of degenerative changes.....	140
Figure 3.2:	Prevalence of the mean grades of osseous lesions recorded across the four articular processes (left and right, cranial and caudal) of each vertebra from the first cervical (C1) to the seventh thoracic (T7) (n = 53 horses).....	143

Figure 3.3:	Overall severity and differences in distribution of osseous lesions from the first cervical (C1) to seventh thoracic (T7) vertebra (n=53horses).....	144
Figure 3.4:	Interactions of mean pathological grade between age and size across all subjects (n=53).....	146
Figure 3.5:	Prevalence of mean pathological grade) in young and old horses from C1 to T7 across all subjects (n=53)	146
Figure 4.1:	Position of a subject in lateral recumbency in the MR machine for MR image acquisition of the cervical spine.....	168
Figure 4.2:	Mean cross-sectional area (CSA) expressed in cm ² of <i>m. multifidus cervicis</i> at four spinal levels across all subjects and as measured by two different US operators.....	174
Figure 4.3:	Mean cross-sectional area (CSA) expressed in cm ² of <i>m. longus colli</i> at four spinal levels across all subjects and as measured by two different US operators.....	174
Figure A1:	Ultrasound (US) images of <i>m. multifidus cervicis</i> at C3.....	184
Figure A2:	Ultrasound (US) images of <i>m. multifidus cervicis</i> at C4.....	184
Figure A3:	Ultrasound (US) images of <i>m. multifidus cervicis</i> at C5.....	185
Figure A4:	Ultrasound (US) images of <i>m. multifidus cervicis</i> at C6.....	185
Figure A5:	Magnetic resonance (MR) images of <i>m. multifidus cervicis</i> at C3.....	186
Figure A6:	Magnetic resonance (MR) images of <i>m. multifidus cervicis</i> at C4.....	187
Figure A7:	Magnetic resonance (MR) images of <i>m. multifidus cervicis</i> at C5.....	188
Figure A8:	Magnetic resonance (MR) images of <i>m. multifidus cervicis</i> at C6.....	189
Figure B1:	Ultrasound (US) images of <i>m. longus colli</i> at C2.....	190
Figure B2:	Ultrasound (US) images of <i>m. longus colli</i> at C3.....	190
Figure B3:	Ultrasound (US) images of <i>m. longus colli</i> at C4.....	191
Figure B4:	Ultrasound (US) images of <i>m. longus colli</i> at C5.....	191
Figure B5:	Magnetic resonance (MR) images of <i>m. longus colli</i> at C2.....	192

Figure B6:	Magnetic resonance (MR) images of <i>m. longus colli</i> at C3.....	193
Figure B7:	Magnetic resonance (MR) images of <i>m. longus colli</i> at C4.....	193
Figure B8:	Magnetic resonance (MR) images of <i>m. longus colli</i> at C5.....	194
Figure 5.1:	Agreement between independent observers for identification of withdrawal responses during manual assessment of the cervical spine and cervicothoracic junction in control subjects and horses with neck pain.....	220
Figure 5.2:	Agreement between independent observers for identification of anxiety responses during manual assessment of the cervical spine and the cervicothoracic junction in control subjects and horses with neck pain.....	221
Figure 5.3:	Categorization of neck pain versus control subject by two independent examiners based on manual palpatory assessment (NR) and videographic assessment of manual palpatory assessment (CH) of the cervical spine and the cervicothoracic junction.....	222
Figure E1:	Ethogram of behaviors identified during manual clinical assessment of the equine cervical and cranial thoracic region	227

KEY TO SYMBOLS OR ABBREVIATIONS

ANOVA	Analysis of variance
AP	Articular process
APA	Articular process articulation
AVMA	American Veterinary Medical Association
CCFT	Craniocervical flexion test
CMPS	Composite measures pain scale
CSA	Cross-sectional area
CSM	Cervical stenotic myelopathy
CT	Computed tomography
CV	Coefficient of variation
EMG	Electromyography
FG	Fast glycolytic
HNPS	Head and neck position sense
ICC	Intraclass correlation coefficient
LC	Longus colli
LCa	Longus capitis
MNT	Mechanical nociceptive threshold
MR	Magnetic resonance imaging
MR	Magnetic resonance imaging
Mul	Multifidus
MUPA	Motor unit action potential
MVC	Maximal voluntary contraction

NRS	Numerical rating scale
NSAID	Non-steroidal anti-inflammatory drug
OA	Osteoarthritis
PA	Pressure algometry
RMS	Root mean square
SCM	Stenotic cervical myelopathy
SDD	Smallest detectable difference
SEM	Standard error of the mean
SID	Sacroiliac joint disease
SO	Slow oxidative
SpC	Semispinalis capitis
US	Ultrasound imaging

INTRODUCTION

There can be no doubt that spinal problems and related pain limit a horse's athletic performance (Murray *et al.*, 2006). To date, equine spinal research has focused on the thoracolumbar and lumbopelvic regions (Jeffcott, 1980; Girodroux *et al.*, 2009; Meehan *et al.*, 2009; Cousty *et al.*, 2010; Stubbs *et al.*, 2010; Cousty *et al.*, 2011), and little is known about the prevalence and distribution of lesions in the cervical spine. Furthermore, studies of diagnostic techniques and rehabilitative treatments for cervical pain or dysfunction are scarce. A major aim of this series of studies was to gain anatomical information on the supporting musculature of the equine cervical spine, to investigate prevalence and distribution of osseous degenerative lesions in articular process articulations of the equine cervical and cranial thoracic spine, to develop a technique for objective measurement of the cross-sectional area of the supporting musculature of the equine cervical spine and to identify potential behavioral indicators in horses with neck pain. With this knowledge, a multi-disciplinary approach to diagnosis of neck pain can be possible. This is a necessary first step towards rehabilitative treatment of horses with neck pain.

Human neck pain is a debilitating disorder with a direct impact on individual physical and psychological health (Ariëns *et al.*, 2002; Hansson *et al.*, 2006) as well as society and the economy as a whole (Borghouts *et al.*, 1999; Collins *et al.*, 2005). Research into disorders of the human cervical spine has shown that there is a high prevalence of neck pain (up to 43%) in both the general and working populations and in both males and females (Croft *et al.*, 2001; Guez *et al.*, 2002; Cotê *et al.*, 2004; Fejer *et al.*, 2006; Hogg-Johnson *et al.*, 2008). The etiology of neck

injury and/or pain primarily includes whiplash associated disorders (WAD) (Atherton *et al.*, 2006; Carroll *et al.*, 2008), chronic APA joint pain (Manchikanti *et al.*, 2004) and degeneration of the intervertebral disc (Bogduk and Aprill, 1995). Recurrence of episodes of neck pain is common (Enthoven *et al.*, 2004; Carroll *et al.*, 2008) and therapeutic approaches to prevent recurrence have been studied, with a specific emphasis on addressing the concept of efficient neuromotor control of the deep paraspinal stabilizing musculature as a preventative measure for recurrence of episodes of neck pain (Jull and Richardson, 2000; Falla *et al.*, 2007).

Clinical evidence in human neck pain studies embraces the key concept of the negative effect of cervical segmental dysfunction on somatosensory function, including joint position sense (Treleaven *et al.*, 2003) and cervical muscle function (Falla *et al.*, 2004). A generic feature of neck pain is that it changes muscle behavior (O’Leary *et al.*, 2009) and properties (Uhlir *et al.*, 1995), and that it has an adverse effect on neuromotor control of the affected spinal segment. The deep stabilizing muscles of the neck, *m. multifidus cervicis* and *m. longus colli*, play a pivotal role in stabilization and movement of the cervical intervertebral joints. These muscles are known to be inactivated by neural inhibition in humans with neck pain, leading to measureable muscle atrophy (O’Leary *et al.*, 2009). To date, the literature does not offer detailed descriptions of the anatomy and morphology of *m. multifidus* and *m. longus colli* in the equine cervical and cranial thoracic spine (*m. longus colli* has its most caudal attachment in the thoracic spine at T5-T6). One of the studies in this series was designed to describe the morphology and architecture of these two perivertebral muscles in equine cervical spine, as a base for further investigation into their effect on stability and their potential relationship to neck pain.

The majority of the published studies on equine spinal pain have focused on injury, pain and pathology of the thoracolumbar spine, with specific emphasis on patho-anatomical diagnosis in the thoracolumbar region in relation to osseous (Jeffcott, 1980; Haussler *et al.*, 1999; Stubbs *et al.*, 2010) and soft-tissue lesions (Denoix and Dyson, 2003). In the equine cervical spine, studies of osseous lesions have focused mainly on cervical vertebral compressive myelopathy (van Biervliet *et al.*, 2006; Levine *et al.*, 2007), although arthropathy of the cervical APAs has been cited in the etiology of reduced performance in the horse (Ricardi and Dyson, 1993). Clinical findings associated with cervical APA arthropathies have been reported to cause forelimb lameness (Ricardi and Dyson, 1993), stiffness in movement, neck muscle atrophy and neck pain (Beck *et al.*, 2002; Dyson, 2003). Another study in this dissertation focused on the evaluation and description of the prevalence and distribution of osseous lesions in the APAs of the equine cervical and cranial thoracic spine (to the level of T5-T6, the most caudal attachment of *m. longus colli*, as this has not been investigated).

Measurement of cross-sectional area (CSA) and left-right symmetry of *m. multifidus cervicis* and *m. longus colli* via ultrasonography (US) is a validated technique that is widely used in clinical and research practices in humans (Kristjansson, 2004; Whittaker *et al.*, 2007; Javanshir *et al.*, 2011). In patients with chronic neck pain, the US-measured CSA of *m. multifidus cervicis* is generally smaller than in non-painful controls (Fernández-de-las-Peñas *et al.*, 2008). US imaging techniques have also shown altered size of *m. longus colli* in patients with chronic neck pain (Javanshir *et al.*, 2011). Similarly, low back pain in people has been linked with atrophy of the deep spinal stabilizer *m. multifidus* in the lumbar region (Kalichman *et al.*, 2010) and this muscle

appears to remain dysfunctional even after resolution of pain through medical intervention (Hides et al., 1996). In the horse, US has been validated as a reliable and repeatable tool for CSA measurement of *m. multifidus* in the thoracolumbar spine (Stubbs, 2011), and according to US CSA measurements it has been shown that ipsilateral atrophy (a reduction of CSA) of *m. multifidus* occurs at the same thoracolumbar levels as osseous pathology (Stubbs *et al.*, 2010). To date there is no validated technique for evaluating or measuring the CSA of the deep stabilizing musculature in the cervical spine of the horse. The third study in this dissertation validated the technique of US for CSA measurement of *m. multifidus* and *m. longus colli* in the equine cervical spine, and to determine intra-operator and inter-operator reliability and repeatability of CSA measurement of *m. multifidus* and *m. longus colli* in the cervical spine of the live, standing horse.

Pain, in its purest form, can be described as a sensory reaction to tissue damage (Loeser and Melzack, 1999). In humans, manual palpation through functional range of motion testing and passive mobilization techniques (Maitland, 1977) is useful for identifying focal points of neck pain that may be indicative of underlying pathology (Humphreys *et al.*, 2004). Clinically it has been reported that palpatory assessment of range of motion of each segment of the equine cervical spine can detect restrictions or hypermobility that may be related to underlying lesions, such as osseous malformations, osteoarthritis or ankylosis (Haussler, 2009). Such palpatory findings may be subjectively correlated to behavioral reactions associated with orthopedic pain (Bussi eres *et al.*, 2008). Pain in horses has been measured subjectively through identification of behavioral manifestations, and the use of behavioral indicators to identify the presence of pain in the horse is advocated as an adjunct to clinical diagnostics as responses such as aggression to

palpation, alterations in posture and movement may be related to the presence of pain (Ashley *et al.*, 2005). One of the studies in this dissertation was designed to test whether manual palpation techniques could be used blindly to identify horses with diagnosed neck pain. In order to better understand behavioral expressions in animals, ethograms are used to define specific behaviors. An ethogram is as list or inventory of behavioral elements specific to a species, with emphasis on specific behaviors observed under a certain condition (McDonnell and Haviland, 1995). The design of an ethogram to describe specific equine behavior related to dysfunction and/or pain in the cervical spine is warranted, based on previous studies of equine behavior under conditions of discomfort and/or pain (Price *et al.*, 2003) and the increased awareness in the field of veterinary medicine that the understanding of equine behavior is an integral component of the clinical examination (Haupt and Mills, 2006). The fourth study in this dissertation was designed to develop an ethogram of specific behavioral manifestations for potential use during manual clinical evaluation of horses with suspected neck pain.

As cervical spinal dysfunction is known to have a deleterious effect on athletic performance, it is vital that we gain a better understanding into the prevalence and therapeutic rehabilitative treatment of lesions in the equine cervical spine. As a prelude, it is essential that the structural basis related to equine neck pain is more clearly understood.

This dissertation is divided into six chapters. Chapter 1 provides a review of the current literature as relevant to the topics covered in this series of studies. Chapter 2 is a descriptive post-mortem study of the architecture and morphology of *m. multifidus* and *m. longus colli* in the equine

cervical spine. Chapter 3 describes the prevalence and severity of osseous lesions in the equine cervical and cranial thoracic spine, under the hypothesis that osseous lesions are more commonly found in the cervicothoracic junction, and that lesions are more prevalent and more severe in older and larger horses. Chapter 4 is divided into two studies. The objective of the first study was to develop a technique using ultrasound imaging as a repeatable and reliable method to measure the CSA of *m. multifidus* and *m. longus colli* in the equine cervical spine, by comparing US measurements against CSA measurements of both muscles using the ‘gold standard’ of magnetic resonance imaging (MR). I hypothesized that image acquisition is more repeatable in the mid-cervical spine (C3-C5) than in the cranial (C2-C3) or caudal (C6-C7) cervical spine. The second study was carried out in live, standing horses with the hypothesis that measurement of the CSA of *m. multifidus cervicis* and *m. longus colli* with US is a repeatable technique within US operators between US operators. I also hypothesized that image acquisition is more repeatable in the mid-cervical spine (C3-C5) than in the cranial (C2-C3) or caudal (C6-C7) cervical spine. A pilot study into behavioral manifestations that can be observed during manual palpation in horses with neck pain is described in Chapter 5. I hypothesized that that manual examination techniques can identify horses with neck pain, and that horses with diagnosed lesions in the cervical spine display specific behaviors during manual examination for neck pain. In addition, the specific behaviors observed during manual examination were used to design an ethogram of equine behaviors. Chapter 6 offers a conclusion of the series of studies, with suggestions for future research based on the results from the series of studies.

BIBLIOGRAPHY

BIBLIOGRAPHY

- Ashley, F. H., Waterman-Pearson, A. E., Whay, H. R. (2005) Behavioral assessment of pain in horses and donkeys: application to clinical practice and future studies. *Equine Veterinary Journal*, 37(6), 565-575.
- Atherton, K., Wiles, N. J., Lecky, F. E., *et al.* (2006) Predictors of persistent neck pain after whiplash injury. *Emergency Medical Journal*, 23, 195-201.
- Beck, C., Middleton, D., Maclean, A., *et al.* (2002) Osteochondrosis of the second vertebra of a horse. *Equine Veterinary Journal*, 34, 210–212.
- Bogduk, N., Aprill, C. (1995) On the nature of neck pain, discography and cervical zygapophysial blocks. *Pain*, 54(2), 213-217.
- Borghouts, J. A. J., Koes, B. W., Vondeling, H., *et al.* (1999) Cost of illness of neck pain in The Netherlands in 1996. *Pain*, 80(3), 629-636.
- Bussi res, G., Jacques, C., Lainay, O., *et al.* (2008) Development of an orthopaedic pain scale in horses. *Research in Veterinary Science*, 85, 294-306.
- Carroll, L. J., Hogg-Johnson, S., van der Velde, G., *et al.* (2008) course and prognostic factors for neck pain in the general population: results of the bone and joint decade 2000 –2010 task force on neck pain and its associated disorders. *European Spine Journal*, 17 (Suppl. 1), 75-82.
- Collins, J. J., Baase, C. M., Sharda, C. E., *et al.* (2005) The assessment of chronic health conditions on work performance, absence, and total economic impact for employers. *Journal of Occupational & Environmental Medicine*, 47(6), 547-557.
- Cousty, M., Retureau, C., Tricaud, C., *et al.* (2010) Location of radiological lesions of the thoracolumbar column in French trotters with and without signs of back pain. *Veterinary Record*, 166, 41-45.
- Cousty, M., Firidolfi, C., Geffroy, *et al.* (2011) Comparison of medial and lateral ultrasound-guided approaches for periarticular injection of the thoracolumbar intervertebral facet joints in horses. *Veterinary Surgery*, 40(4), 494-499.
- Croft, P. R., Lewis, M., Papageorgiou, A. C., *et al.* (2001) Risk factors for neck pain: a longitudinal study in the general population. *Pain*, 93, (3), 317-325.
- Denoix, J.-M., Dyson, S. (2003) The thoracolumbar spine. In: *Diagnosis and management of lameness in the horse*, first edition. Eds: Ross, M. W. and Dyson, S. J., W.B. Saunders, St.Louis, 509-521.

Dyson, S. (2002) Poor performance: cannot or will not? In: Conference on Equine Sports Medicine and Science – the Elite Dressage- and Three-Day Event Horse, October 2002, Saumur, France. Ed. By Dr A. Lindner. Lensing Druck: Dortmund, 43-54.

Dyson, S. J. (2003) The cervical spine and soft tissues of the neck. In: *Diagnosis and management of lameness in the horse*, first edition. Eds: Ross, M. W. and Dyson, S. J., W.B. Saunders, St. Louis, 523-531.

Enthoven, P., Skargren, E., Öberg, B. (2004) Clinical Course in Patients Seeking Primary Care for Back or Neck Pain: A Prospective 5-Year Follow-Up of Outcome and Health Care Consumption with Subgroup Analysis. *Spine*, 29(21), 2458-2465.

Falla, D.L., Jull, G. A., Hodges, P. W. (2004) Patients With Neck Pain Demonstrate Reduced Electromyographic Activity of the Deep Cervical Flexor Muscles During Performance of the Craniocervical Flexion Test. *Spine*, 29(19), 2108-2114.

Falla, D., Jull, G., Russell, T., *et al.* (2007) Effect of neck exercise on sitting posture in patients with chronic neck pain. *Physical Therapy*, 87, 408-417.

Girodroux, M., Dyson, S., Murray, R. (2009) Osteoarthritis of the thoracolumbar synovial intervertebral articulations: Clinical and radiographic features in 77 horses with poor performance and back pain. *Equine Veterinary Journal*, 41, 130-138.

Guez, M., Hildingsson, C., Nilsson, M., Toolanen, G. (2002) The prevalence of neck pain. *Acta Orthopaedica*, 73(4), 455-459.

Hansson, M., Bostrom, C., Harms-Ringdahl, K. (2006) Sickness absence and sickness attendance – What people with neck or back pain think. *Social Science & Medicine*, 62(9), 2183-2195.

Haussler, K. K., (2009) Review of manual therapy techniques in equine practice. *Journal of Equine Veterinary Science*, 29, 849-869.

Haussler, K. K., Stover, S. M., Willits, N. H. (1999) Pathology of the lumbosacral spine and pelvis in Thoroughbred racehorses. *American Journal of Veterinary Research*, 60, 143-153.

Hides, J., Richardson, C. and Jull, G. (1996) Multifidus muscle recovery is not automatic after resolution of acute, first-episode low back pain. *Spine*, 21, 2763 - 2769.

Houpt, K. A., Mills, D.S. (2006) Science: overviews. Why horse behavior is important to the equine clinician. *Equine Veterinary Journal*, 38(5), 386-387.

- Humphreys, B. K., Delahaye, M., Peterson, C. K. (2004) An investigation into the validity of cervical spine motion palpation using subjects with congenital block vertebrae as a 'gold standard'. *BMC Musculoskeletal Disorders*, 15(5)19.
- Javanshir, K., Mohseni-Bandpei, M. A., Rezasoltani, A., *et al.* (2011) Ultrasonography of longus colli muscle: A reliability study on healthy patients and patients with chronic neck pain. *Journal of Bodywork and Movement Therapies*, 15(1), 50-56.
- Jeffcott, L. B. (1980) Disorders of the thoracolumbar spine of the horse- a survey of 443 cases. *Equine Veterinary Journal*, 12, 197-210.
- Kristjansson, E. (2004) Reliability of ultrasonography for the cervical multifidus muscle in asymptomatic and symptomatic subjects. *Manual Therapy*, 9, 83-88.
- Levine, J. M., Adam, E., Mackay J. *et al.* (2007) Confirmed and presumptive cervical vertebral compressive myelopathy in older horses: a retrospective study (1994-2004). *Journal of Veterinary Internal Medicine*, 21, 812-819.
- Loeser, J. D., Melzack, R. (1999) Pain: an overview. *The Lancet*, 353(9164), 1607-1609.
- Maitland, G. D. (1977) *Peripheral Manipulation*, 2nd edition. Butterworths, London, 86-92.
- Manchikanti, L., Boswell, M. V., Singh, V., *et al.* (2004) Prevalance of facet joint pain in chronic spinal pain of cervical, thoracic and lumbar regions. *BMC Muskuloskeletal Disorders*, 5(15), 1-7.
- McDonnell, S. M., Haviland, J. C. S. (1995) Agonistic ethogram of the equid bachelor band. *Applied Animal Behavior Science*, 43, 147-188.
- Meehan, L., Dyson, S., Murray, R. (2009) Radiographic and scintigraphic evaluation of spondylosis in the equine thoracolumbar spine: A retrospective study. *Equine Veterinary Journal*, 41(8), 800-807.
- Murray, R. C., Dyson, S. J., Tranquille, C., *et al.* (2006) Association of type of sport and performance level with anatomical site of orthopaedic injury diagnosis. *Equine Veterinary Journal* (Supplement), 36, 411 – 416.
- Price, J., Seago, C., Welsh, E. M., *et al.* (2003) Preliminary evaluation of a behavior-based system for assessment of post-operative pain in horses following arthroscopic surgery. *Veterinary Anasthaesia and Analgesia*, 30(3), 124-137.
- Ricardi, G., Dyson, S. J. (1993) Forelimb lameness associated with radiographic abnormalities of the cervical vertebrae. *Equine Veterinary Journal*, 25, 422-426.
- Stubbs, N. C., Riggs, C. M., Hodges, P. W., *et al.* (2010) Osseous spinal pathology and epaxial muscle ultrasonography in Thoroughbred racehorses. *Equine Veterinary Journal*, 42(Suppl. 38), 654-661.

Stubbs, N. C. Kaiser, L. J., Hauptman, J., *et al.* (2011). Dynamic mobilization exercises increase cross sectional area of multifidus. *Equine Veterinary Journal*, 43(5), 522-529.

Treleaven, J., Jull, G., LowChoy, N. (2006) The relationship of cervical joint position error to balance and eye movement disturbances in persistent whiplash. *Manual Therapy*, 11(2), 99-106.

Uhlig, Y., Weber, B. R., Grob, D., Muntener, M. (1995) Fiber composition and fiber transformations in neck muscles of patients with dysfunction of the cervical spine. *Journal of Orthopaedic Research*, 13(2), 200-249.

Van Biervliet, J., Mayhew, J., de Lanhunta, A. (2006) Cervical vertebral compressive myelopathy: Diagnosis. *Clinical Techniques in Equine Practice*, 5, 54-59.

Whittaker, J. L., Elliott, J. M., Cook, K., *et al.* (2007) Rehabilitative ultrasound imaging: understanding the technology and its applications. *J. Orthop. Sports Phys.* 37, 434-449.

CHAPTER 1: LITERATURE REVIEW

1.1 ANATOMY OF THE EQUINE CERVICAL SPINE

All mammalian species, with the exception of manatees and sloths, possess seven cervical vertebrae, in contrast to birds, reptiles and amphibians where considerable variations in numbers can be observed (Galis, 1999; Solounias, 1999; Narita and Kuratani, 2005). In a radiographic study of nine vertebrate species including man, the orientation of the cervical spine was found to be vertical in all the species included in the study, except for the frog and lizard (Vidal *et al.*, 1986). In humans, the cervical vertebrae are arranged in a vertical column, to balance the weight of the head above the trunk, whereas in other species the head and neck project rostrally from the body (Richmond *et al.*, 2001). In people, the cervical spine has a natural lordotic curvature (Huelke and Nusholtz, 1986) and it is orientated in a vertical direction above the thoracic spine (Roussouly and Pinheiro-Franco, 2011). At rest, the cervicothoracic junction in humans is held in a neutral position between maximal flexion and extension whilst in quadrupeds this junction is held in a more extended position (Graf *et al.*, 1995).

The first two vertebrae (atlas and axis) are both unique in their morphological characteristics, allowing for specific movements and support of the head. Unlike the third to seventh cervical vertebrae, the atlas does not have a body, and the wings are modified transverse processes. It has a concave dorsal arch (the dorsal tubercle) and a thicker, narrower ventral arch that serves as an attachment for the deep neck flexor, *m. longus colli*. Its articulation with the occiput (atlanto-occipital joint) can be described primarily as a hinge joint where maximal flexion and extension occur, though coupled motion with limited lateral bending and rotation does occur (Penning, 1978). The axis also has an atypical shape, with a dens or odontoid process that projects

cranially, and the axis has a large and long dorsal spinous process. The junction between the atlas and axis (atlanto-axial joint) is a pivot joint (Getty, 1975). A comparison between the morphology of the cervical vertebrae in the horse, ox and dog (Levine *et al.*, 2007) shows that there are some anatomical variations between the three species in the morphology of the atlas and axis, but that the remaining vertebrae have a similar architecture. Morphological design of the vertebral bodies, in particular the shape and orientation of the APAs of the cervical spine of bipeds and quadrupeds, allow or restrict range of motion in the different planes, where movement occurs through functional neuromotor control of the perivertebral musculature (Graf *et al.*, 1995).

1.1.1 THE HUMAN CERVICAL SPINE

With 37 joints (Bland and Boushey, 1990), the human cervical spine is highly mobile. The column is designed to provide stability in mechanical loading and movement (Jaumard *et al.*, 2011), and the morphology of the vertebrae and the attached ligamentous structures contribute to the anti-gravitational stability of the cervical spine (Graf *et al.*, 1995), with the morphology of the individual vertebral bodies allowing for a vertically erect position during bipedal locomotion (Roussouly and Pinheiro-Franco, 2011). The neck supports and stabilizes the sensory and vestibular systems and allows three-dimensional movement through a highly refined interplay between muscular attachments and the morphology of the cervical vertebrae (Bogduk and Mercer, 2000).

The human cervical spine consists of seven cervical vertebrae and has a lordotic shape in the sagittal plane between C1 and C7. The cervical articular process articulations (APAs) are diarthrodial joints, with one pair of articular processes (APs) connecting the inferior and superior APs of two neighbouring vertebrae (Kirpalani and Mitra, 2008). These APAs play a key role in both guiding and limiting motion throughout the cervical spine (Jaumard *et al.*, 2011). The atlas (C1) and axis (C2) have atlanto-occipital (C0-C1) and atlantoaxial (C1-C2) connections through joints and soft-tissue structures, but there are no intervertebral discs at these spinal levels (Penning, 1978). Except for the atlanto-axial joint, an intervertebral disc is present between each pair of vertebrae in the human cervical spine. Mercer and Bogduk (1999) carried out microdissections of 59 cervical intervertebral discs from adult human cadavers (n=12) for a specific morphological description. Through evaluation of transverse sections of the discs, they concluded that the *anulus fibrosus*, made up of collagen, is crescent-shaped around the *nucleus pulposus* (versus the fibrous ring observed in lumbar intervertebral discs) and that it appears to be thickest anteriorly, tapering posteriorly towards the uncinat process. A dissection of 15 fresh human cervical spines (Johnson *et al.*, 1975) revealed that the *anulus fibrosus*, capsular ligament and posterior longitudinal ligament were thought to provide stability to the cervical spine, whilst smaller ligaments (intertransverse, anterior longitudinal ligament, interspinous and supraspinous ligaments and *ligamentum flavum*) were thought to have a function controlling specific movement of the cervical spine. Later it was noted that the anterior longitudinal ligament attaches to the vertebral bodies, whilst the posterior longitudinal ligament attaches directly from the posterior vertebral body to the intervertebral disc (Bland and Boushey, 1990) – both of these structures (which are thicker and broader in the cervical than in the thoracic or lumbar regions) have been implicated in support of the cervical spine. A more recent study (Takeshita *et al.*,

2004) cited the nuchal ligament as another key anatomical structure that resists cervical flexion, based on measurements of load and displacement in flexion testing of cadaveric human cervical spines (n=12).

1.1.2 THE EQUINE CERVICAL SPINE

Like humans, the horse has seven cervical vertebrae. The first two vertebrae (atlas and axis) are atypical in shape compared to the remaining vertebrae: the atlas has two large wings and a dorsal tubercle representing the remnant of a dorsal spinous process, and the axis has a *dens* that projects into the vertebral foramen of the atlas (Levine *et al.*, 2007) and forms a pivot joint with the caudal articulation of the atlas. The third through to seventh cervical vertebrae are more uniform in appearance with large oval-shaped articular processes and roughened surfaces that allow muscular and ligamentous attachment (Getty, 1975). The morphology of the vertebral bodies remains the same from C3 to C7, but the shape and size of the transverse processes is different in C5, C6 and C7 (Getty, 1975; Whitwell and Dyson, 1987). The vertebrae are articulated in the form of an S-shaped curvature with a kyphotic shape in the cranial portion and a lordotic shape in the caudal portion of the neck (Whitwell and Dyson, 1987). Adjacent vertebrae articulate at the intercentral joint and a single pair of articular APAs between the vertebrae, connecting the caudal articular process of the more cranial vertebra with the cranial articular process of the more caudal vertebra (Whitwell and Dyson, 1987).

To date there have been few studies in the horse that have investigated the morphometry and functional anatomy of the musculature of the cervical spine. Human research is more evolved as (the phenomena of) dysfunction and pain in the cervical spine have been widely recognized and described, and there is an active focus on biomechanical modelling of the cervical spine in an

attempt to better understand the role of the paravertebral musculature on postural stability of the cervical spine under static and dynamic conditions. The head and neck comprise approximately 10% of the total body mass of the horse (Buchner *et al.*, 1997). Using segmental kinematics, Dunbar *et al.* (2008) demonstrated that the equine neck functions in association with the head and the trunk to provide stability for the cephalic organs of proprioception and maintain spatial orientation in locomotion, facilitated by specific mobility in the cervical joints.

There are few detailed descriptions of the musculature of the equine cervical spine, with even less information about the deep perivertebral muscles. Gellman *et al.* (2002) carried out a detailed analysis of *m. semispinalis capitis* and *m. splenius* and described the muscular architecture as related to biomechanics of locomotion and position of the head and neck as related to visual and vestibular function. Fiber length, attachments, innervations and tendinous inscriptions were described, and histochemical analysis was carried out to define fiber type properties for each muscle. Based on the morphological description and predominance of type I or type II fibers in each muscle or compartment thereof, muscle function was described as either providing passive support or generating forces that were integral to the locomotor cycle or that controlled the position of the head and neck. The dorsal portion of *m. semispinalis capitis* had a higher concentration of type I fibers, which is consistent with the provision of support and stability, whilst the ventral portion had a higher concentration of type II fibers that can provide the force to elevate the head and neck. *M. splenius* had a majority of type I fibers, suggesting a function in postural stability and support in opposition to inertial and gravitation forces during locomotion.

1.1.3 THE ARTICULAR PROCESS ARTICULATION (APA)

The APA is widely cited to be a key structure in dysfunction of the cervical spine due to injury or degeneration. In healthy function the morphology of the APAs facilitates and directs motion (Jaumard *et al.*, 2011). In humans and animal species, the cervical APA is a diarthrodial joint with articular cartilage on the opposing joint surfaces and enveloped by a joint capsule that is lined with a synovial membrane and surrounded by a fibrous joint capsule (Webb, 2003; Kirpalani and Mitra, 2008; Claridge *et al.*, 2010). Human APA capsules contain mechanoreceptive and nociceptive nerve endings, suggesting that the APAs play a role in proprioception and pain of the cervical spine (McLain, 1994). A review by Kirpalani (2008) on cervical joint dysfunction examined 45 journal articles and one textbook reference for research into the pathophysiology of APAs, including the prevalence, clinical features, diagnostic workup and treatment of APA pain. It was concluded that although OA in the cervical APA is commonly cited to be a key factor in axial neck pain, there is little evidence describing beneficial treatment for APA dysfunction.

Jaumard *et al.* (2011) provided a detailed review of the extensive literature relating to the anatomical, biomechanical and physiological aspects of the APA of the human cervical spine, highlighting the widely-accepted opinion that this structure is implicated in cervical dysfunction and pain. In people, cervical APA joint pain is most often linked to whiplash-associated disorder (WAD), in which excessive strain or stretch to the APA capsule is thought to be linked to both acute and chronic pain (Panjabi *et al.*, 1998; Krafft *et al.*, 2000; Lee *et al.*, 2004; Quinn and Winkelstein, 2007). Pain generated in the APA is also thought to be related to tension created on

the APA capsule by the perivertebral musculature (Anderson *et al*, 2005). Winkelstein *et al* (2001) investigated muscular insertions on the APA capsule in 21 cadaveric cervical joints (ten joints at C4-C5 and 11 joints at C5-C6). The APA capsule was found to have muscular insertions over $22.4 \pm 9.6\%$ of the total area, and reference was made to *m. semispinalis* and *m. multifidus* in terms of proximity to the APA capsule, though neither muscle was stated to insert directly on the APA capsule. Using experimentally estimated muscle loads on the APA capsule, the magnitude of forces exerted on the capsule due to muscular contraction and spinal motion was thought to be sufficient to cause rupture of or injury to the APA capsule, leading to injury of the APA and the capsular ligament. Cavanaugh *et al.* (2006) carried out a C4-C7 laminectomy in an unspecified number of adult female anaesthetized goats. A miniature bipolar electrode was used to record neural activity at the dorsal rootlets of C6 (left side) under induced load and strain to the APA capsule at C5-C6. Results showed activity in high-threshold nociceptors, mechanoreceptor saturation and high-strain afterdischarge at strains of 62% to 82%. These findings suggest a potential causative relationship between loading and stretch of the APA capsule and generation of cervical pain. In a parallel study by Lu *et al.* (2005), nine adult female anaesthetized goats underwent a laminectomy between C4 and C7 to expose the nerve roots of C6. A miniature bipolar electrode was used to measure conduction velocities in 57 single afferent fibers during loading and stretch tests of the C5-C6 APA capsule on the left side of the neck. Neural discharge response and two dimensional strains across the capsules, measured with a stereoisimaging technique and a finite element model, were recorded for displacements from 2 to 16 mm. Principal strains were applied in the same direction as the loading whilst principal shear strains were applied perpendicular to the loading direction. At a low rate of loading, the response of the sensory afferent receptors to this physiological/mechanical stimulus suggested that tensile

loading or stretching of the APA capsule could generate pain. Furthermore, damage to mechanoreceptors in the APA capsule may be linked to alteration of muscular recruitment patterns (Panjabi, 2006). The effect of applying tension to the APA capsule on cervical muscular recruitment was examined through fine-wire electromyography (Azar *et al.*, 2009) in order to demonstrate the existence of a reflex arc between the APA capsule and the perivertebral musculature. Recruitment of *m.multifidus* and *m.longus colli* was measured at the level of C5-C6 in five anesthetized female goats under conditions of loading and stretching. After initial conditioning of the APA capsule through displacement and release, the capsule was subjected to a series of stretch tests in 4mm increments of displacement in a trapezoidal loading pattern, with simultaneous measurement of muscular activity. *M. multifidus* was 100% activated in 100% of the stretch conditions, and *m. longus colli* was responsive in 33.3% (left side) and 38.9% (right side) of the stretch conditions. These findings indicate that there was a relationship between cervical muscle activation and load to the APA capsule, with *m. multifidus* being recruited at a lower load than *m. longus colli*, which may be related to differences in the fiber types within each muscle. Both muscles responded more or less equally at the same capsular strain (around 15-17%) though *m. multifidus* was activated at a lower load. This could be due to the fact that strain was only measured on the dorsal aspect of the joint capsule whereas load was recorded throughout the entire capsule.

Intra-articular APA structures known as synovial folds or meniscoids have been identified and described in human and animal studies. A detailed study by Inami *et al.* (2000) identified three different types of synovial fold in the APAs between C2 and C7 of twenty cadavers aged between 42 and 94 years (mean age=82 years). The type-1 fold was composed primarily of adipose tissue and was thus thought not to have been exposed to mechanical stress. The

composition of the type-2 fold, which consisted of dense fibrous and adipose tissue, suggested a potential exposure to some mechanical stress. The presence of type-3 folds consisting only of fibrous tissue suggested exposure to mechanical stress that was likely linked to a degenerative process. Synovial folds were present in 77% of the APA joints that were examined, though the authors questioned whether the presence of these folds was age-related, given that their subjects were mostly elderly. The authors also stated that the synovial folds were not likely to have a significant function in the APA, other than to enhance the motion of the two opposing articular surfaces. The same group (Inami *et al.*, 2001) carried out immunohistochemical evaluation of ten synovial folds from five patients (aged 32 to 64). The folds, which were obtained from unspecified spinal levels through a double-door laminoplasty, contained individual and bundled nerve fibers that were immunoreactive to substance P and CGRP (calcitonin gene-related peptide), indicating nociceptive characteristics. These findings led the authors to suggest that the synovial fold may play a role in APA pain in the human cervical spine. Friedrich *et al.* (2007) used high-field magnetic resonance imaging (MR) in a detailed anatomical investigation of the anatomy and location of the meniscoid structures (an alternative name for the synovial folds) in six APAs that were harvested between the levels of C3 and C7 from a fresh-frozen anatomical specimen. The results showed that the meniscoid structures contained fibrous and adipose tissue, occupied the intra-articular space of the joint, and were variable in appearance. The anatomical shape and location were thought to facilitate range of motion at the APA and to protect underlying osseous structures. MR was found to be a useful diagnostic tool for future evaluation of the role of the meniscoid structures of the cervical APA in pain and dysfunction of the cervical spine.

The effect of age and gender on degenerative changes and loss of range of motion (ROM) in the APAs of the cervical spine were evaluated in a retrospective study by Simpson *et al.* (2008). Intersegmental ROM was calculated from 195 series of radiographs of the cervical spine, using intersegmental measurements in maximal flexion and extension. Three different observers reviewed angle measurements from the radiographs. The Kellgren-Lawrence grading scale, commonly used to grade loss of interarticular space and formation of osseous degenerative changes, was modified for assessment of intervertebral disc generation between C2 and C7 by three independent reviewers. Interobserver reliability was analysed by an intraclass correlation coefficient (ICC) test for each group of three examiners, prior to evaluation of the ROM angle measurements and prior to grading of the degenerative changes according to the modified Kellgren scale. Results of the ICC interobserver reliability test were good and excellent, respectively. A multivariate analysis was used to identify the effects of age, gender, same-segment and adjacent-segment osseous degenerative generation on ROM in the cervical spine. Age was found to have the most important (negative) effect on ROM at all levels of the cervical spine, except for C6-7. Osseous degeneration (according to the Kellgren scoring system) was negatively associated with ROM at all intersegmental level throughout the cervical spine. Independent of osseous degenerative changes, an increase in age resulted in a decrease of ROM, at a rate of 5° for every ten years. Degenerative changes had a negative effect on ROM at the intersegmental level of interest, and at the adjacent (superior) level.

The most recent review into degenerative osseous changes in APAs of the cervical spine in people (Gellhorn *et al.*, 2013) proposes that OA in APAs is intrinsically linked to degenerative

changes of the intervertebral disc, with involvement of the entire APA complex as opposed so only the cartilage of the articular surfaces. This suggestion was based on the relationship of load distribution between the APAs and in the intervertebral joint, with OA being most prevalent in anatomical regions with higher mechanical forces. Interestingly the authors cited the now more common belief that diagnostic findings of OA in the APAs of the cervical spine is neither specifically indicative of the amount nor of the location of pain generation – the so-called ‘APA joint syndrome’ - and that diagnostic findings may be indicative of end-stage of disease rather than an early indication of a degenerative process within the entire joint complex.

1.1.4 DEEP MUSCULATURE OF THE CERVICAL SPINE: HUMAN STUDIES

In order to understand the concept of neuromotor control as it relates to movement of the cervical spine, and the potential adverse effects of osseoligamentous lesions on movement of the neck, it is essential that the functional anatomy of the musculature as related to movement of the neck is adequately described and understood. Head, neck and muscle kinematics are believed to be intrinsically linked to provide a stable platform for sensory input for the vestibular and ocular systems, providing an efficient system for eye-head movement co-ordination (Vidal *et al.*, 1986). This group described the orientation of the cervical spine in nine unrestrained species of vertebrates at rest, and identified that a vertical orientation stimulates the horizontal semicircular canals and that a horizontal orientation of the neck stimulates the vertical semicircular canals, potentially facilitating motor control by integrating neural pathways in the neck with those in the ocular and vestibular systems. This is important for interpreting and/or coordinating visual input when the head moves.

A study into the morphometry of the paraspinal musculature as related to movement of the neck and head (Kamibayashi and Richmond, 1998) measured muscle mass, pennation angle of muscle fibers, fascicle length and sarcomere length in 14 neck muscles of ten human cadavers. Morphometric parameters were obtained for superficial and deep muscles of the neck through microdissection. The musculature was deemed to be architecturally complex, with direct attachment of muscle fibers to the vertebral bodies, to surrounding fascia and to adjacent muscles through merging and interdigitation of muscle fibers. This complexity limited accurate analytical description of the deeper perivertebral musculature due to difficulty in careful tissue removal. For example, *m. longus colli* attached directly to the vertebral body but also had fascicular interdigitation with *m. intertransversarius* (Cave, 1937). Marked inter-individual variations existed in tendinous insertions, scaling of musculature related to body height and weight and inter-individual variation in muscle CSA.

With specific reference to the deep perivertebral musculature, *m. multifidus* and *m. longus colli* are considered to be functional stabilizers of the cervical spine (Mayoux-Benhamou *et al.*, 1994), with *m. multifidus* providing spinal extension (Cagnie *et al.*, 2011) and segmental stability (Boyd-Clark *et al.*, 2001) in a tonic function, and *m. longus colli* providing cervical flexion (O’Leary *et al.*, 2009; Cagnie *et al.*, 2010) and postural stability (Mayoux-Benhamou *et al.*, 1994) in a more phasic function. Histological evaluation of fiber composition confirmed these functions, with *m. multifidus* having a greater proportion of type I fibers and *m. longus colli* having a greater proportion of type II fibers (Boyd-Clark *et al.*, 2001), which is consistent with a primary function of postural stability to *m. multifidus* and functions of posture and movement to *m. longus colli*. The same group (Boyd-Clark *et al.*, 2002) investigated muscle spindle distribution in *m. multifidus* and *m. longus colli* in the caudal cervical spine between C5 and C7,

and observed that *m. multifidus* had a lower density of single-unit muscle spindles, mainly concentrated close to the vertebral lamina. *M. longus colli* had a higher density of muscle spindles, grouped in clusters and located further from the vertebral body.

The most detailed study to date on the functional anatomy of *m. multifidus* was carried out by Anderson *et al.* (2005) who described the morphology, architecture and biomechanical function of this muscle, based on microdissection between C2 and C7 in the cervical spine of nine human cadavers. The fascicles spanned between two and five intervertebral joints with a direct attachment on the APA capsules of inferior segments and on the spinous processes and laminae of superior segments. Fascicular attachments were defined as deep or superficial further divided into three subgroups (cranial, middle and caudal) based on their respective inferior attachments. The superficial layer originated from the APAs of C7 to C4, the deep layer inserted on the laminae of C4 to C2. For example, in the superficial layer the common superior attachment onto the spinous process of C2 was composed of cranial (originating at the articulation of C4-C5), middle (originating on the articulation of C5-C6) and caudal (originating on the articulation of C6-C7 subgroups. The attachment pattern of the superficial fascicles was consistent in four of the nine specimens. Variations included absence of a cranial subgroup (n=2) and insertions on more than one superior spinous process (n=3). In the deep layer, the fascicle of the cranial subgroup originated at the articulation of C4-C5 and inserted on the lamina of C2, the fascicle of the middle subgroup originated at the articulation of C5-C6 and inserted on the lamina of C3 and the fascicle of the caudal subgroup originated at the articulation of C6-C7 and inserted on the lamina of C4. The attachment pattern of the deep fascicles followed the same patterns in five of the nine specimens, with slight variations in attachments and/or absence of one of the fascicles/subgroups. Architectural parameters that were measured and described included

musculotendinous length, fascicle length, sarcomere length, pennation angle and physiological CSA. Based on these measurements and the anatomical attachments, the authors suggested that *m. multifidus* played a role in neck pain and postural stability of the head and neck. Gellhorn *et al.* (2013) acknowledged that the perivertebral musculature plays a key role in proprioception and stability and that functional impairment can have an adverse effect on intersegmental stability of the APA joint complex in the human cervical spine.

1.1.5 DEEP MUSCULATURE OF THE CERVICAL SPINE: ANIMALS

Findings from morphological measurements and description of deep perivertebral musculature of the human cervical spine are particularly interesting, as experimental electrical stimulation of the C2 nerve root ganglion in decerebrate cats demonstrated that muscle spindles of perivertebral musculature appeared to be a key source of afferent input in cervicocollic and tonic neck reflexes (Chan *et al.*, 1987), and were postulated to play an important role in sensory proprioception and positioning of the head and neck. The neck musculature of three Rhesus monkeys was described post-mortem in terms of morphometry and histochemistry (Richmond *et al.*, 2001) and, similar to findings from microdissection in people and cats, the architecture of the deep perivertebral musculature was found to be complex and difficult to analyse. *M. multifidus* was described as having fiber bundles linking the transverse processes and spanning up to three vertebrae, but no samples were taken for histochemical analysis. *M. longus colli* was described as having fiber bundles that connected the ventral aspect of the cervical vertebrae to the transverse processes of more caudal vertebrae. This muscle was not analysed in terms of muscle CSA due to its architectural complexity, though histochemical testing demonstrated a higher content of type II

fibers. Although this study acknowledged the need for a better understanding of neural circuits related to neuromotor control, the deepest musculature that is thought to be related to this model in terms of position and movement of the head and neck could not be fully described due to the complexity of the muscle morphology.

Similar results were reported by Sharir *et al.* (2006), where post-mortem evaluation of the neck musculature of six dogs showed that complicated fiber integrations and close adhesion of muscle fibers to the vertebral bodies made it difficult to analyse the deeper musculature, including *m. longus colli* and *m. multifidus* in terms of morphometric properties (muscle length, weight, fascicle length and angles of pennation). *M. longus colli* was described as having a cervical portion with three divisions per vertebral level, orientated in a cranio-medial direction and spanning across three intervertebral joints. The cervical portion of *m. multifidus* was described as having deep and superficial layers, with obliquely-orientated fibers that attached between articular processes caudally and more cranial spinous processes. Basic data of total mass and length were calculated as the authors believe that this muscle makes a substantial contribution to dynamics of the canine neck. To date there are no published descriptions of the detailed morphology of the perivertebral musculature of the equine cervical spine. The first study in this dissertation (Chapter 2) describes an investigation of the anatomy and morphology of *m. multifidus* and *m. longus colli* in the equine cervical spine.

1.2 BIOMECHANICS OF THE EQUINE CERVICAL SPINE

The cervical spine facilitates independent movement of the head relative to the trunk and stabilizes the proprioceptive organs therein. It acts as a cantilevered beam to support and move the head (Buchner *et al.*, 1997; Dunbar *et al.*, 2008). The caudal portion (the cervicothoracic junction) is described as a hinge (Gellman and Bertram, 2002a) that facilitates movements of the entire neck (Clayton *et al.*, 2012). Changes in shape of the neck are created through independent motion of the cervical intervertebral joints. Each of these joints is capable of a certain range of motion in flexion, extension, lateral bending and axial rotation and the summation of these movements creates total neck motion (Clayton and Townsend, 1989a). Although cervical spine motion is typically described in terms of three orthogonal rotations, studies with human subjects have shown coupling of the movements in different planes (Moroney *et al.*, 1988; Panjabi *et al.*, 2001). Modeling studies of spinal motion in the horse, which are still in the early stages compared to humans, support the concept of coupled motion in the equine cervical spine, at least under ex vivo conditions (Pagger *et al.*, 2010).

1.2.1 MUSCULAR INFLUENCE ON BIOMECHANICS OF THE CERVICAL SPINE

Most cadaveric studies of muscular morphometry in the human cervical spine have analysed muscle lengths, cross-sectional area (CSA) and angles of fiber pennation to describe the architectural characteristics of that muscle and to postulate on its function (Kamibayashi and Richmond, 1998; Boyd-Clark *et al.*, 2002; Anderson *et al.*, 2005). Long-fibered muscles are known to create greater absolute range of movement under a lower tension; these muscles have

small CSA and are designed for greater excursion and greater velocity of contraction. Short-fibered muscles with greater pennation angles have a larger physiological CSA, that allows the generation of larger forces (Shilling, 2011). Force created by muscle tension results in a moment (a turning force at a joint). Moment depends on the amount of force and its moment arm ('perpendicular distance of muscle insertion to the axis of joint rotation')(Lieber and Bodine-Fowler, 1993). Skeletal muscles can act primarily as stabilizers or movers, depending on their force-creating and moment-generating capacity respectively (Lieber and Bodine-Fowler, 1993). More superficial muscles with longer fast-glycolytic fibers create a larger range of movement over multiple intervertebral joints, whereas deeper (perivertebral) muscles with shorter, slow-oxidative fibers that are more fatigue-resistant provide segmental stabilization between individual joints (Schilling, 2011). Slow oxidative fibers are recruited prior to fast glycolytic fibers which provide stabilization of the joints prior to the initiation of movement (Higham and Biewener, 2011).

In order to better define neuromuscular function (which is an essential component of neuromotor control) in the cervical spine, other elements of muscular architecture should be considered, including aponeuroses and tendons, compartmentalization, fiber typing, moment-arm relationships and individual variation (Richmond, 1998). Knowledge of these elements is vital to fully understand cervical neuromuscular control, especially where this relates to biomechanical modeling of movement. Mobility and large range of motion are facilitated by superficial muscles with longer fibers, whereas stability and support are provided by deeper muscles with shorter fibers. Activity of both muscle types is regulated by proprioceptive input. In cases of musculoskeletal dysfunction and/or loss of normal proprioception both mobility and stability may be compromised, leading to movement dysfunction and/or pain (Comerford and

Mottram, 2001). It is beyond the scope of this thesis to fully describe the concept of neuromuscular function, though its key principles are outlined in an elaborate review on mechanical properties of muscular force generation in movement (Heckman and Sandercock, 1996).

The movement of the head and neck (head and neck position sense: HNPS) has been studied extensively in people. A review by Armstrong *et al.* (2008) analysed findings from nine peer-reviewed studies on HNPS and concluded that neuromotor input from muscles in the cervical spine is essential in providing feed-forward and feedback mechanisms that facilitate HNPS, which involves vestibular, visual and somatosensory input. Specimens of four feline cervical spines were used for histological analysis of small intervertebral muscles and connective tissues in the upper neck, and the identification of muscle spindles, Golgi tendon organs and Pacinian corpuscles led to the conclusion that the joints, muscles and osseoligamentous structures in the cervical spine make an important contribution to HNPS (Richmond and Bakker, 1982). Subsequently, more detailed analysis of the morphology of the muscle spindles in the intervertebral musculature of the upper cervical spine of two feline specimens described morphological differences between muscle spindles (located peripherally at the end of the spindle complexes) at a tendinous insertion versus those of the long intrafusal fibers in the mass of the muscle (Bakker and Richmond, 1982). Both studies questioned the relation between muscle morphometry and architecture and the apparently specialized but not yet defined link to central nervous system (CNS) functioning in terms of HNPS. A later experiment (Keshner *et al.*, 1992) used fine-wire electromyography (EMG) in the neck musculature of three live cats and identified activation of different muscles depending on whether movement was reflex or voluntary, resulting in different patterns of muscle activation for head and neck movement in the

same direction. Thus different CNS responses were involved depending on whether neck movements were reflexive or voluntary.

The musculature of the cervical spine of six canine specimens was investigated post-mortem to study the relationship between the functional anatomy and HNPS. Through morphometrical analysis of the superficial and deep musculature it was concluded that different forces are generated based on muscle CSA and fascicle lengths, and that both force-producing and stabilizing muscles could be found in the neck of the dog (Sharir *et al.*, 2006). Specific mention was made of the difficulty of accurately identifying and describing the deep perivertebral musculature (particularly *m. multifidus* and *m. intertransversarius*), though the combined weight and observed attachments of these muscles were thought to make a significant contribution to the

To date there is limited information on functional anatomy of the musculature in the equine cervical spine in relation to biomechanics of motion in the neck. Studies need to continue to fill gaps in the knowledge about this complex anatomical region.

1.2.2 RANGE OF MOTION OF THE EQUINE CERVICAL SPINE *IN VITRO*

In the horse, there are eight intervertebral motion segments between the skull and the first thoracic vertebra (Clayton and Townsend, 1989b). Motion in the equine cervical spine is both facilitated and controlled/limited by the shape and orientation of the APAs. Claridge *et al.* (2010) investigated six cadaver necks of young horses and used articular process injection and computed tomography (CT) imaging to create three-dimensional reconstructions of the APAs. The joints were found to have a dorsocaudally rounded and cranioventrally wedged shape, with a

steeper angle and larger surface area in the more caudal joints of the cervical spine. The articular surface of the cranial articular processes faces dorsomedially and those of the caudal articular processes face ventrolaterally (Mattoon *et al.*, 2004). Three-dimensional movements are described in terms of three rotations and three translations that occur, respectively, around and along three orthogonal axes. The three rotations are dorsoventral flexion and extension around a transverse axis, lateral bending around a dorsoventral axis and axial rotation around a longitudinal axis (Fig. 1.1). The three translations are transverse shearing, longitudinal compression and vertical shearing. These movements are both facilitated and limited by the architecture of the vertebral bodies and by the specific design of the APAs of the cervical spine (Clayton and Townsend, 1989a).

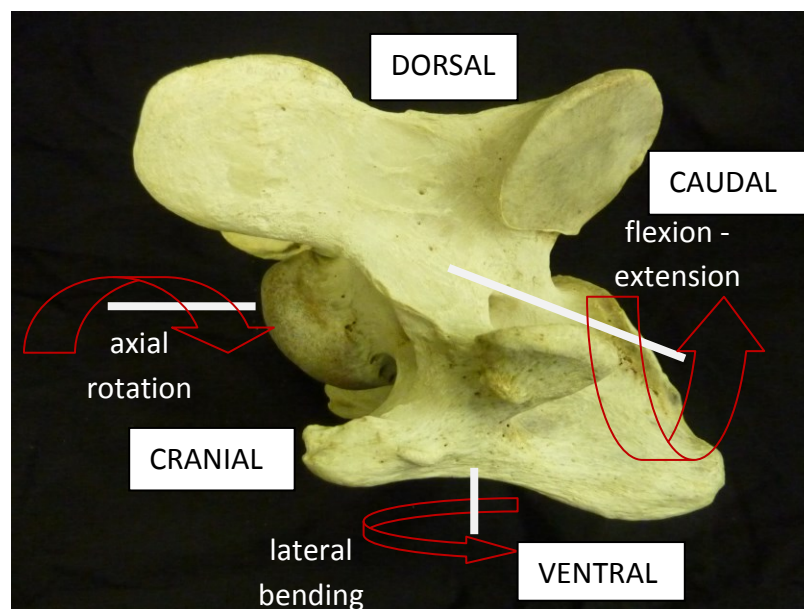


Figure 1.1: Image of the 6th cervical vertebra showing rotations about orthogonal axes in the equine cervical spinal column.

For interpretation of the references to color in this and all other figures, the reader is referred to the electronic version of this dissertation.

The first joint in the neck, the atlantooccipital (OA) joint, moves primarily in flexion and extension though it also allows significant lateral bending and gliding. These movements are difficult to describe due to the complex shape of the articular surfaces. The second joint, the atlantoaxial (AA) joint, is mainly responsible for axial rotation (Getty, 1975). Through post-mortem manual manipulation of osseoligamentous equine cervical spines (n=14), it was established that 32% of the total dorsoventral flexion of the cervical spine takes place in the OA joint and that 73% of total axial rotation takes place in the AA joint (Clayton and Townsend, 1989a). Lateral bending was found to be uniform along the length of the cervical spine caudal to C2, with the least lateral bending found in the AA joint.

A subsequent study by the same group (Clayton and Townsend, 1989b) used the same methodology to compare overall mobility of the cervical spine in vitro between foals (less than 12 months of age) and adult horses (over three years of age). Compared with adult horses, foals were found to have greater mobility in dorsoventral flexion and extension (22%), rotation (17.3%) and lateral bending (18.7%).

In another ex-vivo study, Pagger *et al.* (2010) used cervical spines (from the occiput to T1) of 17 equine subjects aged between 3 and 32 years to determine stiffness in dorsoventral displacement, stiffness in dorsoventral displacement with 30° rotation (coupled motion) and lateral bending. For each spine the nuchal ligament was removed, as were all the muscles. The spines were suspended in a metal frame in a sagittal plane, in a neutral position (defined as a position where there was little or no resistance to motion). Transverse metal bars were used to secure the vertebral body at C3 and at T1 and to attach cranial and caudal circular wheels. The caudal wheel was turned clockwise to guide the spine into 30° of rotation. Dorsoventral holes were made into

the spinous process and vertebral body of C3, where a force transducer was attached for testing of dorsoventral motion by moving the specimen in a dorsal and a ventral position (flexion and extension respectively). The spines displaced through creation of force at C3 at a speed of 5 mm/second in the defined excursions in relation to the manually-set neutral position. Force measurements were taken every five seconds and each spine was tested three times into each excursion. For flexion and extension each spine was tested from the neutral position into ventral flexion (8 cm displacement) and dorsal extension (8 cm displacement). For axial rotation each spine was turned to 30° clockwise rotation and moved 6 cm dorsally, returned to the neutral position and moved 6 cm ventrally, returning to the neutral position. For lateral bending each spine was placed on its side and moved 8cm to the left, returned to the neutral position and moved 8 cm to the right. Stiffness was calculated based on force-excursion data measurements of the entire spine in each of the three conditions and not of (individual) intervertebral segments, and was found to be higher in extension than in flexion. Stiffness in flexion and extension were higher than in coupled flexion and rotation or than in lateral bending. There was no correlation between stiffness and age of the subjects. It must be reiterated that the aforementioned studies were performed ex vivo and the results should not be extrapolated to kinematics of the cervical spine in the live horse.

An ex vivo experiment (Sleutjens *et al.*, 2010) with segments (n=6) from C2 to T2 used computerized tomography to measure foraminal dimensions in the equine cervical spine under conditions of different degrees of flexion and extension away from the neutral position. The neutral position was defined by anchoring the segment to a table and creating a horizontal line between the top of the dorsal spinous process of C6 to the wing of the atlas (it was not stated

which anatomical landmark was used on the atlas). Manual force was used to achieve different degrees of flexion (20° and 40°) and extension (20° and 40°). Five CT images were taken of each specimen in each of the positions (flexion, extension and neutral). Reconstructions in the medial plane were used to calculate changes in angles between adjacent vertebrae. Transverse images were used to calculate height and length of the intervertebral foramina between adjacent vertebrae. The positions in extension (20° and 40°) resulted in a progressive decrease in the height and length of the intervertebral foramina of the lower neck and the cervicothoracic junction, leading the authors to question the effect of in vivo extension of the neck (due to an elevated head-neck position) on neuromuscular function. Flexion at 20° increased foraminal length at the level of C6-C7. Although this is an ex vivo study and results cannot be extrapolated to in vivo head-neck positions, these findings form a useful basis for further investigation into the effect of head-neck position on neuromuscular health of the equine cervical spine.

1.2.3 MOTION OF THE CERVICAL SPINE IN THE STANDING HORSE

A series of dynamic mobilization exercises in eight live horses were used to induce the horse to move the neck into different flexed positions (chin-to-chest, chin-between-carpi and chin-between-fetlocks of thoracic limbs) (Clayton *et al.*, 2010). Reflective markers overlying the transverse processes were tracked by a motion analysis system to determine intervertebral angulations during each exercise. The majority of cervical flexion occurred in the cranial and caudal cervical regions. There was an increase in extension of the joint angle at C1 and an increase in flexion at the joint angle of C6. In the high position (chin-to-chest) there was

increased flexion of the upper joints, whereas in the lower positions (chin-to-carpi, chin-between-fetlock joints) there was increased extension of the cranial angles and increased flexion of the caudal angles.

In another series of dynamic mobilization exercises, the same researchers (Clayton *et al.*, 2012) used the same eight horses and the same kinematic analysis procedure to investigate lateral bending at the cervical intervertebral joints. Angles were measured in three lateral bending positions (chin-to-girth, chin-to-hip and chin-to-tarsus). The angle at C1 showed the greatest lateral flexion in the chin-to-girth position. The caudal positions produced a counter-bend in the upper cervical spine and an increased bend at the base of the cervical spine. Moderate lateral flexion was recorded in the mid-cervical spine in all three positions. The majority of lateral flexion was found in the joint at C6 in the more caudal positions (chin-to-hip and chin-to-tarsus).

It must be noted that measurement errors due to skin motion have not been quantified in the equine cervical spine but previous studies of limb kinematics have indicated that, even without correction for skin artifact, repeated measurements under different conditions are useful (van Weeren *et al.*, 1992, Zsoldos *et al.*, 2010a, Clayton *et al.*, 2011).

1.2.4 MOTION OF THE EQUINE CERVICAL SPINE DURING LOCOMOTION

The head and neck behave mechanically as a cantilevered beam that projects cranially from the trunk segment (Dunbar *et al.*, 2008). During locomotion, the effects of gravity and inertia are opposed by a combination of passive (ligamentum nuchae) and active (muscular) support. Functional characteristics of these structures were derived from ex-vivo measurements and post-

mortem morphometric analysis of five subjects (Gellman and Bertram, 2002a). These authors described a proposed line of action of the nuchal ligament from the withers to C2 (axis), and postulated that it provides antigravitational support of the neck whilst allowing independent movement of the head. Based on analysis of head and neck movements in six Standardbred horses during treadmill work at walk, trot and canter, (Gellman and Bertram, 2002b) it was estimated that elastic strain energy stored in the nuchal ligament contributed 55%, 33% and 31%, respectively, to total energy required to support the head and neck in walk, trot and canter. It must be noted that moment measurements to calculate power calculations were based on previous data from ex-vivo measurements.

Two large muscles located dorsal to the equine cervical spine, namely, *m. semispinalis capitis* and *m. splenius*, were studied post-mortem in three horses to determine morphometry and fiber type composition (Gellman *et al.*, 2002). *M. splenius* was described as having a simple architecture with long fibers, composed of 59% type I or slow-oxidative (SO) muscle fibers. These findings suggest that it was involved in raising the head and stabilizing the neck during locomotion. *M. semispinalis capitis* had a more complex architecture with dorsal and ventral compartments separated by a central energy-storing tendon. There was a mix of type I or SO fibers in the dorsal compartment and a larger percentage of type II or fast-glycolytic (FG) fibers in the ventral compartment. Based on these findings, *m. semispinalis* is presumed to have an antigravitational supportive or stabilizing function as well as playing an active role in raising the head and neck.

Variation in motor unit action potential (MUAP) was measured through needle electromyography (Wijnberg *et al.*, 2010), using changes in MUAP to assess the effect of

different head and neck positions in seven Royal Dutch Warmblood horses during a standardized exercise protocol on the lunge. The results indicated that different head and neck positions affected single muscle fiber recruitment and MUAP. Wijnberg *et al.* (2011) also used needle electromyography to evaluate the normal MUAP in *m. brachiocephalicus* and *m. serratus ventralis cervicis* along the length of the equine cervical spine (at six different segments) of seven Royal Dutch sport horses. The results provided normative data of MUAP for comparison with data from horses with neurological or orthopedic conditions. Deviations from a normal pattern are potentially used for clinical diagnosis of neuromuscular disorders in the neck, in which a loss of functional MUAP can result in altered firing patterns. Based on amplitude output, the authors suggested a larger presence of type I fibers in both muscles, indicating a potential antigravitational function. The authors did not indicate whether EMG recordings were made bilaterally, which raises the question of the effect of how a unilateral neuromuscular disorder affects MUAP on the ipsilateral and contralateral sides of the neck. It must, however, be noted that muscle fiber recruitment and activation patterns can vary within different compartments of a muscle, leading to a complexity in muscle functions (Wakeling, 2009; Higham and Biewener, 2011). In the horse this phenomenon has already been identified in *m. gluteus medius* (López-Rivero *et al.*, 1992).

1.2.4.1 NECK MOTION IN WALK

According to an accelerometric study in the non-lame horse, two longitudinal oscillations of the neck can be observed in each stride of the walk, as well as two dorso-ventral displacements at the level of the sternum (Barrey *et al.*, 1994). Zsoldos *et al.* (2010) recorded in vivo kinematics from

six horses walking on a treadmill to design a preliminary model of movement in different planes in the cervical spine from C1 to C6. Based on kinematic calculations, flexion-extension was largest in the C3-C4 joint and smallest in the C5-C6 joint. The largest amount of axial rotation was found in the atlanto-axial joint, and the smallest amount in the C5-C6 joint. Lateral bending was largest in the cervicothoracic junction and smallest in the C5-C6 joint. These results must be interpreted with some caution as intervertebral segmental calculations were derived from kinematic markers placed at the first, third and sixth cervical vertebrae only. Moreover, the authors do not describe which anatomical landmarks were used to place the skin markers over the individual vertebrae. However, the authors did acknowledge that the largest source error was due to skin motion at the level of C6.

One of the earliest studies into function of the musculature of the equine cervical spine (Tokuriki and Aoki, 1991) employed needle EMG and hoof strain measurement to investigate the activity of *m. splenius*, *m. sternomandibularis* and *m. brachiocephalicus* in standing, walk, trot and canter in four horses, with and without a rider. Placement of the electrodes was not well described so care must be taken with interpretation of muscular activity. *M. splenius* was the only muscle that showed activity in standing both with and without a rider and was active from early mid-stance to late mid-stance in the walk. *M. sternomandibularis* was also noted to be active in walk during riding, but not notably in the unridden horse.

The effect of head and neck position on nuchal ligament and vertebral loading in the equine cervical spine was studied seven Warmblood horses walking along a straight line. Kinematic data were used to construct a model of the entire cervical spine through to the highest point of the withers at T6 (Elgersma *et al.*, 2010). The nuchal ligament was loaded maximally at the

level of C2 in all head and neck positions; the highest loading of the nuchal ligament attachments occurred with the neck in a ‘hyperflexed’ position. This study used five marker positions of which only one was placed on the actual neck (wing of the atlas at C1). The other markers were placed on the facial crest, on the dorsal spinous process of T6, on the suprascapular tubercle and on the lateral styloid process of the radius. Two additional markers were placed on the bridle as a calibration reference. As such, presumed loading on ‘individual’ structures in the neck appears to be questionable as joint angle calculations were gross and not intersegmental, and thus hypothetical measurements were based on gross range of motion in all head and neck positions. This study serves as an interesting pilot project to evaluate the effect of riding technique on the anatomical structures of the neck. Previous in vivo investigations have focused on the effect of head and neck positions on loading of the locomotor system in ridden and unridden horses, measurement of thoracolumbar and limb kinematics, and evaluation of interlimb coordination (Gómez-Álvarez *et al.*, 2006; Weishaupt *et al.*, 2006; de Cocq *et al.*, 2009; Rhodin *et al.*, 2009; Waldern *et al.*, 2009).

1.2.4.2 NECK MOTION IN TROT

In the trot, two cervical oscillations occur during each full stride, but with the neck in a more vertical orientation than in the walk (Buchner *et al.*, 1996, Clayton and Sha, 2006). The head is highest in the first half of stance and lowest at the end of the stance phase, with a downward rotation of the neck during mid-stance. The EMG measurements of Tokuriki and Aoki (1991) showed that *m. splenius* was active in each forelimb from early stance in the trot, when it exerted an antigravitational force, with a higher activity in the contralateral forelimb than in the

ipsilateral forelimb. *M. sternomandibularis* was active during the stance phase of each forelimb in trot, as well as during suspension to control elevation of the neck. *M. brachiocephalicus* was active in the ipsilateral limb from mid to late stance phase to mid to late swing phase in trot, as well as during suspension. In the ridden horse, the activity of *m. splenius* was reduced during the early stance phase. A more recent study (Zsoldos *et al.*, 2010) used surface EMG and kinematic analysis to study head and neck angles and measure activity of *m. splenius* in six horses during walk and trot on a treadmill. Based on the fact that maximal muscle activity was measured prior to early stance in the trot, it was suggested that one of the functions of *m. splenius* is provide stability against the flexion of the head and the neck prior to impact. The methodology of EMG electrode placement over the muscle was poorly described, with a mere mention that it was placed ‘at the level of the second cervical vertebra’. Given that other superficial muscles can be identified in this area, a more precise electrode placement technique is required to ensure the recordings are representative of *m. splenius*.

1.2.4.3 NECK MOTION IN CANTER

In canter, the cranial part of the neck rotates down in mid-stance and rotates upwards during leading forelimb stance and the suspension phase (Denoix and Audigié, 2001). According to EMG measurements by Tokuriki and Aoki (1991), *m. splenius* is active from early stance in the canter, *m. sternomandibularis* is active from late stance to early swing of the leading forelimb and in the swing phase of the trailing forelimb during canter. *M. brachiocephalicus* is active in the ipsilateral limb from mid or late stance phase until mid to late swing phase in canter, which encompasses the time before and after landing of the ipsilateral forelimb (both with and without

a rider). *M. splenius* was also active during the leading forelimb stance phase and the suspension phase, facilitating extension and limiting lowering of the neck. *M. brachiocephalicus* was active during the suspension phase. The upward/downward oscillation of the neck, together with the activity of the supporting musculature in the different phases of the stride, limits or controls the effects of gravity during the full canter stride. The measurement results of this study led the authors to question whether *m. splenius* had an earlier onset in the canter (compared to walk and trot) to stabilize the head and neck at a higher velocity of locomotion, and whether the long period of activity of *m. brachiocephalicus* was related to a more complex function (such as a muscle of locomotion), based on the muscle's size, morphology and anatomical location as it has attachments on the cervical spine and on the thoracic limb.

1.2.4.4 THE EFFECT OF REIN TENSION ON HEAD-NECK POSITION

The effect of the use of martingales on the position of the head and neck relative to the withers was investigated by Heleski *et al.* (2009) in a randomized design with four horses and nine riders, under three different conditions (the use of simple reins, adjustable training martingales and elasticized side reins). Mean rein tension was higher and the head-neck position was lowest for horses ridden with the training martingales. There was no difference in the relative position of the head-neck to the withers using plain reins or elasticized inserts. The lower head-neck position was also positively correlated with increased skill of the rider.

1.3 OSSEOUS LESIONS IN THE CERVICAL SPINE

1.3.1 LESIONS IN THE HUMAN CERVICAL SPINE

Neck pain is highly prevalent in the human population (Fejer *et al.*, 2006, Hogg-Johnson *et al.*, 2008), with up to 60% of subjects reporting persistent or chronic pain a year after the initial episode (Manchikanti *et al.*, 2009). The human cervical spine has 37 joints (Bland and Boushey, 1990). The morphological design of the zygapophyseal joints or articular process articulations (APAs or APA joints) facilitates and limits movement in different planes including flexion, extension, axial rotation, lateral bending and combinations of coupled movements (Bogduk and Mercer, 2000). Through description of orientation and dimensional measurements of APAs of dry macerated segments of the cervical and upper thoracic spine (n=30), it was concluded orientation and size of the APAs are relevant to clinical conditions in the cervical spine (Pal *et al.*, 2001). Contact pressure of the articular surfaces of C5-C6 increases during extension, decreases during flexion and is almost absent in the neutral position, as determined by kinematic three-dimensional motion tracking and pressure-probe measurements during sagittal moment application in the cervical segment of six human cadavers (Jaumard *et al.*, 2011).

When traumatic injuries or degenerative joint disease occur, normal movement in the cervical spine is compromised (Yoganandan *et al.*, 2001). Trauma through whiplash-associated disorder is considered to be a leading cause of chronic neck pain (Evans, 1992, Quinlan *et al.*, 2004) The impact on the cervical spine is thought to be a mechanism for injury to the APAs in the neck, according to biomechanical modeling of whiplash-type trauma in cadavers and healthy subjects (Bogduk and Yoganandan, 2001).

1.3.2 OSSEOUS PATHOLOGY IN THE APAs OF THE HUMAN CERVICAL SPINE

Degenerative disease processes in the APSs affect both material and mechanical properties of the joint and may or may not be accompanied by concurrent changes in the adjacent intervertebral discs (Jaumard *et al.*, 2011). Osteoarthritis (OA) is a degenerative process that affects the metabolism of articular cartilage (Gabay, 2012). Destruction of the cartilage causes alteration of the joint mechanics and affects the integrity of the APA joint capsule (Jaumard *et al.*, 2011). The subsequent joint laxity is thought to result in the formation of osteophytes or bone spurs in an attempt to stabilize the joint and prevent excessive motion caused by joint laxity (Kumaresan *et al.*, 2001).

Through local anaesthetic blocks, APA joint pain has been identified in 55% of patients who reported chronic neck pain (Manchikanti *et al.*, 2004). Post-mortem investigation of cervical APAs (n=21) revealed the presence of both mechanoreceptive and nociceptive nerve endings in the APA joint capsule, indicating that the APA may be a source of pain where instability or degeneration of the APA is present (McLain, 1994). This was further confirmed by identification of substance P and calcitonin gene-related peptide reactive nerve fibers in the APA capsules of the cervical spine (Kallakuri *et al.*, 2004).

The APA joint in the cervical spine has become an accepted contributing factor to human neck pain and grading systems have been developed to describe APA joint degeneration (Kettler and Wilke, 2006). A radiographic grading system recommended as an adjunct in clinical settings.

1.3.3 OSSEOUS PATHOLOGY IN THE EQUINE SPINE

1.3.3.1 OSSEOUS PATHOLOGY IN THE EQUINE THORACOLUMBAR SPINE

To date, studies of the equine spine have focused primarily on patho-anatomical diagnosis of thoracolumbar osseous (Jeffcott, 1980; Haussler *et al.*, 1999; Haussler *et al.*, 1999a; Stubbs *et al.*, 2010) and soft-tissue lesions (Denoix and Dyson, 2003). Lesions such as spondylosis and osteoarthritis of the dorsal spinous and articular processes of the back were observed in retrospective studies in horses with suspected back pain (Gillen *et al.*, 2009, Girodroux *et al.*, 2009, Meehan *et al.*, 2009).

The incidence of back and neck pain in horses has been reported to range between 2-94%, depending on the type of practice surveyed (Jeffcott 1980; Haussler *et al.*, 1999b) with the most common presenting sign being a non-specific loss of performance (Dyson, 2002). Focal lesions in the thoracolumbar spine have been identified as a cause of loss of performance in the racehorse (Wilsher *et al.*, 2006). Post-mortem studies have identified degenerative changes at various sites in the thoracolumbar spinal column in Thoroughbred racehorses (Haussler *et al.*, 1999). In another post-mortem study of 22 Thoroughbred racehorses the most commonly identified lesions were degenerative changes in the APAs of the thoracolumbar spine, vertebral body spondylosis, APA and neural arch fractures, periarticular osteophyte formation, ankylosis of intertransverse joints, osseous proliferation of the dorsal spinous processes and intervertebral disc disease (Stubbs *et al.*, 2010). Spinal biomechanics were thought to be altered with osseous changes in the thoracolumbar spine according to an ex-vivo study of pathological changes in the thoracolumbar spine of 23 horses (Townsend *et al.*, 1986). It was suggested that kinematic evaluation of the thoracolumbar spine may be useful in clinical observation of horses with

suspected back pain, following kinematic analysis of 12 horses with suspected back pain and comparing these findings to motion in the thoracolumbar spine of the asymptomatic horse (Wennerstrand *et al.*, 2004). There is a lack of comparable data on the equine cervical spine. The second study in this thesis (Chapter 3) describes the prevalence and severity of osseous lesions in the APAs of the equine cervical and cranial thoracic spine.

1.3.3.2 OSSEOUS PATHOLOGY IN THE APAS OF THE EQUINE THORACOLUMBAR SPINE

Pathological lesions of the APAs in the equine thoracolumbar spine have been linked with back pain and loss of performance. A retrospective study (Girodroux *et al.*, 2009) examined clinical records of 77 horses that were presented for back pain and diagnosed through radiography with degenerative changes in the APAs of the thoracolumbar spine. The most common findings were sclerosis, periarticular bone formation and narrowing of the intra-articular space in the APAs. Breed, gender and discipline did not affect prevalence of osseous pathology in the APAs. Using nuclear scintigraphy, images of the thoracolumbar region of clinically normal horses (n=31) were compared to those of horses (n=65) with back pain and degenerative changes in the APAs of the thoracolumbar region (Gillen *et al.*, 2009). The authors concluded that an increased uptake of radiopharmaceutical material could be indicative of active degenerative changes in the APAs of the thoracolumbar spine, but that additional diagnostic imaging such as radiography should be carried out to evaluate clinical relevance of findings on scintigraphic imaging. Radiography was used to identify and grade osseous pathology in a group of French trotters with (n=102) and without (n=16) back pain. Lesions in the APAs were mostly identified in the thoracolumbar

junction (T17-L2) and the grade of the lesions was significantly higher in the clinical than in the control group. Intra-articular injections are used diagnostically and therapeutically for horses with suspected pain and/or diagnosed osseous pathology of the APAs. In order to develop an improved technique for intra-articular injections, a cadaveric study using 12 horses attempted to refine a methodology for ultrasound-guided intra-articular injections, but only 27% of the injections were successful in terms of penetration into the actual APA (Fuglbjerg *et al.*, 2009). A more recent cadaveric study in four horses (Cousty *et al.*, 2011) aimed to define an optimal approach (medial or lateral) for intra-articular injection into the APAs of the thoracolumbar spine. Under ultrasonographic guidance, 86% of injections were successful in terms of penetration into the APA, but neither approach was found to be optimal.

1.3.3.3 OSSEOUS PATHOLOGY IN THE EQUINE CERVICAL SPINE

Studies of cervical osseous lesions in the horse have focused mainly on cervical vertebral compressive myelopathy (van Biervliet *et al.*, 2006; Levine *et al.*, 2007). Arthropathy of the cervical APA joints has been cited in the etiology of reduced performance in the horse, and has been reported to cause forelimb lameness (Ricardi and Dyson, 1993), stiffness in movement, neck muscle atrophy and neck pain (Beck *et al.*, 2002; Dyson, 2003). Through examination of six cadaveric necks (Claridge *et al.*, 2010), a three-dimensional model of the APAs was developed, based on radiographs and CT images. This model was used to confirm that effusion within the APA capsule of the cervical spine is unlikely to cause compression of the spinal cord, which is known to be associated with neurological manifestations (Ricardi and Dyson, 1993).

To date there is little known about cervical intervertebral disc disease in horses. Though cervical disc disease has been diagnosed through radiography and clinical examination in five horses that presented with neck pain (Adams *et al.*, 1985), disc disease may be an under-reported pathology due to diagnostic challenges. The only study of the gross anatomy of the discs (Bollwein and Hänichen, 1989) involved sectioning of the cervical vertebrae of 103 horses (aged 42 weeks to 23 years) in the median plane and gross examination of intervertebral disc tissues. The authors reported that a *nucleus pulposus* was absent, and that the disc consisted of a fibrocartilagenous tissue that became more yellow in color with progressive age. A partial to complete loss of disc connection to the vertebrae was also observed with increasing age, and this process appeared to increase in frequency from cranial to caudal intervertebral levels.

1.3.4.4 OSSEOUS PATHOLOGY IN APAs OF THE EQUINE CERVICAL SPINE

There have been few published anatomical descriptions of the APA joints in the equine cervical spine, particularly related to the prevalence, clinical signs and pathological features of degenerative changes. Ultrasonographic (US) imaging of the equine cervical region provided a reference for normal appearance of the cervical vertebrae, APA joints and paravertebral structures in eight horses of unspecified breed, between the ages of two and 14 years (Berg *et al.*, 2003). Withers *et al.* (2009) described a new technique using lateral and oblique radiographic projections, to enhance diagnostic imaging of the caudal cervical spine in six horses. A novel way of imaging the APAs in the cervical spine using a C-Arm technique was described, to aid diagnosis of osseous changes in the APAs of the equine cervical spine (Withers *et al.*, 2009).

Claridge *et al.* (2010) described normal anatomical findings for the APA joints of the cervical spine in six subjects, in terms of general shape, spatial orientation and joint volume.

In an early study that evaluated the efficacy of cervical spinal fusion to treat horses with ‘Wobbler’ syndrome, the APAs of control horses appeared normal on gross examination, whereas APAs of horses diagnosed with cervical vertebral malformation (CVM) showed signs of erosion, fibrillation, lipping and change of shape of the articular surfaces (Wagner *et al.*, 1979). Twenty five horses with cervical static stenosis (CSS) were examined radiographically and post-mortem (Powers *et al.*, 1986) and osseous pathology in the APAs was identified in the majority of the subjects. Lesions included loss of articular space, changes in thickness of the dorsal lamina and osteochondrosis. The authors of a study of compressive spinal cord lesions using radiography and myelography (Papageorges *et al.*, 1987) suggested that bone remodeling in the cervical spine may contribute to ataxia in horses. Post-mortem evaluation of cervical spine segments of nine horses aged 12 months to six years and of different breeds revealed that spinal cord compression, thought to be responsible for ataxia, was accompanied by osseous pathology in the dorsal APAs as well as joint capsule distension (Trostle *et al.*, 1993). Using radiography with radio-opaque markers, the images of 50 horses with cervical stenotic myelopathy (CSM) were compared to images of 50 control cases (Moore *et al.*, 1994). As an aside to the outcome of the study that focused on diameter measurements of the vertebral canal, the authors concluded that degenerative joint disease of the APAs was observed in both groups, though it appeared to be more severe in the SCM cases. A retrospective study of radiographic images of 122 horses aged eight months to 25 years (Down and Henson, 2009) concluded that the size of the caudal cervical APA joint at the level of C5-C6 appears to increase with age, but it is not known whether there is an association between such changes and clinical signs or performance.

Degenerative osseous pathology in the APAs of the equine cervical spine has been identified as a potential source of neck pain and associated loss of performance (Ricardi and Dyson, 1993; Dyson, 2003; Levine *et al.*, 2007; Birmingham *et al.*, 2010) and a methodology for diagnosis and/or treatment has been suggested, using a specific technique for APA injection (Mattoon *et al.*, 2004). The accuracy of injections into the APAs of the cervical spine has been evaluated through ultrasound-guided post-mortem injections with dye into the APAs of C2-C7 and subsequent dissection (Nielsen *et al.*, 2003). Based on the accuracy of the injections (72% into the joint space, 17% into the joint capsule and 98% within 1 mm of the joint capsule) the authors suggested that intra-articular infiltration could be used by practitioners as a diagnostic and/or therapeutic procedure in live horses, after familiarization with the technique in cadavers. The efficacy of corticosteroid injections into the APAs of 124 primarily performance horses with CSM was evaluated in a retrospective study (Birmingham *et al.*, 2010). The authors concluded that ultrasound-guided APA injections may be a useful adjunct for treatment of pain in horses with osseous pathology in the cervical spine.

In the horse, synovial folds have been observed in 98% of APAs of the cervical spine between C2 and C7, and based on their size and morphology they are thought to be susceptible to damage or injury, potentially contributing to equine neck pain (Thomsen *et al.*, 2012). Synovial folds have been identified in APAs of the human cervical spine, and have been described anatomically (Inami *et al.*, 2000). They contain substance P and calcitonin gene-related peptide, suggesting a relationship between damage to synovial folds in the cervical spine and the manifestation of neck pain (Inami *et al.*, 2001). The relation between excessive APA capsule tension and/or stretching and pain generation was established by laminectomy studies in cervical segments of anaesthetized goats, where neural activity was shown to change with increased capsular strain

(Cavanaugh *et al.*, 2006). A similar methodology was used during ex-vivo tension testing of the capsular ligament at the C6-C7 articulation in the cervical spine of Holtzman rats, where damage to the ligament due to excessive strain was thought to be a mechanism for pain (Quinn and Winkelstein, 2007).

It is not yet known which vertebral levels are most frequently affected by degenerative changes in the APAs in the equine cervical spine. The aim of the study in Chapter 3 of this thesis was to describe the prevalence and severity of osseous lesions in the APAs of the cervical and cranial thoracic spine. As osseous lesions in the APAs of the equine cervical spine are commonly treated in a clinical setting, it is essential to determine which vertebrae in the equine cervical and cranial thoracic spine demonstrate the highest prevalence and severity of osseous lesions.

1.4 NECK PAIN AND NEUROMOTOR CONTROL

1.4.1 PAIN

Pain has been recognized as a primordial emotion, communicated to the brain by interoceptors (Craig, 2002). The Gate-Pain theory (Melzack and Wall, 1965) is long known for explanation of pain sensation. In the absence of a noxious stimulus there is no pain (the ‘gate’ to the brain is closed). After a noxious stimulus, type A-delta and C nerve fibers cause transient impulses, that activate projection neurons and block inhibitory neurons that connect with the brain (the ‘gate’ to the brain is open). The result is a sensation of pain. The later theory by Melzack (1999) acknowledges that pain experience is unique to individuals, based on each person’s individual neuromatrix. The Pain Adaptation Model (Lund *et al.*, 1991) suggests that noxious stimulation

alters activity of spinal cord neurons, inhibiting agonist motor units and facilitating antagonist motor units, resulting in limitation of movement. It is widely acknowledged that individual pain experience is based on physical, psychological, cognitive and emotive factors (Helms and Barone, 2008). Emotions can affect pain perception and physiological responses to pain, and are also influenced by previous pain-related experiences (Rainville *et al.*, 2005).

From a neurophysiological point of view, pain can be described as a central sensitization caused by prolonged nociceptor activation of A-delta and C-fibers during a stage of inflammation (Bennett, 2000). The earlier Pain-Gate theory (Melzack and Wall, 1965) and Pain Adaptation model (Lund *et al.*, 1991) offered initial explanations for the association between musculoskeletal pain and altered motor function. In a review of the existing literature, Sterling *et al.* (2001) elaborated on references to the more-recently accepted Neuromuscular Activation model. The concept of this model is based on altered muscular recruitment and activation patterns in the presence of musculoskeletal pain, with negative effects on articular stability and control. These include proprioceptive deficits, loss of kinesthetic awareness, altered muscle function around a joint and change to muscle fiber characteristics, and are all believed to be a still relatively poorly-understood part of a central nervous system adaptations to acute and chronic musculoskeletal pain.

1.4.2 NECK PAIN AND NEUROMOTOR CONTROL

Globally, neck pain is highly prevalent in both general and working populations (Bovim *et al.*, 1994, Croft *et al.*, 2001, Guez *et al.*, 2002, Cotê *et al.*, 2004, Fejer *et al.*, 2006, Hogg-Johnson *et al.*, 2008, Gellhorn, 2011) and a major problem in addressing this condition is the high rate of recurrence (Enthoven *et al.*, 2004, Carroll *et al.*, 2008). A key aim of therapeutic intervention is to prevent the recurrence of neck pain episodes through specific rehabilitative exercises (Bronfort *et al.*, 2001; Jull *et al.*, 2002, Jull *et al.*, 2008; Jull *et al.*, 2009). For effective rehabilitation it is essential that synergistic interdependent function between the osseoligamentous, muscular and neural systems in the cervical spine is well-understood.

Cervical APAs have been cited as a source of neck pain (Bogduk and Marsland, 1988; Manchukonda *et al.*, 2007; Falco *et al.*, 2009) as determined by the use of anesthetic nerve blocks to localize pain in APAs of the cervical region. The paired APAs of the cervical spine have a unique morphological architecture and orientation, to simultaneously allow and limit movement in each of the joints (Pal *et al.*, 2001). The perivertebral musculature of the cervical spine contains high densities of muscle spindles (Armstrong *et al.*, 2008) and ‘unique muscle arrangements’ that function to control movement of the APAs into multiple planes of motion (Bogduk and Mercer, 2000; Falla *et al.*, 2007) and to provide a stable head and neck position sense (HNPS) (Armstrong *et al.*, 2008).

Spinal stability is achieved by interdependent optimal functioning of the osseoligamentous, muscular and neural systems (Jull and Richardson, 2000; Reeves *et al.*, 2007), with a specific emphasis on achieving stability through timely central nervous system feedback control (Reeves *et al.*, 2011). Results from an in-vitro study of axial compressive loading of seven cervical spines

(C0-T7) suggested that the osseoligamentous structures provide 20% and that the perivertebral musculature provides 80% of support to the cervical spine (Panjabi *et al.*, 1998). Intact feedforward (preparatory stabilization or mechanism of anticipation) and feedback (sensorimotor control) mechanisms are essential elements of the neural system as it relates to neuromotor control of the HNPS (Paulus and Brumagne, 2008; Sjölander *et al.*, 2008). In human patients with neck pain, neuromotor control is compromised, resulting in altered muscular functioning (Woodhouse and Vasseljen, 2008).

Alterations in muscle activation due to neck pain affect both superficial and deep neck muscles (e.g. Jull *et al.*, 2004a; Falla and Farina, 2007; Fernández-de-las-Peñas *et al.*, 2008; Elliott *et al.*, 2010; Cagnie *et al.*, 2011; Lindström *et al.*, 2011; O’Leary *et al.*, 2011,). Neck pain also affects muscle properties, with transformation from type I to type IIC fibers (Uhlir *et al.*, 1995; Falla and Farina, 2007), and the changes in muscle properties are not automatically reversed with pain reduction. Through magnetic resonance imaging (MR) it has been shown that relative muscle CSA is altered (increased) in extensor muscles of the cervical spine, including *m. multifidus*, in patients with chronic neck pain (Elliott *et al.*, 2008; Elliott *et al.*, 2010). The authors have suggested that this increase in CSA may be due to an alteration in muscle make-up by fatty infiltration, known to be associated with motor neuron lesions or other myopathies, secondary to whiplash-associated disorders. Conversely, patients with chronic neck pain appear to have a bilaterally reduced CSA (or relative atrophy) of *m. longus colli* in comparison to asymptomatic subjects (Javanshir, 2011), based on a blinded controlled study of 20 neck pain patients and 20 asymptomatic subjects in which muscle CSA was measured by ultrasound imaging at the level of C5-C6. Neck pain has also been found to cause sensory alterations including hyperalgesia with a

lower threshold for pain pressure testing (Scott *et al.*, 2005; Chien *et al.*, 2008; Johnston *et al.*, 2008).

1.4.2.1 ELECTROMYOGRAPHY FOR ASSESSMENT OF NEUROMOTOR CONTROL IN THE CERVICAL SPINE

Surface electromyography (EMG) has been used to measure flexor and extensor activity of superficial neck muscles in patients with neck pain. Falla *et al.* (2004b) investigated differences in myoelectric activity of the sternocleidomastoid (SCM) muscle, a superficial neck flexor. Subjects (n=75) were divided into three equal groups: patients with neck pain of insidious onset, patients with neck pain due to a whiplash injury, and an asymptomatic control group. EMG amplitude of the SCM was recorded during the standardized (Falla *et al.*, 2003b, Jull *et al.*, 2008) craniocervical flexion test (CCFT), a pressure target test that measures deep neck flexor activity of *m. longus colli* (LC) and *m. longus capitis* (Lca). Raw data from EMG recordings were converted to a root mean square (RMS) value which was used for statistical analysis. EMG output was higher in both of the neck pain groups, which were not significantly different from each other. Pressure test readings (indicating a reduction in strength of *m. longus colli* and *m. longus capitis*) were reduced in the neck pain group, compared to the control group, suggesting that neck flexor muscle activity is altered in patients with neck pain. Falla *et al.* (2004e) used surface EMG to compare myoelectric activity of SCM and anterior scalene (AS) muscles between left and right sides in 10 patients with diagnosed chronic (> one year) unilateral neck pain, at 25% and 50% of maximal voluntary contraction (MVC) into cervical flexion. Logarithmic transformations were used to calculate rates of change between three variables: mean power

frequency, average rectified value and conduction velocity. The results showed a consistently greater slope between mean power frequency with respect to conduction velocity on the ipsilateral side of the pain. The authors concluded that the presence of muscle dysfunction on the same side as the pain was a key finding with respect to design of rehabilitative treatment strategies. The same authors (Falla *et al.*, 2004d) used surface EMG in chronic neck pain patients (n=10) and control subjects (n=12) to measure onset of activity in superficial (AS and SCM) and deep (*m. longus colli* or LC) neck flexors during rapid unilateral arm movements to assess the effect of neck pain on the feedforward neuromotor control system in the cervical spine. In the neck pain group there was a significant delay in activity onset of LC on the ipsilateral and AS and SCM on the contralateral sides, in relation to onset of *m. deltoideus* which functions in arm elevation. The authors suggested that this delay in the feedforward mechanism may impact negatively on spinal stability due to perturbations caused by rapid elevation of the arm, in patients with neck pain and the loss of efficient activation of the perivertebral musculature to stabilize the cervical spine prior to perturbation. Results from a similar controlled study (Falla *et al.*, 2004a) using EMG led the authors to suggest that neck pain appears to cause different activation patterns to superficial muscles in the cervical spine, as assessed by a functional repetitive task (pencil tapping), leading to altered neuromotor control of the upper limb. A later controlled study (Johnston *et al.*, 2008) used measurements from neck range of motion testing, EMG recordings of neck flexor activity during the CCFT and a muscle co-ordination task in female office workers with neck pain, and found that subjects with neck pain showed a reduced range of motion, altered muscle activity patterns during the flexion test and an increase in activity in the extensor muscles compared to the control subjects.

Changes in agonist-antagonist activity of *m. splenius capitis* (SC), *m. sternomastoideus* and *m. trapezius* were recorded by EMG in flexion and extension to 60% of MVC before and after artificially-induced muscle pain by saline injections into *m. splenius* or *m. sternomastoideus* (Falla *et al.*, 2006). Following induction of pain, *m. splenius* showed inhibition during extension and *m. sternomastoideus* showed bilateral inhibition during flexion. In *m. trapezius* an associated increase in activity was observed in extension, and a decrease in activity during flexion. Lindström *et al.* (2011) used EMG to compare the activation and force of SCM and SC in women with neck pain (n=13) and control subjects (n=10) into MVC into flexion, extension and lateral bending, ramped contractions into flexion and extension and circular contractions (horizontal plane). The neck pain patients showed a positive correlation between reduced activity and motor control in different directions, suggesting altered neuromotor control of cervical paraspinal musculature during functional tasks in patients with neck pain.

1.4.2.2 MAGNETIC RESONANCE IMAGING FOR ASSESSMENT OF NEUROMOTOR CONTROL IN THE CERVICAL SPINE

Superficial and deep neck flexor and extensor muscle activity has been assessed by magnetic resonance imaging (MR) in asymptomatic subjects and neck pain patients. Activity of deep (LC, Lca) and superficial (SCM) neck flexor muscles was calculated from tracings around all three muscles from axial MR images that were taken at three different cervical levels in 14 healthy subjects (Cagnie *et al.*, 2011). This MR technique enhances the T2 relaxation time of muscle water after contraction so that patterns and intensity of muscle activity can be evaluated. MR images were obtained at rest and after cranio-cervical flexion exercise, and were compared to

measurements before and after induced muscle pain from a saline injection into *m. trapezius*. Before experimental pain induction Lca and LC were more active during CFF than at rest but after pain induction this activity was reduced bilaterally at multiple levels in both muscles. SCM activity increased unilaterally at one level after pain induction. The authors concluded that onset of neck pain results in immediate alteration of deep and superficial neck flexor muscle activation patterns.

The effect of craniocervical orientation on activation of superficial and deep extensor muscles of the cervical spine was evaluated in 14 healthy subjects, using MR measurements (T2 relaxation times) taken at rest (baseline reading) and directly after isometric cervical extension exercises to 20% maximal voluntary contraction in a neutral position and in a position of 15° extension (Elliott *et al.*, 2010). MR images were used to calculate mean relaxation values of *m. multifidus* (Mul), *m. semispinalis cervicis* (SCe) and *m. semispinalis capitis* (SpC) at three levels in the cervical spine. Significant shifts of increased muscle activity were found for both conditions with greater shifts in the position of increased craniocervical extension. The same methodology was repeated in a later study (O'Leary *et al.*, 2011) to investigate alteration of superficial and deep cervical extensor muscle activity in subjects with chronic mechanical neck pain (n=12). Comparison of data from the two studies (Elliott *et al.*, 2010) indicated that a decrease in shift in activity in Mul, Sce and SpC in the neck pain patients compared to the asymptomatic subjects, but only in the measurements of the activity of isometric contractions in the neutral craniocervical position. The authors suggested that further investigation is warranted to examine alterations in cervical extensor muscle activity in patients with neck pain.

1.4.3 STABILIZING MUSCULATURE OF THE CERVICAL SPINE

Two deep stabilizing muscles of the cervical spine, namely *m. multifidus* and *m. longus colli*, play a pivotal role in stabilization and movement of the intervertebral joints, as well as in facilitation of movement of the head and neck (Mayoux-Benhamou *et al.*, 1994; Kamibayashi and Richmond, 1998; Boyd-Clark *et al.*, 2001; Boyd-Clark *et al.*, 2002; Anderson *et al.*, 2005; Cagnie *et al.*, 2011). Both of these muscles are implicated in people with neck pain (Falla, 2004; Anderson *et al.*, 2005; Rankin *et al.*, 2005; Elliott *et al.*, 2006; Falla and Farina, 2007; Falla *et al.*, 2007; Armstrong *et al.*, 2008; Elliott *et al.*, 2008; Fernández-De-Las-Peñas *et al.*, 2008; Siegmund *et al.*, 2008; O’Leary *et al.*, 2009; Elliott *et al.*, 2010; Cagnie *et al.*, 2011; Javanshir *et al.*, 2011; O’Leary *et al.*, 2011).

In patients with chronic neck pain, CSA of *m. multifidus* appears to be smaller than in non-painful controls (Fernández-de-las-Peñas *et al.*, 2008). Imaging techniques were used to measure the CSA of *m. longus colli* in healthy subjects and patients with chronic neck pain, as dysfunction and reduction in cross-sectional area (atrophy) of this muscle group is associated with chronic neck pain (Kristjansson, 2004; Javanshir *et al.*, 2011). Similarly, low back pain has been linked with atrophy of the deep spinal stabilizer *m. multifidus* in the lumbar region (Kalichman *et al.*, 2010) and this muscle appears to remain dysfunctional even after resolution of pain through medical intervention (Hides *et al.*, 1996).

1.4.4. VALIDITY AND RELIABILITY OF ULTRASONOGRAPHY FOR MUSCLE CSA MEASUREMENT IN THE HUMAN CERVICAL SPINE

Measurement of cross-sectional area (CSA) and left-right symmetry of *m. multifidus* and *m. longus colli* via ultrasonography (US) is a widely-used technique in human clinical and research practices (Kristjansson, 2004; Lee *et al.*, 2007; Whittaker *et al.*, 2007; Jesus *et al.*, 2008; Lee *et al.*, 2009; Javanshir *et al.*, 2010; Peolsson *et al.*, 2012). A decrease in the CSA of *m. multifidus* and *m. longus colli* has been linked with chronic neck pain (Kristjansson, 2004; Fernández-de-las-Peñas *et al.*, 2008, Javanshir *et al.*, 2011). A symmetrical increase in the CSA of these muscles is cited as a key aim in rehabilitative therapy to improve segmental stability of the cervical spine, and to prevent recurrence of episodes of neck pain (Jull *et al.*, 2008; Jull *et al.*, 2009).

In order to prove that US is an objective technique to measure muscle CSA in the cervical spine of patients with neck pain, validity and reliability studies were carried out in asymptomatic subjects and neck pain patients. Kristjansson (2004) measured the CSA of *m. multifidus* at the level of C4 in ten asymptomatic women and in ten women with chronic neck pain. The subjects were matched for height and weight. US imaging was carried out on two separate occasions and by two different ultrasonographers/testers. The asymptomatic group measurements and intra-tester measurements for the symptomatic group showed good agreement, but the inter-tester agreement for the symptomatic group was cited as being ‘questionable’. The technique for muscle CSA measurement of *m. multifidus* at C4 was found to be reliable at this level and the authors suggested that further investigation is warranted to determine whether the CSA of *m. multifidus* can be reliably obtained at other levels in the cervical spine. This was addressed by

Rankin *et al.*, (2005) who made repeated measurements of cervical musculature on one side of the neck at the level of C3, in ten asymptomatic subjects. When two images were taken one week apart by the same tester, high intraclass correlation coefficient results (0.98-0.99) indicated good repeatability for between-images and between-days measurements of the deep paraspinal muscles. The same study used US CSA measurements of the deep cervical spine musculature on left and right sides at the level of C3 from 99 asymptomatic subjects to provide normative data on the shape, size and symmetry of *m. multifidus* in the cervical spine. Symmetry between left and right was strong in this group of asymptomatic subjects. Lee *et al.* (2007) tested the validity and reliability of US image capture of *m. multifidus* at the levels of C4, C5 and C6 by comparing US measurements to MR measurements (thickness, width, area and shape ratio) in ten asymptomatic subjects, during rest and during isometric resistance of the extensor muscles of the cervical spine. Results showed that US has acceptable validity to measure thickness of *m. multifidus* at all of the examined levels. Moreover, US detected changes in *m. multifidus* during contraction, which is an important finding for application in a clinical rehabilitative setting.

Based upon the previous reliability/validation studies, Fernández-de-las-Peñas *et al.* (2008) used US CSA measurements of the cervical spine between C3 and C6 to evaluate muscle CSA and shape ratio dimensions for a blinded comparison of differences in size and shape of *m. multifidus* at different cervical levels between 20 asymptomatic women and 20 women with bilateral chronic neck pain. The muscle CSA in patients with neck pain was found to be smaller at all measured levels compared to the muscle CSA of asymptomatic subjects.

Jesus *et al.* (2008) used US to investigate whether muscle thickness of cervical flexor muscles including *m. longus colli* increased during a craniocervical flexion test. Longitudinal US images

were taken at the anterior aspect of the neck, parallel to the trachea. Images were obtained at resting and after five incremental stages of cervical flexor contraction (as measured by a biofeedback pressure sensor). The authors concluded that the cervical flexor muscles were contracted during the exercise, with a greater increase in thickness evidenced during the final three stages of each trial. It was not possible to discern superficial from deep muscle recruitment. The authors acknowledged the need for validation and reliability-testing of this technique and further studies in neck pain patients, as this may be a non-invasive and objective technique for evaluation of muscle recruitment in patients with neck pain.

Javanshir *et al.* (2011) used transverse US images obtained from asymptomatic subjects (n=15) and patients with bilateral neck pain symptoms (n=10) to test intra-tester within-day and between-days repeatability of US imaging of *m. longus colli*. Images were taken on the left and right side of the neck using the thyroid cartilage as a landmark to determine precise position of the transducer (approximately at the level of C6). Each site was scanned three times; twice on day one of the experiment (with a one-hour interval) and once after one week. Measurements of CSA and posterior and lateral dimensions were used. The results indicated a strong reliability between intra- and inter-day US image acquisitions with a stronger reliability for asymptomatic subjects. The authors recognized that image acquisition was carried out at only one cervical level with *m. longus colli* in a relaxed versus active state, that it was challenging to accurately define the muscular borders on US images and that the two population groups in this study were not optimally matched in terms of age and weight, which may affect findings.

Using US and MR, Cagnie *et al.* (2009) measured the CSA of *m. longus colli* in a group of 27 asymptomatic subjects. In this study, validity of US image acquisition was assessed by

comparing ultrasonographic measurements to MR measurements. Images of the left and right sides were obtained at the level of C5-C6 and muscle CSA was calculated by tracing around the fascial borders of *m. longus colli*. Measurements from the two imaging modalities were used to calculate measurement error. Results showed a considerable variation in agreement between the two imaging techniques, and CSA measurements from MR were larger than those from US (though not significantly), potentially due to challenges in defining intermuscular septae in US images and plane of image acquisition of the two modalities. This led the authors to question the validity of US image acquisition. Reliability of US image acquisition was tested by comparing intra-rater measurements from three separate occasions (at weekly intervals) and inter-rater measurements taken by two separate testers on the first day of the experiment. Independently, both testers also calculated the muscle CSA of *m. longus colli* and *m. sternocleidomastoideus* from the MR images. Both intra- and interrater reliability were found to be moderate, with ‘quite high’ values for standard error of measurement (SEM) and smallest detectable difference (SDD). The authors acknowledged that these findings could be due to only one measurement being taken, versus repeated trials. In addition, the small size of the muscle and challenges in defining the intermuscular septae on images may have contributed to the findings of this study.

A pilot study by McGaugh and Ellison (2011) evaluated intrasession and interrater reliability of US imaging of deep neck flexor muscles, including *m. longus colli*. Muscle CSA of eight subjects (three asymptomatic and five chronic neck pain patients) was measured by two US operators at one level in the cervical spine. Specific anatomical landmarks were used to standardize the position for image acquisition but it was not noted at which level of the cervical spine the images were taken. Both investigators independently captured one image on the left and right side for each subject. This was repeated twice during each session. Each investigator

traced the outline of the muscle group (using the inner border of the fascial delineation) using a keyboard mouse after image acquisition. The computer software calculated the muscle CSA. Intrasection agreement was moderate for rater 1 and good for rater 2, and interrater agreement was acceptable.

Javanshir *et al.* (2010) carried out an eloquent review of literature pertaining to validity and reliability of US imaging of the cervical musculature in asymptomatic and neck pain patients. Based on outcomes from 16 separate studies, a number of key issues were highlighted to optimize validity and reliability. To improve validity, suggestions included the need for a standardized imaging protocol with reference to patient positioning, the use of specific anatomical landmarks to guide US image capture (requiring an in-depth knowledge of the anatomy of the region under investigation) and standardized positioning of the ultrasound probe (plane of position). The authors suggested that measurement error could be minimized through US imaging by one tester only, as intra-tester reliability is known to be good. It was also noted that gold-standard imaging with MR could prove less than ideal for a direct comparison with US images due to different planes of capture and patient positioning for the two modalities, especially when identifying small and deep muscles, as well as the fact that MR offers more intramuscular detail such as fatty infiltrate (thought to be associated with chronic cervical dysfunction due to whiplash associated disorders). This is potentially difficult to distinguish from muscle on US image, and could affect delineation of the intermuscular septae. For optimal reliability, inter-rater reliability should be tested where more than one assessor carries out US imaging, appropriate statistical testing should be applied and controls and subjects should be closely matched to minimize additional effect of variables when comparing population groups. Finally, it was suggested that further research is warranted to determine the effect of unilateral

cervical dysfunction on muscle CSA, as the abovementioned studies only examined patients with bilateral neck pain and/or dysfunction.

1.4.4.1 VALIDATION AND RELIABILITY OF ULTRASONOGRAPHY FOR MUSCLE CSA MEASUREMENT IN THE PERIVERTEBRAL MUSCULATURE OF THE EQUINE SPINAL COLUMN

Ultrasonographic imaging (US) has been identified as a non-invasive and reliable tool to measure muscular dimensions and has been found to be useful for objective evaluation of the perivertebral musculature of the spinal column in people in relation to spinal dysfunction. To date little is known about the relationship between spinal dysfunction and perivertebral muscle (dys)function in the horse, although osseous pathology of the thoracolumbar column and back pain are known to be limiting factors in sport horse performance (Jeffcott, 1980; Haussler, 1999b; Denoix and Dyson, 2003; Wennerstrand *et al.*, 2004; Murray *et al.*, 2006; Wilsher *et al.*, 2006; McGowan *et al.*, 2007; Goff *et al.*, 2008; Girodroux *et al.*, 2009; Haussler *et al.*, 2009; Meehan *et al.*, 2009; Cousty *et al.*, 2010, Stubbs *et al.*, 2010, Cousty *et al.*, 2011).

To date only one study has addressed the potential association between osseous pathology and dysfunction of the adjacent paravertebral musculature in the equine spine. Stubbs *et al.* (2006) investigated and described the functional anatomy of the thoracolumbar and lumbosacral regions of the equine vertebral column in 120 subjects, including 65 Thoroughbred racehorses, with the specific aim of increasing knowledge of vertebral anatomy and biomechanics as a potential link to equine back pain and subsequent loss of athletic performance. The spines were examined

using MR (n=3), anatomical dissection (n=11) and biomechanical analysis (n=6) of the epaxial musculature. *M. multifidus* was described in detail, and based upon its anatomical morphology and biomechanical properties the authors suggested that its function is similar to that in man, namely, to provide dynamic segmental stability.

In a group of 22 Thoroughbred racehorses, Stubbs *et al.* (2010) confirmed a significant association between the presence of osseous spinal pathology and reduced CSA of *m. multifidus* in the equine thoracolumbar spine. Ultrasonographic measurements of the CSA of *m. multifidus* were reliability-tested and subsequently validated against MR (the accepted ‘gold standard’) as an objective measurement technique in the equine thoracolumbar spine (McGowan *et al.*, 2007) of the live horse. The authors suggested that ultrasonography of this muscle group is potentially a useful tool to identify spinal pathologies in the thoracolumbar spine of the horse. This is an important finding since spinal disease and dysfunction in the thoracolumbar spine of people can be identified through ultrasonographic detection of atrophy of *m. multifidus* (Hides *et al.* 1996, 2001; Kalichman *et al.*, 2009). This technique also has an application in evaluation of the efficacy of therapeutic exercises implemented for re-activation and retraining of dysfunctional perivertebral musculature associated with spinal lesions. When atrophy is present due to osseous pathology, retraining is necessary to prevent further damage as a consequence of spinal instability.

Validation of US as a valid and reliable method to measure CSA of the stabilizing musculature of the equine cervical spine would provide a valuable tool for identification and rehabilitation of lesions in this anatomical region. Berg *et al.* (2003) used US images from eight live horses (clinically free from lameness or pathology in the cervical spine) to describe the normal

appearance of anatomical structures and identify muscle borders in the cervical segment from C2 to T1, using transverse US images taken at each cervical level. Post-mortem the muscular borders were confirmed by identification of intermuscular septae on cross-sectional slices of the cervical spine of all subjects. On US images, *m. multifidus* was cited as challenging to image due to the presence of ‘tendinous strips difficult to differentiate from fascia’. *M. longus colli* was identified on US images, but only as far caudal as the level of C4, and was also cited to be challenging to identify, both in US imaging and in dissection. The only other study of US in the cervical spine was carried out by Gollob *et al.* (2002), where the atlanto-occipital joint was examined with US to describe the anatomy in this region, and to design a technique to aid diagnosis of pathology in this joint. To date there is no reported validation or reliability for the use of US to measure CSA of the deep stabilizing musculature of the equine cervical spine, nor have there been any studies linking osseous pathology with muscular dysfunction of the deep spinal stabilizing muscles in the equine cervical spine. The study in Chapter 4 of this thesis describes the validation, reliability and repeatability within and between operators of US as an objective technique to measure CSA of *m. multifidus* and *m. longus colli* in the equine cervical spine.

1.4.5 DYNAMIC REHABILITATION FOR EQUINE CERVICAL DYSFUNCTION

In people, specific active mobilization and stabilization exercises have been shown to reactivate *m. multifidus* and *m. longus colli* and reduce the rate of recurrence of back (Hides *et al.*, 1996; Hides *et al.*, 2001, Kavcic, 2004, Hodges and Cholewicki, 2007) and neck pain (Bronfort *et al.*, 2001; Jull *et al.*, 2002, Jull *et al.* 2008; Jull *et al.*, 2009). Ultrasonography has been reported to be a

useful measurement tool in the assessment of thoracolumbar injuries in horses, and in evaluating the effects of treatment based on measurements of left:right asymmetry of *m. multifidus* CSA as an indicator of spinal dysfunction (McGowan *et al.*, 2007; Stubbs *et al.*, 2010). Following on from findings in people with low back pain (Hides *et al.*, 1994; Hodges *et al.*, 2006), a study in 22 horses showed ipsilateral atrophy of *m. multifidus* at the same thoracolumbar levels as osseous pathology (Stubbs *et al.*, 2010).

Regular performance of dynamic mobilization exercises has been shown to increase *m. multifidus* CSA from T10 to L5 (Stubbs *et al.*, 2011). Eight clinically-sound horses performed five repetitions of mobilization exercises five days per week, over a three-month period. The exercises consisted of three cervical flexion positions, one cervical extension position and three lateral bending positions to left and right sides. The CSA of *m. multifidus* was measured through US image acquisition of *m. multifidus* on the left and right sides at six levels in the thoracolumbar spine. US images were taken at the start and at the end of the study. Three images were taken at each side and level, and the CSA of each image was measured blindly three times. Statistical results were based on multiple images and measurements. In comparing the US images from the beginning and end of the study, the CSA of *m. multifidus* increased at all spinal levels and asymmetry of CSA decreased. This is an important finding, as an increase in muscle size of perivertebral stabilizing musculature is a key aim of therapeutic rehabilitative programs in people with back and neck pain.

1.5 PAIN AND ITS EFFECT ON BEHAVIOR IN THE HORSE

Pain in animals is considered to be a ‘stressor’ (Moberg, 2000), defined by the author as ‘the biological response elicited when an individual perceives a threat to its homeostasis’. Homeostasis, or the process by which the body maintains a state of stable physiological equilibrium, can be negatively affected in animals by pain, resulting in stress and adaptive behavioral manifestations (Bracke and Hopster, 2006). Objective measurement of pain in animals has been long recognized as a challenge. Difficulties in obtaining reliable and repeatable measurements that are reflective of a state of pain in animals include inter-species difference in responses to pain caused by injury or disease and, importantly, the fact that assessment of pain in animals cannot be based on a direct comparison of mechanisms and behavior observed and measured in people with pain (Bateson, 1991; Short, 1998). Means to assess pain in animals include clinical assessment, physiological measurements and behavioral responses (Short, 1998; Rutherford, 2002; Mogil, 2009). As self-measurement of pain is not possible in animals (Mogil, 2009), it is suggested that increased magnitude of pain measurement responses, including behavioral changes, indicate a greater significance of the perceived pain to the animal (Rutherford, 2002). With specific reference to the use of animal models for pain testing, Mogil (2009) suggested that behavioral evaluation of pain should not be based solely on withdrawal responses as these are not reflective measures of pain, but rather of hypersensitivity, and thus potentially less valid in a clinical setting. Spontaneous reactions are thought to be a more reliable indicator of presence of acute clinical pain, whereas more complex behavioral changes could be associated with chronic pain.

1.5.1 MEASUREMENT OF PAIN IN THE HORSE

The symbiotic relationship between pain and behavior in horses has been recognized by the veterinary professional as an adjunct factor in clinical examinations (Short, 1998; Houpt and Mills, 2006; Driessen and Zaruco, 2007). There have been a number of studies that have aimed to assess pain in the horse using various types of objective measures.

In an early epidemiological study, questionnaires were used to obtain information about veterinarian attitude to pain in the horse (Price *et al.*, 2002), and based on the results of this preliminary investigation it was concluded that differences existed within the sample group in interpretation of pain in the horse, and how to address this in a clinical setting. Disparities were noted within the group of respondents between pain scores (observations of low severity versus high severity of pain), and observations of demeanor (attitude and behavior) and heart rate measurements in different clinical conditions, with a lack of consensus as to the definition of pain behavior in the horse.

Physiological measurements of heart rate, respiratory rate and plasma cortisol levels (which are known to rise with stress and/or pain) were collected in a group of 27 horses (Pritchett *et al.*, 2003) in an attempt to identify indicators of post-operative pain after exploratory colic surgery. Surgery cases (n=7) showed significantly higher heart rate readings and plasma cortisol levels compared to the control group (n=10) and the placebo/non-surgery group (n=10).

Reaction times to thermal dermal stimuli, applied manually with a copper probe, were used to evaluate pain responses in a blinded, randomized, prospective experimental cross-over study in seven healthy horses, for comparison of the efficacy of caudal epidural anesthesia between

methadone and lidocaine (Olbrich and Mosing, 2003). The authors questioned whether the horse's inherent sensitivity to tactile stimuli and the known 'learning effect' could have influenced the results of this study.

Rietmann *et al.* (2004) used heart rate variability and stress catecholamine (adrenaline and noradrenaline) levels as measures to monitor pain in horses with laminitis (n=19), before and after treatment with non-steroidal anti-inflammatory drugs (NSAIDs). Based on measurement outcomes, the authors suggested that heart rate variability was a non-invasive and more useful technique to measure stress responses as related to pain, but cautioned that heart rate can also be affected by non-pain related factors. Plasma cortisol levels were measured by Sellon *et al.* (2004) in a randomized, controlled and blinded trial of horses (n=16 control, 15 treatment) undergoing celiotomy (an incision in the wall of the abdomen). It was hypothesized that the administration of butorphanol (a synthetic opioid analgesic) to enhance pain control in the treatment group would have an effect on physiological parameters. The subjects in the treatment group were found to have significantly lower plasma cortisol levels than those in the control group, suggesting that the enhanced pain management protocol had a positive effect on plasma cortisol levels, thought to be associated with pain.

Bussi res *et al* (2008) designed a controlled study using induced pain (inflammatory synovitis) in 18 horses to develop a composite orthopedic pain scale, including evaluation of physiological parameters and behavioral observations to place subjects in the category of 0 (no pain) to 3 (the greatest change in physiological measurements and behavioral observations in relation to intense pain). The authors concluded that physiological parameters including heart rate, were not considered to be valid indicators of pain, though they acknowledge that the small group sizes of

the different treatment conditions may have influenced the results. This statement reiterates the suggestion by Raekallio *et al.* (1997) and Taylor *et al.* (2002) that physiological parameters such as heart rate, beta-endorphin levels and cortisol concentration should not be taken as completely objective stand-alone measures of pain in the horse as there are a number of potential reasons for alterations to these parameters, aside from pain.

A modified composite pain scoring system, which included physiological parameters of heart and respiratory rate, the Obel laminitis pain scale and evaluation of behavioral manifestations, was used to identify inflammatory and neuropathic pain states in a horse with chronic laminitis (Dutton *et al.*, 2009). The authors suggested that multiple observers were in agreement of pain scoring with the pain scoring system, and that changes in the scores over the course of the treatment were reflective of the analgesic therapy. Lindegaard *et al.* (2010) used a visual analogue scale (VAS) and a composite measure pain scale (CMPS) to evaluate pain in induced radiocarpal synovitis in eight adult horses, in a blinded, randomized study with cross-over design. Inter-observer agreement between two observers was measured, as was agreement between the readings from the VAS and CMPS. The CMPS was suggested as a useful means for repeatable and reproducible pain scoring, although the authors questioned the validity/sensitivity in assessment of low-level pain.

Though a number of useful models exist for assessment of pain in the horse, it is acknowledged that pain is likely to be an individual experience in animals just as it is in people, and it has been questioned whether measurements or observations of pain in the horse could be reflections of nociceptive responses as opposed to actual experiences of pain (Taylor *et al.*, 2002).

1.5.2 BEHAVIORAL MANIFESTATIONS OF PAIN IN THE HORSE

Pain in horses has been measured subjectively through identification of specific behavioral manifestations, and behavioral evaluation is strongly advocated as an adjunct to clinical and physiological measurements as manifestations such as reaction to palpation and alterations in temperament, posture and locomotion may be related to the presence of pain (Short, 1998; Ashley *et al.*, 2005). It is essential that normal behavior should be understood in order to interpret any behavioral changes where these may be related to pain (Taylor *et al.*, 2002; Pritchett *et al.*, 2003), and that differentiation should be made between acute and chronic pain (Love, 2009).

Raekallio *et al.* (1997) used behavior as a subjective tool to evaluate post-operative pain after orthopaedic surgery in 13 horses. Use of the operated leg, neck position and ground pawing were evaluated by one examiner at pre-determined intervals before and after surgery. Based upon these observations each horse received an overall subjective pain score. No significant differences were noted in the behavioral evaluations pre-and post-surgery, but the post-operative pain score was higher than the pre-operative pain score. The authors acknowledge that this was not a blinded study, nor was it detailed what the subjective pain score entailed other than that this was based on clinical experience and personal judgment of the examiner.

Following a pilot study to determine behavior in normal horses and horses recovering from abdominal surgery, Pritchett *et al.* (2003) designed a controlled study which used a numerical rating scale (NRS) and time budget evaluation/length of time for which a specific behavior is performed (for visual scoring from video tapes) of 27 horses to identify changes in behavior due to post-surgical pain. The subjects were divided into a control group (n=10), a placebo group that

underwent anesthesia (n=10) and a surgery group (n=7). Data collection started at time of presentation or surgery. The NRS was based on the total amount of behaviors that were observed (divided into posture and socialization scores). Time budgets (divided into active, locomotion, pain or resting phases) were based on randomized video assessments performed by two trained observers, one of whom was blinded to the subjects and the study aims. For the NRS, the surgery group had a significantly higher score than the other groups. According to the time budgets, the surgery group was least active and most restful, compared to the other groups, and it was the only group that displayed pain behavior. According to the authors, reduced locomotion and increased pain behaviors (such as pawing and looking at the flank) were indicative of pain following surgery.

A prospective clinical study of 12 horses (six horses that underwent arthroscopy and six pain-free control horses) used behavioral parameters to assess post-operative pain (Price *et al.*, 2003). Direct observation by a single examiner assessed posture (including ear, head and tail position as well as oral behavior and activity/position in the stable) for the two groups. The ear, and head positions and muzzle activities were significantly different (greater) in the surgery subjects than in the control group pre-surgery, and were increased in post-surgery observations for lower head position and lower lip tension. Instantaneous time sampling video recordings at set intervals were used to identify the time budget of the subjects from 24 hours pre-surgery to 48 hours post-surgery. Using pre-defined event behaviors (including posture, position in stable, eating, lying down, locomotion and abnormal behaviors), surgery horses spent more time away from the front of the stable, less time eating and more abnormal postures and behaviors than the control group. The authors suggested that direct observation and evaluation of time budgets could be sensitive indicators of presence of post-operative pain in horses.

Olbrich and Mosing (2003) suggested that avoidance movements of the head, neck, trunk, limbs and tail could be classed as positive pain responses to direct thermal dermal stimuli in the caudal region of the horse, when compared to responses from horses who received caudal epidural analgesia.

Sellon *et al.* (2004) evaluated behavior related to pain in 31 horses divided into a treatment group (n=16) that received pain management and a control group (n=15) that received a placebo treatment, following exploratory abdominal surgery. A numerical rating scale (NRS) was used to calculate a sum of scores for nine different behaviors thought to be related to pain. These included gross pain behavior, position of the head and ear, location in the stable, locomotion, response to stable door opening, response to lifting of a front foot and response to an offer of food. Behaviors were evaluated at set time intervals, up to 72 hours following surgery and within 24 hours of discharge from the clinic. The mean behavior scores for the treatment group were lower than those for the control group within 24 hours following the surgery, suggesting less pain.

In a repeated-measures study design, 19 horses with laminitic pain were examined before and after administration of non-steroidal inflammatory drugs (NSAIDs), for time frequency of weight-shifting between contralateral limbs (to alleviate the affected foot). Each horse served as its own control for measurements that were taken on day one of the study, and on day 7 following treatment. Continuous video recordings were taken from within the stable of each horse. Data evaluation showed a decrease in weight-shifting at recordings after one hour and after seven days following treatment with NSAIDs, suggesting a decrease in pain. The authors acknowledged that interpretations of behavior can differ between assessors, and that video

recordings and knowledge of behavior are essential for production of objective data (such as from a numerical rating score) when attempting to quantify pain in the horse. This was also emphasized by Driessen and Zarucco (2007), in the suggestion that direct or recorded behavioral observations should be carried out frequently and/or over longer periods of time as brief subjective evaluations of behavior may not be sufficiently sensitive to link behavioral manifestations to pain in the horse.

Bussi res *et al.* (2008) used behavioral indicators to evaluate pain intensity to aid in the design of a composite orthopaedic pain scale in horses. Eighteen horses were divided into six groups, including three control groups, and three groups with artificially-induced synovitis of the tarsocrural joint, all of which were administered with different analgesic treatments. Video recordings were made of each horse in its stable (undisturbed state), followed by palpation over the tarsocrural region by a single assessor who was blinded to the control and treatment subjects. The assessor scored each horse according to the pain scale that was designed for this study. The video recordings were used in a double-blinded assessment by experienced animal behaviorists. Inter-observer reliability was tested to determine whether the behavioral assessments were repeatable. Based on identical repeated assessments, the behavioral indicators were deemed to be repeatable. Behavioral parameters that were found to be sensitive to repeated testing/evaluation included posture, pawing on the floor, head movement, kicking at the abdomen and appearance, with palpation of the painful region being the most specific behavioral indicator.

In a case report of management of foot pain caused by acute subsolar seroma and chronic laminitis, a composite pain scoring system was used, which included behavioral responses to multimodal analgesia administration during acute and chronic phases (Dutton *et al.*, 2009).

Observations of behavior were used to grade pain. Restlessness, position in the stable, resistance to handling and patterns of locomotion were included in the grading system, which was adapted from systems used in previous studies. The authors concluded that there was consistency in multi-observer scoring, and that scores changed in an expected pattern according to intensity of the analgesic treatment.

In a blinded, randomized controlled study using eight Warmblood mares (van Loon *et al*, 2010), an orthopaedic pain model was used to assess the effects of intra-articular administration of morphine (a drug with analgesic and anti-inflammatory properties) on pain associated with artificially-induced synovitis in the talocrural joint. Each subject underwent treatment with analgesia and a placebo treatment. Categories of behavior included eating, walking, standing still, lying down, rolling and shifting of weight. Video scoring was used for each subject to evaluate reaction to approach by an assessor and limb loading, followed by palpation of the region of interest on both hind limbs. The placebo group showed significantly greater reaction to palpation, spent less time eating and weight bearing on the affected limb, and more time lying down, compared to the treatment group. The authors suggested that these behavioral manifestations should be taken into consideration in composite pain assessment in horses.

Mansmann *et al.* (2011) used a survey response (n=17) from professional farriers to identify specific behaviors that were observed in horses that demonstrated poor behavior during farrier work. Based on the responses, behaviors were broadly categorized as defensive/evasive or offensive/aggressive. Using these behavioral responses, 11 horses with clinically diagnosed conditions in the foot (or multiple feet) were evaluated for altered behavior during farrier work.

The authors suggested that pain appeared to be the stimulus for the undesirable behavior, and that these behaviors were less evident after intervention with pain relief.

1.5.2.1 IDENTIFICATION OF SPINAL PAIN IN HORSES

Spinal dysfunction in horses is known to have a negative effect on performance. Behavioral assessments in clinical cases with spinal pain have become a topic of interest alongside manual palpation, as an adjunct to diagnostic evaluation in the spinal column. Mechanical nociceptive threshold (MNT) testing through pressure algometry (PA) has been suggested as a non-invasive method to identify and quantify sensitivity in the equine spine (Haussler and Erb, 2006; Varcoe-Cocks *et al.*, 2006; Sullivan *et al.*, 2008; Haussler, 2009; Goff, 2009; Paulekas and Haussler, 2009; de Heus *et al.*, 2010). Pressure algometry involves direct manual pressure from the rubber tip of an algometer with a force gauge. Pressure is applied perpendicular to the area of testing and can be reported as kg of force/cm² or as Newton per millisecond (N/ms). The point where a horse shows an avoidance reaction to gradually increasing direct pressure is referred to as the MNT. A lower MNT is thought to reflect higher sensitivity or a pain response.

Pressure algometry was used to test for MNT in a group of 36 horses without acute back pain or lameness, at 62 anatomical landmarks along the axial skeleton (Haussler and Erb, 2006). Repeatability of the measurements was tested through three repetitions of the measurements at 3-4 second intervals, and anatomical locations were evaluated symmetrically to identify any differences between left and right sides. Local avoidance reactions included skin twitching, muscular contraction, induced lordosis or stepping away from the pressure. The exact anatomical

locations of MNT testing were very clearly described. Pressure algometry was suggested as a repeatable technique for MNT testing, based on the measurements from the three readings which evaluated trends (adaptation, sensitization or no change in reaction) and prevalence (combined across all horses and all sites of testing) of reactions. No significant differences were found between left and right sides. Based on these findings, Haussler and Erb (2006) used PA for MNT/musculoskeletal pain testing in a group of 20 horses (over a two-year period) with artificially-induced back pain through temporary implantation of fixation half-pins into dorsal spinous processes of the thoracolumbar spine. A reduction in the MNT/pain threshold at and around the implantations sites was identified through PA measurements, which revealed reduced MNT readings compared to those taken at non-painful sites. The authors acknowledged potential shortfalls in the study due to non-blinding of the PA examiner, pooling of all the data for all the horses versus individual pain matrix scoring and the influence of the non-steroidal anti-inflammatory drugs that were administered to the horses to prevent inflammation following the induction of back pain. No references were made to behavioral reactions to MNT testing/assessment of pain.

Varcoe-Cocks *et al.* (2006) used PA to determine intra-observer repeatability and reliability of MNT testing for muscle pain in racehorses with suspected sacroiliac joint dysfunction (SID), in order to add objective measurements of pain to manual palpation for muscular sensitivity. Reliability was established through four repeated PA measurements that were taken bilaterally at four different paraspinal locations in the thoracolumbar spine of 12 horses, and PA was found to be a reliable technique for repeated MNT testing.

In the second part of this study, pressure algometry was carried out in 15 horses (including five control horses without signs of SID), at four different bilateral anatomical locations in a caudal direction from the thoracolumbar spine. Horses were scored clinically for signs of SID by one examiner before undergoing PA testing and manual palpation by another examiner who was proficient in the use of the pressure algometer. Subjects with clinical signs of SID had lower MNT measurements and showed differences between readings of the left and right sides as compared to the control horses. The correlation between PA measurements and grade of SID as well as response to manual palpation was significant. No references were made to observations of behavioral manifestations during MNT testing or manual palpation.

Pressure algometry was used to investigate the possibility of quantifying sensitivity along the neck and back in six clinically sound horses that were randomly assigned to a control group (n=3) and a treatment group (n=3) that underwent grading of neck and back dysfunction in terms of temperature, pain, muscle tone and mobility, in a randomized order by three different experienced equine physiotherapists. PA measurements were taken separately by a different examiner (experienced in the operation of the pressure algometer) who remained blinded to the PA readings. MNT testing was carried out at predetermined anatomical landmarks along the spinal column, some bilateral and some directly over the dorsal spinous processes (thoracic spine). Pressure was maintained until a behavioral avoidance reaction was observed, including withdrawal movement and facial expressions. This is the first study where manual palpation of the neck and back was also graded according to a pain scoring system, correlating behavioral expressions to sensitivity on manual palpation. The agreement between the manual palpation by the three physiotherapists was highest for the category of pain, and horses with increased sensitivity to manual palpation had lower MNT readings as quantified by the PA measurements.

This is also the first study to report that there was a high variation in MNT between individual horses, acknowledging the individual pain matrix for each horse and highlighting the fact that inter-horse MNT readings are not reliable indicators of individual sensitivity/pain. However, variation between readings on left and right sides was not significant, suggesting that bilateral measurements may be useful in the identification of unilateral lesions. The authors acknowledged that it was challenging to maintain a constant pressure in PA measurements which may influence the repeatability of results, and that some horses may have anticipated the PA procedure (a learned behavior) in the cervical spine as head-shaking was evident in some cases. However, expressions of sensitivity of pain/sensitivity to palpation correlated with PA measurements, which could have useful future applications in clinical settings for identification and evaluation of spinal dysfunction in the horse.

1.5.2.2 ETHOGRAM USE FOR PAIN EVALUATION IN THE HORSE

An ethogram can be defined as list or inventory of behavioral elements specific to a species, with emphasis on specific behaviors observed under a certain condition (McDonnell and Haviland, 1995). A specialized ethogram is useful to study individual animals in a specific context. In an elaborate study, McDonnell and Haviland (1995) developed an ethogram of behavior in a group of domestic pony stallions, through observations from video recordings. The final ethogram included identification of interactive behaviors, complex behavior sequences and vocalizations. The descriptions for each behavior were annotated succinctly, referenced to previous studies where applicable, and accompanied by a drawing of the posture/behavior that was observed.

These clear descriptions in this ethogram can be used in practical research settings, and lack of ambiguity will aid in identification of behavior in future studies.

Simplified ethograms of behavior have been used as part of studies in clinical settings to aid equine diagnostics and monitor pain. Pritchett *et al.* (2003) differentiated behavior categories to identify post-operative pain behaviors in a control, placebo treatment and surgery group of 27 horses. Behaviors included position of head and ears, location in the stall, responses to human approach, spontaneous movement/locomotion and lifting of feet. The authors used a numerical rating score to grade observations of behavior to identify which behaviors may be related to pain. The descriptions of each behavior were succinct but sufficient for repeated identification by different observers. The observational data were combined with physiological measurements which were used to quantify stress (related to pain) in the subject group.

Price *et al.* (2003) used a similar ethogram to assess post-operative pain in a group of six treatment and six control horses. Categories for the evaluation of the time budgets included position, locomotion, lying down, eating and abnormal behaviors (which were not identified individually but grouped as a whole). The ethogram for event behaviors was elaborate with clear definitions for each behavior. For example, leg movements were differentiated into pawing, knocking, stamping, lifting or kicking, with a clear definition of each movement. Similarly, head movements were divided into shake, swing or toss, each with its own definition to differentiate between the movements. The two groups were also assessed on physiological measurements of heart and respiratory rate. The results were collated for future design of a composite pain scoring system to monitor post-surgical pain in horses and the authors emphasized that both

behavioral and physiological characteristics should be considered for a functional and consistent system monitoring system.

A very basic ethogram of behaviors related to thermal dermal stimulation along the lower back/quarters of horses who underwent testing with two different types of epidural analgesia (Olbrich and Mosing, 2003) used a score from grade 1 to 3 to categorize increase in demonstration of aversive behaviors related to dermal stimulation, along with scoring of head position (grade 1 to 3) and body posture/ataxia (grade 1 to 4). Although the abstract referred to pain responses in terms of specific avoidance movements and expressions of aggression, these points were not referred to or elaborated upon in the main body of the study.

Sellon *et al.* (2004) evaluated the effects of pain management through analgesic treatment in two groups of horses (treatment and control), following abdominal surgery. Nine different behaviors were identified for scoring, but no definitions were given to clearly describe each behavior.

Based on a review of publications and proceedings, Driessen and Zarucco (2007) produced a useful ethogram of behaviors observed in horses with different forms of pain. The authors categorized the behaviors broadly into acute, chronic, musculoskeletal and visceral/abdominal pain and listed behaviors for each category, but did not offer a definition for each behavior.

Behavioral observations were part of the design and validation of a composite pain scale for assessment of acute orthopaedic pain in horses (Bussi res *et al.*, 2008). The authors included five categories of behavior and provided a clear definition for the criteria of grading the behavior within each category.

Mansmann *et al.* (2011) based responses (n=17) from a questionnaire survey to design an ethogram of poor behavior observed in farriery in horses. Two groups of behavior were identified (defensive/evasive action and offensive/aggressive action). Each group was further divided into specific behaviors, with a clear definition for each behavior.

1.5.2.3 ETHOGRAM USE IN EVALUATION OF PAIN RELATED TO SPINAL DYSFUNCTION IN THE HORSE

Fureix *et al.* (2010) used behavior alongside manual chiropractic vertebral examination in 59 horses. A standardized test divided behaviors into broad categories of threats or positive behaviors, but though examples of behaviors were listed for each category, no detailed descriptions were given for each behavior. Subjects were classed to be aggressive or non-aggressive, based upon behavioral observations.

Aside from a brief reference to some broad examples of behavioral responses included in palpation scoring alongside MNT testing using PA (Varcoe-Cocks *et al.*, 2006), there are currently no published ethograms that clearly identify, define and describe behaviors observed in examination and/or treatment of horses with spinal dysfunction or pain. As the relation between equine behavior and pain is recognized in clinical settings, an increased understanding of specific behaviors related to pain is an essential factor in clinical examination and for enhanced evaluation of progress in rehabilitative programs. For this reason I designed a study to identify and define specific behaviors that may be observed in examination of horses with neck pain, as

this knowledge may enhance clinical examination of horses with a suspected dysfunction of the cervical spine.

Based on review of the literature pertaining to dysfunction and/or pain in the equine cervical spine, a number of gaps in knowledge were identified. In order to address some of these aspects, I designed a series of studies to further knowledge on this complex phenomenon. The first study was designed describe the detailed morphology of two perivertebral stabilizing muscles in the equine cervical spine, namely *m. multifidus cervicis* and *m. longus colli*, both of which have been extensively researched with reference to their key role in human neck pain. The second study was designed to identify the prevalence and severity of osseous degenerative lesions in the APAs of the equine cervical spine, with the hypothesis that these lesions are more prevalent and severe in the cervicothoracic region of the equine cervical spine with an equal distribution between the left and right sides, and that lesions are more prevalent in severe in older and larger horses. The third study was designed to validate the use of ultrasonography for objective measurement of the cross-sectional area of *m. multifidus cervicis* and *m. longus colli* in the equine cervical spine, with the hypothesis that ultrasonography can be used as a repeatable objective measurement technique within and between different US operators. The fourth study was a pilot study to design an ethogram of behaviors, based on the observation of behaviors during manual assessment of horses with neck pain. I hypothesized that specific aversive behaviors could be identified during manual assessment of the equine cervical spine in horses with diagnosed neck pain, and that manual assessment techniques could accurately identify horses with diagnosed neck pain. The findings from this series of studies will serve as a contribution to current knowledge on dysfunction of the equine cervical spine.

BIBLIOGRAPHY

BIBLIOGRAPHY

- Adams, S. B., Steckel, R., Blevis, W. (1985) Diskospondylitis in five horses. *Journal of the American Veterinary Medical Association*, 186 (3), 270-272.
- Anderson, J. S., Hsu, A. W., Vasavada, A. (2005) Morphology, architecture and biomechanics of human cervical multifidus. *Spine*, 30(4), 86-91.
- Armstrong, B., McNair, P., Taylor, D. (2008) Head and neck position sense. *Sports Medicine*, 38(2), 101-117.
- Ashley, F. H., Waterman-Pearson, A. E., Whay, H. R. (2005) Behavioral assessment of pain in horses and donkeys: application to clinical practice and future studies. *Equine Veterinary Journal*, 37(6), 565-575.
- Azar, N. R., Kallakuri, S., Chen, C., *et al.* (2009) Strain and load thresholds for cervical muscle recruitment in response to quasi-tensile stretch of the caprine C5-C6 APA joint capsule. *Journal of Electromyography and Kinesiology*, 19, 387-394.
- Bakker, D. A., Richmond, F. J. R. (1982) Muscle spindle complexes in muscles around upper cervical vertebrae in the cat. *Journal of Neurophysiology*, 48(1), 62-74.
- Barrey, E., Hermelin, M., Vaudelin, J. L., *et al.* (1994) Utilisation of an accelerometric device in equine gait analysis. *Equine Veterinary Journal*, 26(Suppl.17), 07-12.
- Bateson, P. (1991) Assessment of pain in animals. *Animal Behavior*, 42, 827-839.
- Beck, C., Middleton, D., Maclean, A., *et al.* (2002) Osteochondrosis of the second cervical vertebra of a horse. *Equine Veterinary Journal*, 34(2), 210-212.
- Bennett, G. J. (2000) Update on the Neurophysiology of Pain Transmission and Modulation: Focus on the NMDA-Receptor. *Journal of Pain and Symptom Management*, 19, Supplement 1(1), 02-06.
- Berg, L. C., Nielsen, J. V., Thoenner, M. B., *et al.* (2003) Ultrasonography of the equine cervical region: a descriptive study in eight horses. *Equine Veterinary Journal*, 35, 647-655.
- Birmingham, S. S. W., Reed, S. M., Mattoon, J. S. *et al.* (2010) Qualitative assessment of corticosteroid cervical articular facet injection in symptomatic horses. *Equine Veterinary Education*, 22(2), 77-82.
- Bland, J. H., Boushey, D. R. (1990) Anatomy and physiology of the cervical spine. *Seminars in Arthritis and Rheumatism*, 20(1), 1-20.

Bogduk, N., Marsland, A. (1988) The cervical zygapophysial joints as a source of neck pain. *Spine*, 13(6), 610-617.

Bogduk, N., Mercer, S. (2000) Biomechanics of the cervical spine. I: Normal kinematics. *Clinical Biomechanics*, 15, 633-638.

Bogduk, N., Yoganandan, N. (2001) Biomechanics of the cervical spine. III: Minor Injuries. *Clinical Biomechanics*, 16(4), 267-275.

Bollwein, A., Hänichen, T. (1989) Age-related changes in the intervertebral disks of the cervical vertebrae of the horse. *Tierärztliche Praxis*, 17(1), 73-76.

Bovim, G., Shrader, H., Sand, T. (1994) Neck pain in the general population. *Spine*, 19(12), 1307-1309.

Boyd-Clark, L. C., Briggs, C. A., Galea, M. P. (2001) Comparative histochemical composition of muscle fibers in a pre-and a postvertebral muscle of the cervical spine. *Journal of Anatomy*, 199, 709-716.

Boyd-Clark, L. C., Briggs, C. A., Galea, M. P. (2002) Muscle spindle distribution, morphology and density in longus colli and multifidus muscles of the cervical spine. *Spine*, 27(7), 694-701.

Bracke, M. B. M., Hopster, H. (2006) Assessing the importance of natural behavior for animal welfare. *Journal of Agricultural and Environmental Ethics*, 19, 77-89.

Bronfort, G., Evans, R., Nelson, B., *et al.* (2001) A randomized clinical trial of exercise and spinal manipulation for patients with chronic neck pain. *Spine*, 26(7), 788-797.

Buchner, H. H. F., Savelberg, H. H. C. M., Schamhardt, H. C., *et al.* (1997) Inertial properties of Dutch Warmblood horses. *Journal of Biomechanics*, 30(6), 653-658.

Buchner, H. H. F., Savelberg, H. H. C., Schamhardt, H. C. *et al.* (1996) Head and trunk movement adaptations in horses with experimentally induced fore-and hind limb lameness. *Equine Veterinary Journal*, 28, 71-76.

Bussi res, G., Jacques, C., Lainay, O. *et al.* (2008) Development of an orthopaedic pain scale in horses. *Research in Veterinary Science*, 85, 294-306.

Cagnie, B., Derese, E., Vandamme, L., *et al.* (2009) Validity and reliability of ultrasonography for the longus colli in asymptomatic subjects. *Manual Therapy*, 421-426.

Cagnie, B., D'Hooge, R., Achten, E. *et al.* (2010) A magnetic resonance imaging investigation into the function of the deep cervical flexors during the performance of craniocervical flexion. *Journal of Manipulative Physiology and Therapy*, 33(4), 286-291.

Cagnie, B., Dirks, R., Schouten, *et al.* (2011) Functional reorganization of cervical flexor activity because of induced muscle pain evaluated by muscle functional magnetic resonance imaging. *Manual Therapy*, 16, 470-475.

Cagnie, B., O'Leary, S., Elliott, J., *et al.* (2011) Pain-induced changes in the activity of the cervical extensor muscles evaluated by muscle functional magnetic resonance imaging. *The Clinical Journal of Pain*, 27(5), 392-397.

Carroll, L. J., Holm, L. W., Hogg-Johnson *et al.* (2008) Course and prognostic factors for neck pain in whiplash-associated disorders (WAD):_results of the bone and joint decade 2000-2010 task force on neck pain and its associated disorders. *European Spine Journal*, 17 (Suppl. 1), 83-92.

Cavanaugh, J. M., Lu, Y., Chen, C., Kallakuri, S. (2006) Pain generation in lumbar and cervical APA joints. *The Journal of Bone and Joint Surgery*, 88a (Suppl. 2), 63-67.

Cave, A. J. (1937) The innervations and morphology of the cervical intertransverse muscles. *Journal of Anatomy*, 71(4), 497-515.

Chan, Y. S., Kasper, J., Wilson, V. J. (1987) Dynamics and directional sensitivity of neck muscle spindle responses to head rotation. *Journal of Neurophysiology*, 57(6), 1716-1729.

Chien, A., Eliav, E., Sterling, M. (2008) Whiplash (grade ii) and cervical radiculopathy share a similar sensory presentation: an investigation using quantitative sensory testing. *Clinical Journal of Pain*, 24(7), 595-603.

Claridge, H. A. H., Piercy, R. J., Parry, A., *et al.* (2010) The 3D anatomy of the cervical articular process joints in the horse and their topographical relationship to the spinal cord. *Equine Veterinary Journal*, 42(8), 726-731.

Clayton, H. M., Sha, D. H. (2006) Head and body centre of mass movement in horses trotting on a circular path. *Equine Veterinary Journal*, 36 (Suppl.), 462-467.

Clayton, H. M., Townsend, H. G. G. (1989a) Kinematics of the cervical spine of the adult horse. *Equine Veterinary Journal*, 21, 189-192.

Clayton, H. M., Townsend, H. G. G. (1989b) Cervical spinal kinematics: a comparison between foals and adult horses. *Equine Veterinary Journal*, 21(3), 193-195.

Clayton, H.M., Kaiser, L.J., Lavagnino, M. *et al.* (2010) Dynamic mobilizations in cervical flexion: Effects on intervertebral angulations. *Equine Veterinary Journal*, 42 (Suppl.38), 688-694.

Clayton, H.M., Kaiser, L.J., Lavagnino, M. *et al.* (2011) Intervertebral angulations in dynamic mobilizations performed in cervical lateral bending. *American Journal of Veterinary Research*, 73(8), 1153-1159.

- Comerford, M. J., Mottram, S. L. (2001) Movement and stability dysfunction: contemporary developments. *Manual Therapy*, 6(1), 15-26.
- Cotê, P., Cassidy, D. J., Carroll, L. J., *et al.* (2004) The annual incidence and course of neck pain in the general population: a population-based cohort study. *Pain*, 112 (3), 267-273.
- Cousty, M., Retureau, C., Tricaud, C., *et al.* (2010) Location of radiological lesions of the thoracolumbar column in French trotters with and without signs of back pain. *Veterinary Record*, 166, 41-45.
- Cousty, M., Firidolfi, C., Geffroy, O., *et al.* (2011) Comparison of medial and lateral ultrasound-guided approaches for periarticular injection of the thoracolumbar intervertebral APA joints in horses. *Veterinary Surgery*, 40, 494-499.
- Craig, A. D. (2002) How do you feel? Interoception: the sense of the physiological condition of the body. *Current Opinion in Neurobiology*, 13(4), 500-505.
- Croft, P. R., Lewis, M., Papageorgiou, A. C., *et al.* (2001) Risk factors for neck pain: a longitudinal study in the general population. *Pain*, 93, (3), 317-325.
- de Cocq, P., Prinsen, H., Springer, N. C. N., *et al.* (2009) The effect of rising and sitting trot on back movements and head-neck position of the horse. *Equine Veterinary Journal*, 41(5), 423-427.
- de Heus, P., van Oosaenen, G., van Dierendonck, M. C., *et al.* (2010) A pressure algometer is a useful tool to objectively monitor the effect of diagnostic palpation by a physiotherapist in warmblood horses. *Journal of Equine Veterinary Science*, 30(6), 310-321.
- Denoix, J.-M., Adigié, F. (2001) The neck and back. In: *Equine Locomotion* (Ed. Clayton H. M., Back, W.). Harcourt Publishers Limited, London, United Kingdom.
- Denoix, J.-M., Dyson, S. (2003) The thoracolumbar spine. In: *Diagnosis and management of lameness in the horse*, first edition. Eds: Ross, M. W. and Dyson, S. J., W.B. Saunders, St.Louis, 509-521.
- Down, S. S., Henson, F. M. D. (2009) Radiographic retrospective study of the caudal cervical APA articulations in the horse. *Equine Veterinary Journal*, 41(1), 01-07.
- Driessen, B., Zarucco, L. (2007) Pain: from diagnosis to effective treatment. *Clinical Techniques in Equine Practice*, 6(2), 126-134.
- Dunbar, D. C., MacPherson, J. M., Simmons, R. W., *et al.* (2008) Stabilization and mobility of the head, neck and trunk in horses during overground locomotion: comparisons with humans and other primates. *Journal of Experimental Biology*, 211(24), 3889-3907.

- Dutton, D. W., Lashnits, K. J., Wegner, K. (2009) Managing severe hoof pain in a horse using multimodal analgesia and a modified composite pain score. *Equine Veterinary Education*, 21, 37-43.
- Dyson, S. (2002) Poor performance: cannot or will not? In: Conference on Equine Sports Medicine and Science – the Elite Dressage- and Three-Day Event Horse, October 2002, Saumur, France. Ed. By Dr A. Lindner. Lensing Druck: Dortmund, 43-54.
- Dyson, S. J. (2003) The cervical spine and soft tissues of the neck. In: *Diagnosis and management of lameness in the horse*, first edition. Eds: Ross, M. W. and Dyson, S. J., W.B. Saunders, St.Louis, 523-531.
- Elgersma, A. E., Wijnberg, I. D., Sleutjens, J., *et al.* (2010) A pilot study on objective quantification and anatomical modelling of *in vivo* head and neck positions commonly applied in training and competition of sport horses. *Equine Veterinary Journal*, 42 (Supplement 38), 436-443.
- Elliott, J., Jull, G., Noteboom, J. T., *et al.* (2008) MR study of the cross-sectional area for the cervical extensor musculature in patients with persistent whiplash-associated disorders (WAD). *Manual Therapy*, 13, 258-265.
- Elliott, J. M., O’Leary, S. P., Cagnie, B., *et al.* (2010) Craniocervical orientation affects muscle activation when exercising the cervical extensors in healthy subjects. *Archives of Physical Medicine and Rehabilitation*, 91, 1418-1422.
- Enthoven, P., Skargren, E., Öberg, B. (2004) Clinical course in patients seeking primary care for back or neck pain: a prospective 5-year follow-up of outcome and health care consumption with subgroup analysis. *Spine*, 29(21), 2458-2465.
- Evans, R. W. (1992) Some observations on whiplash injuries. *Neurologic Clinics*, 10(4), 975-997.
- Falco, F. J., Erhart, S., Wargo, B. W., *et al.* (2009) Systematic review of diagnostic utility and therapeutic effectiveness of cervical APA joint interventions. *Pain Physician*, 12(2), 323-344.
- Falla, D., Jull, G., Dall’Alba, P., *et al.* (2003b) An electromyographic analysis of the deep cervical flexor muscles in performance of craniocervical flexion. *Physical Therapy*, 83(10), 899-906.
- Falla, D. (2004) Unravelling the complexity of muscle impairment in chronic neck pain. *Manual Therapy*, 9, 125-133.
- Falla, D., Jull, G., Hodges, P.W. (2004a) Feedforward activity of the cervical flexor muscles during voluntary arm movements is delayed in chronic neck pain. *Experimental Brain Research*, 157, 43-48.

- Falla, D., Jull, G., Edwards, S. *et al* (2004b) Neuromuscular efficiency of the sternocleidomastoid and anterior scalene muscles in patients with chronic neck pain. *Disability and rehabilitation*, 26(12), 712-717.
- Falla, D., Bilenkij, G., Jull, G. (2004c) Patients with chronic neck pain demonstrate altered patterns of muscle activation during performance of a functional upper limb task. *Spine*, 29(13), 1436-1440.
- Falla, D., Jull, G., Hodges, P. W. (2004d) Patients with neck pain demonstrate reduced electromyographic activity of the deep cervical flexor muscles during performance of the craniocervical flexion test. *Spine*, 29(19), 2108-2114.
- Falla, D., Jull, G., Rainoldi, A., *et al*. (2004e) Neck flexor muscle fatigue is side specific in patients with unilateral neck pain. *European Journal of Pain*, 8, 71-77.
- Falla, D., Farina, D. (2007) Neural and muscular factors associated with motor impairment in neck pain. *Current Rheumatology Reports*, 9(6), 497-502.
- Falla, D., Farina, D. (2008) Neuromuscular adaptation in experimental and clinical neck pain. *Journal of Electromyography and Kinesiology*, 18, 255–261.
- Falla, D., Farina, D., Kanstrup Dahl, *et al*. (2006) Muscle pain induces task-dependent changes in cervical agonist-antagonist activity. *Journal of Applied Physiology*, 102, 601-6-9.
- Falla, D., Farina, D., Kanstrup Dahl, M., *et al*. (2007) Muscle pain induces task-dependent changes in cervical agonist/antagonist activity. *Journal of Applied Physiology*, 102, 601-609.
- Falla, D., Jull, G., Russell, T., *et al*. (2007) Effect of neck exercise on sitting posture in patients with chronic neck pain. *Physical Therapy*, 87(4), 408-417.
- Fejer, R., Kyvik, K. O., Hartvigsen, J. (2006) The prevalence of neck pain in the world population: a systematic critical review of the literature. *European Spine Journal*, 15, 834-848.
- Fernández-de-las-Peñas, C., Albert-Sanchís, J. C., Buil, M., *et al*. (2008) Cross-sectional area of cervical multifidus muscle in females with chronic bilateral neck pain compared to controls. *Journal of Orthopaedic and Sports Physical Therapy*, 38, 175-180.
- Friedrich, K. M., Trattinig, S., Millington, S. A., *et al*. (2007) High-field magnetic resonance imaging of meniscoids in the zygapophyseal joints of the human cervical spine. *Spine*, 32(2), 244-248.
- Fuglbjerg, V., Nielsen, J. V., Thomsen, P. D., *et al*. (2009) Accuracy of ultrasound-guided injections of thoracolumbar articular process joints in horses: a cadaveric study. *Equine Veterinary Journal*, 41(1), 18-22.
- Fureix C, Menguy H, Hausberger M (2010) Partners with Bad Temper: Reject or Cure? A Study of Chronic Pain and Aggression in Horses. *PLoS ONE* 5(8): e12434.

- Gabay, O. (2012) Editorial: Osteoarthritis: new perspectives. *Spine*, 19(1), 1-2.
- Galis, F. (1999) Why do almost all mammals have seven cervical vertebrae? Developmental constraints, *Hox genes* and cancer. *Journal of Experimental Zoology*, 285, 19-26.
- Gellhorn, A. C. (2011) Cervical APA-mediated pain. *Physical Medicine and Rehabilitation Clinics of North America*, 22(3), 447-458.
- Gellhorn, A. C., Katz, J. N., Suri, P. (2013) Osteoarthritis of the spine: the APA joints. *Nature Reviews Rheumatology*, 9 (4), 216-224.
- Gellman, K. S., Bertram, J. E. A. (2002a) The equine nuchal ligament 1: structure and material properties. *Veterinary and Comparative Orthopaedics and Traumatology*, 15, 7-14.
- Gellman, K. S., Bertram, J. E. A. (2002b) The equine nuchal ligament 2: passive dynamic energy exchange in locomotion. *Veterinary and Comparative Orthopaedics and Traumatology*, 15, 1-6.
- Gellman, K. S., Bertram, J. E. A., Hermanson, J. W. (2002) Morphology, histochemistry, and function of epaxial cervical musculature in the horse (*Equus caballus*). *Journal of Morphology*, 251(2), 182-194.
- Getty, R. (1975) Equine osteology. In: *Sisson and Grossman's The Anatomy of the Domestic Animals*, 5th edition. Ed: Getty, R. WB Saunders & Co, Toronto, 255-262.
- Gillen, A., Dyson, S., Murray, R. (2009) Nuclear scintigraphic assessment of the thoracolumbar synovial intervertebral articulations. *Equine Veterinary Journal*, 41(6), 534-540.
- Girodroux, M., Dyson, S., Murray, R. (2009) Osteoarthritis of the thoracolumbar synovial intervertebral articulations: clinical and radiographic features in 77 horses with poor performance and back pain. *Equine Veterinary Journal*, 41(2), 130-138.
- Goff, L. M., Jeffcott, L. B., Jasiewicz, J., *et al.* (2008). Structural and biomechanical aspects of sacroiliac joint function and their relationship to clinical disease. *The Veterinary Journal*, 176 281-293.
- Goff, L. M. (2009) Manual therapy for the horse: a contemporary perspective. *Journal of Equine Veterinary Science*, 29(11), 799-808.
- Gollob, E., Edinger, H., Stanek, C., *et al.* (2002) Ultrasonographic investigation of the atlanto-occipital articulation in the horse. *Equine Veterinary Journal*, 34(1), 44-50.
- Gómez-Álvarez, C. B., Rhodin, M., Bobbert, M. F., *et al.* (2006) The effect of head and neck position on the thoracolumbar kinematics in the unriden horse. *Equine Veterinary Journal*, 38 (Supplement 36), 445-451.
- Graf, W., De Waele, C., Vidal, P. P. (1995) Functional anatomy of the head-neck movement system of quadrupedal and bipedal mammals. *Journal of Anatomy*, 186, 55-74.

- Guez, M., Hildingsson, C., Nilsson, M., *et al.* (2002) The prevalence of neck pain. *Acta Orthopaedica*, 73(4), 455-459.
- Haussler, K. K. (1999a) Osseous spinal pathology. *Veterinary Clinics of North America: Equine Practitioner*, 15, 103-112.
- Haussler, K. K. (1999b) Chiropractic evaluation and management. *Clinics of North America: Equine Practitioner*, 15, 195-208.
- Haussler, K. K. (2009) Review of manual therapy techniques in equine practice. *Journal of Equine Veterinary Science*, 29(12), 849-869.
- Haussler, K. K., Stover, S. M., Willits, N. H. (1999) Pathology of the lumbosacral spine and pelvis in Thoroughbred racehorses. *American Journal of Veterinary Research*, 60, 143-153.
- Haussler, K. K., Erb, H. N. (2006) Mechanical nociceptive thresholds in the axial skeleton of horses. *Equine Veterinary Journal*, 38(1), 70-75.
- Heckman, C. J., Sandercock, T. G. (1996) From motor unit to whole muscle properties during locomotor movements. *Exercise and Sport Sciences Reviews*, 24(1), 109-134.
- Heleski, C. R., McGreevy, P. D., Kaiser, L. J., *et al.* (2009) Effects on behavior and rein tension on horses ridden with or without martingales and rein inserts. *The Veterinary Journal*, 181(1), 56-62.
- Helms, J. E., Barone, C. P. (2008) Physiology and treatment of pain. *Critical Care Nurse*, 28(6), 38-49.
- Hides, J., Richardson, C. and Jull, G. (1996) Multifidus muscle recovery is not automatic after resolution of acute, first-episode low back pain. *Spine*, 21, 2763 - 2769.
- Hides, J. A., Jull, G. A., and Richardson, C. A. (2001) Long-term effects of specific stabilizing exercises for first-episode low back pain. *Spine*, 26(11), E243-8.
- Higham, T. E., Biewener, A. A. (2011) Functional and architectural complexity within and between muscles: regional variation and intermuscular force transmission. *Philosophical Transactions of the Royal Society*, 366, 1477-1487.
- Hodges, P., Holm, A. K., Hansson, T., Holm, S. (2006) Rapid atrophy of the lumbar multifidus follows experimental disc or nerve root injury. *Spine*, 31, 2926-2933.
- Hodges, P., W., Cholewicki, J. (2007) Functional control of the spine. In: *Movement, Stability and Lumbopelvic Pain*. 2nd Ed. Ed: Vleeming, A., Mooney, V., Stoeckart, R., Elsevier, Edinburgh, 489-512.

Hogg-Johnson, S., van der Velde, G., Carroll, L. J., *et al.* (2008) The burden and determinants of neck pain in the general population. Results of the Bone and Joint Decade 2000-2010 task force on neck pain and its associated disorders. *European Spine Journal*, 17(Supplement 1), 39-51.

Houpt, K. A., Mills, D. S. (2006) Why horse behavior is important to the equine clinician. *Equine Veterinary Journal*, 38(5), 386-387.

Huelke, D. F., Nusholtz, G. S. (1986) Cervical spine biomechanics: A review of the literature. *Journal of Orthopaedic Research*, 4, 232-245.

Inami, S., Kaneoka, K., Hayashi, K., *et al.* (2000) Types of synovial fold in the cervical APA joint. *Journal of Orthopaedic Science*, 5, 475-480.

Inami, S., Shiga, T., Tsujino, A., *et al.* (2001) Immunohistochemical demonstration of nerve fibers in the synovial fold of the human cervical APA joint. *Journal of Orthopaedic Research*, 19, 593-596.

Jaumard, N. V., Bauman, J. A., Weisshaar, C. L., *et al.* (2011) Contact pressure in the facet joint during sagittal bending of the cadaveric cervical spine. *Journal of Biomechanical Engineering*, 133, (7), 10041-0710049.

Jaumard, N. V., Welch, W. C., Winkelstein, B. A. (2011) Spinal APA joint biomechanics and mechanotransduction in normal, injury and degenerative conditions. *Journal of Biomechanical Engineering*, 133(7), 07101001-07101031.

Javanshir, K., Amiri, M., Mohseni-Bandpei, M., *et al.* (2010) Ultrasonography of the cervical muscles: a critical review of the literature. *Journal of Manipulative and Physiological Therapeutics*, 33(8), 630-637.

Javanshir, K., Mohseni-Bandpei, M. A., Rezasoltani, A., *et al.* (2011) Ultrasonography of longus colli muscle: A reliability study on healthy patients and patients with chronic neck pain. *Journal of Bodywork and Movement Therapies*, 15(1), 50-56.

Javanshir, K., Rezasoltani, A., Mohseni-Bandpei, M. A., Amiri, M., *et al.* (2011) Ultrasound assessment of bilateral longus colli muscles in subjects with chronic bilateral neck pain. *American Journal of Physical Medical Rehabilitation*, 90, 293-301.

Jeffcott, L. B. (1980) Disorders of the thoracolumbar spine of the horse- a survey of 443 cases. *Equine Veterinary Journal*, 12, 197-210.

Jesus, F. M. R., Ferreira, P. H., Ferreira, M. L. (2008) Ultrasonographic measurement of neck muscle recruitment: a preliminary investigation. *Journal of Manual and Manipulative Therapy*, 16(2), 89-92.

Jesus-Moraleida, F. R., Ferreira, P. H., Pereira, L. S., *et al.* (2011) Ultrasonographic analysis of the neck flexor muscles in patients with chronic neck pain and changes after cervical spine mobilization. *Journal of Manipulative and Physiological Therapeutics*, 34(8), 514-524.

- Johnson, R. M., Crelin, E. S., White, A. A., *et al.* (1975) Some new observations on the functional anatomy of the lower cervical spine. *Clinical Orthopaedics and Related Research*, 111, 192-200.
- Johnston, V., Jull, G., Souvlis, Jimmieson, N. L. (2008) Neck movement and muscle activity characteristics in female office workers with neck pain. *Spine*, 33(5), 555-563.
- Jull, G. A., Richardson, C. A. (2000) Motor control problems with spinal pain: a new direction for therapeutic exercise. *Journal of Manipulative and Physiological Therapeutics*, 23(2), 115-117.
- Jull, G., Trott, P., Potter, H., *et al.* (2002) A randomized controlled trial of exercise and manipulative therapy for cervicogenic headache. *Spine*, 27(17), 1835-1843.
- Jull, G., Kristjansson, E., Dall'Alba, P. (2004a) Impairment in the cervical flexors: a comparison of whiplash and insidious onset neck pain patients. *Manual Therapy*, 9, 89-94.
- Jull, G. A., O'Leary, S. P., Falla, D. L. (2008) Clinical assessment of the deep cervical flexor muscles: the craniocervical flexion test. *Journal of Manipulative and Physiological Therapeutics*. 31(7), 525-533.
- Jull, G. A., Falla, D., Vicenzino, B., *et al.* (2009) The effect of therapeutic exercise on activation of the deep cervical flexor muscles in people with chronic neck pain. *Manual Therapy*, 14(6), 696-701.
- Kalichman L, Hodges P, Li L, *et al.* (2009) Changes in paraspinal muscles and their association with low back pain and spinal degeneration: CT study. *European Spine Journal* 19, 1136-1144.
- Kallakuri, S., Singh, A., Chen, C., Cavanaugh, J. M. (2004) Demonstration of substance P, calcitonin gene-related peptide, and protein gene product 9.5 containing nerve fibers in human cervical APA joint capsules. *Spine*, 29(11), 1182-1186.
- Kamibayashi, L. K., Richmond, F. J. (1998) Morphometry of human neck muscles, *Spine*, 23(12), 1314-1323.
- Kavcic, N, Grenier, S., McGill, S.M. (2004) Determining the stabilizing role of individual torso muscles during rehabilitation exercises. *Spine*, 29(11), 1254-1265.
- Keshner, E. A., Baker, J. F., Banovetz, J., *et al.* (1992) Patterns of neck muscle activation in cats during reflex and voluntary head movements. *Experimental Brain Research*, 88, 361-374.
- Kettler, A., Wilke, H.-J. (2006) Review of existing grading systems for cervical or lumbar disc and APA joint degeneration. *European Spine Journal*, 15, 705-718.
- Kirpalani, D., Mitra, R. (2008) Cervical APA joint dysfunction: a review. *Archives of Physical Medicine and Rehabilitation*, 89 (4), 770-774.

- Krafft, M., Kullgren, A., Tingvall, C., *et al.* (2000) How crash severity in rear impacts influences short- and long-term consequences to the neck. *Accident: Analysis and Prevention*, 32, 187-195.
- Kristjansson, E. (2004) Reliability of ultrasonography for the cervical multifidus muscle in asymptomatic and symptomatic subjects. *Manual Therapy*, 9, 83-88.
- Kumaresan, S., Yganandan, N., Pintar, F. A., *et al.* (2001) Contribution of disc degeneration to osteophyte formation in the cervical spine: a biomechanical investigation. *Journal of Orthopaedic Research*, 19(5), 977-984.
- Lee, K. E., Thinnes, J. H., Gokhin, D. S., *et al.* (2004) A novel rodent neck pain model of APA-mediated behavioral hypersensitivity: implications for persistent pain and whiplash injury. *Journal of Neuroscience Methods*, 137, 151-159.
- Lee, J.-P., Tsen, W.-Y. I., Shau, Y.-W., *et al.* (2007) Measurement of segmental cervical multifidus contraction by ultrasonography in asymptomatic adults. *Manual Therapy*, 12(3), 286-294.
- Lee, J.-P., Tsen, W.-Y. I., Shau, Y.-W., *et al.* (2009) Measurement of cervical multifidus contraction pattern with ultrasound imaging. *Journal of Electromyography and Kinesiology*, 19(3), 319-397.
- Levine, J. M., Adam, E., Mackay J. *et al.* (2007) Confirmed and presumptive cervical vertebral compressive myelopathy in older horses: a retrospective study (1994-2004). *Journal of Veterinary Internal Medicine*, 21, 812-819.
- Levine, J. M., Levine, G. J., Hoffman, A. G., *et al.* (2007) Comparative anatomy of the horse, ox and dog: the vertebral column and peripheral nerves. *Compendium Equine*, Sep/Oct, 279-292.
- Lieber, R. L., Bodine-Fowler, S. C. (1993) Skeletal muscle mechanics: implications for rehabilitation. *Physical Therapy*, 73(12), 844-856.
- Lindegaard, C., Thomsen, M. H., Larsen, S., *et al.* (2010) Analgesic efficacy of intra-articular morphine in experimentally induced radiocarpal synovitis in horses. *Veterinary Anaesthesia and Analgesia*. 37(2), 171-185.
- Lindström, R., Schomacher, J., Farina, D., *et al.* (2011) Association between neck muscle coactivation, pain and strength in women with neck pain. *Manual Therapy*, 16, 80-86.
- López-Rivero, J. L., Serrano, A. L., Diz, A. M., *et al.* (1992) Variability of muscle fiber composition and fiber size in the horse gluteus medius: an enzyme-histochemical and morphometric study. *Journal of Anatomy*, 181(Pt 1), 1-10.
- Love, E. J. (2009) Assessment and management of pain in horses. *Equine Veterinary Education*, 21(1), 46-48.

- Lu, Y., Chen, C., Kallakuri, S., *et al.* (2005) Neurophysiological and biomechanical characterization of goat cervical APA joint capsules. *Journal of Orthopaedic Research*, 23, 779-787.
- Lund, J. P., Donga, R., Widmer, C. G., *et al.* (1991) The pain-adaptation model: a discussion between chronic musculoskeletal pain and motor activity. *Canadian Journal of Physiological Pharmacology*, 69(5), 683-694.
- Maitland, G. D. (1977) *Peripheral Manipulation*, 2nd edition. Butterworths, London, 86-92.
- Manchikanti, L., Boswell, M. V., Singh, V., *et al.* (2004) Prevalence of facet joint pain in chronic spinal pain of cervical, thoracic and lumbar regions. *BMC Musculoskeletal Disorders*, 5(15), 1-7.
- Manchukonda, R., Manchikanti, K. N., Cash, *et al.* (2007) Facet joint pain in chronic spinal pain: an evaluation of prevalence and false-positive rate of diagnostic blocks. *Journal of Spinal Disorders and Techniques*, 20(7), 539-545.
- Mansmann, R. A., Currie, M. C., Correa, M. T. *et al.* (2011) Equine behavior problems – around farriery: foot pain in 11 horses. *Journal of Equine Veterinary Science*, 31, 44-48.
- Mattoon, J. S., Drost, W. T., Grguric, M. R., *et al.* (2004) Technique for equine cervical articular process joint injection. *Veterinary Radiology and Ultrasound*, 45(3), 238-240.
- Mayoux-Benhamou, M. A., Revel, M., Vallée, C., *et al.* (1994) Longus colli has a postural function on cervical curvature. *Surgical and Radiological Anatomy*, 16(4), 367-371.
- McDonnell, S. M., Haviland, J. C. S. (1995) Agonistic ethogram of the equid bachelor band. *Applied Animal Behavior Science*, 43, 147-188.
- McGaugh, J., Ellison, J. (2011) Intrasection and interrater reliability of rehabilitative ultrasound imaging measures of the deep neck flexors: a pilot study. *Physiotherapy Theory and Practice*, 27(8), 572-577.
- McGowan, C.M., Hodges, P.W., and Jeffcott, L.B *et al.*(2007) Epaxial musculature and its relationship with back pain in the horse. *A report for the Rural Industries Research and Development Corporation* (www.rirdc.gov.au).
- McLain, R. F. (1994) Mechanoreceptor endings in human cervical facet joints. *Spine*, 19(5), 495-501.
- Meehan, L., Dyson, S., Murray, R. (2009) Radiographic and scintigraphic evaluation of spondylosis in the equine thoracolumbar spine: a retrospective study. *Equine Veterinary Journal*, 41(8), 800-807.
- Melzack, R., Wall, P. D. (1965) Pain mechanisms: a new theory. *Science*, 150, 971-979.

- Melzack, R. (1999) From the gate to the neuromatrix. *Pain* (Supplement), 6, 121-126.
- Mercer, S. B., Bogduk, N. (1999) The ligaments and anulus fibrosus of human cervical intervertebral discs. *Spine*, 24(7), 619-626.
- Moberg, G. P. (2000) Biological response to stress: implications for animal welfare. In: *The Biology of Animal Stress* (Eds. Moberg, G. P. and Mench, J. A.). CABI Publishing, New York, United States of America.
- Mogil, J. S. (2009) Animal models of pain: progress and challenges. *Nature Review Neuroscience*, 10, 283-294.
- Moore, B. R., Reed, S. M., Biller, D. S. *et al.* (1994) Assessment of vertebral canal diameter and bony malformations of the cervical part of the spine in horses with cervical stenotic myelopathy. *American Journal of Veterinary Research*, 55(1), 05-13.
- Moroney, S. P., Schultz, A. B., Miller, J. A. A., *et al.* (1988) Load-displacement properties of lower cervical spine motion segments. *Journal of Biomechanics*, 21(9), 769-779.
- Murray, R. C., Dyson, S. J., Tranquille, C., *et al.* (2006) Association of type of sport and performance level with anatomical site of orthopaedic injury diagnosis. *Equine Veterinary Journal* (Supplement), 36, 411 – 416.
- Narita, Y, Kuratani, S. (2005) Evolution of the vertebral formulae in mammals: A perspective on developmental constraints. *Journal of Experimental Zoology*, 304B(2), 91-106.
- Nielsen, J. V., Berg, L. C., Thoenner, M. B., Thomson, P. D. (2003) Accuracy of ultrasound-guided intra-articular injection of cervical APA joints in horses: a cadaveric study. *Equine Veterinary Journal*, 35(7), 657-661.
- O’Leary, S., Elliott, J. M., Falla, D., *et al.* (2009) Muscle dysfunction in cervical spine pain: implications for assessment and management. *Journal of Orthopaedic and Sports Physical Therapy*, 39(5), 324-333.
- O’Leary, S., Cagnie, B., Reeve, A., *et al.* (2011) Is there altered activity of the extensor muscles in chronic mechanical neck pain? A functional magnetic resonance imaging study. *Archives of Physical Medicine and Rehabilitation*, 92, 929-934.
- Olbrich, V. H., Mosing, M. (2003) A comparison of the analgesic effects of caudal epidural methadone and lidocaine in the horse. *Veterinary Anaesthesia and Analgesia*, 30, 156-164.
- Pagger, H., Schmidburg, I., Peham, C., *et al.* (2010) Determination of the stiffness of the equine cervical spine. *The Veterinary Journal*, 186, 338-341.

- Pal, G. P., Routal, R. V., Saggu, S. K. (2001) The orientation of the articular APAs of the zygophyseal joints at the cervical and upper thoracic region. *Journal of Anatomy*, 198, 431-441.
- Panjabi, M. Cholewicki, J., Nibu, K. *et al* (1998) Capsular ligament stretches during in vitro whiplash simulations. *Journal of Spinal Disorders and Techniques*, 11(3), 227-232.
- Panjabi, M. M., Crisco, J., Vasavada, A., *et al.* (2001) Mechanical properties of the human cervical spine as shown by three-dimensional load-displacement curves. *Spine*, 26(24), 2692-2700.
- Panjabi, M. (2006) A hypothesis of chronic back pain: ligament sub-failure injuries lead to muscle control dysfunction. *European Spine Journal*, 15, 668-676.
- Papageorges, M., Gavin, P. R., Sande, R. D. *et al.* (1987) Radiographic and myelographic examination of the cervical vertebral column in 306 ataxic horses. *Veterinary Radiology and Ultrasound*, 28(2), 53-59.
- Paulekas, R., Haussler, K. K. (2009) Principles and practice of therapeutic exercise for horses. *Journal of Equine Veterinary Science*, 29(12), 870-893.
- Paulus, I, Brumagne, S. (2008) Altered interpretation of neck proprioceptive signals in persons with subclinical recurrent neck pain. *Journal of Rehabilitation Medicine*, 40, 426-432.
- Penning, L. (1978) Normal movements of the cervical spine. *American Journal of Roentgenology*, 130, 317-326.
- Peolsson, A., Brodin, L.-Å., Peolsson, M., (2012) A tissue velocity ultrasound imaging investigation of the dorsal neck muscles during resisted isometric extension. *Manual Therapy*, 15(6), 567-573.
- Powers, B. E., Stashak, T. S., Nixon, A. J., *et al.* (1986) Pathology of the vertebral column of horses with cervical static stenosis. *Veterinary Pathology*, 23, 392-399.
- Price, J., Marques, J. M., Welsh, E. M., *et al.* (2002) Pilot epidemiological study of attitudes towards pain in horses. *The Veterinary Record*, 151, 570-575.
- Price, J., Seago, C., Welsh, E. M., *et al.* (2003) Preliminary evaluation of a behavior-based system for assessment of post-operative pain in horses following arthroscopic surgery. *Veterinary Anaesthesia and Analgesia*, 30, 124-137.
- Pritchett, L. C., Ulibarri, C., Roberts, M. C. *et al.* (2003) Identification of potential physiological and behavioral indicators of postoperative pain in horses after exploratory celiotomy for colic. *Applied Animal Behavior Science*, 80, 31-43.

- Quinlan, K. P., Annest, J. L., Myers, B., **et al.** (2004) Neck strains and sprains among motor vehicle occupants – United States, 2000. *Accident Analysis and Prevention*, 36(1), 21-27.
- Quinn, K. P., Winkelstein, B. A. (2007) Cervical APA capsular ligament yield defines the threshold for injury and persistent joint-mediated neck pain. *Journal of Biomechanics*, 40, 2299-2306.
- Raekallio, M., Taylor, P. M., Bloomfield, M. (1997) A comparison of methods for evaluation of pain and distress after orthopaedic surgery in horses. *Journal of Veterinary Anaesthesiology*, 24(2), 17-20.
- Rainville, P., Bao, Q. V. H., Chrétien, P. (2005) Pain-related emotions modulate experimental pain perception and autonomic responses. *Pain*, 118 (3), 306-318.
- Rankin, G., Stokes, M., Newham, D. J. (2005) Size and shape of the posterior neck muscles measured by ultrasound imaging: normal values in males and females of different ages. *Manual Therapy*, 10, 108-115.
- Reeves, P. N., Narendra, K. S., Cholewicki, J. (2007) Spine stability: The six blind men and the elephant. *Clinical Biomechanics*, 22, 266-274.
- Rhodin, M., Gómez-Álvarez, C. B., Byrström, A., *et al.* (2009) The effect of different head and neck positions on the caudal back and hindlimb kinematics in the elite dressage horse at trot. *Equine Veterinary Journal*, 41(3), 274-279.
- Ricardi, G., Dyson, S. J. (1993) Forelimb lameness associated with radiographic abnormalities of the cervical vertebrae. *Equine Veterinary Journal*, 25, 422-426.
- Richmond, F. J. R., Bakker, D. (1982) Anatomical organization and sensory receptor content of soft tissues surrounding upper cervical vertebrae in the cat. *Journal of Neurophysiology*, 48(1), 49-61.
- Richmond, F. J. R. (1998) Elements of style in neuromuscular architecture. *American Zoology*, 38, 729-742.
- Richmond, F. J. R., Singh, K., Corneil, B. D. (2001) Neck muscles in the Rhesus monkey: I. Muscle morphometry and histochemistry. *Journal of Neurophysiology*, 86, 1717-1728.
- Rietmann, T. R., Stauffacher, M., Bernasconi, P. *et al.* (2004) The association between heart rate, heart rate variability, endocrine and behavioral pain measures in horses suffering from laminitis. *Journal of Veterinary Medicine*, 51, 218-225.
- Roussouly, P., Pinheiro-Franco, J. L. (2011) Sagittal parameters of the spine: biomechanical approach. *European Spine Journal*, 20(5), 578-585.

- Rutherford, K. M. D. (2002) Assessing pain in animals. *Animal Welfare*, 11, 31-53.
- Schilling, N. (2011) Evolution of the axial system in craniates: morphology and function of the perivertebral musculature. *Frontiers in Zoology*, 8:4.
- Scott, D., Jull, G., Sterling, M. (2005) Widespread sensory hypersensitivity is a feature of chronic whiplash-associated disorder but not chronic idiopathic neck pain. *Clinical Journal of Pain*, 21(2), 175-181.
- Sellon, D. C., Roberts, M. C., Blikslager, A. T. *et al.* (2004) Effects of continuous rate intravenous infusion of butorphanol on physiologic and outcome variables in horses after celiotomy. *Journal of Veterinary Internal Medicine*, 18, 555-563.
- Sharir, A., Milgram, J., Shahr, R. (2006) Structural and functional anatomy of the neck musculature of the dog (*Canis familiaris*). *Journal of Anatomy*, 208, 331-351.
- Short, C. E. (1998) Fundamentals of pain perception in animals. *Applied Animal Behavior Science*, 59, 125-133.
- Siegmund, G. P., Blouin, J-S., Carpenter, M. G., *et al.* (2008) Are cervical multifidus muscles active during whiplash and startle? *BMC Musculoskeletal Disorders*, 9, 80.
- Simpson, A. K., Biswas, D., Emerson, J. W., Lawrence, B. D., Grauer, J. N. (2008) Quantifying the effects of age, gender, degeneration, and adjacent level degeneration on cervical spine range of motion using multivariate analyses. *Spine*, 33(2), 183-186.
- Sjölander, P., Michaelson, P., Jaric, S., *et al.* (2008) Sensorimotor disturbances in chronic neck pain - range of motion, peak velocity, smoothness of movement, and repositioning acuity. *Manual Therapy*, 13, 122-131.
- Sleutjens, J., Voorhout, G., van der Kolk, J. H., *et al.* (2010) The effect of *ex vivo* flexion and extension on intervertebral foramina dimensions in the equine cervical spine. *Equine Veterinary Journal*, 42 (Supplement 38), 425-430.
- Solounias, N. (1999). The remarkable anatomy of the giraffe's neck. *Journal of Zoology*, 247, 257-268.
- Sterling, M., Jull, G., Wright, A. (2001) The effect of musculoskeletal pain on motor activity and control. *The Journal of Pain*, 2(3), 135-145.
- Stubbs, N. C., Hodges, P. W., Jeffcott, L. B., *et al.* (2006) Functional anatomy of the caudal thoracolumbar and lumbosacral spine in the horse. *Equine Veterinary Journal* (Supplement), 36, 393-399.

- Stubbs, N. C., Riggs, C. M., Hodges, P. W. *et al.* (2010) Osseous spinal pathology and epaxial muscle ultrasonography in Thoroughbred racehorses. *Equine Veterinary Journal*, 38 (Supplement), 654-661.
- Stubbs, N. C., Kaiser, L. J., Hauptman, J., *et al.* (2011) Dynamic mobilization exercises increase cross sectional area of *musculus multifidus*. *Equine Veterinary Journal*, 43 (5), 522-529.
- Sullivan, K. A., Hill, A. E., Haussler, K. K. (2008) The effects of chiropractic, massage and phenylbutazone on spinal mechanical nociceptive thresholds in horses without clinical signs. *Equine Veterinary Journal*, 40(1), 14-20.
- Takeshita, K., Peterson, E.T.K., Bylski-Austrow, D., *et al.* (2004) The nuchal ligament restrains cervical spine flexion. *Spine*, 29(18), E388-E393.
- Taylor, P. M., Pascoe, P. J., Mama, K. R. (2002) Diagnosing and treating pain in the horse: where are we today? *The Veterinary Clinics Equine Practice*, 18, 1-19.
- Thomsen, L. N., Berg, L. C., Markussen, B., *et al.* (2012) Synovial folds in equine articular process joints. *Equine Veterinary Journal*, DOI: 10.1111/j.2042-3306.2012.00687.x
- Tokuriki, M., Aoki, O. (1991) Neck muscles activity in horses during locomotion with and without a rider. *Equine Exercise Physiology*, 3, 146-150.
- Townsend, H. G. G., Leach, D. H., Doige, C. E., *et al.* (1986) Relationship between spinal biomechanics and pathological changes in the equine thoracolumbar spine. *Equine Veterinary Journal*, 18(2), 107-112.
- Trostle, S. S., Dubielzig, R. R., Beck, K. A. (1993) Examination of frozen cross sections of cervical spinal intersegments in nine horses with cervical vertebral malformation: lesions associated with spinal cord compression. *Journal of Veterinary Diagnostic Investigation*, 5, 423-431.
- Uhlig, Y., Weber, B. R., Grob, D., *et al.* (1995) Fiber composition and fiber transformations in neck muscles of patients with dysfunction of the cervical spine. *Journal of Orthopaedic Research*, 13(2), 240-249.
- van Biervliet, J., Mayhew, J., de Lanhunta, A. (2006) Cervical vertebral compressive myelopathy: Diagnosis. *Clinical Techniques in Equine Practice*, 5, 54-59.
- van Loon, J. P. A. M., de Grauw, J. C., van Dierendonck, M., *et al.* (2010) Intra-articular opioid analgesia is effective in reducing pain and inflammation in an equine LPS induced synovitis model. *Equine Veterinary Journal*, 42(5), 412-419.
- van Weeren, P. R., van den Bogert, A. J., Barneveld, A. (1992) Correction models for skin displacement in equine kinematics gait analysis. *Journal of Equine Veterinary Science*, 12(3), 178-192.

- Varcoe-Cocks, K., Sagar, K. N., Jeffcott, L. B., *et al.* (2006) Pressure algometry to quantify muscle pain in racehorses with suspected sacroiliac dysfunction. *Equine Veterinary Journal*, 38(6), 558-562.
- Vidal, P. P., Graf, W., Berthoz, A. (1986) The orientation of the cervical vertebral column in unrestrained awake animals. *Experimental Brain Research*, 61, 549-559.
- Vorstenbosch, M. A., Buchner, H. H., Savelberg, H. H., *et al.* (1997) Modeling study of compensatory head movements in lame horses. *American Journal of Veterinary Research*, 58(7), 713-718.
- Wagner, P. C., Grant, B. D., Bagby, G. W., *et al.* (1979) Evaluation of cervical spinal fusion as a treatment in the equine 'wobbler' syndrome. *Veterinary Surgery*, 8, 84-88.
- Wakeling, J. M. (2009) The recruitment of different compartments within a muscle depends on the mechanics of the movement. *Biology Letters*, 5(1), 30-34.
- Waldern, N. M., Wiestner, T., von Peinen, K., *et al.* (2009) Influence of different head-neck position on vertical ground reaction forces, linear and time parameters in the unriden horse walking and trotting on a treadmill. *Equine Veterinary Journal*, 41(3), 268-273.
- Webb, A. A. (2003) Potential sources of neck and back pain in clinical conditions of dogs and cats: a review. *The Veterinary Journal*, 165, 193-213.
- Weishaupt, M. A., Wiestner, T., von Peinen, K., *et al.* (2006) Effect of head and neck position on vertical ground reaction forces and interlimb coordination in the dressage horse ridden at walk and trot on a treadmill. *Equine Veterinary Journal*, Supplement 36, 387-392.
- Wennerstrand, J., Johnston, C., Roethlisberger-Holm, K., *et al.* (2004) Kinematic evaluation of the back in the sport horse with back pain. *Equine Veterinary Journal*, 36(8), 707-711.
- Whittaker, J. L., Elliott, J. M., Cook, K., *et al.* (2007) Rehabilitative ultrasound imaging: understanding the technology and its applications. *J. Orthop. Sports Phys.* 37, 434-449.
- Whitwell, K. E., Dyson, S. (1987) Interpreting radiographs 8: Equine cervical vertebrae. *Equine Veterinary Journal*, 19(1), 8-14.
- Wijnberg, I. D., Sleutjens, J., van der Kolk, J. H., *et al.* (2010) Effect of head and neck position on outcome of quantitative neuromuscular diagnostic techniques in Warmblood riding horses directly following moderate exercise. *Equine Veterinary Journal*, 42 (Suppl. 38), 261-267.
- Wijnberg, I. D., Graubner, C., Auriemma, E., *et al.* (2011) Quantitative motor unit action potential analysis in 2 paraspinal neck muscles in adult Royal Dutch sporthorses. *Journal of Veterinary Internal Medicine*, 25, 592-597.
- Wilsher, S., Allen, W. R., Wood, J. L. (2006) Factors associated with failure of thoroughbreds to train and race. *Equine Veterinary Journal*, 38(2), 98-100.

Winkelstein, B. A., McLendon, R. E., Barbir, A., *et al.* (2001) An anatomical investigation of the human cervical APA capsule, quantifying muscle insertional area. *Journal of Anatomy*, 198, 455-461.

Withers, J. M., Voûte, L. C., Hammond, G., *et al.* (2009) Radiographic anatomy of the articular process joints of the caudal cervical vertebrae in the horse on lateral and oblique projections. *Equine Veterinary Journal*, 41, 9, 895-902.

Woodhouse, A., Vasseljen, O. (2008) Altered motor control patterns in whiplash and chronic neck pain. *BMC Musculoskeletal Disorders*, 9, 90.

Yoganandan, N., Kumaresan, S., Pintar, F. A. (2001) Biomechanical of the cervical spine Part 2. Cervical spine soft tissue responses and biomechanical modeling. *Clinical Biomechanics*, 16(1), 01-27.

Zsoldos, R. R., Kotschwar, A. B., Kotschwar, A., *et al.* (2010a) Electromyography activity of the equine splenius muscle and neck kinematics during walk and trot on the treadmill. *Equine Veterinary Journal*, 42, (Supplement 38), 455-461.

Zsoldos, R. R., Groesel, M., Kotschwar, A., *et al.* (2010b) A preliminary modelling study on the equine cervical spine with inverse kinematics at walk. *Equine Veterinary Journal*, 42 (Supplement 38), 516-522.

CHAPTER 2

GROSS ANATOMY OF THE EQUINE DEEP PERIVERTEBRAL MUSCULATURE, *M. MULTIFIDUS CERVICIS* AND *M. LONGUS COLLI*

2.1 ABSTRACT

This study describes the gross morphology and architecture of two deep perivertebral muscles in the equine cervical and cranial thoracic spine, *m. multifidus cervicis* and *m. longus colli*, which are thought to play a key role in intersegmental spinal dynamic stability and proprioception. Detailed anatomical dissections of were performed in 15 horse cadavers. *M. multifidus cervicis* consisted of five fascicles arranged in lateral, middle and deep layer at each vertebral level from C2 caudally. Each fascicle attached cranially to a dorsal spinous process then diverged laterally to its caudal attachment onto the joint capsule of an articular process articulation (APA) after crossing between one and four intervertebral joints. This pattern of attachment continued through the cervicothoracic junction into the thoracic spine. *M. longus colli* had ventral, medial and deep layer of fibers. From C1 to C5 these layers consisted of five distinct fascicles that had their cranial attachment on a ventral process of the vertebral body, diverged laterally as they crossed one to four intervertebral joints then attached onto a transverse process as far caudally as C6. The multi-fascicular structure was replaced by a single, well-defined muscle belly from C6 to T5/T6, with intermediate muscular attachments onto the ventral vertebral bodies, and strong, short musculotendinous attachments onto the intercentral joints and onto the craniomedial aspect of the costovertebral joint capsules. The structure of *m. multifidus cervicis* and *m. longus colli* is consistent with a role in providing sagittal-plane intersegmental stability of the cervical spine and the cervicothoracic junction.

2.2 INTRODUCTION

The neck comprises approximately 6% of the total body mass of the horse (Buchner *et al.*, 1997), with the majority of the mass consisting of muscular tissue. The neck connects the head with the trunk allowing freedom of movement combined with stability of orientation for the cephalic organs of proprioception. This is facilitated by three-dimensional motion of the cervical joints (Clayton and Townsend, 1989a; Clayton and Townsend, 1989b; Mattoon *et al.*, 2004; Dunbar *et al.*, 2008; Claridge *et al.*, 2010) controlled by synergistic interplay between superficial and deep musculature and the nuchal ligament (Gellman *et al.*, 2002; Gellman and Bertram, 2002a; Gellman *et al.*, 2002b). The gross anatomy of the equine cervical musculature is described in anatomical text books (Rooney *et al.*, 1967; Getty, 1975; Nickel *et al.*, 1985; Dyce *et al.*, 1987). In addition, muscle architecture of the more superficial intrinsic muscles, *m. semispinalis capitis* and *m. splenius*, have been described in detail in terms of length, attachments, innervation and fiber type properties (Gellman *et al.*, 2002), their role in locomotor biomechanics (Tokuriki and Aoki, 1991; Gellman and Bertram, 2002a; Gellman and Bertram, 2002b; Zsoldos *et al.*, 2010a) and their importance in visual and vestibular function through influence on the head and neck position sense (Dunbar *et al.*, 2008). The superficial extrinsic *m. brachiocephalicus* has been classified as a forelimb locomotor muscle rather than a cervical positioning muscle on the basis of its phasic contraction pattern during locomotion (Tokuriki and Aoki, 1991).

Much less is known about the structure and function of the deep perivertebral musculature which is thought to play a role in postural stability of the equine cervical spine under static and dynamic conditions. *M. multifidus cervicis* and *m. longus colli* have been described in Rhesus monkeys and dogs. Their importance in relation to head and neck position sense, based on morphometrical

muscle characteristics and attachments, has been documented in the Rhesus monkey (Richmond *et al.*, 2001) and their contribution to dynamic motion of the canine cervical spine based on morphometrical measurements has been described (Sharir *et al.*, 2006). The deep musculature of the equine cervical spine has received much less attention. In prominent anatomical texts, *m. multifidus* and *m. longus colli* have received but a brief description (Getty, 1975) or a fleeting mention within the description of their anatomical region (Rooney *et al.*, 1967; Dyce *et al.*, 1987).

In contrast to the dearth of information in animals, the deep cervical musculature has been studied extensively in people, with more than 55 publications on morphology and function of the perivertebral musculature and its association with neck pain in terms of stability and neuromotor control. *M. multifidus* and *m. longus colli* are considered to be functional stabilizers of the cervical spine (Mayoux-Benhamou *et al.*, 1994), with *m. multifidus cervicis* providing spinal extension (Cagnie *et al.*, 2011) and segmental stability (Boyd-Clark *et al.*, 2001) in a tonic function, and *m. longus colli* providing cervical flexion (O’Leary *et al.*, 2009) and postural stability (Mayoux-Benhamou *et al.*, 1994) in a more phasic manner. *M. multifidus cervicis* has direct attachments onto the joint capsule of the articular process articulation (APA), potentially influencing degenerative joint disease processes linked to neck pain (Anderson *et al.*, 2005). In people with neck pain, CNS adaptations and changes in neuromotor control result in proprioceptive deficits, loss of kinesthetic awareness, altered function around the joints and changes to fiber characteristics of the deep perivertebral stabilizing musculature. It is not known if the same patterns of morphological, biomechanical and neuromotor control (dys)function exist in the cervical spine of the horse. Knowledge of the anatomy of the deep perivertebral musculature of the equine cervical spine is essential to understanding the role of *m. multifidus*

cervicis and *m. longus colli* in terms of spinal stability and sagittal motion and their potential involvement in neck dysfunction and/or pain. The specific aim of this study was to describe the gross morphology of *m. multifidus cervicis* and *m. longus colli* as a first step toward understanding their role in stability and motion in the neck of the horse, which are prerequisites to further investigations into structural and mechanical changes associated with cervical pain and dysfunction in horses.

2.3 MATERIALS AND METHODS

Approval for this study was obtained under the Institutional Animal Care and Use Committee number 02-11/020-00.

The architecture and morphology of *m. multifidus cervicis* and *m. longus colli* were studied through detailed gross dissection in the cervical (C) and cranial thoracic (T) spines of 15 horses (mean \pm SD age: 18.3 \pm 7.3 years) that presented for euthanasia for reasons other than primary neck pain (Table 2.1). Following euthanasia, which was performed according to current AVMA guidelines (<https://www.avma.org/KB/Policies/Documents/euthanasia.pdf>) by intravenous administration of pentobarbital sodium at 86 mg/kg, visceral contents were removed carefully to avoid damaging the thoracic portion of *m. longus colli*, which lies adjacent to the ventral surface of the vertebrae and has attachments as far caudally as T5 or T6 (Getty, 1975; Nickel *et al.*, 1985). After disarticulation of the head at the atlantooccipital joint, the thoracic limbs and extrinsic musculature were removed. The first eight (true) ribs were transected 15 cm ventral to the costovertebral joints and the sternum was removed. The costovertebral and costotransverse

joints were then disarticulated from the vertebral bodies. The thoracic spine was disarticulated between T7 and T8, which is caudal to the most caudal attachment of *m. longus colli*.

The specimen from C1 to T7 was placed on its lateral side on a dissection table. Superficial layers of the cervical and scapulothoracic musculature were carefully removed after identification of intermuscular septae and separation at the perimysial divisions, until the deep perivertebral musculature was exposed. The lamellar and funicular portions of the nuchal ligament were left intact. Specific attention was paid to careful removal of the superficial musculature that had direct attachments onto the dorsal, ventral and transverse processes and articular process articulations (APAs) of the vertebrae, to avoid damaging attachments of the deep musculature to these structures.

M. multifidus cervicis was exposed from C1 to T7 by peeling off the fascial attachments of *m. trapezius cervicis et thoracis* to the funicular portion of the nuchal ligament (cervical region) and the supraspinous ligament (thoracic region). *M. rhomboideus* was removed by dissecting along its borders with *m. splenius*, the funicular portion of the nuchal ligament and *m. spinalis thoracis*. *M. brachiocephalicus* and *m. omotransversarius* were reflected, the latter from its fascial attachments to the dorsal aspect of the transverse processes of C2, C3 and C4. *M. serratus cervicis* was retracted along its fascial separation from the more medial *m. splenius*, and from the fascial attachments to the dorsal aspects of the transverse processes of C3 to C7. *M. longissimus capitis et atlantis* were removed by careful dissection from their fascial connections with the joint capsules of the APAs from C2-C3 to C7-T1. The fascial attachments of *m. semispinalis capitis* were removed from the joint capsule of the APAs at C3-C4 to C6-C7. *M. iliocostalis cervicis* was removed from its cranialmost attachments to the transverse processes of C6, C7 and

T1. *M. longissimus cervicis* was removed from its attachments to the transverse processes of C4 to C7. *M. spinalis cervicis* was identified lateral to the fibrous remnants of the lamellar portions of the nuchal ligament at the level of C4-C5, C5-C6 and C6-C7 and medial to *m. multifidus cervicis*, with a strong tendinous interdigitation with fibers from *m. multifidus* at the level of C7. Caudal to C7, *m. spinalis cervicis* emerged to lie lateral to *m. multifidus thoracis* in the cranial thoracic spine, where it bridged the concavity in the caudal cervical curvature and attached firmly onto the elongating dorsal spinous processes from T1 to T3. Following intact muscle isolation, *m. multifidus cervicis* was divided into three layers (Evans, 1993; Boyd-Clark *et al.*, 2002), according to its vertebral attachments and the number of vertebral levels crossed by the muscle bundles. The three layers were divided into fascicles by careful separation of muscle fiber bundles along the fascial planes and according to their attachment sites. The segmentally-arranged bundles were described from their cranial to their caudal attachments (Stubbs *et al.*, 2006).

The cervical and cervicothoracic portions of *m. longus colli* were isolated by careful removal of the more superficial musculature, the esophagus and the trachea. The remnants of *m. sternocephalicus*, *m. sternothyroideus* and *m. omohyoideus* were removed, exposing *m. longus capitis* in the cranial cervical spine and *m. scalenus medius* in the caudal cervical spine, where it extended across the cervicothoracic junction. The attachments of *m. longus capitis* onto the transverse processes of C2, C3, C4 and C5 and of *m. scalenus ventralis* onto the transverse processes of C5, C6 and C7 were removed. During this process a distinct interdigitation between *m. longus capitis* and *m. scalenus ventralis* on the transverse process of C5 was noted. *M. intertransversarius* remained intact on the lateral aspect in the cervical spine. Both the left and

right sides of each specimen were dissected to evaluate symmetry of muscular architecture and morphology.

Horse	Breed	Age (year)	Gender
1	Thoroughbred	5	Mare
2	Warmblood	18	Gelding
3	Draft	14	Gelding
4	Quarter horse	17	Mare
5	Thoroughbred	21	Mare
6	Thoroughbred	6	Mare
7	Thoroughbred	22	Gelding
8	Thoroughbred	20	Gelding
9	Thoroughbred	18	Gelding
10	Unknown breed	12	Gelding
11	Arabian	21	Mare
12	Quarter horse	24	Mare
13	Pony	8	Mare
14	Quarter horse	29	Mare
15	Warmblood	29	Mare

Table 2.1 Details of the horses used in the study

2.4 RESULTS

M. multifidus cervicis was identified deep to the ventral portion of *m. semispinalis capitis* and adjacent to the lamellar portion of the nuchal ligament between C2 and C4. Cranial to C4, *m. multifidus cervicis* was lateral to the cervical portion of *m. spinalis cervicis*. *M. multifidus cervicis* covered the dorsolateral aspect of the cervical vertebrae from C2 to C6 where it merged seamlessly into *m. multifidus thoracis*. Five fascicles were identified at each vertebral level and their attachments were consistent across specimens. The fascicles were divided into three layers (lateral, medial and deep) according to their cranial and caudal attachments and following the

architectural divisions used to describe the morphology of *m. multifidus* in people (Boyd-Clark *et al.*, 2002) and in dogs (Evans, 1993). Each fascicle attached cranially to a dorsal tubercle of the vertebral body and caudally onto the joint capsule of an APA, with the exception of the most cranial attachments at C2, where the lateral and medial layers interdigitated with tendinous fibers of *m. obliquus capitis caudalis* arising from the caudolateral aspect of the dorsal tubercle. The different attachments at this level are adapted to the atypical morphology of C2 compared with the other cervical vertebrae, and the extensive attachment of the nuchal ligament over the dorsal spinous process.

The lateral layer of *m. multifidus cervicis* consisted of two fascicles (superficial and deep) on each side, that diverged from the midline in a caudolateral direction with each successive pair of fascicles filling the V-shaped gap between the more cranial fascicles (Fig. 2.1). The superficial fascicle of the lateral layer crossed three intervertebral joints, attaching cranially on the dorsolateral edge of the dorsal tubercle of the vertebral body and caudally on the dorsocranial aspect of the APA joint capsule via short tendons (Fig. 2.2). The deep fascicle of the lateral layer was the longest fascicle of *m. multifidus cervicis*, emerging from beneath the superficial fascicle on its ventral aspect and spanning four intervertebral joints (Fig. 2.2). The cranial attachment was on the dorsal tubercle of the vertebral body via a strong tendon that fanned into the muscle belly as it coursed towards its caudal attachment on the dorsocranial aspect of the APA joint capsule via several short tendons (Fig. 2.2). The two fascicles of the lateral layer were separated cranially by a wide flat tendon that extended along the length of the muscle belly of the longest fascicle. Caudally a separate tendon was visible on the dorsal side of the muscle belly that was not continuous with the cranial tendon. The most caudal attachment onto the APA joint capsule was facilitated via a tendinous connection with a strong fibrous band that connected two

adjacent APAs, overlying the lateral vertebral lamina and serving as an anchor for attachment (Fig. 2.3). Throughout their length, fibers from the two fascicles of the lateral layer interdigitated with each other and also attached onto the superficial tendon of the more caudal fascicles. Superficial fascicles from multiple levels conjoined into the tendinous attachment over the APAs and the fibrous bands that bridged adjacent APAs.

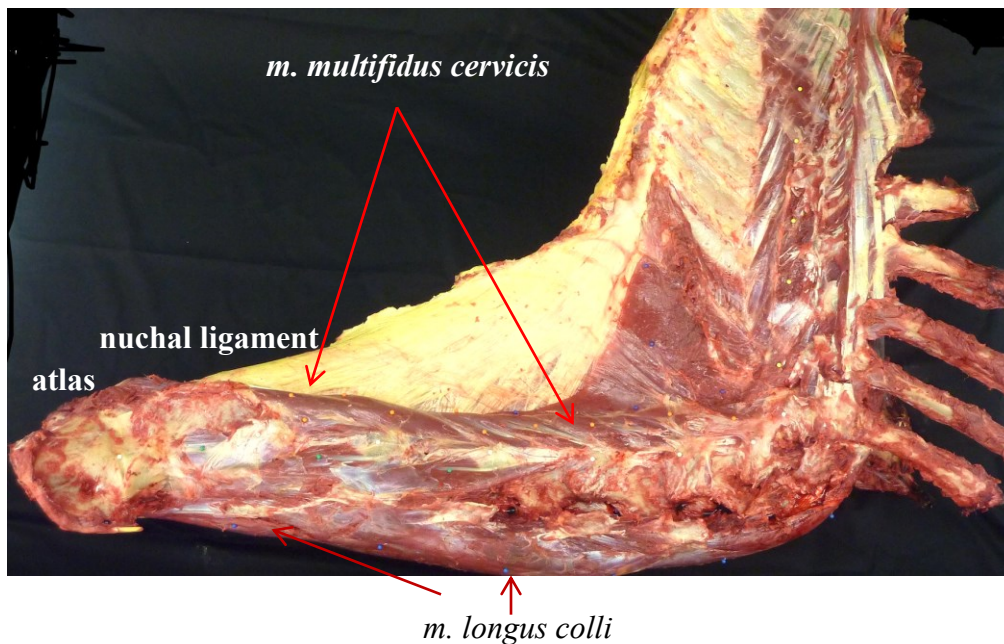


Figure 2.1: Lateral aspect of cervical spine and cervicothoracic junction demonstrating *m. multifidus cervicis* and *m. longus colli* (cranial to T1)

m. multifidus cervicis:
Lateral layer

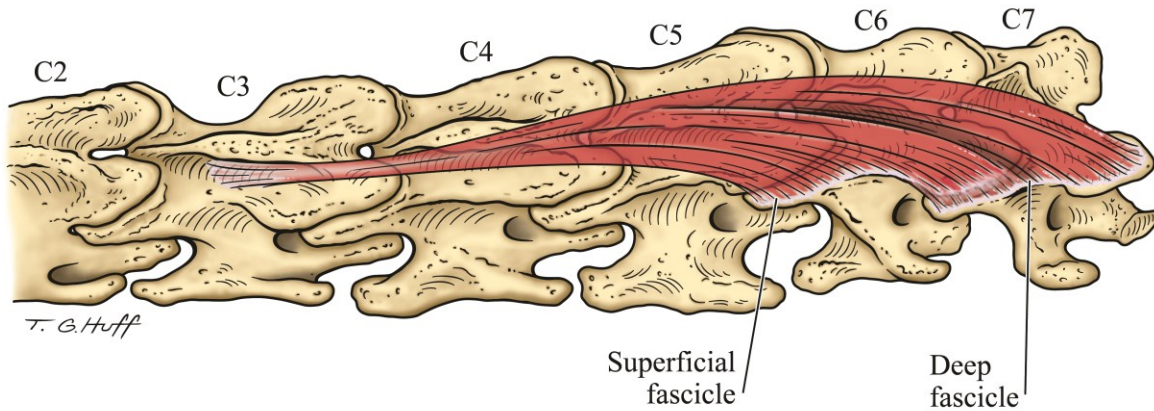


Figure 2.2: Dorsolateral oblique view of lateral layer of *m. multifidus cervicis* indicating cranial and caudal (superficial and deep fascicle) attachments.

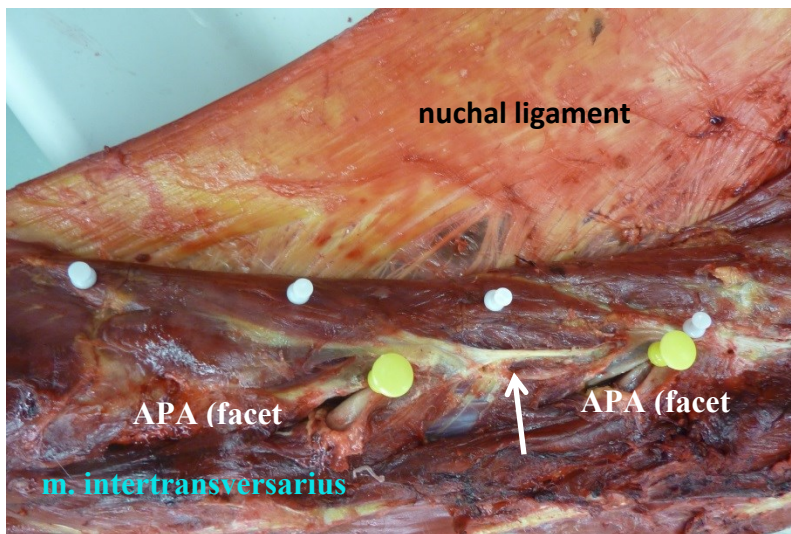


Figure 2.3: Fibrous band (white arrow) along length vertebral body lamina (between yellow markers) for attachment of *m. multifidus cervicis* (white markers)

The medial layer of *m. multifidus cervicis* consisted of two fascicles (short and long) that extended across two and three intervertebral levels respectively. The two fascicles had a common muscular and tendinous cranial attachment on the dorsal tubercle of the vertebral body,

ventromedial to the cranial attachments of the lateral layer, and a caudal attachment on the dorsocranial aspect of the APA joint capsule (Fig 2.4). The musculotendinous units of the medial layer were shorter than those of the lateral layer and had more muscle fibers attaching directly into the fibrous capsule of the APAs. The tendon forming the common cranial attachment for the two fascicles of the medial layer continued into the muscle belly, forming a partial separation between the two fascicles and giving attachment to the pennated muscle fibers (Fig. 2.4).

m. multifidus cervicis:
Medial layer

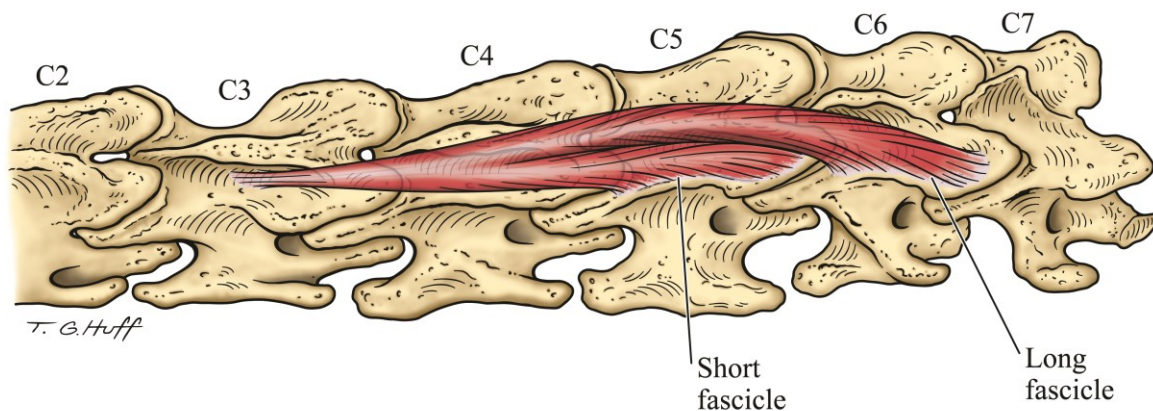


Figure 2.4: Dorsolateral oblique view of medial layer of *m. multifidus cervicis* indicating cranial and caudal (short and long fascicle) attachments

The deep layer of *m. multifidus cervicis* consisted of one fascicle that crossed a single intervertebral joint, spanning the distance between adjacent APAs and filling the concavity on the dorsolateral surface of the vertebral body (Fig 2.5). It had tendinous attachments on the dorsal aspect of successive APA joint capsules, together with muscle fibers that inserted directly into the fibrous band that bridged the length of the lateral lamina of the vertebral body (Fig 2.3).

m. multifidus cervicis:
Deep layer

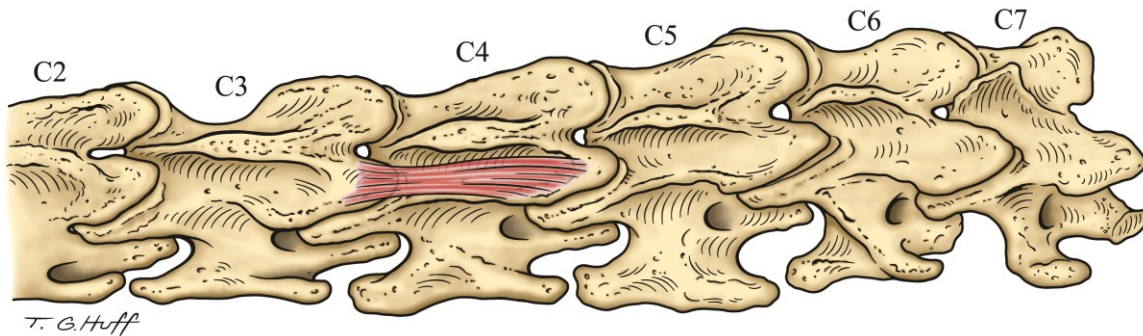


Figure 2.5: Dorsolateral oblique view of deep layer of *m. multifidus cervicis* indicating cranial and caudal fascicle attachments

As the vertebral bodies became shorter in the caudal cervical spine the absolute length of the fascicles of *m. multifidus cervicis* became correspondingly shorter and there was less difference in length between the fascicles of the lateral and medial layers, especially caudal to C5. The attachment pattern of the five fascicles of *m. multifidus cervicis* was maintained across the cervicothoracic junction, but their orientation changed in accordance with the elongation of the thoracic spinous processes to form the withers. *M. multifidus thoracis* continued caudally along the thoracic spine as described by Stubbs *et al* (2006). The change in relative fascicle lengths became most evident caudal to C5. Despite the close proximity of *m. multifidus* to *m. intertransversarius dorsalis*, no direct interdigitations were found, and the two muscle groups were separated by a fibrous band overlying the lateral vertebral lamina (Fig 2.3). The observed cross-sectional area (CSA) of *m. multifidus cervicis* was smallest at its cranial attachment at C2,

increased to a uniform size from C3 to C5 and then became thinner and flatter in the caudal cervical and cranial thoracic regions where it attached to the longer dorsal spinous processes.

M. longus colli occupies the ventrolateral aspect of the vertebral bodies on each side, from the atlanto-occipital joint to T5 or T6. It is deep to *m. longus capitis* in the cranial part of the neck and *m. scalenus ventralis* caudally, with the trachea and esophagus overlying the muscle ventrally. In the cranial thoracic region, *m. longus colli* is surrounded ventrally by the aorta, pleura and viscera, up to and including its most caudal attachment at the level of T5 or T6. Five fascicles of *m. longus colli* originated at each vertebral level from C1 to C5. These fascicles had a cranial attachment on the ventral tubercle of the vertebral body then diverged laterally to their caudal attachment to a transverse process of a more caudal vertebra as far caudally as C6. Fascicles arising from the occiput to C2 had also direct musculotendinous attachments into the ventral aspect of the joint capsules of the APAs. Beyond C6, the caudal attachments were to the medial aspect of the joint capsules of the costovertebral joints and to the ventral longitudinal ligament where this crossed over the thoracic intercentral joints. The part of *m. longus colli* originating from C6 and extending caudally had a well-defined muscle belly without fascicular subdivisions.

Based on the fascicular attachments in the cervical spine, *m. longus colli* was divided into ventral, medial and deep layers, in a similar pattern to the fascicles of *m. multifidus cervicis*. The ventral layer consisted of two fascicles, both of which had a strong cranial tendon attaching onto the ventral tubercle of the vertebral body. The more superficial fascicle of the ventral layer crossed three intervertebral joints before attaching via direct muscle fiber insertions interspersed with tendinous fibers onto the ventrocaudal aspect of the transverse process (Fig. 2.6). The

medial fascicle of the ventral layer was the longest fascicle of *m. longus colli*. It spanned four intervertebral joints from a strong tendon at its cranial attachment on the ventral tubercle of the vertebral body to its caudal attachment on the lateroventral aspect of the transverse process via a musculotendinous insertion (Fig 2.6). From C1 to C5 long thin muscle bellies of the two fascicles of the ventral layer of *m. longus colli* were separated by a fascial septum. Superficial fascicles from the ventral layer from one vertebral level interdigitated with those of the more caudal ventral layers and with tendinous fibers from fascicles of the medial layer.

m. longus colli:
Ventral layer

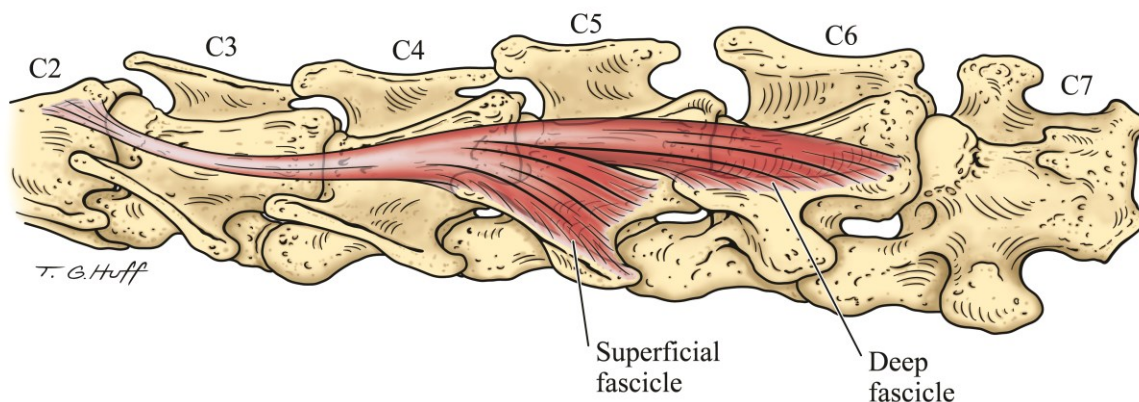


Figure 2.6: Ventrolateral oblique view of lateral layer of *m. longus colli* indicating cranial and caudal (superficial and deep fascicle) attachments

The medial layer of *m. longus colli* consisted of two fascicles (short and long) with cranial attachments on the ventral tubercle of the ventral process, medial to the attachments of the fascicles of the lateral layer, and with caudal attachments on the medioventral aspect of the transverse process, medial to those of the lateral layer (Fig. 2.7). These fascicles spanned two

and three intervertebral levels respectively and, compared with fascicles of the lateral layer, had relatively shorter muscle bellies with longer tendons that extended further into the muscle belly. The longer (and deeper) of the two fascicles of the medial layer had a predominantly muscular cranial attachment whereas the shorter (and more superficial) fascicle was more tendinous in nature with the tendons also inserting on the fibrous band between the cranial and caudal parts of the transverse process (Fig. 2.7). A distinct fibrous band spanned the distance between the cranial and caudal parts of the transverse processes of each cervical vertebra from C3 to C6, and served as an anchor for musculotendinous attachment (Fig. 2.8).

m. longus colli:
Medial layer

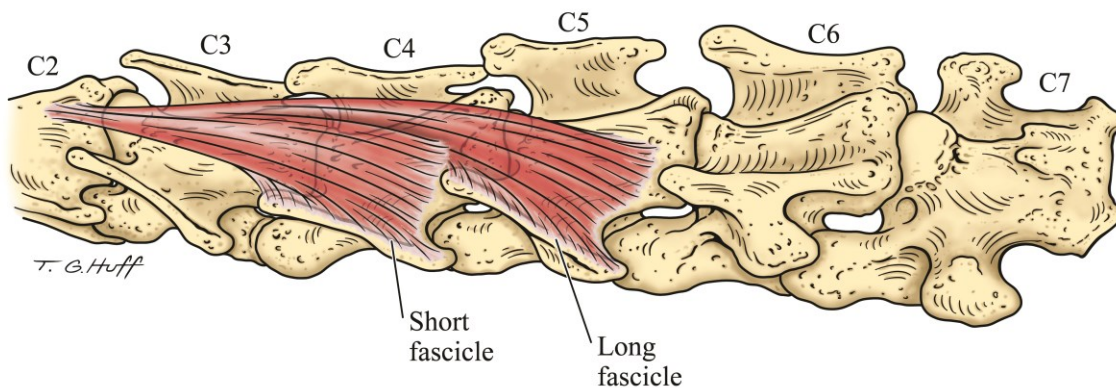


Figure 2.7: Ventrolateral oblique view of medial layer of *m. longus colli* indicating cranial and caudal (short and long fascicle) attachments

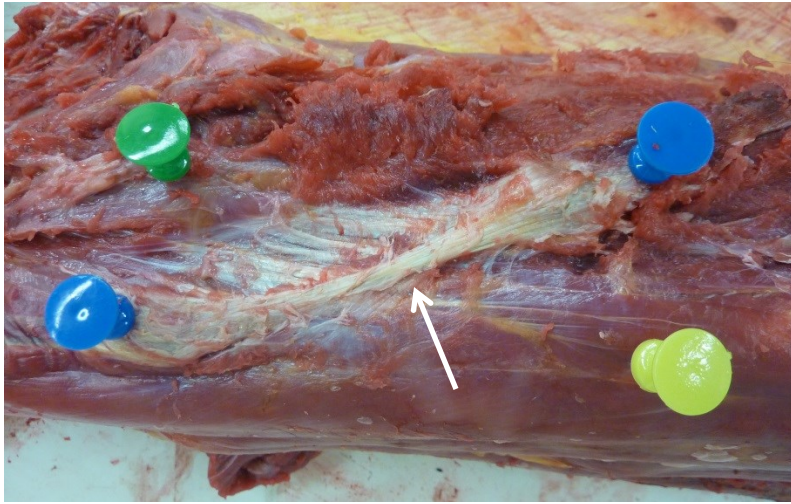


Figure 2.8: Fibrous band (white arrow) across transverse process (between blue markers) for attachment of *m. longus colli* (yellow marker). *M. intertransversarius* (green marker) attaches ventrally over the same fibrous band.

The deep layer of *m. longus colli* consisted of one fascicle that spanned a single intervertebral joint with a muscular cranial attachment onto the lateral aspect of the ventral tubercle of a vertebral body (medial to the cranial attachments of the medial layer) and a tendinous caudal attachment onto the ventromedial aspect of the transverse process of the adjacent vertebra. The fascicle had many tendinous septae interspersed with fleshy muscle fibers. It filled the concavity on the ventral aspect of the vertebral body, between the midline and the transverse process (Fig. 2.9).

m. longus colli:
Deep layer

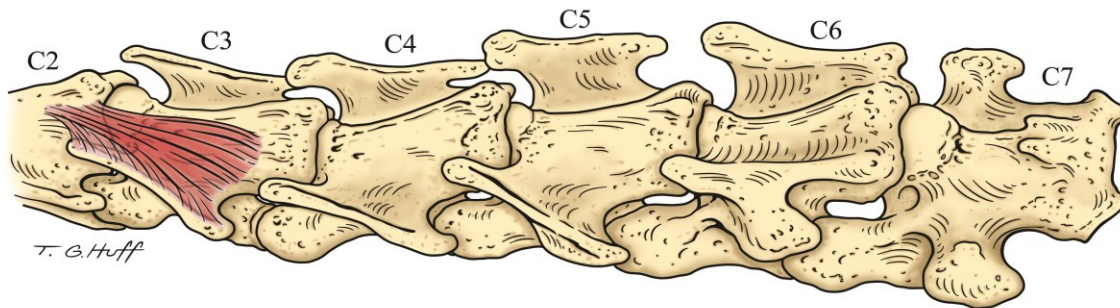


Figure 2.9: Ventrolateral oblique view of deep layer of *m. longus colli* indicating cranial and caudal fascicle attachments

There was no distinct fascial separation between *m. longus colli* and *m. intertransversarius* in the cervical spine. The attachments of *m. intertransversarius ventralis cervicis* to the dorsal aspect of the transverse process interdigitated medially with those of the superficial layer of *m. longus colli* and fibers from both muscles attached on the fibrous band that extended across the transverse process (Fig. 2.8).

The multi-fascicular arrangement of *m. longus colli* was repeated segmentally in the cranial attachments from C1 to C5. The ventral layer of the muscle that originated on C5 terminated in a tendon that inserted into a large single muscle belly as *m. longus colli* continued from the medioventral aspect of the transverse process of C6 to the ventral aspect of the vertebral bodies of T5 or T6. A single deep fascicle was observed in the ventrolateral concavity of the vertebral body of C7. This fascicle had cranial and caudal musculotendinous attachments, extending laterally from the tendon at the caudal aspect of the ventral transverse process of C6 to attach

onto the craniomedial aspect of the costovertebral joint at C7-T1. This fascicle did not attach directly to the transverse process at C7 but filled the concavity directly below the transverse process.

From C6 caudally, *m. longus colli* was represented by a single fusiform muscle belly with parallel fibers that filled the concavity on the ventral aspect of the vertebral bones as far caudally as T5 or T6 (Fig. 2.10). It attached to C6 via a thick, strong tendon from the medioventral transverse process, without direct/superficial attachment to the transverse process of C7 (Fig. 2.10). The tendon became embedded within the muscle belly, then gradually disappeared by the level of T2. Short thick musculotendinous fibers connected the lateral aspect of the muscle to the craniomedial aspect of the fibrous capsule of the costovertebral joints. There were muscular attachments to the ventral aspect of the vertebral bodies and musculotendinous insertions onto the ventral longitudinal ligament where it spanned the intercentral joints (Fig. 2.10). The ventral longitudinal ligament was observed to be thickest over the intercentral joints and consisted of only a few indistinct thin fibers where it crossed the intervening vertebral bodies.

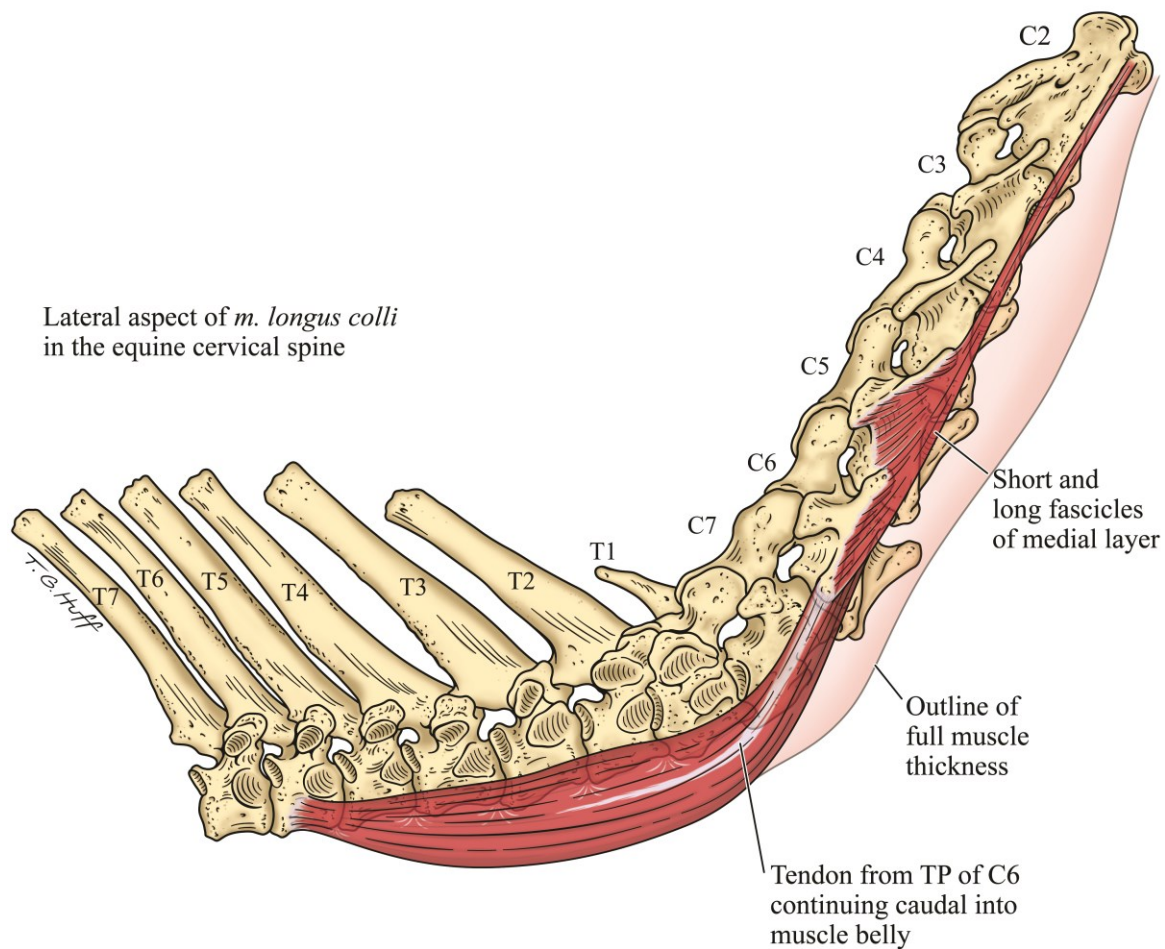


Figure 2.10: Lateral aspect of *m. longus colli* in the equine spine detailing the caudal aspect from C6 – T5/T6

The observed combined CSA of the five fascicles of *m. longus colli* was smallest from C1 to C3, increased from C3 to C5, then decreased markedly. In the thoracic region, the CSA of *m. longus colli* increased from T2 towards the caudal attachment where it decreased abruptly.

In the cervical region, the muscle fibers of *m. multifidus* and *m. longus colli* were orientated at an oblique angle to the long axis of the vertebrae, with the obliquity increasing in the deeper fibers. The lateral and medial layers had longer muscle bellies that extended across multiple segments

whereas the deepest layer had the shortest, most oblique fibers, spanning only one intervertebral joint.

The number of fascicles and their attachment sites were consistent among the horses for *m. multifidus* and *m. longus colli*.

2.5 DISCUSSION

This study describes the gross anatomy of the sagittal deep stabilizing musculature of the equine cervical and cranial thoracic spine. The results showed that *m. multifidus cervicis* and *m. longus colli* were consistent among horses in terms of the number of fascicles and their attachment sites onto the vertebrae. Each muscle has five fascicles per vertebral level from C2 to C6 forming a virtual mirror image on the dorsal and ventral aspects of the vertebrae as they do in people (Mayoux-Benhamou *et al.*, 1994; Anderson *et al.*, 2005). Caudal to C6, *m. multifidus* maintained its multi-fascicular pattern but with changes in fiber orientation to accommodate the elongation of the dorsal spinous processes in the thoracic region. *M. longus colli* was continued caudally by a single muscle belly extending from C6 to T5/T6, with intermediate attachments to the ventral longitudinal ligament overlying the intervertebral discs, where it likely acted to stabilize the joints, and into the joint capsules of the medial costovertebral articulations from T1 to T4/5.

The existing anatomical descriptions of the fascicular arrangements and attachments of the equine *m. multifidus cervicis* and *m. longus colli* vary between anatomical texts and are often rather vague. For example, *m. multifidus cervicis* is noted to have ‘five or six segments with superficial fascicles that pass in an oblique cranio-medial direction from articular process

articulations to the spines of preceding vertebrae' (Getty, 1975) and as representing the 'deepest layer of the long muscles of the neck and back which extend from the sacrum to the 2nd or 3rd cervical vertebrae'(Nickel *et al.*, 1985). Getty (1975) describes *m. longus colli* as having thoracic and cranial parts with origins on the 5th or 6th thoracic vertebra, but does not elaborate on details of the attachments or the precise number of fascicles. In Dyce, Sack and Wensing (1987), *m. multifidus cervicis* is described as a 'less important and obviously more segmental muscle' that forms part of the transversospinalis system and *m. longus colli* is not mentioned.

Functionally, muscles with long, parallel fibers and a small CSA are designed for large excursions and fast velocities of contraction and movement, whereas muscles with short, pennate fibers and large physiological CSA are able to create large forces (Schilling, 2011). The long equine neck, suspended in a somewhat horizontal orientation, requires both long, parallel-fibered and short, pennate-fibered muscles on all aspects of the vertebrae to facilitate and control its motion and stability. Gravity lowers the neck passively, an effect that is enhanced by inertia during locomotion, especially in gaits with a suspension phase. Gravitational forces are opposed by the well-developed dorsal musculature, specifically *m. splenius* and *m. semispinalis capitis*, assisted by the nuchal ligament. Gellman and Bertram (2002a) proposed that the line of action of the nuchal ligament from the withers to its strongest attachment on C2 provides antigravitational support of the neck whilst allowing independent movement of the head. During locomotion it was estimated that elastic strain energy stored in the nuchal ligament contributed 55%, 33% and 31%, respectively, to total energy required to support the head and neck in walk, trot and canter (Gellman and Bertram, 2002b). The simple long-fibered architecture of *m. splenius* with predominantly type I muscle fibers suggests that this muscle actively raises the head and

stabilizes the neck during locomotion. *M. semispinalis capitis* has a more complex architecture with predominantly type I fibers in its dorsal compartment and predominantly type II fibers in its ventral compartment separated by a central energy-storing tendon, which suggests both an anti-gravitational stabilizing function and an active role in raising the head and neck.

The long superficial muscles of the neck affect numerous intervertebral joints simultaneously but their effect cannot be isolated to a single joint. Therefore, a series of short, deep cervical muscles is required to provide localized changes in neck shape and to stabilize the individual intervertebral joints. The multi-fascicular *m. multifidus cervicis* and *m. longus colli* fulfill these functions. Stratification of the deep cervical musculature, which provides simultaneous control of mobility and stability in people (Vasavada *et al.*, 1998), is also present in horses. The longer, thinner muscle bellies and short tendinous attachments of the superficial layers contribute more to multisegmental mobilization whilst the monosegmental fascicle of the deep layer primarily provides intersegmental stability. In the thoracolumbar spine there are five overlapping fascicles of *m. multifidus* at each vertebral segment with an attachment pattern identical to that described here in the cervical spine. Calculation of the moment arms of individual fascicles (McGowan *et al.*, 2007) confirmed that the superficial fascicles are mechanically adapted to produce localized changes in back shape whereas the deeper fascicles are better suited to provide stability of the intervertebral joints. Cross-sectional area of *m. multifidus thoracis et lumborum* increased caudally and was largest at the lumbosacral junction, perhaps indicating an increased need for stabilization in this area where severe osseous pathologies commonly occur (Stubbs *et al.*, 2010). In the cervical and cranial thoracic spines, CSA of *m. multifidus* and *m. longus colli* was greatest in the mid-cervical region at the levels of C4 and C5, according to CSA measurements calculated from ultrasonographic images (Rombach, 2013, thesis Chapter 4). This is also an area showing a

high prevalence of osseous degenerative lesions in the articular process articulations (Rombach, 2013, thesis Chapter 3).

In people with neck pain the direct attachments of *m. multifidus* onto the APAs of the cervical spine, and the resulting tension or shearing of mechanoreceptive and nociceptive nerve endings in the joint capsule, are directly linked with altered proprioception and dysfunction (Cavanaugh *et al.*, 2006; Quinn *et al.*, 2007). Tension on the synovial folds within the APAs is also a contributory factor in human neck pain (Cavanaugh *et al.*, 2006). The similarities in attachment of the equine *m. multifidus cervicis* shown here together with the presence of similar synovial folds within equine cervical APAs (Thomsen *et al.*, 2012) suggest that these may also be sources of cervical pain in horses. Cervical proprioceptive changes lead to altered recruitment patterns of the deep stabilizing musculature (Panjabi, 2006; Azar *et al.*, 2009) and, based on the similarities in architectural arrangement of the equine *m. multifidus cervicis*, we suggest that forces exerted by these muscles on the APAs are not only essential for dynamic stabilization and postural stability but that dysfunction of these muscles is involved in the etiopathogenesis of cervical pain in horses. This may be a key finding in establishing a link between neck pain, loss of intersegmental dynamic stability, proprioceptive deficits and compromised neuromotor control in the horse.

In people, *m. longus colli* has been described as a prevertebral muscle divided into anterior, superior and oblique layers with direct fascicular attachments from the vertebral bodies and the transverse processes of the second or third thoracic vertebrae (individual variation exists) to the anterior arch of the atlas (Mayoux-Benhamou *et al.*, 1994; Cagnie *et al.*, 2010; Javanshir *et al.*, 2011). Muscle recruitment patterns in healthy people identified the function of *m. longus colli* as

flattening of the cervical lordosis and provision of intersegmental joint stability (Falla *et al.*, 2006), as well as segmental co-activation with *m. longus capitis* in craniocervical flexion (Cagnie *et al.*, 2010; Cagnie *et al.*, 2011). The primary function of the overlying *m. longus capitis* appears to be flexion in the cranio-cervical region (Falla *et al.*, 2006) with a synergistic action from *m. longus colli* to flatten the cervical lordosis in the cranial cervical spine. In our equine dissections *m. longus capitis* and *m. longus colli* had common attachments at C2, C3 and C4 suggesting that the two muscles may share a common synergistic function of simultaneous facilitation of dynamic motion and passive support in the cranial cervical region. In people *m. longus colli* terminates around T3, whereas the most caudal attachment of the segmental part of *m. longus colli* in the horse was to the transverse processes of C6. Caudal to this a strong, parallel fibered muscle with a well-developed tendon embedded in it continued beneath the first 5 or 6 thoracic vertebrae representing the hypaxial musculature. Between T6 and T15 there is no direct attachment of hypaxial musculature to the vertebral bodies.

In vitro studies of the equine cervical spine after removal of all muscles have shown that considerable flexion, extension and lateral bending are possible at all the intervertebral (Clayton *et al.*, 1989a; Pagger *et al.*, 2010). *In vivo*, however, the cervical spine is stiffened by the deep perivertebral musculature with most of the motion occurring at the curvatures in the cranial cervical spine and at the cervicothoracic junction (Clayton *et al.*, 2010; Clayton *et al.*, 2011). The cervicothoracic junction serves as a hinge (Gellman *et al.*, 2002) that moves the entire neck (Clayton *et al.*, 2010; Clayton *et al.*, 2011) while the cranial cervical curvature allows independent movement of the head relative to the neck thereby stabilizing the proprioceptive organs (Dunbar *et al.*, 2008). The synergistic interplay between the large, superficial muscles and the small, deep muscles of the equine cervical spine influences spinal motion in standing

(Gellman *et al.*, 2002) and in locomotion (Tokuriki and Aoki, 1991; Wijnberg *et al.*, 2011). Awareness of head and neck position relies on a combination of feed-forward and feedback mechanisms involving vestibular, visual and somatosensory input. Proprioceptive input from muscle spindles, Golgi tendon organs and Pacinian corpuscles in the deep cervical musculature, particularly *m. multifidus*, has been shown to be very important in people (Armstrong *et al.*, 2008) and similar mechanisms have been identified in cats (Richmond and Bakker, 1982; Keshner *et al.*, 1992) and dogs (Sharir *et al.*, 2006). *M. multifidus* likely plays a similar role in cervical proprioception in horses. Human neck pain is associated with loss of preparatory stabilization of the intervertebral joints by the deep perivertebral musculature (Woodhouse and Vasseljen, 2008) due to delayed onset of muscle activation in preparation for movement, fatiguability in craniocervical flexion, relative atrophy and alteration in fiber type properties (Uhlig *et al.*, 1995; Jull and Richardson, 2000; Falla *et al.*, 2004; Javanshir *et al.*, 2011; O’Leary *et al.*, 2011). The muscles become atrophied and the resulting loss of intersegmental spinal stability predisposes the joints to further osteoarthritic or osseous proliferative changes (Anderson *et al.*, 2005; Armstrong *et al.*, 2008; Cagnie *et al.*, 2011). Similarities in the morphology of the deep cervical musculature in people and horses suggest that activation of *m. multifidus* and *m. longus colli* may be altered in horses with cervical dysfunction or pain leading to instability of the cervical intervertebral joints and predisposing the region to osseous degenerative pathologies.

2.6 CONCLUSION

This multi-fascicular morphology of the equine *m. multifidus cervicis* and *m. longus colli* is consistent with a function of providing dynamic segmental stability and support in the equine cervical spine. *M. multifidus* maintains the same anatomical arrangement and attachments through the cervicothoracic junction into the thoracic spine. The multi-fascicular pattern of *m. longus colli* in the cervical region is replaced by a single, well-defined muscle belly that extends from C6 to T5-/T6 and is reinforced by a strong tendon that appears to support the ventral aspect of the cervicothoracic curvature. Effective stabilization by the deep perivertebral muscles is thought to reduce the risk of osteoarthritis and protect the horse against the development of neck pain which is known to be a limiting factor in equine performance.

BIBLIOGRAPHY

BIBLIOGRAPHY

Anderson, J.S., Hsu, A.W., Vasavada, A.N. (2005) Morphology, architecture and biomechanics of human cervical multifidus. *Spine*, 30(4), 86-91.

Armstrong, B., McNair, P., Taylor, D. (2008) Head and neck position sense. *Sports Med*, 38, 101-117.

Azar, N.R., Kallakuri, S., Chen, C. et al. (2009) Strain and load thresholds for cervical muscle recruitment in response to quasi-tensile stretch of the caprine C5-C6 facet joint capsule. *J Electromyogr Kines*, 19, 387-394.

Boyd-Clark, L.C., Briggs, C.A., Galea, M.P. (2001) Comparative histochemical composition of muscle fibres in a pre-and a postvertebral muscle of the cervical spine. *J Anat*, 199, 709-716.

Boyd-Clark, L.C., Briggs, C.A., Galea, M.P. (2002) Muscle spindle distribution, morphology and density in longus colli and multifidus muscles of the cervical spine. *Spine*, 27(7), 694-701.

Buchner, H.H.F., Savelberg, H.H.C.M., Schamhardt, H. et al. (1997). Inertial properties of Dutch Warmblood horses. *J Biomech*, 30, 653–658.

Cagnie, B., D’Hooge, R., Achten, E. et al. (2010) A magnetic resonance imaging investigation into the function of the deep cervical flexors during the performance of craniocervical flexion. *Journ Manipulative Physiol Ther*, 33(4), 286-291.

Cagnie, B., Dirks, R., Schouten et al. (2011) Functional reorganization of cervical flexor activity because of induced muscle pain evaluated by muscle functional magnetic resonance imaging. *Manual Ther*, 16, 470-475.

Cavanaugh, J.M., Lu, Y., Chen, C. et al. (2006) Pain generation in lumbar and cervical facet joints. *J Bone Joint Surg*, 88a(Suppl. 2), 63-67.

Claridge, H.A.H., Piercy, R.J., Parry, A., et al. (2010) The 3-D anatomy of the cervical articular process joints in the horse and their topographical relationship to the spinal cord. *Equine Vet J*, 42, 726-731.

Clayton, H.M., Kaiser, L.J., Lavagnino, M. et al. (2010) Dynamic mobilizations in cervical flexion: Effects on intervertebral angulations. *Equine Vet J*, 42 (Suppl.38), 688-694.

Clayton, H.M., Kaiser, L.J., Lavagnino, M. et al. (2011) Evaluation of intersegmental vertebral motion during performance of dynamic mobilization exercises in cervical lateral bending in horses. *Am J Vet Res*, 73, 1153-1159.

Clayton, H.M., Townsend, H.G.G. (1989a) Kinematics of the cervical spine of the adult horse. *Equine Vet J*, 21, 189-192.

Clayton, H.M., Townsend, H.G.G. (1989b) Cervical spinal kinematics: a comparison between foals and adult horses. *Equine Vet J*, 21, 193-195.

Dunbar, D.C., MacPherson, J.M., Simmons, R.W., et al. (2008) Stabilization and mobility of the head, neck and trunk in horses during overground locomotion: comparisons with humans and other primates. *J Exp Biol*, 211, 3889-3907.

Dyce, K.M., Sack, W.O., Wensing, C.J.G. (1987) Textbook of veterinary anatomy. W.B. Saunders, Philadelphia, United States of America.

Evans, H. E. (1993) Miller's anatomy of the dog 3rd Ed. 295-298, 301, 284. WB Saunders, Philadelphia, United States of America.

Falla, D., Farina, D., Kanstrup Dahl, M. et al. (2006) Muscle pain induces task-dependent changes in cervical agonist-antagonist activity. *J Appl Physiol*, 102, 601-6-9.

Falla, D.L., Jull, G.A., Hodges, P.W. (2004) Patients With Neck Pain Demonstrate Reduced Electromyographic Activity of the Deep Cervical Flexor Muscles During Performance of the Craniocervical Flexion Test. *Spine*, 29, 2108-2114.

Gellman, K.S., Bertram, J.E.A. (2002a) The equine nuchal ligament 1: structure and material properties. *Veterinary Comp Orthopaed*, 15, 7-14.

Gellman, K.S., Bertram, J.E.A. (2002b) The equine nuchal ligament 2: passive dynamic energy exchange in locomotion. *Vet Comp Orthopaed*, 15, 1-6.

Gellman, K.S., Bertram, J.E.A., Hermanson, JW (2002) Morphology, histochemistry, and function of epaxial cervical musculature in the horse (*Equus caballus*). *J Morphol*, 251, 182-194.

Getty, R. (1975) Equine osteology. In: Sisson and Grossman's The Anatomy of the Domestic Animals, 5th edition. Ed: Getty, R. WB Saunders & Co, Toronto, 255-262.

Javanshir, K., Mohseni-Bandpei, M.A., Rezasoltani, et al. (2011) Ultrasonography of longus colli muscle: A reliability study on healthy patients and patients with chronic neck pain. *J Bodyw Mov Ther*, 15(1), 50-56.

Jull, G.A., Richardson, C.A. (2000) Motor control problems in patients with spinal pain: a new direction for therapeutic exercise. *J Manip Physiol Ther*, 23, 115-117.

Keshner, E.A., Baker, J.F., Banovetz, J. et al. (1992) Patterns of neck muscle activation in cats during reflex and voluntary head movements. *Exp Brain Res*, 88, 361-374.

- Mattoon, J.S., Drost, W.T., Grguric, M.R., et al. (2004) Technique for equine cervical articular process joint injection. *Vet Radiol Ultrasoun*, 45, 238-240.
- Mayoux-Benhamou, M. A., Revel, M. Vallée, C., Roudier, R., Barbet, J. P., Bargo, F. (1994) Longus colli has a postural function on cervical curvature. *Surg Radiol Anat*, 16(4), 367-371.
- McGowan, C.M., Hodges, P.W., Jeffcott, L.B. (2007) Epaxial musculature and its relationship with back pain in the horse. A report for the Rural Industries Research and Development Corporation. (www.rirdc.gov.au)
- Nickel, R., Schummer, A., Seiferle, E. et al.,(1985) The anatomy of the domestic animals Volume 1. The locomotor system of the domestic mammals. Verlag Paul Parey, Hamburg, Germany, 274-275, 271.
- O'Leary, S., Cagnie, B., Reeve, A., et al. (2011) Is there altered activity of the extensor muscles in chronic mechanical neck pain? A functional magnetic resonance imaging study. *Arch Phys Med Rehab*, 92, 929-934.
- O'Leary, S., Elliott, J.M., Falla, D. et al. (2009) Muscle dysfunction in cervical spine pain: implications for assessment and management. *J Orthop Sports Phys*, 39(5), 324-333.
- Pagger, H., Schmidburg, I., Peham, C. et al. (2010) Determination of the stiffness of the equine cervical spine. *Vet J*, 186, 338-341.
- Panjabi, M (2006) A hypothesis of chronic back pain: ligament sub-failure injuries lead to muscle control dysfunction. *Eur Spine J*, 15, 668-676.
- Quinn, K.P., Winkelstein, B.A. (2007) Cervical facet capsular ligament yield defines the threshold for injury and persistent joint-mediated neck pain. *J Biomech*, 40, 2299-2306.
- Richmond, F.J.R., Bakker, D. (1982) Anatomical organization and sensory receptor content of soft tissues surrounding upper cervical vertebrae in the cat. *J Neurophysiol*, 48, 49-61.
- Richmond, F.J.R., Singh, K., Corneil, B.D. (2001) Neck muscles in the Rhesus monkey: I. Musclic morphometry and histochemistry. *J Neurophysiol*, 86, 1717-1728.
- Rooney, J.R., Sack, W.O., Habel, R.E. (1967) Guide to the dissection of the horse. Wolfgang O. Sack, NY, USA.
- Schilling, N. (2011) Evolution of the axial system in craniates: morphology and function of the perivertebral musculature. *Front Zool*, 8:4.
- Sharir, A., Milgram, J., Shahr, R. (2006) Structural and functional anatomy of the neck musculature of the dog (*Canis familiaris*). *J Anat*, 208, 331-351.

- Stubbs, N.C., Hodges, P.W., Jeffcott, L.B. et al. (2006) Functional anatomy of the caudal thoracolumbar and lumbosacral spine in the horse. *Equine Vet J* (Supplement), 36, 393-399.
- Stubbs, N.C., Riggs, C.M., Hodges, P.W. et al. (2010) Osseous spinal pathology and epaxial muscle ultrasonography in Thoroughbred racehorses. *Equine Vet J*, 42(Supplement), 654-661.
- Thomsen, L. N., Berg, L. C., Markussen, B. et al. (2012) Synovial folds in equine articular process joints. *Equine Vet J*. DOI: 10.1111/j.2042-3306.2012.00687.x
- Tokuriki, M., Aoki, O. (1991) Neck muscles activity in horses during locomotion with and without a rider. *Equine Exercise Physiology*, 3, 146-150.
- Uhlig, Y., Weber, B.R., Grob, D. et al. (1995) Fiber composition and fiber transformations in neck muscles of patients with dysfunction of the cervical spine. *J Orthopaed Res*, 13, 240-249.
- Vasavada, A.N., Li, S., Delp, S. (1998) Influence of muscle morphometry and moment arms on the moment-generating capacity of human neck muscles. *Spine*, 23(4), 412-422.
- Wijnberg, I.D., Graubner, C., Auriemma, E. et al. (2011) Quantitative motor unit action potential analysis in 2 paraspinal neck muscles in adult Royal Dutch sporthorses. *J Vet Intern Med*, 25, 592-597.
- Woodhouse, A., Vasseljen, O. (2008) Altered motor control patterns in whiplash and chronic neck pain. *BMC Musc Dis*, 9, 90.
- Zsoldos, R.R., Kotschwar, A.B., Kotschwar et al. (2010a) Electromyography activity of the equine splenius muscle and neck kinematics during walk and trot on the treadmill. *Equine Vet J*, 42, (Supplement 38), 455-461.

CHAPTER 3

THE PREVALENCE OF OSSEOUS PATHOLOGY IN THE EQUINE CERVICAL AND CRANIAL THORACIC VERTEBRAE

3.1. SUMMARY

3.1.1 REASONS FOR PERFORMING STUDY: Osteoarthritis (OA) of the articular processes (APs) has been recognised as a clinical condition in the equine cervical spine but there is little information on the prevalence and distribution of OA in the APs of the cervical and cranial thoracic vertebrae.

3.1.2 OBJECTIVES: To determine the prevalence and distribution of OA in the APs of the equine cervical and cranial thoracic vertebrae in relation to vertebral level, side of the neck, and age and size of the horse.

3.1.3 HYPOTHESES: OA in the equine cervical spine is most prevalent and most severe in the APs forming the more mobile joints of the cervicothoracic junction. The prevalence and severity of OA increases with age and size in the horse and OA is equally distributed on left and right sides.

3.1.4 METHODS: The cervical (C1-C7) and cranial thoracic (T1-T7) vertebrae of 53 horses were removed at necropsy and boiled. OA of the dorsal aspect of the APs was graded on a scale of 0 (no osseous lesions) to 3 (severe osseous lesions). A three-factor ANOVA was used to test random effects of horse, age (young, old) and size (small, large) and fixed factors of AP site on the vertebra (cranial, caudal), side (left, right) and vertebral level (C1 to T7).

3.1.5 RESULTS: OA lesions were most severe in the mid-cervical vertebrae (C3-C4) followed by those at the cervicothoracic curvature (C5-T1). Severity of OA did not differ between left and right sides but increased with age and size of the horse, and was greater on the caudal aspect than on the cranial aspect of the vertebrae.

3.1.6 CONCLUSIONS AND POTENTIAL RELEVANCE: OA is symmetrically present with higher severity in the mid-cervical and cervicothoracic regions and a higher prevalence in older and larger horses. These factors support bilateral injections of APs in specific APAs for clinical treatment of OA in the equine cervical spine.

3.2. INTRODUCTION

In the horse, the neck functions mechanically as a cantilevered beam projecting cranially from the trunk segment. The ventrally concave curvature at the craniocervical junction and the dorsally concave curvature at the cervicothoracic junction correspond with the regions of greatest mobility *in vivo* (Clayton *et al.*, 2010; Clayton *et al.*, 2012). The cervicothoracic junction acts as a hinge (Gellman and Betram, 2002a-b), about which the neck moves in flexion, extension and lateral bending (Clayton *et al.*, 2012). The cephalic vestibular organs are stabilised by independent movements of the cranial cervical intervertebral joints (Dunbar *et al.*, 2008) which are anatomically adapted to allow considerable flexion/extension and lateral bending at the atlanto-occipital joint and axial rotation at the atlanto-axial joint (Clayton and Townsend, 1989a).

Changes in neck shape involve movements of the articular process articulations (APAs) (Clayton and Townsend, 1989a) and intercentral joints (Haussler, 1999a) under neuromotor control of the

superficial and deep musculature. The shape, size and angulation of the APs change from the cervical region through the cervicothoracic junction into the cranial thoracic region and this affects the type and amount of motion that occurs (Claridge *et al.*, 2010). Cervical APAs are large with incongruent opposing articular surfaces. The thoracic APs are considerably smaller relative to the size of the vertebral body and have more congruent articular surfaces (Getty, 1975; Withers *et al.*, 2009). Motion patterns are thought to affect the susceptibility to degenerative osseous pathologies including osteoarthritis (OA), which are known to occur in the equine cervical APs (Ricardi and Dyson, 1993; Down and Henson, 2009; Claridge *et al.*, 2010; Thomsen *et al.*, 2012). Studies of the prevalence of OA in the equine APAs have focused on the mid-thoracic through to the lumbopelvic region (Girodroux *et al.*, 2009; Meehan *et al.*, 2009; Cousty *et al.*, 2010; Stubbs *et al.*, 2010). Relatively little is known about the prevalence, type and distribution of OA lesions on the APs of the equine cervical and cranial thoracic vertebrae.

The objectives of the present study were to determine the prevalence, severity and distribution of osseous degenerative lesions in the APs of the equine cervical and cranial thoracic vertebrae in relation to vertebral level, side of the neck, and age and size of the horse. I hypothesized that OA is more prevalent in APs of the more mobile joints in the cervicothoracic region, that the prevalence increases with the age and size of the horse, and that the lesions are equally distributed on left and right sides.

3.3 METHODS

Approval for this study was obtained under Institutional Animal Care and Use Committee number 02-11/020-00. The spines of 53 horses aged 13.75 ± 7.5 years (mean \pm SD) that were presented for euthanasia for reasons other than clinically diagnosed neck pain were assessed.

The dorsal aspect of the APs of the cervical and cranial thoracic vertebrae was evaluated from the cranial aspect of C1 to the caudal aspect of T7. This cut-off point was chosen because *m. longus colli* usually has its most caudal attachment at T5 or T6. Cranial and caudal APs were assessed separately on the left and right sides of each vertebra for the presence of osseous degenerative lesions.

Euthanasia was performed according to current AVMA guidelines by intravenous administration of pentobarbital sodium at 86 mg/kg (www.avma.org/KB/Policies/Documents/euthanasia.pdf). The carcasses were exviscerated, disarticulated at the atlanto-occipital junction, and the thoracic and pelvic limbs with their extrinsic musculature were removed. After transection of the true ribs, the sternum was removed and the costovertebral and costotransverse joints were disarticulated. The skull was removed and the thoracic spine was disarticulated at the level of T7-T8. The musculature was removed and the vertebral bodies were separated by sharp dissection of the supraspinous, interspinous, interarcuate, dorsal longitudinal and ventral longitudinal ligaments and disarticulation at the APAs and the intercentral joints. Each vertebra was boiled for 15 hours to remove any remaining soft tissue. The bones were then scrubbed with water, submerged in a solution of isopropyl alcohol (34.5%), hydrogen peroxide (1.7%), ammonium hydroxide (0.6%) and water (63.2%) for a minimum of 48 hours, washed with water

and air dried. Following drying, the APs of each vertebra were examined to evaluate degenerative osseous lesions.

Following this process, subjects were numbered and separated by age (young: <15 years; old: ≥ 15 years) [18] and by height (small: <150 cm; large ≥ 150 cm). Osseous proliferative lesions were examined at each spinal level. Severity of osseous lesions of the APs (of each subject, one at a time) was evaluated by one examiner and graded according to Stubbs *et al* (2010), based on area and thickness of osseous proliferative lesions in relation to the dorsal surface area of the AP as grade 0: no lesion, grade 1: mild osseous proliferation (evident on 25-50% of the AP), grade 2: moderate proliferation (evident on 50-75% of the AP) or grade 3: severe osseous proliferation (evident on more than 75% of the AP) (Fig. 3.1).

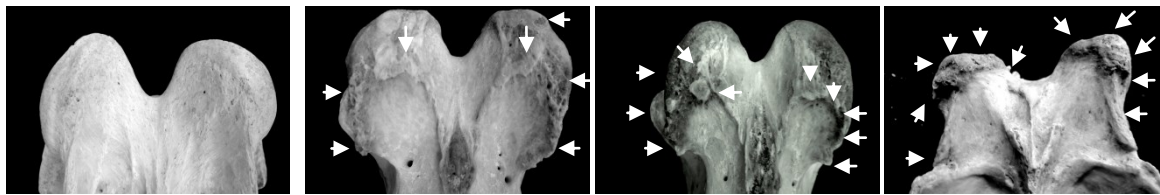


Figure 3.1: Grading of osseous pathology of the articular processes according to size of degenerative changes. The photographs show a dorsal view of the caudal articular processes. White arrows point to osteoarthritic lesions. (Photographs by Nicole Rombach). Left to right: Grade 0: smooth articular surfaces, no proliferative changes; Grade 1: mild proliferative changes; Grade 2: moderate proliferative changes; Grade 3: severe proliferative changes

The four APs (left and right, cranial and caudal) of the 14 vertebrae were graded separately for a total of 56 observations per horse. The mean vertebral pathological grade was calculated by taking the most severe grade recorded at all the four APs of that vertebra in each horse and averaging over all horses. These mean grades were used to represent each vertebral level in the

statistical tests. A mean score was calculated for each pair of cranial or caudal and left or right APs using the higher grade osseous lesion to represent the vertebral site or side, respectively

SAS Software was used to determine summary statistics (mean, SEM) for the mean vertebral pathological grade for each vertebra and for the mean grade at each vertebral site and side. The highest pathological grade recorded for the four APs of each vertebra was used to indicate prevalence of each grade of osseous lesions at each spinal level as percentages of observations across all subjects (Fig. 3.2 - top). Although the Kolmogorov-Smirnov and Shapiro-Wilk tests did not demonstrate normality of distribution for the data describing the mean vertebral pathological grade, further evaluation of histograms showed a normal Gaussian (unimodal and symmetrical) distribution and normal probability plots showed a positive linear relationship, both of which are indicative of a normal distribution (Petrie and Watson, 2006). Therefore, parametric statistical tests were used in the analysis. A three factor ANOVA with horse, age (young, old) and size (small, large) as random and (vertebral level (C1-T7), site (cranial, caudal) and side (left, right) as fixed factors was used to determine main effects and interactions between the random and fixed factors ($P < 0.05$). A post-hoc Bonferroni test which corrected for multiple samples (91 comparisons at $P < 0.05$; critical value = $P < 0.0005$) was then used to detect differences between specific vertebral levels.

3.4 RESULTS

The most common osseous proliferative lesions detected on the APs between C1 and T7 were osteophytes, enthesophytes and lipping. In addition, non-proliferative osseous lesions of intra-articular lysis and eburnation were observed in the APs of some subjects.

The prevalence of the different grades of AP lesions from C1 to T7 is shown in Fig. 3.2. Grade 1 (mild) or grade 2 (moderate) osseous lesions were found in at least one AP in all horses (100%). Grade 3 (severe) osseous lesions were found in at least one AP in 38/53 horses (72%). The prevalence of the different grades of AP lesions from C1 to T7 is shown in Fig. 3.2 (top). The ANOVA showed that vertebral level had an effect ($P < 0.0001$) on mean vertebral pathological grade with more severe OA lesions being present between C3 and T1 (Fig. 3.3). Bonferroni's post-hoc comparisons partitioned the entire vertebral segment into four regions (Fig. 3.3). C1 and C2 had the least severe mean vertebral pathological grade, C3 and C4 had the most severe mean vertebral pathological grade, C5 to T1 showed intermediate mean vertebral pathological grades and T2 to T5 had low pathological grades that decreased caudally with T5 to T7 being similar to C1 and C2.

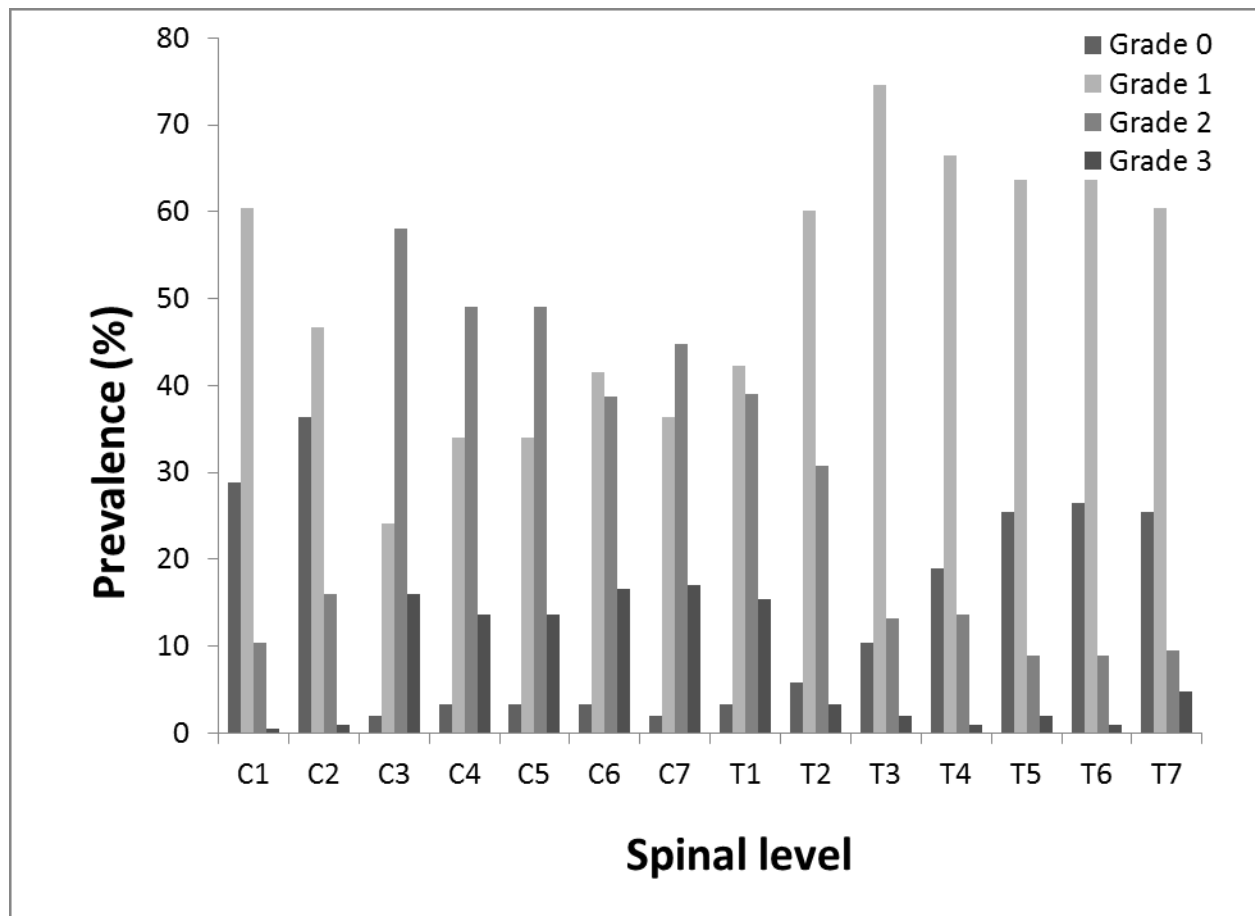
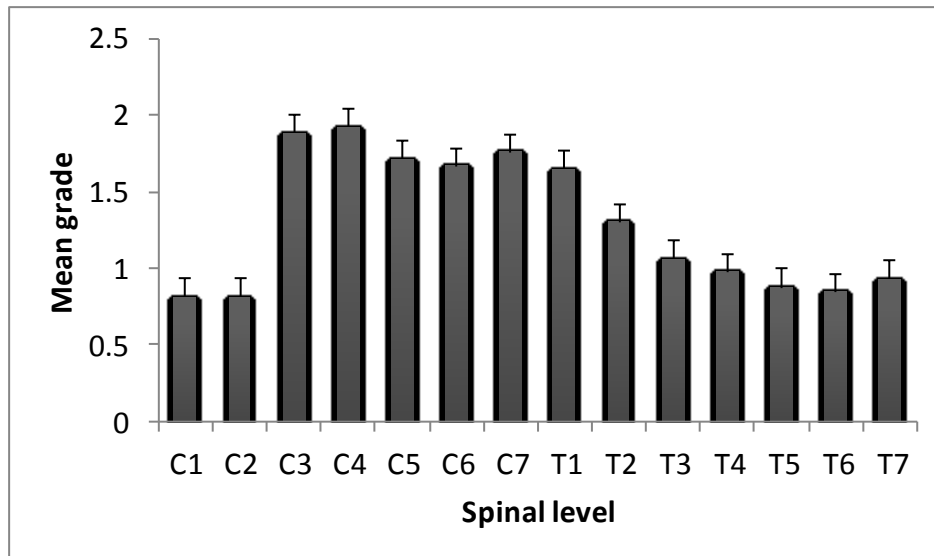


Figure 3.2: Prevalence of the mean grades of osseous lesions recorded across the four articular processes (left and right, cranial and caudal) of each vertebra from the first cervical (C1) to the seventh thoracic (T7) (n = 53 horses).



	C1	C2	C3	C4	C5	C6	C7	T1	T2	T3	T4	T5	T6	T7
C1														
C2														
C3														
C4														
C5														
C6														
C7														
T1														
T2														
T3														
T4														
T5														
T6														
T7														

Figure 3.3: Overall severity and differences in distribution of osseous lesions from the first cervical (C1) to seventh thoracic (T7) vertebra (n=53horses).

Above: Mean grade (0-3) of osseous lesions. Values are mean±SD.

Below: Differences in mean grade of osseous lesions of the articular processes between vertebrae from the first cervical (C1) to the seventh thoracic (T7) (n=53 horses). Shaded boxes indicate a significant difference in the severity of osseous lesions between vertebrae ($P<0.05$).

There were no significant differences in mean pathological grades of osseous lesions on the left and right sides. There were, however, significant effects of the horse's age ($P=0.004$) and size ($P=0.01$) on the mean pathological grade of AP osseous lesions, with older horses and larger horses showing more severe lesions. Overall, osseous lesions on the caudal APs were more severe than those on the cranial APs.

There was an interaction between age and size ($P=0.032$); overall pathological grade was higher in young, large horses than young, small horses ($P=0.001$), in old, small horses than young, small horses ($P=0.0011$) and in old, large horses than young, small horses ($P<0.0001$) (Fig. 3.4). Age also showed an interaction with spinal level ($P<0.0001$); old horses had a significantly higher grade of AP lesions from C2 to T2 (Fig. 3.5). At several spinal levels there was an interaction between pathological grades on the cranial versus the caudal APs ($p<0.0001$); the mean lesion grade was higher on the cranial APs at C1, C3, C4 and T1 and higher on the caudal APs at C2 and from T3 to T7.

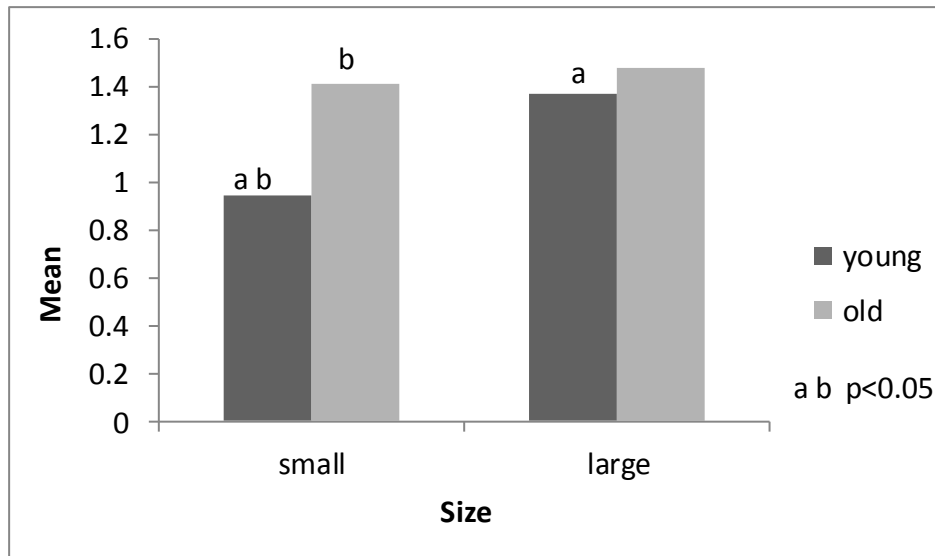


Figure 3.4: Interactions of mean pathological grade between age and size across all subjects (n=53). The letters above the bars denote significant interactions between the variables.

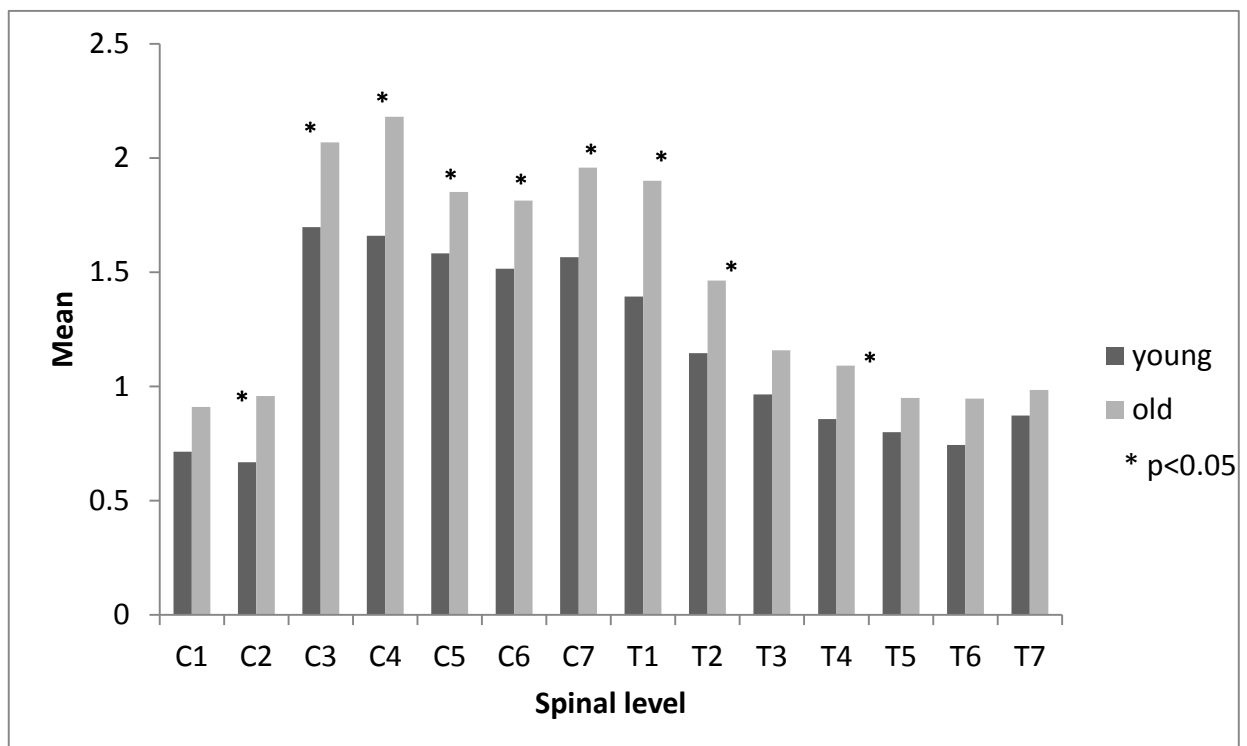


Figure 3.5: Prevalence of mean pathological grade) in young and old horses from C1 to T7 across all subjects (n=53). Significant differences between young and old horses at each spinal level are indicated by an asterisk.

3.5 DISCUSSION

The findings indicate that osseous vertebral lesions occur frequently in the APs of the cervical and cranial thoracic vertebrae. Osseous lesions are most prevalent in the mid-cervical region (C3-C4), followed by the cervicothoracic junction (C5-T1) where >95% of horses had osseous pathological lesions of the APs. This supports my first hypothesis in that osseous lesions are prevalent in the cervicothoracic junction. It is, however, notable that lesions in the mid-cervical region were more prevalent and more severe than expected. Larger and older horses had more severe lesions and lesions were equally distributed between left and right sides, which also supported the experimental hypotheses. Limitations in this study include the inability to evaluate the effect of occupation or workload on cervical APA lesions due to there being insufficient number of horses involved in different sports and the lack of a full anamnesis of all the horses included in this study.

OA in the cervical APAs is recognised as a source of neck pain in horses (Mattoon *et al.*, 2004; Withers *et al.*, 2009; Thomsen *et al.*, 2012). The most common presenting sign is a non-specific loss of performance (Dyson, 2003) which can pose challenges from a diagnostic perspective. The equine thoracolumbar spine has received more attention than the cervical or cranial thoracic spine in terms of investigating osseous lesions. Thoracolumbar lesions include periarticular surface remodeling, sclerotic alterations to subchondral bone or AP surfaces, narrowing of the joint space, dorsal extension of the joint, lytic lesions and complete APA ankylosis (Girodroux *et al.*, 2009). Lesions are more prevalent in the caudal thoracic and lumbar regions than in the cranial thoracic region. The authors hypothesised that biomechanical stresses on the thoracolumbar region predispose to failure of the APAs and osseoligamentous structures.

Contrary to findings in the present study, age, breed and size did not differ significantly between cases with thoracolumbar pain and/or APA lesions and the general clinic (Girodroux *et al.*, 2009). Another study found that periarticular proliferative lesions are most common in APAs of the more mobile thoracolumbar region between T16 and L1 (Cousty *et al.*, 2010). This is similar to my findings that osseous lesions are prevalent in the mobile joints at the cervicothoracic junction, where large forces are required to support and move the entire neck. However, as severe lesions are also prevalent in the APAs of the mid-cervical spine, further investigation is suggested to increase understanding of the biomechanical forces in this region.

Osteoarthritis in the APAs of the equine cervical spine contributes to loss of intervertebral motion, neck muscle atrophy and neck pain (Ricardy and Dyson, 1993; Beck *et al.*, 2002; Dyson, 2003; Levine *et al.*, 2007; Birmingham *et al.*, 2010). To date, descriptions of osseous lesions in the equine cervical spine are limited and have focused on vertebral malformations and stenotic lesions. In horses with cervical vertebral malformation, degenerative lesions included erosion, fibrillation, lipping and change of shape in the APA surfaces (Wagner *et al.*, 1979). Horses with cervical static stenosis showed loss of articular space, changes in thickness of the dorsal lamina and osteochondrosis of the APAs (Powers *et al.*, 1986). Spinal cord compression was accompanied by osseous pathology and joint capsule distension in the APAs (Trostle *et al.*, 1993). Cervical stenotic myelopathy was associated with severe degenerative joint disease of the APAs (Moore *et al.*, 1994). My study identified enthesiophytes at the AP joint margins where the fibrous joint capsule attaches onto the articular pillar. Osteophytes and lipping were most often present around the lateral joint margins of the AP, although it is important to note that osseous proliferation frequently extended medially towards the intervertebral foramen where it may compress the spinal cord or the emerging spinal nerves. The foraminal dimensions at the

cervicothoracic junction decrease when the neck is extended under *ex vivo* conditions (Sleutjens *et al.*, 2010). If similar narrowing occurs *in vivo*, there may be a greater risk of osteophytes causing signs of nerve impingement in this region. The relatively high prevalence of osseous lesions at the cervicothoracic junction may contribute to the identification of clinical issues in this area. Complete ankylosis of the APA (identified in one subject) results in decreased range of motion and is likely to affect loading of the adjacent joints based on the results of *in vitro* testing (Pagger *et al.*, 2010).

In my study group, at least one moderate (Grade 2) osseous lesion was identified at the APs from C1 to T7 for all subjects and 72% of horses had at least one severe (Grade 3) lesion in the APs of cervical and cranial thoracic vertebrae. A similar study in the thoracolumbar spine found at least one moderate (Grade 2) osseous lesion of the vertebral body, its processes or APAs at each of five spinal levels that were examined (T13, L1, L3, L5, S3) and at least one severe (Grade 3) osseous lesion in 77% of the 22 horses examined (Stubbs *et al.*, 2010). Thus, osseous pathology in the cervical and cranial thoracic vertebrae appears comparable in severity to that reported in the thoracolumbar region.

In people with neck pain, the most common aetiologies are whiplash associated disorders (Carroll *et al.*, 2008) chronic facet joint pain from osseous degenerative lesions (Manchikanti *et al.*, 2004) and intervertebral disc degeneration (Bogduk and Aprill, 1995). Episodes of neck pain are often recurrent (Carroll *et al.*, 2008) and therapeutic/prophylactic approaches to prevent recurrence emphasise the concept of efficient neuromotor control by the deep perivertebral stabilizing musculature (Jull and Richardson, 2000; Falla *et al.*, 2007). Dynamic stiffening of the cervical perivertebral musculature prevents excessive motion and stiffens the spine both in

preparation for and during neck movement. Inefficient dynamic control of these muscles results in instability and micromotion of the APAs (Jull *et al.*, 2009), which may predispose to the development of OA (Kumaresan *et al.*, 2001). APA instability or degeneration is associated with pain (McLain, 1994) and results in neurogenic deactivation and subsequent atrophy of the deep cervical stabilizing muscles, *m. multifidus* and *m. longus colli* 34 (Fernández-de-las-Peñas *et al.*, 2008; Javanshir *et al.*, 2011). Horses are thought to follow the same sequence of changes involving neurogenic atrophy of the deep spinal stabilising musculature. This relationship has been confirmed in the equine thoracolumbar spine (Stubbs *et al.*, 2010) where atrophy of *m. multifidus* has been identified ipsilaterally and at the same spinal level as severe unilateral osseous pathology. The morphology of *m. multifidus cervicis* and *m. longus colli* in the equine cervical spine is consistent with these muscles having the same function of providing intersegmental spinal stability and the same potential for dysfunction resulting in intersegmental spinal instability. Interestingly, the cross-sectional area of the equine *m. multifidus cervicis* and *m. longus colli* is normally largest in the mid-cervical region at C4 and C5 (Rombach, 2013, thesis Chapter 4), which corresponds with the region showing high grades of osseous lesions. Further studies should investigate whether there is a direct association between osseous lesions of the cervical vertebrae and suboptimal activation and/or atrophy of *m. multifidus cervicis* and *m. longus colli* at the same spinal levels.

Osseous degenerative changes in the human cervical spine increase with age (Gellhorn *et al.*, 2013) which parallels our findings that horses ≥ 15 years have a higher prevalence of osseous lesions in APs of the cervical and cranial thoracic vertebrae. Age has also been shown to be a factor in enlargement of equine APAs in the caudal cervical spine (C5-6), although this enlargement was not associated with clinical signs (Down and Henson, 2009). Age was not

identified as having a significant effect on the occurrence of osseous lesions in the thoracolumbar spine (Girodroux et al., 2009; O’Leary et al., 2009, Cousty et al., 2010).

The length of the horse’s neck poses some unique problems in terms of dynamic stabilization and susceptibility to injury. Motion of the cervical spine, which is greatest at the cervicothoracic junction (Clayton *et al.*, 2010; Clayton *et al.*, 2012), is both facilitated and limited by the architecture of the vertebral bodies and the specific morphology and orientation of the APAs (Haussler, 1999a). Orientation of the head is controlled by movements between the occiput and C2 (Dunbar *et al.*, 2008). In the mid-cervical and cervicothoracic regions, optimal function of the deep stabilising musculature is required to control both gross and microscopic motion of the intervertebral joints. This is in contrast to the atlanto-occipital region with its atypical articulations that allow for specific joint motion, and the ability to absorb impact forces during locomotion through the elastic properties of the nuchal ligament (Gellman and Bertram, 2002b). In the cranial thoracic spine, range of motion is limited by the orientation of the APs. The high prevalence of osseous lesions in the cervicothoracic junction may be related to the large motion generated to move the entire neck, or failure to stabilise the joints that undergo a large range of motion (Clayton *et al.*, 2010; Clayton *et al.*, 2012). I hypothesise that the high prevalence of osseous lesions in C3 and C4 represents an end-stage of the disease process due to a failure of stabilisation by the deep perivertebral musculature which normally provides spinal stability and stiffness, with osseous degenerative lesions being the end-stage of the disease process. *M. multifidus* and *m. longus colli* have their largest cross-sectional area in the mid-cervical region between C3 and C5, indicating a potential requirement for the provision of stability in this region. These muscles are known to become dysfunctional and atrophied in people with neck

pain (Fernández-de-las-Peñas *et al.*, 2008; Javanshir *et al.*, 2011) and a similar mechanism is thought to be involved in cervical vertebral disease in horses.

From a therapeutic perspective, intra-articular APA injections of anti-inflammatory medications are frequently used to treat horses with signs of neck pain or reduced range of motion that involves arthritic lesions of the APAs (Nielsen *et al.*, 2003; Mattoon *et al.*, 2004; Birmingham *et al.*, 2010). Different injection techniques have been described (Nielsen *et al.*, 2003; Birmingham *et al.*, 2010) but little information is available regarding injection protocols for multiple cervical levels. The prevalence of lesions from C3 through the cervicothoracic junction and the high incidence of bilateral lesions from C3 to T1 reported here supports the practice of performing bilateral injections at the APAs from the level of C3-C4 to the level of C6-C7.

Knowledge of the relationship between spinal dysfunction and suboptimal neuromotor control of the deep stabilising musculature of the cervical spine can be used to design appropriate exercise-based rehabilitation programmes to optimise neuromotor control and dynamic stability. Dynamic mobilisation exercises have been associated with hypertrophy of *m. multifidus* in the equine thoracolumbar spine (Stubbs *et al.*, 2010) and may also be effective in restoring and maintaining function of the cervical deep stabilising muscles, with the goal of preventing the development of osseous degenerative lesions in the equine cervical spine.

3.6 CONCLUSIONS

Osseous lesions of the equine APs are most severe from C3 to T1 and are equally distributed between left and right sides. These findings support the clinical practice of injecting the APAs

bilaterally from C3-C4 to C6-C7 in horses with clinical signs due to OA lesions of the cervical APs. Intervention for pain control should be followed by therapeutic exercises designed to strengthen the deep paraspinal musculature that stabilises the joints in preparation for and during movement, with the goal of preventing recurrence of neck pain due to intersegmental vertebral instability.

BIBLIOGRAPHY

BIBLIOGRAPHY

- Beck, C., Middleton, D., Maclean, A. and Lavelle, R. (2002) Osteochondrosis of the second cervical vertebra of a horse. *Equine Vet. J.* 34, 210-212.
- Birmingham, S. S. W, Reed, S. M., Mattoon, J. S. and Saville, W. J. (2010) Qualitative assessment of corticosteroid cervical articular facet injection in symptomatic horses. *Equine Vet. Educ.* 22, 77-82.
- Birmingham, S. S. W, Reed, S. M., Mattoon, J. S. and Saville, W. J. (2010) Qualitative assessment of corticosteroid cervical articular facet injection in symptomatic horses. *Equine Vet. Educ.* 22, 77-82.
- Bogduk, N. and Aprill, C. (1995) On the nature of neck pain, discography and cervical zygapophysial blocks. *Pain*, 54, 213-217.
- Carroll, L. J., Holm, L. W., Hogg-Johnson, S., Cotê, P., Cassidy, J. D., Haldeman, S., Nordin, M., Hurwitz, E. L., Carragee, E. J., van der Velde, G., *et al* (2008) Course and prognostic factors for neck pain in whiplash-associated disorders (WAD): Results of the bone and joint decade 2000-2010 task force on neck pain and its associated disorders. *Eur. Spine. J.* 17 (Suppl. 1), 83-92.
- Claridge, H. A. H., Piercy, R. J., Parry, A. and Weller, R. (2010) The 3-D anatomy of the cervical articular process joints in the horse and their topographical relationship to the spinal cord. *Equine Vet. J.* 42, 726-731.
- Clayton, H. M. and Townsend, H. G. G. (1989a) Kinematics of the cervical spine of the adult horse. *Equine Vet. J.* 21, 189-192.
- Clayton, H. M., Kaiser, L. J., Lavagnino, M. and Stubbs, N. C. (2010) Dynamic mobilisations in cervical flexion: Effects on intervertebral angulations. *Equine Vet. J.* 42(Supplement 38), 688-694.
- Clayton, H.M., Kaiser, L.J., Lavagnino, M. and Stubbs, N.C. (2012) Evaluation of intersegmental vertebral motion during performance of dynamic mobilization exercises in cervical lateral bending in horses. *Am. J. Vet. Res.* 73, 1153-1159.
- Cousty, M., Retureau, C., Tricaud, C., Geffroy, O. and Caure, S. (2010) Location of radiological lesions of the thoracolumbar column in French trotters with and without signs of back pain. *Vet. Rec.* 166, 41-45.
- Down, S. S. and Henson, F. M. D. (2009) Radiographic retrospective study of the caudal cervical facet articulations in the horse. *Equine Vet. J.* 41, 01-07.

Dunbar, D. C., Macpherson, J. M., Simmons, R. W and Zarcades, A. (2008) Stabilization and mobility of the head, neck and trunk in horses during overground locomotion: comparisons with humans and other primates. *J. Exp. Biol.* 211, 3889-3907.

Dyson, S. J. (2003) The cervical spine and soft tissues of the neck. In: *Diagnosis and management of lameness in the horse*, 1st edn., Eds: M. W. Ross and S. J. Dyson, W.B. Saunders, St.Louis. pp 523-531.

exercise on activation of the deep cervical flexor muscles in people with chronic neck pain. Falla, D., Jull, G., Russell, T., Vicenzino, B. and Hodges, P. (2007) Effect of neck exercise on sitting posture in patients with chronic neck pain. *Phys. Ther.* 87, 408-417.

Fernández-de-las-Peñas, C., Albert-Sanchís, J. C., Buil, M., Benitez, J. C., Albuquerque-Sendín, F. (2008) Cross-sectional area of cervical multifidus muscle in females with chronic bilateral neck pain compared to controls. *J. Orthop. Sports. Phys.* 38, 175-180.

Gellhorn, A. C., Katz, J. N. and Suri, P. (2013) Osteoarthritis of the spine: the facet joints. *Nt. Rev. Rheumatol.* 9, 216 – 224.

Gellman, K. S. and Bertram, J. E. A. (2002a) The equine nuchal ligament 1: structure and material properties. *Vet. Comp. Orthopaed.* 15, 7-14.

Gellman, K. S. and Bertram, J. E. A. (2002b) The equine nuchal ligament 2: passive dynamic energy exchange in locomotion. *Vet. Comp. Orthopaed.* 15, 1-6.

Getty, R. (1975) Equine osteology. In: *Sisson and Grossman's The Anatomy of the Domestic Animals*, 5th edition. Ed: Getty, R. WB Saunders & Co, Toronto, 255-262.

Girodroux, M., Dyson, S. and Murray, R. (2009) Osteoarthritis of the thoracolumbar synovial intervertebral articulations: clinical and radiographic features in 77 horses with poor performance and back pain. *Equine Vet. J.* 41, 130-138.

Haussler, K. K. (1999a) Osseous spinal pathology. *Vet. Clin. N. Am - Equine*, 15, 103-112.

Haussler, K. K., Stover, S. M., Willits, N. H. (1999) Pathology of the lumbosacral spine and pelvis in Thoroughbred racehorses. *Am. J. Vet. Res.* 60, 143-153.

Javanshir, K., Rezasoltani, A., Mohseni-Bandpei, M. A., Amiri, M., Ortega-Santiago, R., Fernández-de-las-Peñas, C. (2011) Ultrasound assessment of bilateral longus colli muscles in subjects with chronic bilateral neck pain. *Am. J. Phys. Med. Rehab.* 90, 293-301.

Jull, G. A. and Richardson, C. A. (2000) Motor control problems in patients with spinal pain: a new direction for therapeutic exercise. *J. Manipulative. Physiol. Ther.* 23, 115-117.

Jull, G. A., Falla, D., Vicenzino, B. and Hodges, P. W. (2009) The effect of therapeutic
Kumaresan, S., Yganandan, N., Pintar, F. A., Maiman, D. J. and Goel, V. K. (2001) Contribution
of disc degeneration to osteophyte formation in the cervical spine: a biomechanical investigation.
J. Orthopaed. Res. 19, 977-984.

Levine, J. M., Adam, E., Mackay J. *et al* (2007) Confirmed and presumptive cervical vertebral
compressive myelopathy in older horses: a retrospective study (1994-2004). *J. Vet. Int. Med.* 21,
812-819.

Manchikanti, L., Boswell, M. V., Singh, V., Pampati, V., Damron, K. S. and Beyer, C. D. (2004)
Prevalance of facet joint pain in chronic spinal pain of cervical, thoracic and lumbar regions.
BMC Musculoskelet.Disord. 5, 1-7.

Mattoon, J. S., Drost, W. T., Grguric, M. R., Auld, D. M. and Reed, S. M. (2004) Technique for
equine cervical articular process joint injection. *Vet. Radiol. Ultrasoun.* 45, 238-240.

McGowan, T. W., Pinchbeck, G., Phillips, C. J. C., Perkins, N., Hodgson, D. R. and McGowan,
C. M. (2010) A survey of aged horses in Queensland, Australia. Part 1: management and
preventive health care. *Aust. Vet. J.* 88, 420-427.

McLain, R. F. (1994) Mechanoreceptor endings in human cervical facet joints. *Spine* 19, 495-
501.

Meehan, L., Dyson, S. and Murray, R. (2009) Radiographic and scintigraphic evaluation of
spondylosis in the equine thoracolumbar spine: a retrospective study. *Equine Vet. J.* 41, 800-807.

Moore, B. R., Reed, S. M., Biller, D. S., Kohn, C. W. and Weisbrode, S. E. (1994) Assessment
of vertebral canal diameter and bony malformations of the cervical part of the spine in horses
with cervical stenotic myelopathy. *Am. J. Vet. Res.* 55, 05-13.

Nielsen, J. V., Berg, L. C., Thoenfer, M. B. and Thomson, P. D. (2003) Accuracy of ultrasound-
guided intra-articular injection of cervical facet joints in horses: a cadaveric study. *Equine Vet. J.*
35, 657-661.

O'Leary, S., Elliott, J. M., Falla, D., Jull, G. (2009) Muscle dysfunction in cervical spine pain:
implications for assessment and management. *J. Orthop. Sports. Phys.* 39, 324-333.

Pagger, H., Schmidburg, I., Peham, C. and Licka, T. (2010) Determination of the stiffness of the
equine cervical spine. *Vet. J.* 186, 338-341.

Petrie, A. and Watson, P. (2006) Statistics for veterinary and animal science, 2nd edn. Blackwell
Publishing, London. pp 39-41.

Powers, B. E., Stashak, T. S., Nixon, A. J., Yovich, J. V. and Norrdin, R. W. (1986) Pathology of
the vertebral column of horses with cervical static stenosis. *Vet. Path.* 23, 392-399.

Ricardi, G. and Dyson, S. J. (1993). Forelimb lameness associated with radiographic abnormalities of the cervical vertebrae. *Equine Vet. J.* 25, 422-426.

Sleutjens, J., Voorhout, G., van der Kolk, J. H., Wijnberg, I. D. and Back, W. (2010) The effect of *ex vivo* flexion and extension on intervertebral foramina dimensions in the equine cervical spine. *Equine Vet. J.* 42 (Supplement 38), 425-430.

Stubbs, N. C., Riggs, C. M., Hodges, P. W., Jeffcott, L. B., Hodgson, D. R., Clayton, H. M. and McGowan, C. M. (2010) Osseous spinal pathology and epaxial muscle ultrasonography in Thoroughbred racehorses. *Equine Vet. J.* 38 (Supplement), 654-661.

Thomsen, L. N., Berg, L. C., Markussen, B. and Thomsen, P. D. (2012) Synovial folds in equine articular process joints. *Equine Vet. J.* DOI: 10.1111/j.2042-3306.2012.00687.x.

Trostle, S. S., Dubielzig, R. R. and Beck, K. A. (1993) Examination of frozen cross sections of cervical spinal intersegments in nine horses with cervical vertebral malformation: lesions associated with spinal cord compression. *J. Vet. Diagn. Inv.* 5, 423-431.

Wagner, P. C., Grant, B. D., Bagby, G. W, et al. (1979) Evaluation of cervical spinal fusion as a treatment in the equine 'wobbler' syndrome. *Vet. Surg.*, 8, 84-88.

Withers, J. M., Voûte, L. C., Hammond, G., Lischer, C. J. (2009) Radiographic anatomy of the articular process joints of the caudal cervical vertebrae in the horse on lateral and oblique projections. *Equine Vet. J.* 41, 895-902.

CHAPTER 4

THE USE OF ULTRASONOGRAPHY FOR REPEATABLE MEASUREMENT OF MUSCLE CROSS-SECTIONAL AREA OF *M. MULTIFIDUS CERVICIS* AND *M. LONGUS COLLI* IN THE EQUINE VERTEBRAL COLUMN

4.1 SUMMARY

4.1.1 REASONS FOR PERFORMING STUDY: In people with neck pain, ultrasonography (US) is used to measure atrophy and response to physiotherapy in the perivertebral muscles of the cervical spine, i.e. *m. multifidus* and *m. longus colli*. It is not known whether neck pain in horses results in measurable atrophy of *m. multifidus cervicis* and *m. longus colli*.

4.1.2 OBJECTIVE: To validate US as a technique for repeatable CSA measurement of *m. multifidus* and *m. longus colli* in the cervical spine of the horse.

4.1.3 HYPOTHESES: I hypothesized that repeatability of US measurements is similar to ‘gold standard’ magnetic resonance imaging (MR) measurements for muscle CSA measurement of *m. multifidus cervicis* and *m. longus colli* (Study 1), and that the technique for US image acquisition is reliable and repeatable for intra- and inter-operator CSA measurements of *m. multifidus cervicis* and *m. longus colli* (Study 2).

4.1.4 METHODS: From MR and US images of three mature pony cadavers, CSA was calculated at vertebral levels C3-C6 (*m. multifidus*) and C2-C5 (*m. longus colli*) (Study 1).

ANOVA analysis compared US and MR image acquisition repeatability (n=360) and CSA (n=1080) among subjects and vertebral levels. Two US operators independently acquired 60 unilateral US images per horse of 5 standing horses (mean±SD: age: 12.1±10.5 years) at spinal levels C3-C6 (*m. multifidus*) and C2-C5 (*m. longus colli*) to calculate CSA (n=360 per operator) (Study 2). ANOVA analysis compared CSA across all subjects within and between operators for effects of vertebral level and repeatability of image acquisition and of CSA calculation.

4.1.5 RESULTS: In study 1 across all subjects, repeatability of image evaluation of *m. multifidus* (C3-C5), the ICC for MR and US was 99% and 61%, respectively. Repeatability of image evaluation was lowest at C6. For *m. longus colli* (C3-C5) across all subjects, the ICC for repeatability of image evaluation was 100% and 88% for MR and US, respectively. Repeatability of image acquisition was lowest at C2. For both muscles, the mean CSA was consistently largest at C4 and C5. In Study 2, intra-operator results for repeatability of image evaluation for *m. multifidus* were 72% (ICC) and 5% (CV), and 90% (ICC) and 4% (CV) between operators. Image evaluation was least repeatable at C6. Intra-operator results for *m. longus colli* were 100% (ICC) and 0% (CV), and 77% (ICC) and 0% (CV) between operators. Image evaluation was least repeatable at C2. The CSA for both muscles was consistently largest at C4 and C5.

4.1.6 CONCLUSIONS AND POTENTIAL RELEVANCE: Based on these results, ultrasonography could be used in the live horse for repeatable CSA measurement of *m.*

multifidus and *m. longus colli* in the mid-cervical spine. This technique may advance knowledge of causes and effects of neck pain in horses.

4.2 INTRODUCTION

Neck pain in horses is increasingly recognized as a contributing factor to poor performance (Dyson, 2003; Mattoon *et al.*, 2004; Withers *et al.*, 2009; Thomsen *et al.*, 2012). The equine cervical spine is susceptible to lesions such as intervertebral disc disease (Adams *et al.*, 1985), cervical vertebral malformation (Wagner *et al.*, 1979), cervical static stenosis (Powers *et al.*, 1986), compressive spinal cord lesions (Papageorges *et al.*, 1987), compressive vertebral myelopathy (van Biervliet *et al.*, 2006; Levine *et al.*, 2007), cervical stenotic myelopathy (Moore *et al.*, 1984) and degenerative joint disease of the articular process articulations (APAs) (Dyson, 2003; Mattoon *et al.*, 2004; Levine *et al.*, 2007; Withers *et al.*, 2009; Birmingham *et al.*, 2010). Major causative factors of neck pain in the horse are thought to include the biomechanical demands of stabilization of the cervical spine whilst maintaining head and neck position sense in locomotion, increased forces during athletic activity, and traumatic accidents that can cause direct injury to the neck.

In people, spinal stability is achieved by interdependent optimal functioning of the osseoligamentous, muscular and neural systems (Jull and Richardson, 2000; Reeves *et al.*, 2007), with a specific emphasis on achieving stability through timely central nervous system control of feed-forward (preparatory stabilisation) and feedback (sensorimotor control) mechanisms (Paulus and Brumagne, 2008; Sjölander *et al.*, 2008; Reeves *et al.*, 2011). Two deep stabilizing muscles of the cervical spine, namely *m. multifidus* and *m. longus colli*, play a pivotal role in intersegmental stabilization and movement of the intervertebral joints, as well as in facilitation of

movement of the head and neck (Mayoux-Benhamou *et al.*, 1994; Kamibayashi and Richmond, 1998; Boyd-Clark *et al.*, 2001; Boyd-Clark *et al.*, 2002; Anderson *et al.*, 2005; Cagnie *et al.*, 2011). Both of these muscles are implicated in people with neck pain (Falla and Farina, 2007; Falla *et al.*, 2007; Armstrong *et al.*, 2008; Elliott *et al.*, 2008; Fernández-De-Las-Peñas *et al.*, 2008; Siegmund *et al.*, 2008; O’Leary *et al.*, 2009; Elliott *et al.*, 2010; Cagnie *et al.*, 2011; Javanshir *et al.*, 2011; O’Leary *et al.*, 2011). In people, neck pain is known to alter muscle properties (Uhlir *et al.*, 1995; Falla and Farina, 2008) and activation patterns (Jull *et al.*, 2004; Falla and Farina, 2007; Fernández-de-las-Peñas *et al.*, 2008; Elliott *et al.*, 2010; Cagnie *et al.*, 2011; Lindström *et al.*, 2011; O’Leary *et al.*, 2011) of *m. multifidus* and *m. longus*. In addition, the cross-sectional area (CSA) of *m. multifidus* and *m. longus colli* is reduced and/or asymmetrical between the left and right sides in affected vertebral segments of the cervical spine (Kristjansson, 2004; Fernández-de-las-Peñas *et al.*, 2008; Javanshir *et al.*, 2009; Javanshir *et al.*, 2011).

Muscle CSA measurement via ultrasonography (US) is a validated technique in human clinical and research practices for repeatable measurement of the size of *m. multifidus* and *m. longus colli* in the cervical spine (Kristjansson, 2004; Lee *et al.*, 2007; Whittaker *et al.*, 2007; Jesus *et al.*, 2008; Lee *et al.*, 2009; Javanshir *et al.*, 2010; Peolsson *et al.*, 2012). Measurements are used in a functional diagnostic setting and as a tool to analyze changes in muscle size in rehabilitative programs that employ specific muscle activation techniques to strengthen the stabilizing musculature of the spine. These programs aim to prevent the progression of degenerative joint disease including osteoarthritis (OA) and recurrence of episodes of neck pain, caused in part by a lack of spinal stability due to dysfunction of the perivertebral stabilizing musculature (Hides *et al.*, 1996; Bronfort *et al.*, 2001; Jull *et al.*, 2002; Jull *et al.*, 2008; Jull *et al.*, 2009).

The morphological characteristics of *m. multifidus* and *m. longus colli* have been described in the cervical spine of the horse (Rombach *et al.*, 2013, accepted for publication). *M. multifidus cervicis* is made up of five muscle fascicles that cross between one and four intervertebral joints, with direct attachments onto the dorsal process, the dorsomedial lamina of the vertebral body and the articular process articulations throughout the cervical spine. *M. longus colli* is made up of five muscle fascicles that cross between one and four intervertebral joints, and has direct attachments onto the ventral process, the ventromedial aspects of the vertebral body and the transverse process up to and including the level of C6. Based on their respective morphological characteristics and patterns of attachments, both muscles potentially have a similar function to those in people, in terms of providing dynamic intersegmental spinal stability and facilitation of proprioception for head and neck position sense.

In the horse, US has been validated as a reliable and repeatable tool for CSA measurement of *m. multifidus* in the thoracolumbar spine (Stubbs, 2011), and according to US CSA measurements it has been shown that ipsilateral atrophy (a reduction of CSA) of *m. multifidus* occurs at the same thoracolumbar levels as osseous pathology (Stubbs *et al.*, 2010). Regular performance of dynamic mobilization exercises in horses was shown to increase muscle CSA according to US measurements of *m. multifidus* in the thoracolumbar spine (Stubbs *et al.*, 2011). Thus, US has been reported to be a useful measurement tool in the assessment of thoracolumbar injuries in horses, and in evaluating the effects of therapeutic rehabilitative treatment for dysfunction in the thoracolumbar region, based on measurements of *m. multifidus* CSA (Stubbs *et al.*, 2010; Stubbs, 2011).

A descriptive study (Berg *et al.*, 2003) used US to identify anatomical structures of the equine cervical spine. The borders of the vertebral bodies, the articular process articulations (APAs) and the fascial definitions of superficial and deep cervical musculature were identified and based on these findings, US is suggested as a non-invasive means for investigation of anatomical structures in the equine cervical spine. To date there is no validated technique for measuring the CSA of the deep stabilizing musculature in the cervical spine of the horse. The aim of this study was to develop a technique for repeatable CSA measurement of *m. multifidus* and *m. longus colli* in the equine cervical spine.

The objective of this post-mortem study (Study 1) was to develop a technique using US as a repeatable method to measure CSA of *m. multifidus* and *m. longus colli* in the equine cervical spine, by comparing repeatability of evaluation of US measurements of CSA to repeatability of evaluation of measurements using the gold standard of magnetic resonance imaging (MR). I hypothesized that repeatability of evaluation of US measurements would be similar to repeatability of evaluation of MR measurements for muscle CSA measurement. I also hypothesized that repeatability of image acquisition is higher in the mid-cervical spine (C3-C5) than in the cranial (C2-C3) or caudal (C6-C7) cervical spine.

The objective of this study (Study 2) was to develop a repeatable technique within operator and between operators for US image evaluation of *m. multifidus cervicis* and *m. longus colli* at different levels in the cervical spine in the live horse, based on the technique for US CSA muscle measurement that was developed in Study 1. I hypothesized that the technique for US image evaluation is repeatable for intra- and inter-operator CSA measurements of *m. multifidus cervicis* and *m. longus colli*. I also hypothesized that image evaluation is more repeatable in the mid-

cervical spine (C3-C5) than in the cranial (C2-C3) or caudal (C6-C7) cervical spine, and that the CSA of *m. multifidus* and *m. longus colli* is largest in the mid-cervical spine.

4.3 MATERIALS AND METHODS

Approval for this study was obtained under Institutional Animal Care and Use Committee number 02-11/020-00.

For Study 1, three small (<120cm) pony mares (mean±SD: age: 17.5±7.5 years) were presented for euthanasia for reasons other than known neck pain. Following euthanasia, which was performed according to current AVMA guidelines using intravenous administration of pentobarbital sodium (Vortech Pharmaceutical Ltd.) at 86 mg/kg, each pony was placed in lateral recumbency with the neck in a horizontal line from the withers and the head at a 45° angle to the neck. A helper ensured that this constant head and neck position were maintained throughout US image acquisition. One operator (NR) acquired transverse-oblique US images of *m. multifidus cervicis* and *m. longus colli*, following the protocol for US image acquisition that was developed in a pilot study. Two horses were imaged on the left and right side, one horse was imaged on the right side only, for a total of five image full sides of US image acquisition. Ultrasound images of *m. multifidus cervicis* were acquired at C3, C4, C5 and C6. Ultrasound images of *m. longus colli* were acquired at C2, C3, C4 and C5. Three different images were taken at each level. The transducer was removed from the neck after each image was taken and the protocol for muscle identification at each spinal level was repeated after each image capture. The images were transferred and stored for later analysis. After US image acquisition of *m. multifidus cervicis* and

m. longus colli on one side of the neck, the subject was turned manually to lateral recumbency on the opposite side. The US image acquisition and storage protocol was then repeated on the other side of the neck in two of the three subjects. For each side of the neck, a total of 12 US images was obtained for *m. multifidus cervicis*, and a total of 12 US images was obtained for *m. longus colli*. The images were analyzed using the processing programme Image J. The process for measuring muscle CSA involved evaluation by tracing the outline of the muscle on the US image on the computer screen, using the intermuscular septae of *m. multifidus* and *m. longus colli* (Appendix A). Following image calibration, the software calculated the muscle CSA based on the traced area and the scaling factor. The images were evaluated blindly three separate times by one operator (NR).

Following US image acquisition, each pony hoisted onto the MR scanner table (Siemens Espree, 1.5 T MR from Siemens Healthcare, Melvern, PA, USA) for MR image acquisition. Two ponies were imaged in dorsal recumbency and one was imaged in lateral recumbency. Once the table was moved into the bore, four-channel extremity coils were placed over the cervical spine (Fig. 4.1). For image acquisition of *m. multifidus cervicis* and *m. longus colli*, the cervical spine was divided into cranial, middle and caudal regions. Each pony was manually positioned in the isocentre for each of the three regions, and was moved manually in between sequences. Due to the restrictions of the bore size, all ponies were imaged with the table partially out of the MR unit. The image parameters were all using a field of view of 40 cm: T1 - TE = 12 ms, TR = 930, slice thickness = 4 mm, Averages = 2, flip angle of 150 degrees - Time of acquisition 3 minutes 30 seconds. PD - TE = 29 ms, TR = 2280, slice thickness = 4 mm, Averages = 1, flip angle of 150 degrees - Time of acquisition 6 minutes. T2 turbo spin echo - TE = 100 ms, TR = 7820, slice thickness = 4 mm, Averages = 2, flip angle = 150 degrees, acquisition 8 minutes.

Images were acquired at 3mm slices without an interstice gap. T1, T2 and PD images were acquired in transverse and sagittal planes. Following MR image acquisition, transverse MR image slices were chosen for CSA evaluation. The MR images of *m. multifidus cervicis* were taken at roughly the same site and level on the vertebral body as that of the US image acquisition of *m. multifidus cervicis*, namely, caudal to the APA joint of C2-C3, C3-C4, C4-C5 and C5-C6. The MR images of *m. longus colli* were taken at approximately the same anatomical site on the vertebral body as that of the US image acquisition of *m. longus colli*, namely, ventral to the dorsocaudal portion of the transverse process of C2, C3, C4 and C5. The MR images for both muscles were analyzed using the processing programme Image J. The process for measuring muscle CSA involved evaluation by tracing the outline of the muscle on the MR image on the computer screen, using the intermuscular septae between *m. multifidus* and *m. longus colli* and the adjacent muscles as fascial borders (Appendix B). Following calibration, the software calculated the muscle CSA, based on the traced area and the scaling factor. The images were evaluated blindly three separate times by one operator (NR). For two of the subjects both left and right sides of *m. multifidus cervicis* and *m. longus colli* were evaluated at each of the spinal levels where images were taken. For the third subject, the MR images *m. multifidus cervicis* and *m. longus colli* were evaluated on one side only at each of the spinal levels where the MR images were taken. This process produced CSA measurements for five sides.

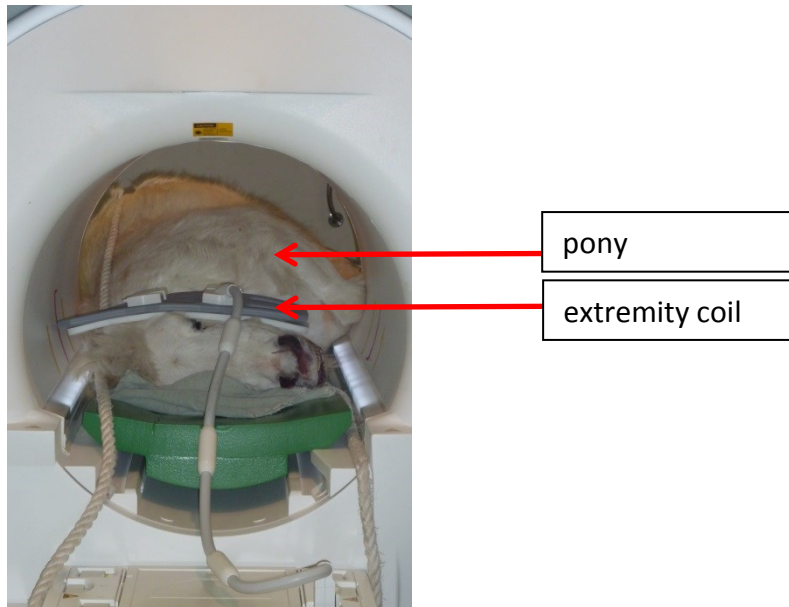


Figure 4.1: Position of a subject in lateral recumbency in the MR machine for MR image acquisition of the cervical spine.

For statistical analysis, the difference between repeatability of US image acquisition and image evaluation was analyzed by a random effects ANOVA model, comparing US CSA measurements to CSA measurements of the magnetic resonance (MR). *M. multifidus cervicis* was evaluated at cervical levels C3, C4, C5 and C6. *M. longus colli* was evaluated at cervical levels C2, C3, C4 and C5. The response variable was the muscle CSA, expressed in cm^2 . Data from the CSA measurements from three different US and MR images were used to analyze the repeatability of image acquisition. Each of the three US and MR images was measured separately and blindly three times to generate data for the repeatability of image evaluation. Results from US and MR CSA measurements were evaluated separately. The factors that could affect repeatability of image acquisition and image evaluation were the random factors of image acquisition, image evaluation and horse for MR and US. Analysis of repeatability of image

acquisition was based on the evaluations from three separate image acquisitions. Analysis of repeatability of image evaluation was based on the evaluations of the three blinded evaluations of each image that was acquired. Errors were evaluated by means of a normal probability plot and histograms and normality was accepted (Petrie and Watson, 2006). Variances and degrees of freedom for each random factor of muscle, level, horse and technique were reported. Repeatability of image acquisition and image digitization was evaluated by means of intraclass correlation (ICC) and coefficients of variation (CV). In the context of this study, the ICC measures the reliability of the measurements (evaluations) and the CV expresses the size of variation relative to the size of the measurements (evaluations).

To determine intra- and inter-operator repeatability for image acquisition and evaluation of US measurements of CSA of *m. multifidus cervicis* and *m. longus colli* (Study 2), five different horses (two mares and three geldings, mean \pm SD: age: 12.1 \pm 10.5 years) were used. Each horse was imaged in standing on one occasion by two operators (NR and NS) using real-time ultrasonography, with a VingMed System 5 ultrasound machine with a curvilinear 2.5-10 Mhz probe at a 12cm depth. Ultrasound image acquisition was carried out according following the US image acquisition protocol that was developed in a pilot study with 20 horses, with a technique that was adapted from Berg *et al* (2003). Each operator recorded the images for *m. multifidus* and *m. longus colli* separately. Both operators recorded images on the same side of each subject (random left or right). Three images were acquired at each site for each muscle (a total of 36 images per muscle per operator). The transducer was moved away from the neck after each image was taken and the protocol for muscle identification at each spinal level was repeated after each image capture. The images were transferred and stored for later analysis. Due to Institutional

Animal Care and Use Committee restrictions on the duration of time under sedation, only one side of the neck could be imaged by both operators for each subject during the data collections.

For statistical analysis, the repeatability of intra- and inter-operator US image acquisition and muscle CSA measurement in the live horse was analyzed by a random effects ANOVA model. Errors were evaluated by means of a normal probability plot and histograms and normality was accepted (Petrie and Watson, 2006). The response variable was the muscle CSA, expressed in cm^2 . *M. multifidus cervicis* was evaluated at cervical levels C3, C4, C5 and C6. *M. longus colli* was evaluated at cervical levels C2, C3, C4 and C5. Image acquisitions from both operators (NR and NS) were evaluated blindly and separately. For each muscle and level, the factors that could affect intra- and inter-operator repeatability were the random factors of operator, observer, trial (image acquisition), repetition (image evaluation) and horse according to following statistical model:

$$RV = \mu + H + Op + H*Op + T(H*Op) + Ob + Ob*H + Ob*Op + Ob*H*Op + T(Ob*H*Op) + \text{Rep}(H*Op*T*Obs)$$

where H=horse(5), Op=Operator(2), T=Trials(3,nested), Ob=Observers, Rep=repetitions(3, nested)

Variances and degrees of freedom for each random factor of muscle, spinal level and horse were reported. Intra-operator and inter-operator CSA measurements were evaluated for repeatability and variability of image acquisition and image evaluation by means of intraclass correlation (ICC) and coefficients of variation (CV).

4. RESULTS

In Study 1, for *m. multifidus cervicis*, the mean ICC across all subjects and all spinal levels for MR measurements was excellent for repeatability of image acquisition (99%) and image evaluation (100%). The repeatability between horses was poor (1%). The mean CV across all subjects and all spinal levels for MR measurements showed low variability for image acquisition (2%) and no variability for image evaluation (0%). For US measurements, the mean ICC across all subjects and all spinal levels was lower for image acquisition and (46%) than for image evaluation (100%). The mean CV across all subjects and all spinal levels was higher for image acquisition (15%) than for image evaluation (0%). Tables of full results for each spinal level can be found in Appendix C.

	MR		US	
	ICC	CV	ICC	CV
Acquisition	99%	2%	46%	18%
Evaluation	100%	0%	100%	0%
Horse	1%	29%	60%	5%

Table 4.1: Mean ICC and CV across all subjects and spinal levels for MR and US CSA measurements of *m. multifidus cervicis*.

For *m. longus colli*, the mean ICC across all subjects and all spinal levels for MR measurements was excellent for reliability of image acquisition (100%) and image digitization (94%). The mean CV across all subjects and all spinal levels for MR measurements showed a low variability for image acquisition (3%) and no variability for image digitization (0%). For US measurements, the mean ICC across all subjects and all spinal levels was lower (69%) for image acquisition than for image evaluation (100%). The mean CV across all subjects and all spinal levels showed

higher variability for image acquisition (8%) than for image evaluation (1%). Tables of full results for each spinal level can be found in Appendix C.

	MR		US	
	ICC	CV	ICC	CV
Acquisition	100%	3%	69%	8%
Evaluation	94%	0%	100%	1%
Horse	6%	15%	32%	15%

Table 4.2: Mean ICC and CV across all subjects and spinal levels for MR and US CSA measurements of *m. longus colli*.

For Study 2, for *m. multifidus cervicis*, the mean ICC across all subjects and all spinal levels was lower for intra-operator repeatability (72%) than for inter-operator repeatability (94%) of image acquisition and image evaluation. Variability across all subjects and spinal levels was low (CV=3%) for intra-operator variability of image acquisition and image evaluation, and there was no variability for inter-operator variability of image acquisition and image digitization. Tables of full results for each spinal level can be found in Appendix D.

	ICC	CV
Intra-operator	72%	3%
Inter-operator	94%	0%
Horse	6%	15%

Table 4.3: Mean ICC and CV across all subjects and spinal levels for intra- and inter-operator CSA measurements of *m. multifidus cervicis*.

For *m. longus colli*, the mean ICC across all subjects and all spinal levels was higher for intra-operator repeatability (ICC=100%) than for inter-operator repeatability (ICC=77%) of image acquisition and image evaluation. The mean variability was higher (CV=8%) for inter-operator than for intra-operator (CV=0%) variability of image acquisition and image evaluation across all subjects and spinal levels. Tables of full results for each spinal level can be found in Appendix D.

	ICC	CV
Intra-operator	100%	0%
Inter-operator	77%	8%
Horse	24%	17%

Table 4.4: Mean ICC and CV across all subjects and spinal levels for intra- and inter-operator CSA measurements of *m. longus colli*.

The mean CSA was calculated at four spinal levels across all subjects (n=5) and from US measurements by both operators. Across all subjects, the mean muscle CSA for *m. multifidus cervicis* and *m. longus colli* was largest at spinal levels C4 and C5 (Fig. 4.2 and Fig. 4.3).

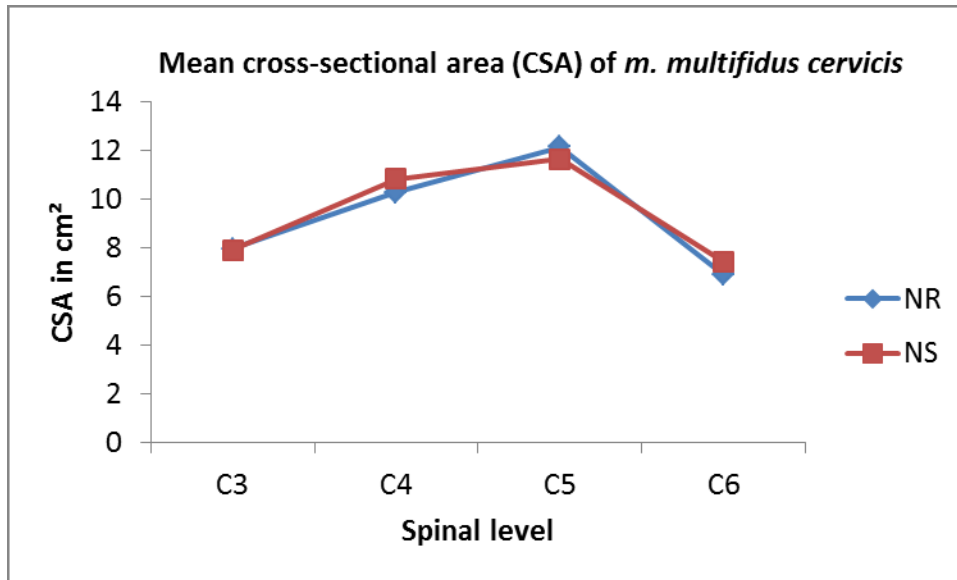


Figure 4.2: Mean cross-sectional area (CSA) expressed in cm² of *m. multifidus cervicis* at four spinal levels across all subjects and as measured by two different US operators.

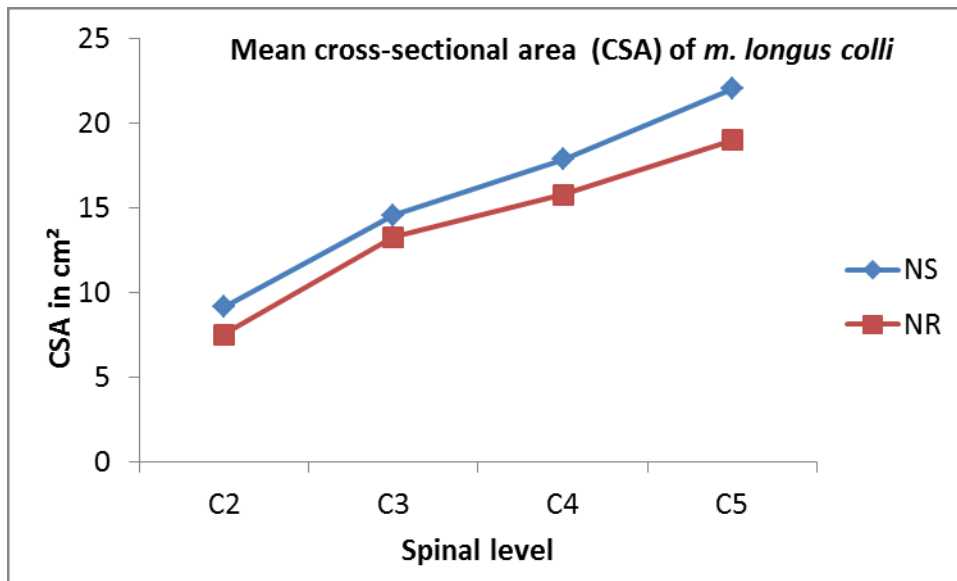


Figure 4.3: Mean cross-sectional area (CSA) expressed in cm² of *m. longus colli* at four spinal levels across all subjects and as measured by two different US operators.

5. DISCUSSION

The first aim of this study was to develop a technique for using ultrasonography (US) as a technique for repeatable measurement of the cross-sectional area (CSA) of *m. multifidus cervicis* and *m. longus colli* in the equine cervical spine. Using this US technique for muscle CSA measurement, the second aim of this study was to demonstrate repeatable US image acquisition and CSA measurement of *m. multifidus cervicis* and *m. longus colli* in the equine cervical spine, within and between different US operators. Muscle CSA measurements are used in clinical therapeutic settings as an objective tool to evaluate perivertebral muscles in human patients with neck pain.

In Study 1, magnetic resonance imaging (MR) was used as the ‘gold standard’ as compared to US, for analysis of repeatability of muscle CSA measurement of *m. multifidus cervicis* and *m. longus colli* in the equine cervical spine. This protocol has been used in similar studies in people (Elliott *et al.*, 2006; Lee *et al.*, 2007; Cagnie *et al.*, 2009) and in the thoracolumbar spine of the horse (Stubbs, 2011). For *m. multifidus cervicis*, the repeatability for muscle CSA measurement on the MR images was high with a mean intraclass correlation coefficient (ICC) of 99% and variability was low with a mean coefficient of variation (CV) of 2% across all subjects. In comparison, the repeatability for muscle CSA measurement of the US images of *m. multifidus cervicis* was lower with a mean ICC of 46% and showed a higher variability with a mean CV of 18% (Table 4.1). This result was likely due to the fact that spinal level C6 had an ICC value of 2% for CSA measurement with US, which swayed the mean ICC (Appendix C). The mean ICC for CSA measurements with US for C3, C4 and C5 was 61%. At the spinal level of C6 it was difficult to obtain clear fascial borders with US, potentially due to the fact that *m. multifidus*

cervicis has a strong interdigitation with *m. spinalis cervicis* at this spinal level. This affected muscle CSA evaluation at this level. In dissection it is virtually impossible to separate these two muscles at this site of interdigitation (thesis, Chapter 2). For *m. longus colli* across all subjects, the repeatability for muscle CSA measurement of the MR images was high with a mean ICC of 100%, and was without variability (mean CV =0%) (Table 4.2). In comparison, the repeatability for muscle CSA measurement of the US images of *m. longus colli* was lower with a mean ICC of 69%. Similar to *m. multifidus cervicis*, there was one spinal level (C2) with a low mean result (ICC= 9%) that swayed the results for mean repeatability of muscle CSA measurement across all spinal levels (Appendix C). The mean ICC for US image acquisition for C3, C4 and C5 was 88%. US image acquisition of *m. longus colli* at C2 was challenging due to the fact that the ventral aspect of the vertebral body has little concavity compared to the more caudal cervical vertebrae. In dissection it is consistently observed that the muscle CSA of *m. longus colli* is considerably smaller at C2 than at the more caudal cervical vertebrae (Rombach, thesis Chapter 2). It was not possible to consistently identify anatomical landmarks in repeated US image acquisitions at C2. The effects of spinal level on repeatability of US image acquisition of *m. multifidus cervicis* and *m. longus colli* in the equine cervical spine are not unexpected. During my pilot study it became evident that *m. multifidus cervicis* at C6 and *m. longus colli* at C2 were challenging to capture on US image. A key consideration is the effect of head and neck position of the standing horse, which may affect US image acquisition at different cervical spinal levels. In the MR unit, the head-neck angle and the neck of the subjects was much more extended than in the live subjects, allowing for clear definition of muscle borders on MR images. Human studies have shown that changes in lordosis will affect results of US and MR muscle measurements and images in terms of size (CSA) and shape (Elliott *et al.*, 2006; Cagnie *et al.*,

2009). This is due to the fact that scanning planes in the MR machine are different to those of the US images ultrasound, based on US transducer position in relation to the neck (to gain the optimal perpendicular position for US image acquisition). For this reason I chose not to compare US and MR muscle CSA measurements for each technique, due to the difference in head and neck position of the subjects for US and MR image acquisition. Instead, I used MR as the ‘gold standard’ for muscle CSA measurement based on the fact that MR images offer a clear display of anatomical borders, and compared this with muscle measurement from US images taken at the same spinal levels.

In Study 2, two experienced US operators acquired US images of *m. multifidus cervicis* and *m. longus colli* at four different levels in the equine cervical spine, using the protocol for the US imaging technique as defined in Study 1. In people, intra-operator reliability for CSA measurement of *m. multifidus* at C4 is described as ‘acceptable’ and inter-operator reliability ‘questionable’ (Kristjansson, 2004). The repeatability of US image acquisition and CSA calculation for *m. multifidus* is described as ‘good’ for measurements between C3 and C6, both for within-day (ICC=96%) and between-days measurements (ICC=88%) (Fernandez-de-las-Peñas *et al.*, 2008). My results in Study 2 show that the inter-operator repeatability of US measurements of *m. multifidus cervicis* (mean ICC= 90%) is higher than the intra-operator reliability (mean ICC=72%). Spinal level C5 gave an unexpected low result for intra-operator reliability (21%), which swayed the data for overall intra-operator reliability, although the intra-operator variance at this level was low (CV= 4%) (Appendix D). A reason for this may be the

head and neck position during image acquisition in the standing horse, which resulted in a different lordosis of the caudal cervical spine.

In US CSA measurement of *m. longus colli* at the level of C5-C6 in people, Cagnie *et al.*, (2009) concluded that intra-operator repeatability was higher than inter-operator repeatability (ICC=71% and ICC=68% respectively). The repeatability for US image acquisition and CSA calculation for *m. longus colli* is described as ‘good’ for measurements at C6, both within day (ICC=86%) and between days (ICC=81%) (Javanshir *et al.*, 2009). Mc Gaugh and Ellison (2011) found moderate and good intra-operator and moderate inter-operator repeatability by two different operators for CSA measurements of *m. longus colli* at C4. My results from Study 2 show excellent (ICC=100%) intra-operator but a lower (ICC=77%) inter-operator reliability for CSA measurement of *m. longus colli*. This confirms my hypothesis that intra-operator repeatability is high for US image acquisition and digitization of *m. longus colli*.

The repeatability for image acquisition for *m. multifidus* in the thoracolumbar spine of the horse is described as ‘good’ (ICC= 83%), based on within-day measurements from two different operators (Stubbs, 2011). Based on use of the same US image acquisition protocol as Stubbs (2011), my findings suggest that US can be used repeatably within a single US session for image acquisition of *m. multifidus cervicis* and *m. longus colli* in the equine cervical spine. A future study could be performed with US image acquisition over different days, to evaluate repeatability over time.

Studies 1 and 2 both identified the factor of horse as having a lower repeatability and showing a larger variance between horses, than the factors of image acquisition and image evaluation. Similar to findings in studies with people and in the thoracolumbar spine of the horse, the results

of my studies suggest that muscle CSA measurements of *m. multifidus* and of *m. longus colli* should not be compared between horses.

In people, factors that are known to affect repeatability of US image acquisition of *m. multifidus cervicis* and *m. longus colli* are the operator (Kristjansson, 2004), position of the ultrasound transducer (Lin *et al.*, 2009, Cagnie *et al.*, 2009, Javanshir *et al.*, 2009) and consistency in identification of anatomical landmarks (Lin *et al.*, 2009). For optimal repeatability, these studies suggest a single US operator, a consistent protocol for ultrasound transducer placement, clear identification of known anatomical landmarks in the US image and acquisition of multiple images (three). For optimal repeatability of US image acquisition of *m. multifidus* in the thoracolumbar spine of the horse (Stubbs, 2011), operator experience is cited as a key factor, and it is suggested that multiple images are acquired and analyzed by the same operator, and that the same machine is used for repetition of image acquisition.

Based on findings from my studies, I suggest a protocol of multiple US image acquisitions and image evaluations, carried out by one experienced operator. Although intra-operator repeatability was perfect for *m. longus colli* (ICC=100%), intra-operator repeatability was lower for *m. multifidus cervicis* (ICC=72%). Similarly, the repeatability was different between operators for *m. longus colli* (ICC=77%) and *m. multifidus cervicis* (ICC=94%). It is essential that the same anatomical landmarks are identified at each spinal level of interest prior to US image acquisition. This involves a sound knowledge of identification of anatomical landmarks with US in the equine cervical spine. The angle of the ultrasound transducer must retain the same perpendicular/oblique direction throughout the imaging session as alteration to this angle or

direction will change the area of the muscle shown on the US image, affecting CSA digitization. Based on observations in my pilot study, alterations in the head/neck position of the horse during US image acquisition could have a distinct effect on the shape of the muscle as it appears on US image. This finding needs to be evaluated further to determine if a significant difference is present. It is recommended that the head and neck of the horse are maintained straight and at a constant height throughout the entire US imaging session, if possible. However, this too is a realm for future study.

In Study 2, *m. multifidus cervicis* and *m. longus colli* had the largest CSA at the levels of C4 and C5 (Fig. 4.2 and Fig. 4.3). The identification of C4 and C5 as spinal levels with the largest CSA of *m. multifidus cervicis* and *m. longus colli* is an interesting finding because osseous lesions in the articular process articulations of the equine cervical spine appear to be most severe at the spinal levels of C3 and C4 (Rombach, thesis Chapter 3). In people, the CSA of the deep stabilizing muscles (*m. multifidus* and *m. longus colli*) becomes reduced and/or asymmetrical between the left and right sides in segments of spinal dysfunction (Kristjansson, 2004; Fernández-de-las-Peñas *et al.*, 2008; Javanshir *et al.*, 2009; Javanshir *et al.*, 2011), and ipsilateral atrophy of *m. multifidus* occurs in the thoracolumbar spine of the horse at the site and side of osseous lesions (Stubbs *et al.*, 2010). There have not been any studies linking muscular dysfunction of *m. multifidus cervicis* and *m. longus colli* with osseous pathology in the equine cervical spine. Based on their morphological design in the horse, *m. multifidus cervicis* and *m. longus colli* are thought to fulfil functions of feedforward (dynamic preparatory stabilization) and feedback (sensorimotor control) mechanisms. These mechanisms are essential elements of the

neural system as it relates to neuromotor control of head and neck position sense in people (Paulus and Brumagne, 2008; Sjölander *et al.*, 2008). In human patients with neck pain, these key mechanisms of neuromotor control of the cervical spine are compromised, resulting in loss of intersegmental/intervertebral stability and altered muscular functioning (Woodhouse and Vasseljen, 2008). A symmetrical increase in the CSA of the deep perivertebral spinal musculature is cited as a key aim in rehabilitative therapy to improve segmental stability of the cervical spine, and to prevent recurrence of episodes of neck pain (Jull *et al.*, 2008; Jull *et al.*, 2009), as evaluated via US CSA measurements taken over time. In the horse, specific activation exercises have been shown to promote a symmetrical increase in CSA of *m. multifidus cervicis*, a key stabilizer of the thoracolumbar spine (Stubbs *et al.*, 2011).

Specific exercises for mobilization and stabilization are a key intervention to break the (often recurrent) cycle of neuromuscular dysfunction and osseous lesions in human neck pain (Bronfort *et al.*, 2001; Jull *et al.*, 2002). The aim of these therapeutic exercises is to promote hypertrophy and symmetrical development of *m. multifidus cervicis* and *m. longus colli* and reduce the recurrence of neck pain. This is a well-established directive in rehabilitative treatment of human neck pain (Jull *et al.*, 2008; Jull *et al.*, 2009). A similar approach could be considered for the horse. With the use of US to measure CSA of *m. multifidus cervicis* and *m. longus colli*, objective evaluation of horses with neck pain could be performed to determine if changes in size of muscles can be detected with therapeutic intervention for equine neck pain. This evaluation may be particularly relevant in the mid-cervical spine (C3-C5) where osseous lesions are most severe and more prevalent (Rombach, thesis Chapter 3).

4.6 CONCLUSIONS

Ultrasonography is a non-invasive tool that can be used by an experienced operator for objective measurement of muscle size. The results of this study show that US can be used for repeatable muscle CSA measurement of *m. multifidus cervicis* and *m. longus colli* at specific spinal levels in the equine cervical spine. Based on my findings, I propose US to be a useful tool for objective measurement of muscle CSA in the equine cervical spine.

APPENDICES

APPENDICES

APPENDIX A: Ultrasound and magnetic resonance images of *m. multifidus cervicis*

Ultrasound (US) images of *m. multifidus cervicis* (MF) at C3 (Fig A.1), C4 (Fig. A2), C5 (Fig. A3), C6 (Fig. A4), demonstrating the anatomical landmarks for US image acquisition (left hand side): AP (caudal aspect of articular process articulation of preceeding vertebral level); VB (vertebral body), and the cross-sectional shape of the muscle (right hand side). The dorsal aspect of the vertebral body is on the left hand side of the image, the ventral aspect of the vertebral body is on the right hand side of the image.

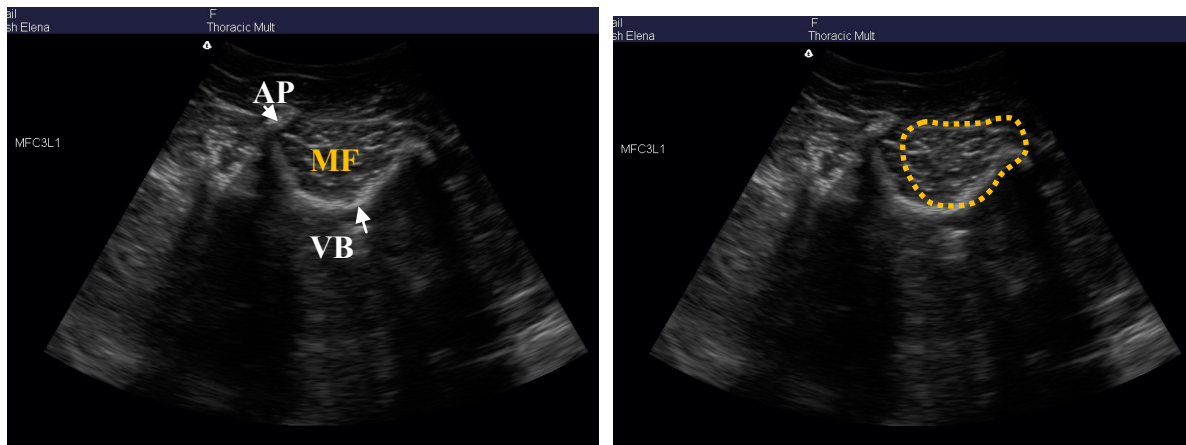


Figure A1: Ultrasound (US) images of *m. multifidus cervicis* at C3

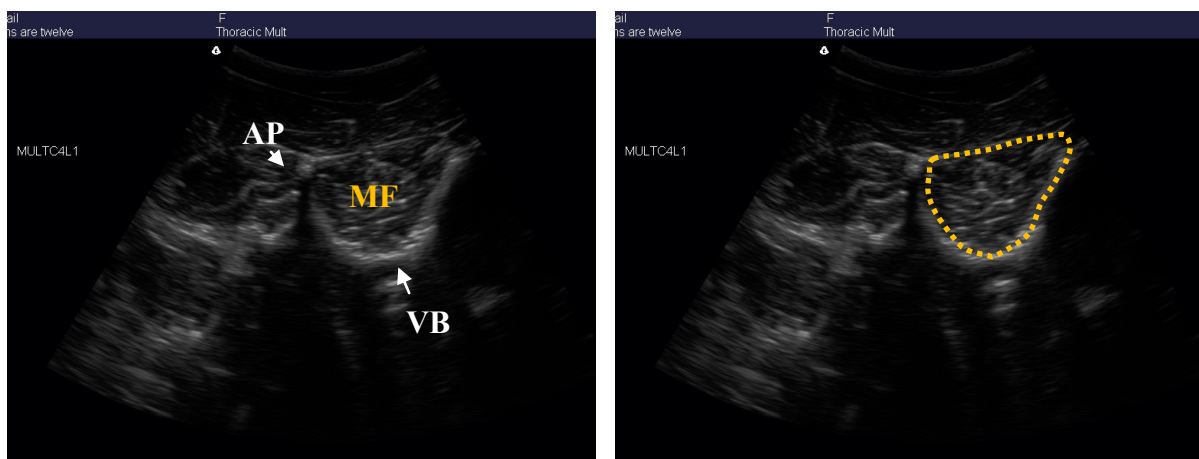


Figure A2: Ultrasound (US) images of *m. multifidus cervicis* at C4

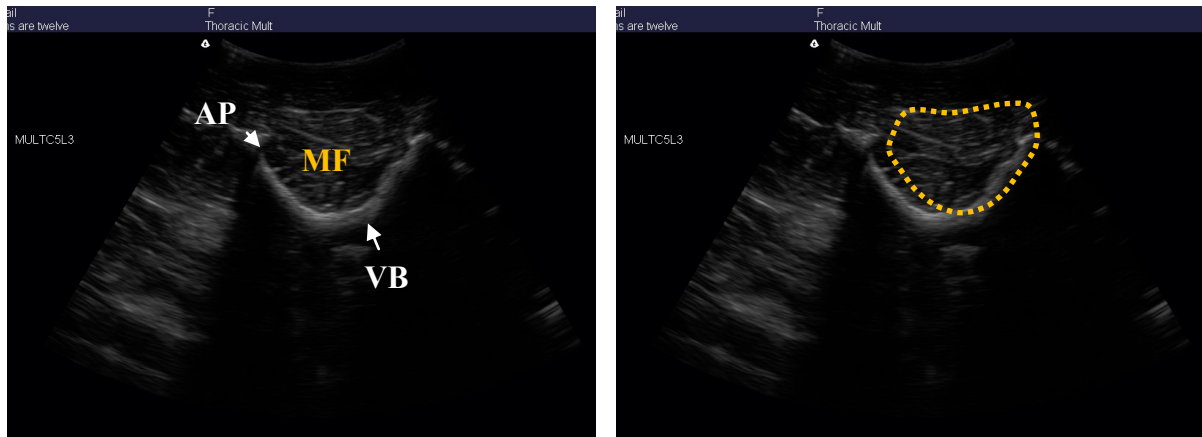


Figure A3: Ultrasound (US) images of *m. multifidus cervicis* at C5

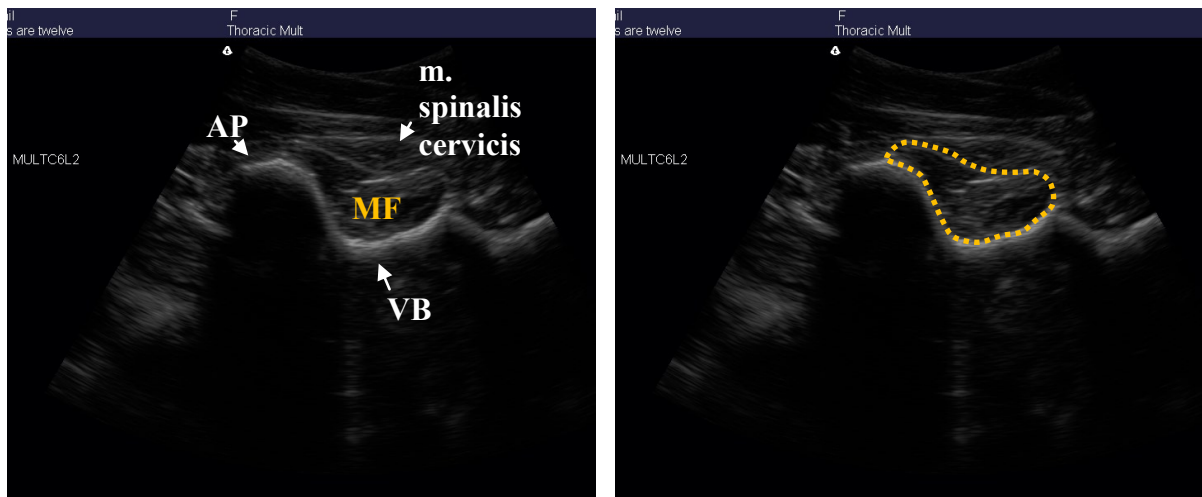


Figure A4: Ultrasound (US) images of *m. multifidus cervicis* at C6

T2 (Fig. A5, Fig. A7) and PD (Fig. A8) magnetic resonance images in transverse plane of *m. multifidus cervicis* at C3 (Fig. A5), C4 (Fig. A6), C5 (Fig. A7) and C6 (Fig. A8), demonstrating the cross-sectional shape of the muscle at the different vertebral levels and in relation to the vertebral body (image on the left side), and the outline of the fascial muscle borders (dashed line) (image on the right side). Some images are inverted due to subjects being imaged in dorsal recumbency.

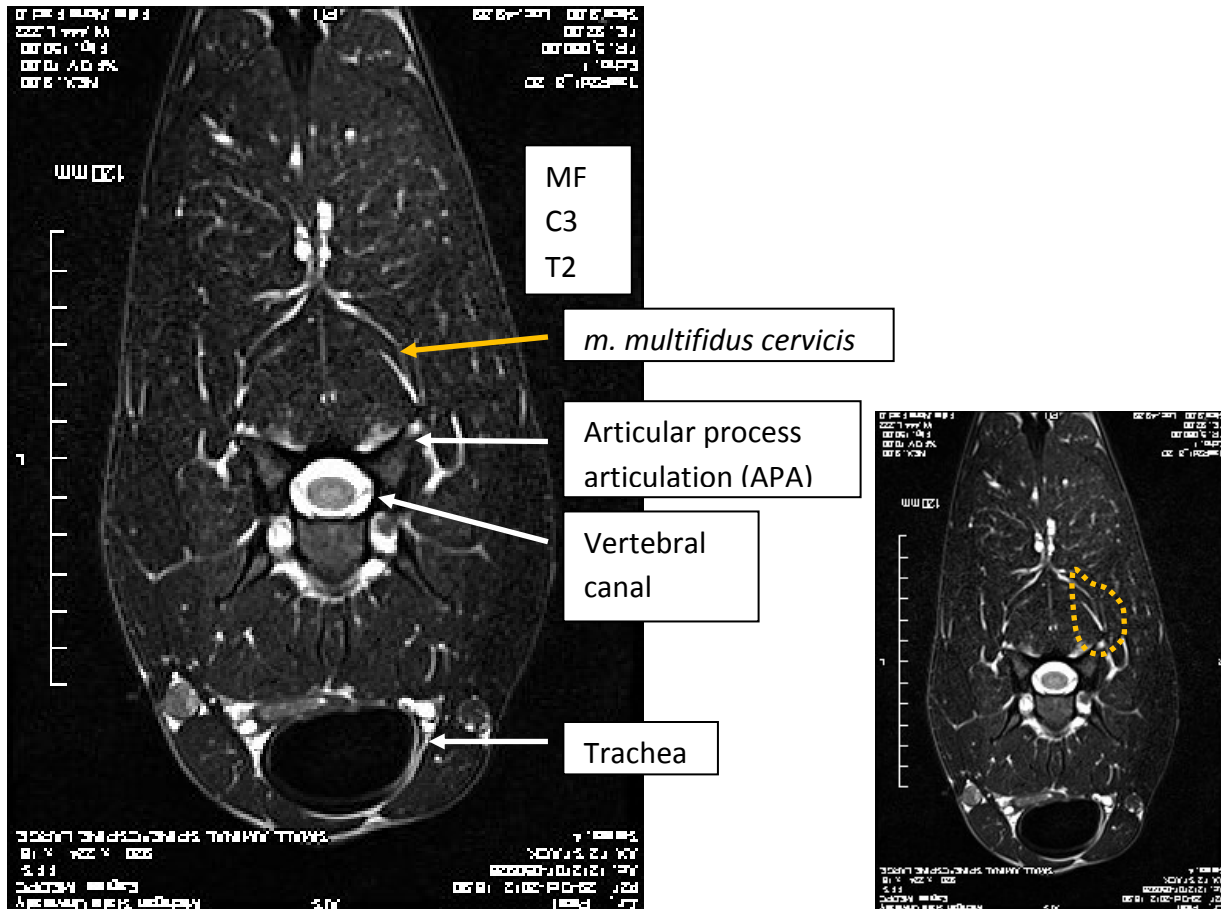


Figure A5: Magnetic resonance (MR) images of *m. multifidus cervicis* at C3

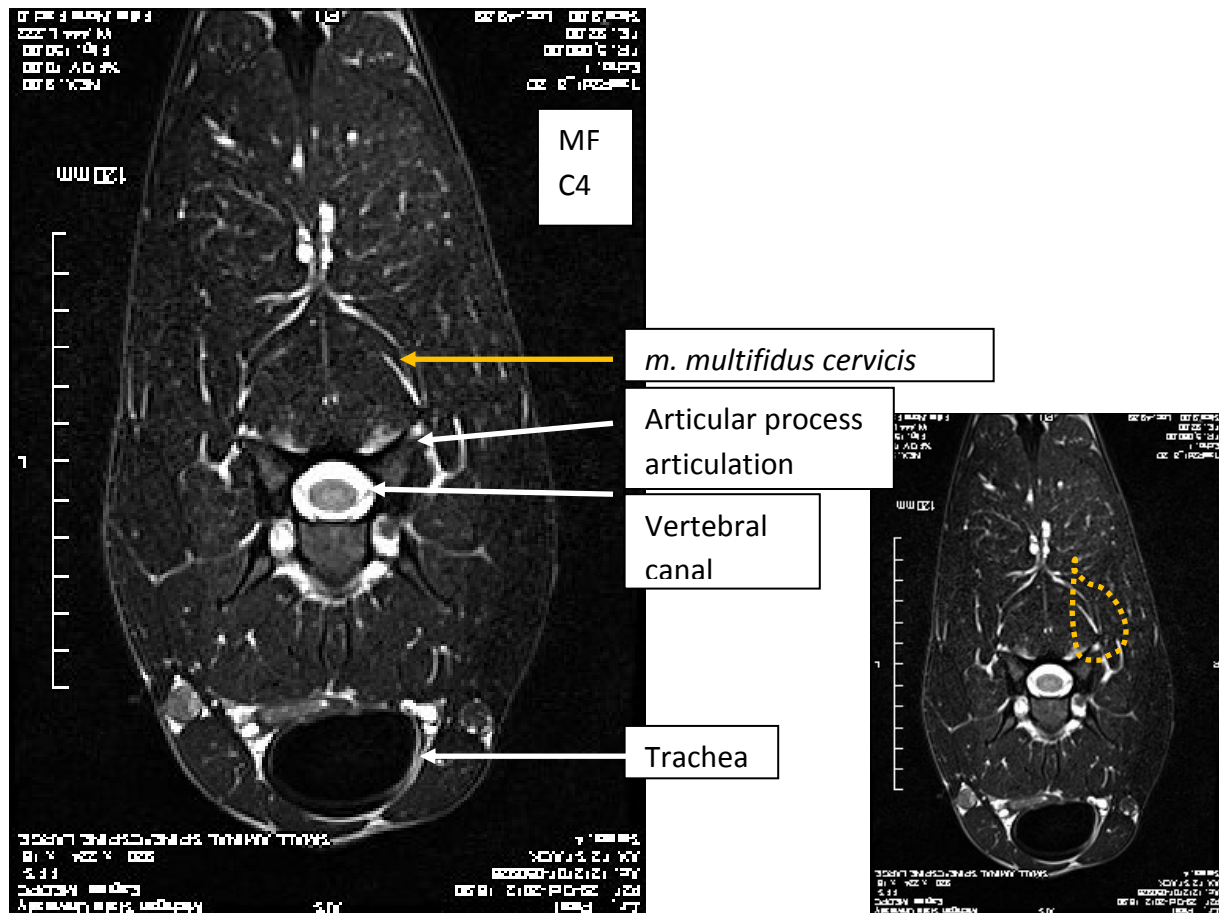


Figure A6: Magnetic resonance (MR) images of *m. multifidus cervicis* at C4

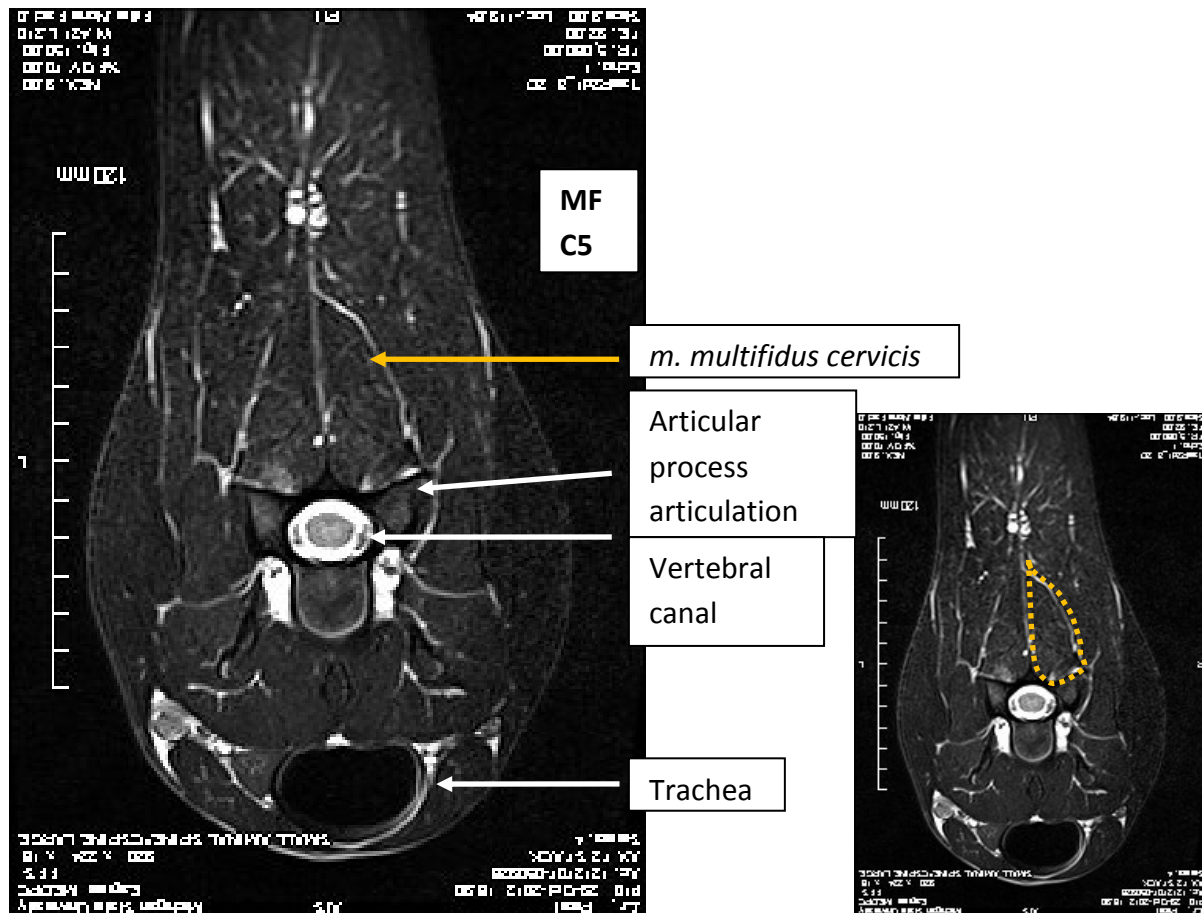


Figure A7: Magnetic resonance (MR) images of *m. multifidus cervicis* at C5

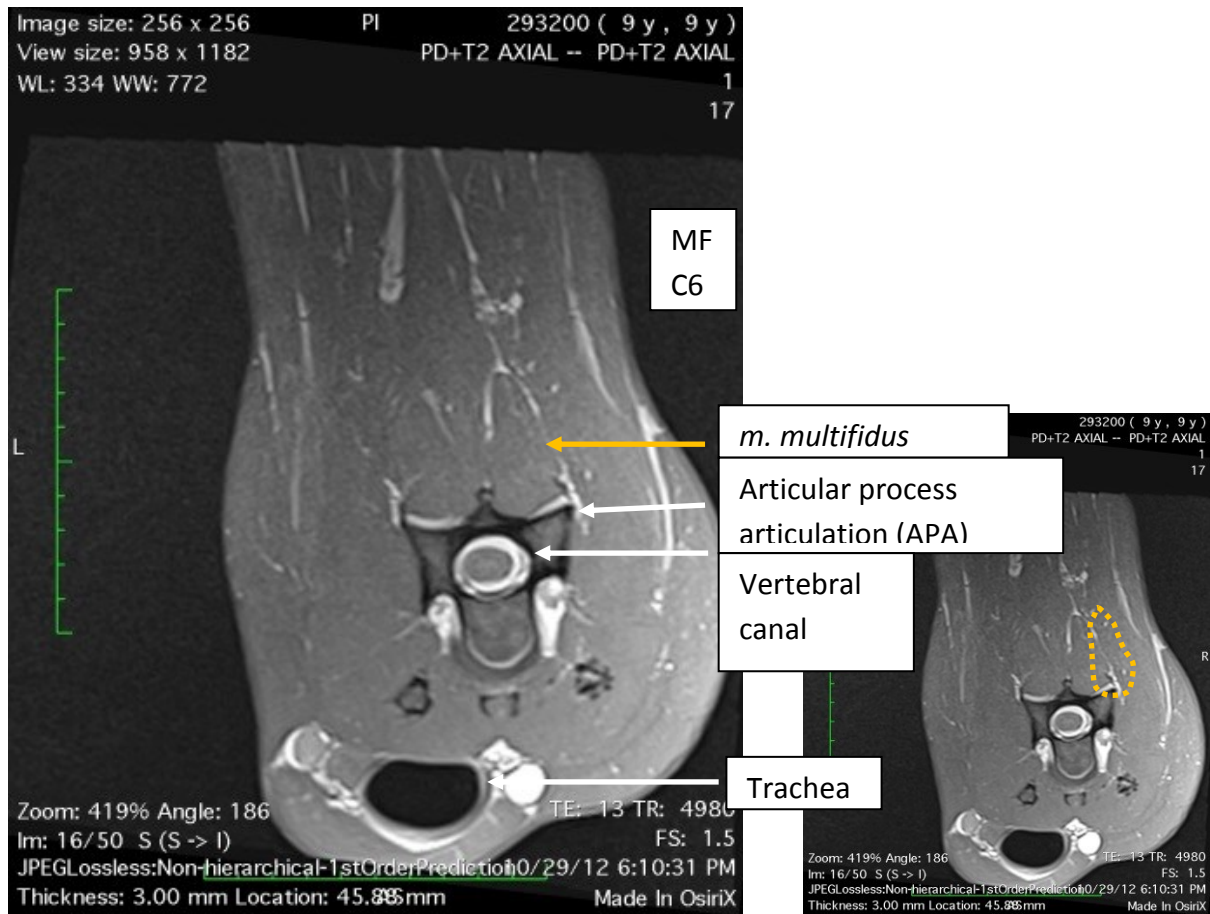


Figure A8: Magnetic resonance (MR) images of *m. multifidus cervicis* at C6

APPENDIX B: Ultrasound and magnetic resonance images of *m. longus colli*

Ultrasound images of left hand side of *m. longus colli* (LC) at C2 (Fig. B1), C3 (Fig. B2), C4 (Fig. B3) and C5 (Fig. B4), demonstrating the anatomical landmarks for US image acquisition (left hand side): JV (jugular vein) and VB (vertebral body), and the cross-sectional shape of the muscle (right hand side). The ventral aspect of the vertebral body is shown at the top of the image, the dot at the top of the image points to the left side of the horse.

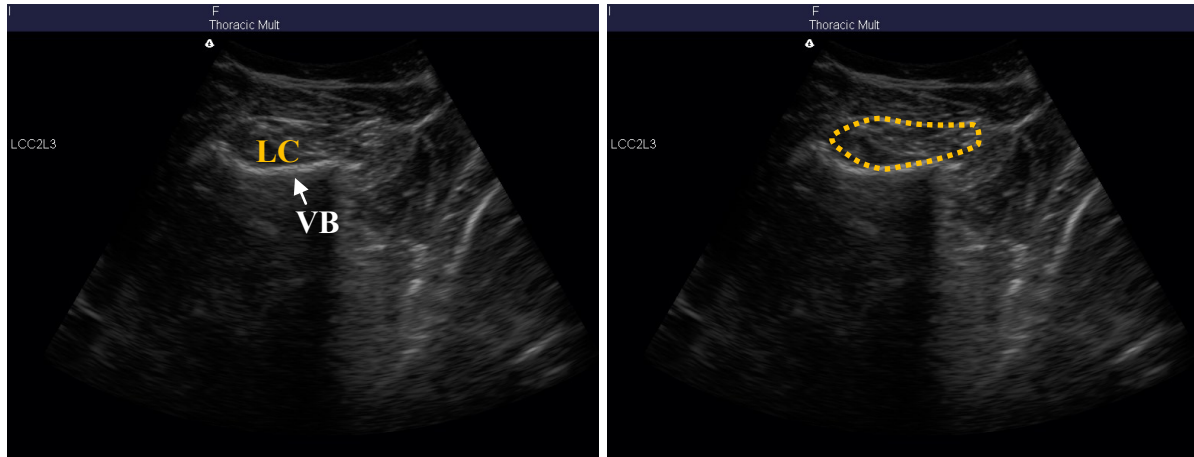


Figure B1: Ultrasound (US) images of *m. longus colli* at C2

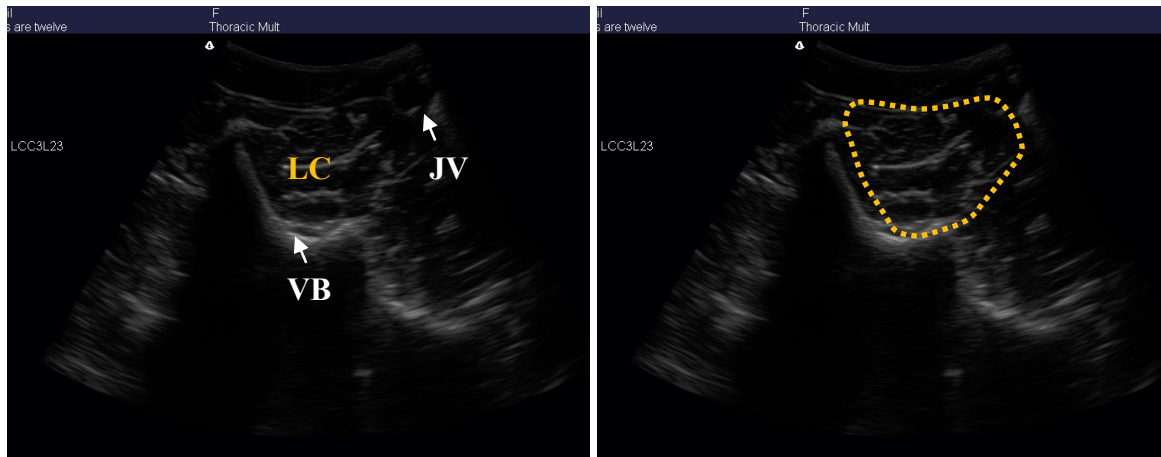


Figure B2: Ultrasound (US) images of *m. longus colli* at C3

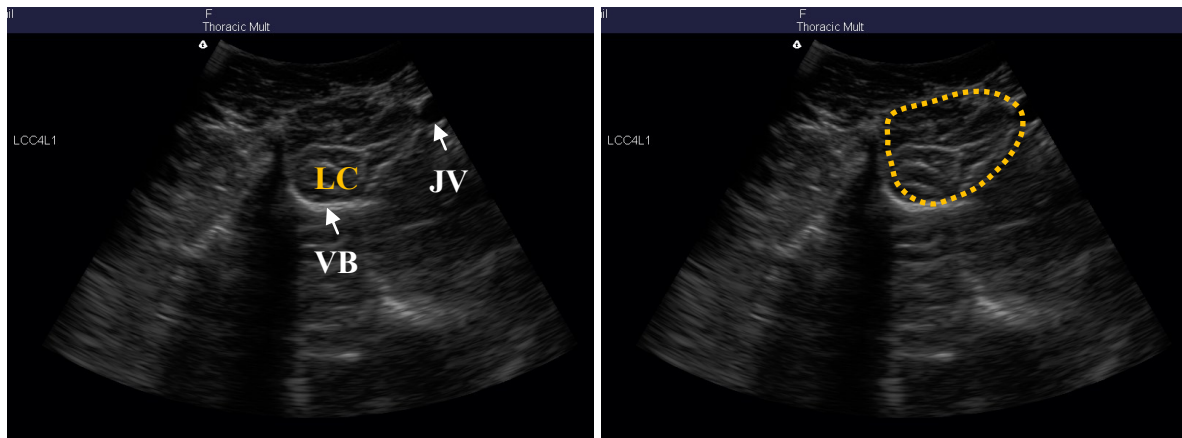


Figure B3: Ultrasound (US) images of *m. longus colli* at C4

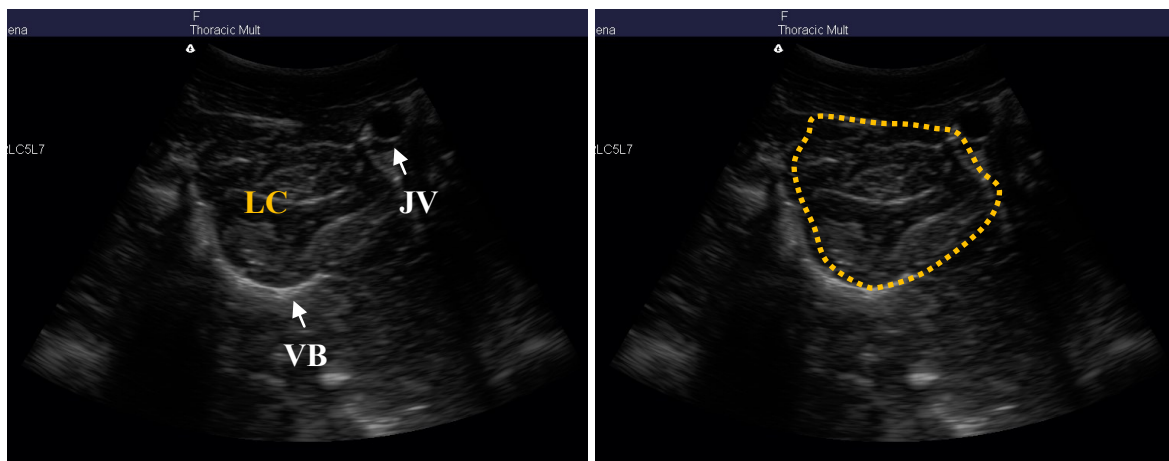


Figure B4: Ultrasound (US) images of *m. longus colli* at C5

PD (Fig. B5, Fig. B7) and T2 (Fig. B6, Fig. B8) magnetic resonance image in the transverse plane of *m. longus colli* at C2 (Fig. B5), C3 (Fig. B6), C4 (Fig. B7) and C5 (Fig. B8), demonstrating the cross-sectional shape of the muscle at the different vertebral levels and in relation to the vertebral body (image on the left side) and the outline of the fascial muscle borders (dashed line) (image on the right side). Some images are inverted due to subjects being imaged in dorsal recumbency.

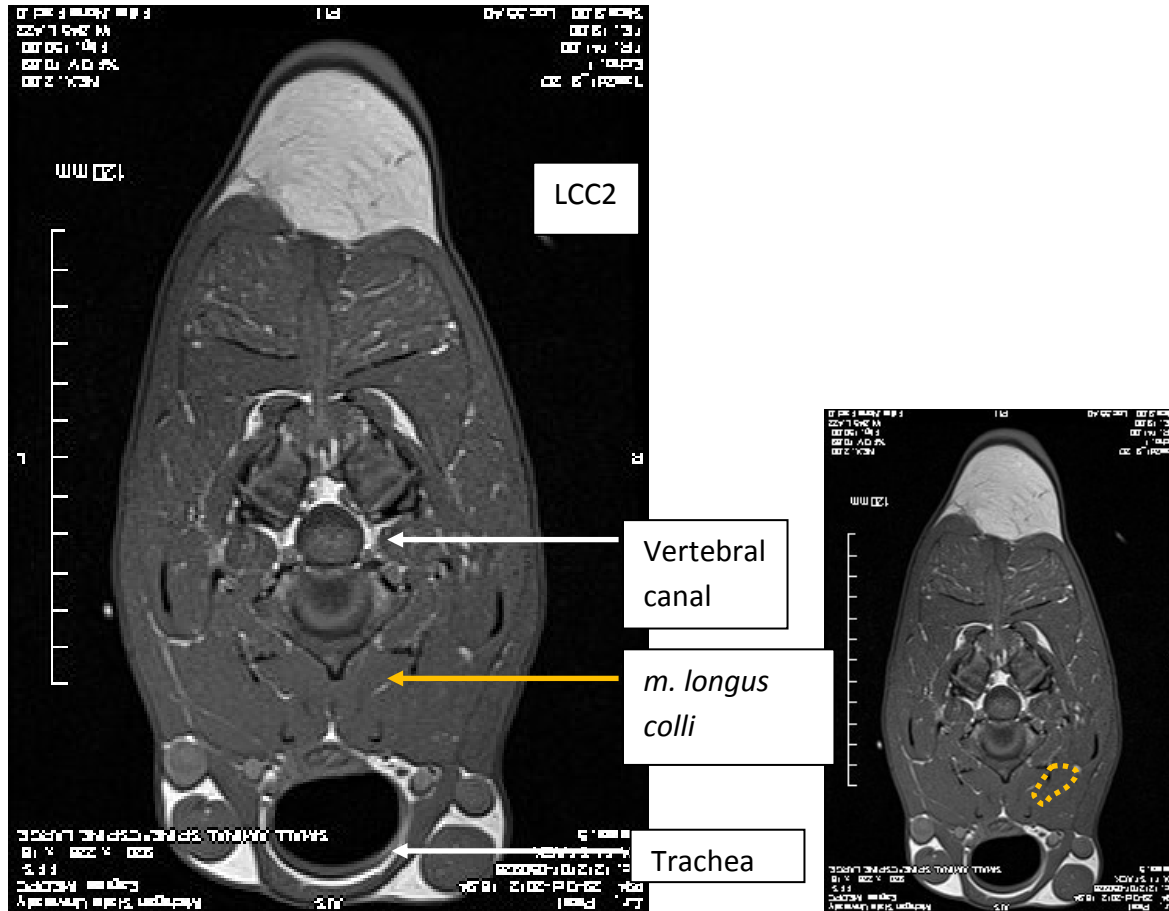


Figure B5: Magnetic resonance (MR) images of *m. longus colli* at C2

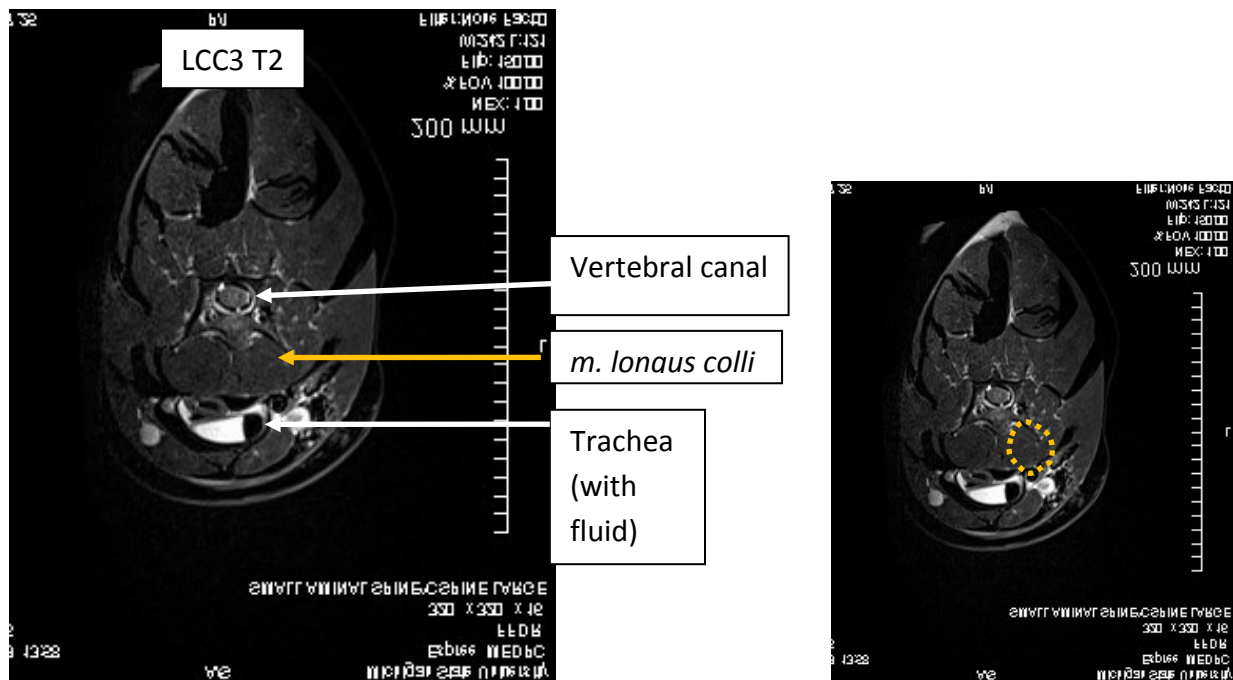


Figure B6: Magnetic resonance (MR) images of *m. longus colli* at C3

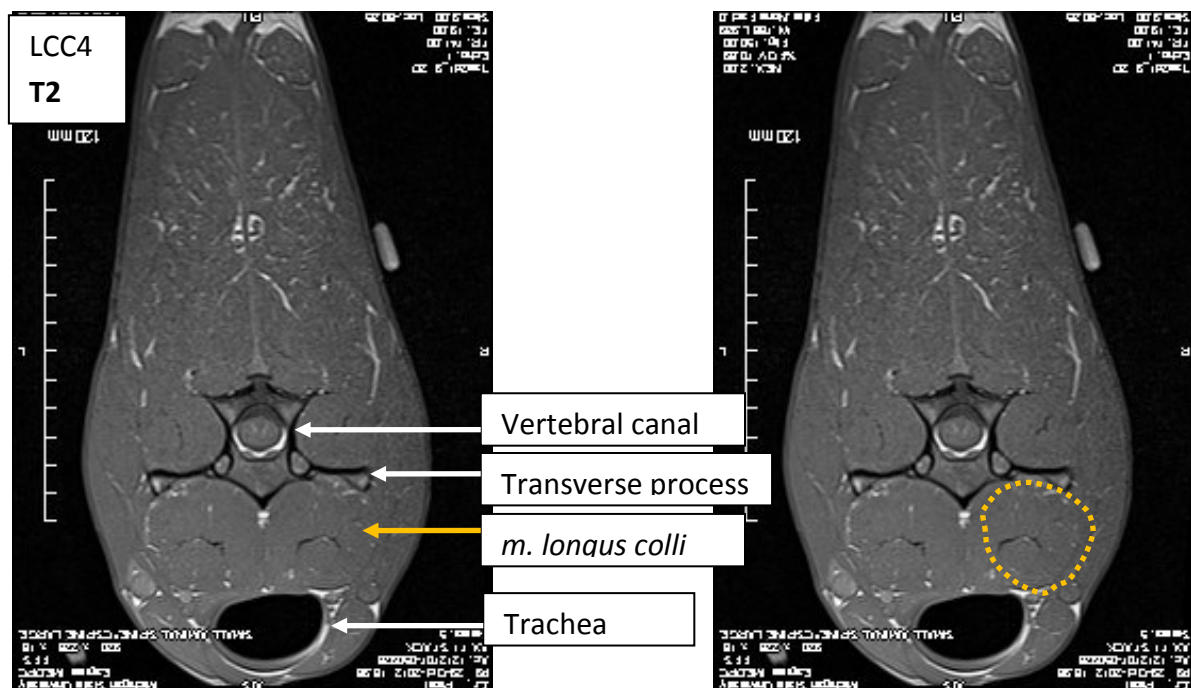


Figure B7: Magnetic resonance (MR) images of *m. longus colli* at C4

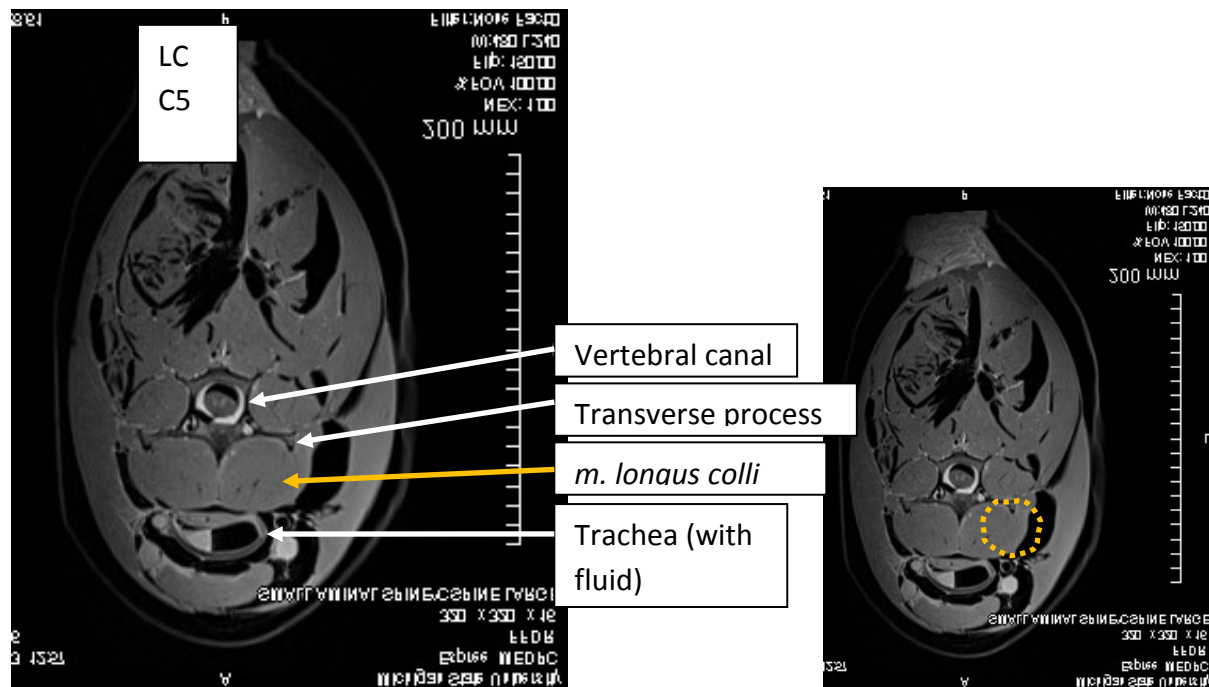


Figure B8: Magnetic resonance (MR) images of *m. longus colli* at C5

APPENDIX C: Results for variability and repeatability of MR and US image acquisition and image evaluation across all horses for each spinal level for *m. multifidus cervicis* and *m. longus colli* (Study 1)

	horse (df=4)		
	EV	95% CI	ICC
C3	2.79	(1.00-23.04)	0%
C4	5.71	(2.05-47.15)	1%
C5	1.54	(0.55-12.72)	3%
C6	1.59	(0.57-13.13)	2%
trial (df=10)			
	EV	95% CI	ICC
C3	0	(0.00-0.00)	100%
C4	0.05	(0.02-0.15)	99%
C5	0.04	(0.02-0.12)	97%
C6	0.03	(0.01-0.09)	98%
repetition (df=30)			
	EV	95% CI	ICC
C3	0	(0.00-0.00)	100%
C4	0	(0.00-0.00)	100%
C5	0	(0.00-0.00)	100%
C6	0	(0.00-0.00)	100%

df: degrees of freedom; EV: estimated variance; 95% CI (lower 95% CI - higher 95% CI); ICC: intraclass correlation coefficient (%)

Table C1: Variability across all horses for magnetic resonance (MR) CSA measurements of *m. multifidus cervicis* for spinal levels (C3, C4, C5, C6), image acquisition (trial) and image evaluation (repetition).

	horse (df=4)		
	ESD	95% CI	CV
C3	1.67	(0.61-2.94)	37%
C4	2.39	(1.02-4.91)	39%
C5	1.24	(0.27-1.32)	19%
C6	1.26	(0.00-0.00)	23%
trial (df=10)			
	ESD	95% CI	CV
C3	0.00	(0.50-1.26)	0%
C4	0.22	(0.49-1.24)	4%
C5	0.20	(1.16-2.92)	3%
C6	0.17	(0.50-1.24)	3%
repetition (df=30)			
	ESD	95% CI	CV
C3	0.00	(0.05-0.09)	0%
C4	0.00	(0.06-0.09)	0%
C5	0.00	(0.06-0.10)	0%
C6	0.00	(0.05-0.08)	0%

df: degrees of freedom; ESD: estimated standard deviation; 95% CI: (lower 95% CI-higher 95%CI); CV: coefficient of variation (%)

Table C2: Repeatability across all horses for magnetic resonance (MR) CSA measurements of *m. multifidus cervicis* for spinal levels (C3, C4, C5, C6); image acquisition (trial) and image evaluation (repetition).

	horse (df=4)		
	EV	95% CI	ICC
C3	1.05	(0.38-8.63)	33%
C4	2.92	(1.05-25.10)	15%
C5	0.21	(0.08-1.73)	93%
C6	0.00	(0.00-0.00)	100%
trial (df=10)			
	EV	95% CI	ICC
C3	0.52	(0.25-1.59)	67%
C4	0.50	(0.24-1.53)	85%
C5	2.77	(1.35-8.55)	31%
C6	0.50	(0.25-1.55)	2%
repetition (df=30)			
	EV	95% CI	ICC
C3	0.004	(0.00-0.01)	100%
C4	0.005	(0.00-0.01)	100%
C5	0.01	(0.00-0.01)	100%
C6	0.00	(0.00-0.01)	100%

df: degrees of freedom; EV: estimated variance; 95% CI (lower 95% CI - higher 95% CI); ICC: intraclass correlation coefficient (%)

Table C3: Variability across all horses for ultrasound (US) CSA measurements of *m. multifidus cervicis* for spinal levels (C3, C4, C5, C6), image acquisition (trial) and image evaluation (repetition).

	horse (df=4)		
	ESD	95% CI	CV
C3	0.92	(0.61-2.94)	21%
C4	1.00	(1.02-4.91)	29%
C5	0.00	(0.27-1.32)	8%
C6	0.00	(0.00-0.00)	0%
	trial (df=10)		
	ESD	95% CI	CV
C3	0.72	(0.50-1.26)	15%
C4	0.70	(0.49-1.24)	12%
C5	1.67	(1.16-2.92)	28%
C6	0.71	(0.50-1.24)	18%
	repetition (df=30)		
	ESD	95% CI	CV
C3	0.07	(0.05-0.09)	0%
C4	0.07	(0.06-0.09)	0%
C5	0.07	(0.06-0.10)	0%
C6	0.06	(0.05-0.08)	0%

df: degrees of freedom; ESD: estimated standard deviation; 95% CI: (lower 95% CI-higher 95%CI); CV: coefficient of variation (%)

Table C4: Repeatability across all horses for ultrasound (US) CSA measurements of *m. multifidus cervicis* for spinal levels (C3, C4, C5, C6), image acquisition (trial) and image evaluation (repetition).

	horse (df=4)		
	EV	95% CI	ICC
C2	0.78	(0.28-6.44)	20%
C3	4.73	(1.70-39.06)	1%
C4	2.86	(1.03-23.62)	2%
C5	2.91	(1.04-24.03)	3%
trial (df=10)			
	EV	95% CI	ICC
C2	0.00	(0.00-0.00)	100%
C3	0.01	(0.01-0.02)	100%
C4	0.01	(0.01-0.02)	100%
C5	0.00	(0.00-0.00)	100%
repetition (df=30)			
	EV	95% CI	ICC
C2	0.97	(0.09-0.59)	80%
C3	4.76	(0.01-0.06)	100%
C4	2.92	(0.02-0.15)	98%
C5	3.01	(0.05-0.31)	97%

df: degrees of freedom; EV: estimated variance; 95% CI (lower 95% CI - higher 95% CI); ICC: intraclass correlation coefficient (%)

Table C5: Variability across all horses for magnetic resonance (MR) CSA measurements of *m. longus colli* for spinal levels (C2, C3, C4, C5), image acquisition (trial) and image evaluation (repetition).

	horse (df=4)		
	ESD	95% CI	CV
C2	0.88	(0.53-2.54)	15%
C3	2.17	(1.30-6.25)	20%
C4	1.69	(1.01-4.86)	12%
C5	1.71	(1.02-4.90)	14%
	trial (df=10)		
	ESD	95% CI	CV
C2	0.00	(0.00-0.00)	0%
C3	0.10	(0.08-0.13)	1%
C4	0.10	(0.08-0.13)	1%
C5	0.00	(0.00-0.00)	0%
	repetition (df=30)		
	ESD	95% CI	CV
C2	0.44	(0.30-0.76)	7%
C3	0.14	(0.10-0.25)	1%
C4	0.22	(0.16-0.39)	2%
C5	0.32	(0.22-0.55)	3%

df: degrees of freedom; ESD: estimated standard deviation; 95% CI: (lower 95% CI-higher 95%CI); CV: coefficient of variation (%)

Table C6: Repeatability across all horses for magnetic resonance (MR) CSA measurements of *m. longus colli* for spinal levels (C2, C3, C4, C5), image acquisition (trial) and image evaluation (repetition).

	horse (df=4)		
	EV	95% CI	ICC
C2	0.01	(0.00-0.06)	92%
C3	1.24	(0.44-10.22)	24%
C4	2.88	(1.04-23.82)	10%
C5	7.18	(2.58-59.30)	3%
trial (df=10)			
	EV	95% CI	ICC
C2	0.11	(0.05-0.33)	9%
C3	0.38	(0.18-1.16)	77%
C4	0.30	(0.14-0.91)	91%
C5	0.24	(0.12-0.73)	97%
repetition (df=30)			
	EV	95% CI	ICC
C2	0.00	(0.00-0.01)	100%
C3	0.01	(0.00-0.01)	100%
C4	0.01	(0.01-0.02)	100%
C5	0.02	(0.01-0.04)	100%

df: degrees of freedom; EV: estimated variance; 95% CI (lower 95% CI - higher 95% CI); ICC: intraclass correlation coefficient (%)

Table C7: Variability across all horses for ultrasound (US) CSA measurements of *m. longus colli* for spinal levels (C2, C3, C4, C5), image acquisition (trial) and image evaluation (repetition).

	horse (df=4)		
	ESD	95% CI	CV
C2	0.09	(0.05-0.25)	3%
C3	1.11	(0.67-3.20)	17%
C4	1.70	(1.02-4.88)	19%
C5	2.68	(1.61-7.70)	22%
trial (df=10)			
	ESD	95% CI	CV
C2	0.33	(0.23-0.57)	11%
C3	0.61	(0.43-1.08)	10%
C4	0.54	(0.38-0.96)	6%
C5	0.49	(0.34-0.85)	6%
repetition (df=30)			
	ESD	95% CI	CV
C2	0.07	(0.05-0.09)	0%
C3	0.08	(0.06-0.10)	1%
C4	0.11	(0.09-0.14)	1%
C5	0.15	(0.12-0.20)	2%

df: degrees of freedom; ESD: estimated standard deviation; 95% CI: (lower 95% CI-higher 95%CI); CV: coefficient of variation (%)

Table C8: Repeatability across all horses for ultrasound (US) measurements of *m. longus colli* for spinal levels (C2, C3, C4, C5), image acquisition (trial) and image evaluation (repetition).

APPENDIX D: Results for variability and repeatability of US image acquisition and image digitization across all horses for each spinal level, within US operators and between US operators for *m. multifidus cervicis* and *m. longus colli* (Study 2)

	horse (df=4)		
	EV	95% CI	ICC
C3	4.10	(1.47-33.88)	1%
C4	2.66	(0.95-21.96)	37%
C5	0.00	(0.00-0.00)	100%
C6	1.17	(0.42-9.58)	40%
operator (df=1)			
	EV	95% CI	ICC
C3	0.00	(0.00-0.00)	100%
C4	1.02	(0.20-1036.08)	76%
C5	0.24	(0.05-242.55)	21%
C6	0.20	(0.04-199.48)	91%
trial (df=20)			
	EV	95% CI	ICC
C3	0.02	(0.01-0.03)	100%
C4	0.00	(0.00-0.00)	100%
C5	0.05	(0.03-0.11)	83%
C6	0.00	(0.00-0.00)	100%
observer (df=1)			
	EV	95% CI	ICC
C3	0.00	(0.00-0.00)	100%
C4	0.06	(0.01-64.21)	99%
C5	0.00	(0.00-0.00)	100%
C6	0.89	(0.18-910.73)	61%
repetition (df=120)			
	EV	95% CI	ICC
C3	0.01	(0.01-0.01)	100%
C4	0.47	(0.37-0.62)	89%
C5	0.02	(0.01-0.01)	97%
C6	0.02	(0.01-0.02)	99%

df: degrees of freedom; EV: estimated variance; 95% CI (lower 95% CI - higher 95% CI); ICC: intraclass correlation coefficient (%)

Table D1: Variability across all horses for ultrasound (US) CSA measurements of *m. multifidus cervicis* for spinal levels (C3, C4, C5, C6), within operators (operator), image acquisition (trial), between operators (observer) and image evaluation (repetition).

horse (df=4)			
	ESD	95% CI	CV
C3	2.03	(1.21-5.82)	25%
C4	1.63	(0.98-4.69)	15%
C5	0.00	(0.00-0.00)	0%
C6	1.08	(0.65-3.10)	14%
operator (df=1)			
	ESD	95% CI	CV
C3	0.00	(0.00-0.00)	0%
C4	1.01	(0.45-32.19)	10%
C5	0.49	(0.22-15.57)	4%
C6	0.44	(0.20-14.12)	6%
trial (df=20)			
	ESD	95% CI	CV
C3	0.12	(0.10-0.18)	2%
C4	0.00	(0.00-0.00)	0%
C5	0.23	(0.17-0.33)	2%
C6	0.00	(0.00-0.00)	0%
observer (df=1)			
	ESD	95% CI	CV
C3	0.00	(0.00-0.00)	0%
C4	0.25	(0.11-8.01)	2%
C5	0.00	(0.00-0.00)	0%
C6	0.95	(0.42-30.18)	12%
repetition (df=120)			
	ESD	95% CI	CV
C3	0.09	(0.08-0.10)	1%
C4	0.69	(0.61-0.79)	6%
C5	0.10	(0.09-0.11)	1%
C6	0.12	(0.11-0.14)	2%

df: degrees of freedom; ESD: estimated standard deviation; 95% CI: (lower 95% CI-higher 95%CI); CV: coefficient of variation (%)

Table D2: Repeatability across all horses for ultrasound (US) CSA measurements of *m. multifidus cervicis* for spinal levels (C3, C4, C5, C6), within operators (operator), image acquisition (trial); between operators (observer) and image evaluation (repetition).

horse (df=4)			
	EV	95% CI	ICC
C2	2.59	(0.93-21.36)	33%
C3	6.52	(2.34-53.86)	1%
C4	4.33	(1.56_35.77)	35%
C5	13.11	(4.71-108.28)	26%
operator (df=1)			
	EV	95% CI	ICC
C2	0.00	(0.00-0.00)	100%
C3	0.00	(0.00-0.00)	100%
C4	0.09	(0.02-90.76)	99%
C5	0.00	(0.00-0.00)	100%
trial (df=20)			
	EV	95% CI	ICC
C2	0.04	(0.03-0.09)	99%
C3	0.05	(0.03-0.10)	99%
C4	0.00	(0.00-0.00)	100%
C5	0.03	(0.02-0.07)	100%
observer (df=1)			
	EV	95% CI	ICC
C2	1.23	(0.24-1247.37)	68%
C3	0.00	(0.00-0.00)	100%
C4	2.26	(0.45-2304.83)	66%
C5	4.53	(0.90-4610.06)	74%
repetition (df=120)			
	EV	95% CI	ICC
C2	0.01	(0.01-0.02)	100%
C3	0.03	(0.02-0.03)	100%
C4	0.02	(0.02-0.03)	100%
C5	0.02	(0.02-0.03)	100%

df: degrees of freedom; EV: estimated variance; 95% CI (lower 95% CI - higher 95% CI); ICC: intraclass correlation coefficient (%)

Table D3: Variability across all horses for ultrasound (US) CSA measurements of *m. longus colli* for spinal levels (C2, C3, C4, C5), within operators (operator), image acquisition (trial), between operators (observer) and repeated image evaluation (repetition).

	horse (df=4)		
	ESD	95% CI	CV
C2	1.61	(0.96-4.62)	19%
C3	2.55	(1.53-7.34)	19%
C4	2.08	(1.25-5.98)	12%
C5	3.62	(2.17-10.41)	18%
operator (df=1)			
	ESD	95% CI	CV
C2	0.00	(0.00-0.00)	0%
C3	0.00	(0.00-0.00)	0%
C4	0.30	90.13-9.53)	2%
C5	0.00	(0.00-0.00)	0%
trial (df=20)			
	ESD	95% CI	CV
C2	0.21	(0.16-0.30)	2%
C3	0.21	(0.16-0.31)	2%
C4	0.00	(0.00-0.00)	0%
C5	0.18	(0.14-0.26)	1%
observer (df=1)			
	ESD	95% CI	CV
C2	1.11	0.49-34.32)	13%
C3	0.00	(0.00-0.00)	0%
C4	1.50	(0.67-48.01)	9%
C5	2.13	(0.95-67.90)	10%
repetition (df=120)			
	ESD	95% CI	CV
C2	0.11	(0.10-0.12)	1%
C3	0.16	(0.14-0.18)	1%
C4	0.15	(0.14-0.18)	1%
C5	0.14	(0.13-0.16)	1%

df: degrees of freedom; ESD: estimated standard deviation; 95% CI: (lower 95% CI-higher 95%CI); CV: coefficient of variation (%)

Table D4: Repeatability across all horses for ultrasound (US) CSA measurements of *m. longus colli* for spinal levels (C2, C3, C4, C5), within operators (operator), image acquisition (trial); between operators (observer) and image evaluation (repetition).

BIBLIOGRAPHY

BIBLIOGRAPHY

- Anderson, J. S., Hsu, A. W., Vasavada, A. (2005) Morphology, architecture and biomechanics of human cervical multifidus. *Spine*, 30(4), 86-91.
- Armstrong, B., McNair, P., Taylor, D. (2008) Head and neck position sense. *Sports Medicine*, 38(2), 101-117.
- Berg, L. C., Nielsen, J. V., Thoenner, M. B., *et al.* (2003) Ultrasonography of the equine cervical region: a descriptive study in eight horses. *Equine Veterinary Journal*, 35, 647-655.
- Birmingham, S. S. W., Reed, S. M., Mattoon, J. S. *et al.* (2010) Qualitative assessment of corticosteroid cervical articular facet injection in symptomatic horses. *Equine Veterinary Education*, 22(2), 77-82.
- Boyd-Clark, L. C., Briggs, C. A., Galea, M. P. (2001) Comparative histochemical composition of muscle fibers in a pre-and postvertebral muscle of the cervical spine. *Journal of Anatomy*, 199, 709-716.
- Boyd-Clark, L. C., Briggs, C. A., Galea, M. P. (2002) Muscle spindle distribution, morphology and density in longus colli and multifidus muscles of the cervical spine. *Spine*, 27(7), 694-701.
- Bronfort, G., Evans, R., Nelson, B., *et al.* (2001) A randomized clinical trial of exercise and spinal manipulation for patients with chronic neck pain. *Spine*, 26(7), 788-797.
- Cagnie, B., O'Leary, S., Elliott, J., *et al.* (2011) Pain-induced changes in the activity of the cervical extensor muscles evaluated by muscle functional magnetic resonance imaging. *The Clinical Journal of Pain*, 27(5), 392-397.
- Dyson, S. J. (2003) The cervical spine and soft tissues of the neck. In: *Diagnosis and management of lameness in the horse*, first edition. Eds: Ross, M. W. and Dyson, S. J., W.B. Saunders, St. Louis, 523-531.
- Elliott, J. Jull, G., Noteboom, J. T., *et al.* (2006) Fatty infiltration in the cervical extensor muscles in persistent whiplash-associated disorders: a magnetic resonance imaging analysis. *Spine*, 31, E847-844.
- Elliott, J., Jull, G., Noteboom, J. T., *et al.* (2008) MR study of the cross-sectional area for the cervical extensor musculature in patients with persistent whiplash-associated disorders (WAD). *Manual Therapy*, 13, 258-265.
- Elliott, J. M., O'Leary, S. P., Cagnie, B., *et al.* (2010) Craniocervical orientation affects muscle activation when exercising the cervical extensors in healthy subjects. *Archives of Physical Medicine and Rehabilitation*, 91, 1418-1422.

- Falla, D. (2004) Unravelling the complexity of muscle impairment in chronic neck pain. *Manual Therapy*, 9, 125-133.
- Falla, D., Jull, G., Hodges, P. (2006) An endurance-strength training regime is effective in reducing myoelectric manifestations of cervical flexor muscle fatigue in females with chronic neck pain. *Clinical Neurophysiology*, 117, 828-837.
- Falla, D., Farina, D. (2007) Neural and muscular factors associated with motor impairment in neck pain. *Current Rheumatology Reports*, 9(6), 497-502.
- Falla, D., Jull, G., Russell, T., *et al.* (2007) Effect of neck exercise on sitting posture in patients with chronic neck pain. *Physical Therapy*, 87(4), 408-417.
- Falla, D., Farina, D. (2008) Neuromuscular adaptation in experimental and clinical neck pain. *Journal of Electromyography and Kinesiology*, 18, 255-261.
- Fernández-de-las-Peñas, C., Albert-Sanchís, J. C., Buil, M., *et al.* (2008) Cross-sectional area of cervical multifidus muscle in females with chronic bilateral neck pain compared to controls. *Journal of Orthopaedic and Sports Physical Therapy*, 38, 175-180.
- Javanshir, K., Mohseni-Bandpei, M. A., Rezasoltani, A., *et al.* (2009) Ultrasonography of longus colli muscle: a reliability study on healthy subjects and patients with chronic neck pain. *Journal of Bodywork and Movement Therapies*, 15, 50-56.
- Javanshir, K., Amiri, M., Mohseni-Bandpei, M., *et al.* (2010) Ultrasonography of the cervical muscles: a critical review of the literature. *Journal of Manipulative and Physiological Therapeutics*, 33(8), 630-637.
- Javanshir, K., Mohseni-Bandpei, M. A., Rezasoltani, A., *et al.* (2011) Ultrasonography of longus colli muscle: A reliability study on healthy patients and patients with chronic neck pain. *Journal of Bodywork and Movement Therapies*, 15(1), 50-56.
- Jesus, F. M. R., Ferreira, P. H., Ferreira, M. L. (2008) Ultrasonographic measurement of neck muscle recruitment: a preliminary investigation. *Journal of Manual and Manipulative Therapy*, 16(2), 89-92.
- Jull, G. A., Richardson, C. A. (2000) Motor control problems with spinal pain: a new direction for therapeutic exercise. *Journal of Manipulative and Physiological Therapeutics*, 23(2), 115-117.
- Jull, G., Trott, P., Potter, H., *et al.* (2002) A randomized controlled trial of exercise and manipulative therapy for cervicogenic headache. *Spine*, 27(17), 1835-1843.
- Jull, G., Kristjansson, E., Dall'Alba, P. (2004) Impairment in the cervical flexors: a comparison of whiplash and insidious onset neck pain patients. *Manual Therapy*, 9, 89-94.

- Jull, G. A., O’Leary, S. P., Falla, D. L. (2008) Clinical assessment of the deep cervical flexor muscles: the craniocervical flexion test. *Journal of Manipulative and Physiological Therapeutics*. 31(7), 525-533.
- Jull, G. A., Falla, D., Vicenzino, B., *et al.* (2009) The effect of therapeutic exercise on activation of the deep cervical flexor muscles in people with chronic neck pain. *Manual Therapy*, 14(6), 696-701.
- Kamibayashi, L. K., Richmond, F. J. R. (1998) Morphometry of human neck muscles. *Spine*, 23(12), 1314-1323.
- Kristjansson, E. (2004) Reliability of ultrasonography for the cervical multifidus muscle in asymptomatic and symptomatic subjects. *Manual Therapy*, 9, 83-88.
- Lee, J. P., Tseng, W. Y., Shau, Y. W., *et al.* (2007) Measurement of segmental cervical multifidus contraction by ultrasonography in asymptomatic adults. *Manual Therapy*, 12, 286-294.
- Lee, J.P., Tseng, W.Y. I., Shau, Y.W., *et al.* (2009) Measurement of cervical multifidus contraction pattern with ultrasound imaging. *Journal of Electromyography and Kinesiology*, 19(3), 319-397.
- Levine, J. M., Adam, E., Mackay J. *et al.* (2007) Confirmed and presumptive cervical vertebral compressive myelopathy in older horses: a retrospective study (1994-2004). *Journal of Veterinary Internal Medicine*, 21, 812-819.
- Lin, Y. J., Chai, H. M., Wang, S. F. (2009) Reliability of thickness measurements of the dorsal muscles of the upper cervical spine: an ultrasonographic study. *Journal of Orthopaedic Sports and Physical Therapy*. 39, 850-857.
- Lindström, R., Schomacher, J., Farina, D., *et al.* (2011) Association between neck muscle coactivation, pain and strength in women with neck pain. *Manual Therapy*, 16, 80-86.
- Mattoon, J. S., Drost, W. T., Grguric, M. R., *et al.* (2004) Technique for equine cervical articular process joint injection. *Veterinary Radiology and Ultrasound*, 45(3), 238-240.
- Mayoux-Benhamou, M. A., Revel, M. Vallée, C., *et al.* (1994) Longus colli has a postural function on cervical curvature. *Surgical and Radiological Anatomy*, 16(4), 367-371.
- Moore, B. R., Reed, S. M., Biller, D. S. *et al.* (1994) Assessment of vertebral canal diameter and bony malformations of the cervical part of the spine in horses with cervical stenotic myelopathy. *American Journal of Veterinary Research*, 55(1), 05-13.
- Moore, B. R., Reed, S. M., Biller, D. S. *et al.* (1994) Assessment of vertebral canal diameter and bony malformations of the cervical part of the spine in horses with cervical stenotic myelopathy. *American Journal of Veterinary Research*, 55(1), 05-13.

O'Leary, S., Elliott, J. M., Falla, D., *et al.* (2009) Muscle dysfunction in cervical spine pain: implications for assessment and management. *Journal of Orthopaedic and Sports Physical Therapy*, 39(5), 324-333.

O'Leary, S., Cagnie, B., Reeve, A., *et al.* (2011) Is there altered activity of the extensor muscles in chronic mechanical neck pain? A functional magnetic resonance imaging study. *Archives of Physical Medicine and Rehabilitation*, 92, 929-934.

Papageorges, M., Gavin, P. R., Sande, R. D. *et al.* (1987) Radiographic and myelographic examination of the cervical vertebral column in 306 ataxic horses. *Veterinary Radiology and Ultrasound*, 28(2), 53-59.

Paulus, I., Brumagne, S. (2008) Altered interpretation of neck proprioceptive signals in persons with subclinical recurrent neck pain. *Journal of Rehabilitation Medicine*, 40, 426-432.

Peolsson, A., Brodin, L.-Å., Peolsson, M., (2012) A tissue velocity ultrasound imaging investigation of the dorsal neck muscles during resisted isometric extension. *Manual Therapy*, 15(6), 567-573.

Petrie, A. and Watson, P. (2006) Statistics for veterinary and animal science, 2nd edn. Blackwell Publishing, London. pp 39-41.

Rankin, G., Stokes, M., Newham, D. J. (2005) Size and shape of the posterior neck muscles measured by ultrasound imaging: normal values in males and females of different ages. *Manual Therapy*, 10, 108-115.

Reeves, P. N., Narendra, K. S., Cholewicki, J. (2007) Spine stability: The six blind men and the elephant. *Clinical Biomechanics*, 22, 266-274.

Reeves, P. N., Narendra, K. S., Cholewicki, J. (2011) Spine stability: Lessons from balancing a stick. *Clinical Biomechanics*, 26, 326-330.

Siegmund, G. P., Blouin, J-S., Carpenter, M. G., *et al.* (2008) Are cervical multifidus muscles active during whiplash and startle? *BMC Musculoskeletal Disorders*, 9, 80.

Sjölander, P., Michaelson, P., Jaric, S., *et al.* (2008) Sensorimotor disturbances in chronic neck pain - range of motion, peak velocity, smoothness of movement, and repositioning acuity. *Manual Therapy*, 13, 122-131.

Stubbs, N. C., Riggs, C. M., Hodges, P. W., *et al.* (2010) Osseous spinal pathology and epaxial muscle ultrasonography in Thoroughbred racehorses. *Equine Veterinary Journal*, 42(Suppl. 38), 654-661.

Stubbs, NC (2011). *Epaxial Musculature and its Relationship with Back Pain in the Horse* PhD. Chapter 3: Measurement of equine epaxial muscles using ultrasonography. Thesis, School of Agriculture and Food Sciences, The University of Queensland.

Thomsen, L. N., Berg, L. C., Markussen, B., *et al.* (2012) Synovial folds in equine articular process joints. *Equine Veterinary Journal*. DOI: 10.1111/j.2042-3306.2012.00687.x

Uhlig, Y., Weber, B. R., Grob, D., Muntener, M. (1995) Fiber composition and fiber transformations in neck muscles of patients with dysfunction of the cervical spine. *Journal of Orthopaedic Research*, 13(2), 200-249.

Van Biervliet, J., Mayhew, J., de Lanhunta, A. (2006) Cervical vertebral compressive myelopathy: Diagnosis. *Clinical Techniques in Equine Practice*, 5, 54-59.

Wagner, P. C., Grant, B. D., Bagby, G. W., *et al.* (1979) Evaluation of cervical spinal fusion as a treatment in the equine 'wobbler' syndrome. *Veterinary Surgery*, 8, 84-88.

Withers, J. M., Voûte, L. C., Hammond, G., *et al.* (2009) Radiographic anatomy of the articular process joints of the caudal cervical vertebrae in the horse on lateral and oblique projections. *Equine Veterinary Journal*, 41, 9, 895-902.

Woodhouse, A., Vasseljen, O. (2008) Altered motor control patterns in whiplash and chronic neck pain. *BMC Musculoskeletal Disorders*, 9, 90.

CHAPTER 5

DEVELOPMENT OF AN ETHOGRAM TO ASSIST IN IDENTIFICATION OF EQUINE NECK PAIN DURING MANUAL CLINICAL ASSESSMENT: A PILOT STUDY

5.1 ABSTRACT

Spinal dysfunction negatively affects sport horse performance, and undiagnosed conditions may have welfare implications. In a pilot study using a single-blinded randomized controlled design, ten clinically non-lame horses (mean±SD: age=11.8±3.3 years) from matched career backgrounds (five cases with veterinary-diagnosed neck pain and five veterinary-assessed controls) were assessed blindly by an experienced equine manual therapy practitioner for signs of neck pain. Soft-tissue irritability and cervical vertebral joint range of motion assessment techniques adapted from human practice were used to identify muscular sensitivity and/or articular dysfunction from the atlanto-occipital joint to the cervicothoracic junction. Each session was recorded on video, focusing on the horse's head, neck and thoracic limbs during the manual assessment. Analysis of recordings was conducted blindly by an equine behaviorist and also by the manual therapy practitioner for evidence of behavioral manifestations in response to the manual assessment. Two groups of behavior that are subjectively associated with manifestations of pain/discomfort were identified, namely, aversive behaviors with the head/neck (withdrawal responses e.g. head toss, bite threat) and altered expressions of the eyes/ears (anxiety responses e.g. pinned ears, sclera showing). The numbers of occurrences were added from the observations for each horse. A Spearman's rank correlation coefficient test quantified agreement between paired scores from both observers. There was a strong correlation between agreements for evidence of withdrawal ($r=0.78$, $p<0.01$) and anxiety ($r=0.77$, $p<0.02$) responses. Overall, both groups of responses were noted more frequently in neck pain cases than in control horses

(mean \pm SE; cases: 237.60 \pm 75.18; controls: 57.60 \pm 18.22) but this difference was not statistically significant. Subjects were correctly identified as neck pain or control according to manual assessment. Behavioral manifestations should be considered in clinical assessment, however, behavioral observations alone as based on this pilot work were insufficient to accurately place all the subjects into their correct clinical classification of neck pain/control.

5.2 INTRODUCTION

The incidence of back and neck pain in horses has been reported to be between 2-94%, depending on the type of practice surveyed (Jeffcott 1980; Haussler *et al.* 1999b). Spinal dysfunction in horses is known to have a negative effect on performance (Ricardi and Dyson, 1993; Dyson, 2002; Murray *et al.*, 2006). Clinical findings associated with cervical arthropathies have been reported to cause forelimb lameness (Ricardi and Dyson, 1993), stiffness in movement, neck muscle atrophy and neck pain (Beck *et al.*, 2002; Dyson, 2003). Osseous lesions of articular process articulations are prevalent in the equine cervical and cranial thoracic column and severe osseous lesions, thought to be linked to pain, were found in at least one side, site or level in 38 out of 53 (72%) randomly selected spines in a post mortem study of the equine cervical and cranial thoracic spine (Thesis, Chapter 2).

Pain, in its purest form, can be described as a sensory reaction to tissue damage (Loeser and Melzack, 1999). In humans, manual palpation is useful for identifying focal points of neck pain that may be indicative of underlying pathology (Humphreys *et al.*, 2004). Clinically it has been reported that palpatory assessment of superficial and deep musculature of the equine cervical spine can be indicative of musculoskeletal dysfunction, according to localized reactions of hypersensitivity (Taylor and Romano, 1999; Sullivan *et al.*, 2008). In addition, intervertebral

range of motion testing of the equine cervical spine can detect restrictions or hypomobility that may be related to underlying pathologies such as osseous malformations, osteoarthritis or ankylosis (Haussler, 2009). Palpatory findings may be subjectively correlated to behavioral reactions associated with orthopedic pain (Bussi res *et al.*, 2008). Behavioral assessments in clinical cases with spinal pain have become a topic of interest alongside manual palpation as an adjunct to diagnostic evaluation in the equine spinal column, as the symbiotic relationship between pain and behavior in horses is recognized by the veterinary professional as a factor for consideration in clinical examinations (Short, 1998; Houpt and Mills, 2006; Driessen and Zarucco, 2007). Behavioral evaluation is strongly advocated as an adjunct to clinical and physiological measurements as reactions to palpation and alterations in temperament, posture and locomotion may be related to the presence of pain in the horse (Short, 1998; Ashley *et al.*, 2005).

One tool in the assessment of the behavioral component of pain in the horse has been the design and use of specialized ethograms. An ethogram can be defined as a list or inventory of behavioral elements specific to a species, with an emphasis on specific behaviors observed under a certain condition (McDonnell and Haviland, 1995). Simplified ethograms of behavior have been used as part of studies in clinical settings to aid equine diagnostics and monitor pain (Olbrich and Mosing, 2003; Price *et al.*, 2003; Pritchett *et al.*, 2003; Bussi res *et al.*, 2008; Fureix *et al.*, 2010). A specialized ethogram is useful to study individual animals in a specific context. Olbrich and Mosing (2003) suggested that avoidance movements of the head, neck, trunk, limbs and tail could be classed as positive pain responses in animals. Based on a review of publications and proceedings, Driessen and Zarucco (2007) produced a useful ethogram of behaviors observed in horses with acute, chronic, musculoskeletal or visceral/abdominal pain.

Specific to the spinal column of the horse, Fureix *et al* (2010) used a standardized test alongside chiropractic vertebral manual examination in 59 horses, dividing behaviors into broad categories of threats or positive behaviors, and aggression or non-aggression, based upon behavioral observations during the manual examination. Another measure of tissue sensitivity testing suggested for use in a clinical setting is mechanical nociceptive threshold (MNT) testing through pressure algometry (PA). PA has been suggested as a non-invasive method to identify and quantify sensitivity in the equine spine (Haussler and Erb, 2006; Sullivan *et al*, 2008; Haussler, 2009; Goff, 2009; Paulekas and Haussler, 2009; de Heus *et al*, 2010), and involves direct manual pressure from the rubber tip of an algometer with a force gauge. Pressure is applied with the rubber tip perpendicular to the area of testing, and the force gauge readings are reported as kg of force/cm² or as Newton per millisecond (N/ms). The point where a horse shows an avoidance reaction to gradually increasing direct pressure is referred to as the MNT. A lower MNT is thought to reflect higher sensitivity or a pain response. Behavioral manifestations including withdrawal responses and facial expressions were correlated with pain scoring based on PA readings in a study to assess muscle sensitivity in sacroiliac dysfunction in racehorses (Varcoe-Cocks *et al*, 2006).

There are currently no published ethograms that clearly identify, define and describe behaviors observed in examination and/or treatment of horses with dysfunction or pain in the cervical spine. The aim of this pilot study was to develop an ethogram of specific behaviors based on blinded videographic assessment by two independent examiners for specific behavioral reactions during manual palpation of the cervical spine in horses with diagnosed neck pain. We hypothesized that there would be positive agreement between the two examiners for evidence of

specific behaviors elicited during manual palpation of the cervical spine, and that these behaviors would be more frequently observed in horses with neck pain than in control subjects. We hypothesized that that both examiners could place neck pain and control subjects into their respective categories, based on observations of behavioural manifestations. We also hypothesized that the manual practitioner would be able to correctly place neck pain and control subjects into their respective categories, based on behavioral responses elicited during the blinded manual examination of the cervical spine and cervicothoracic junction of each subject.

5.3 METHODS

Ten clinically functionally sound horses (mean \pm SD: age=11.8 \pm 3.3 years) from a single veterinary practice were presented for manual examination of the cervical and cranial thoracic spine. The horses were matched by signalment as a neck pain subject and control subject based on similar age, height and weight and training/level of work. Four pairs of subjects were show jumping horses and one pair was comprised of dressage horses. All subjects were in current work. The neck pain subjects had been diagnosed as such, based on diagnostic imaging including radiography and ultrasonography and with reported loss of performance attributed to neck pain. Lesions included degenerative osseous changes in the articular process articulations (four subjects) and nuchal ligament insertional desmopathy (one subject). The control cases were all clinically assessed by the same veterinarian and were confirmed to be free from neck pain, based on clinical assessment and absence of behavioral signs indicating neck pain. All subjects were evaluated for soundness directly prior to the examination of the cervical spine through a standard lameness examination on a hard regular surface.

Exclusion criteria included a Grade 2 or more lameness using the AAEP lameness grading scale (http://www.aaep.org/health_articles_view.php?id=280). Following lameness examination, each subject was assessed by an experienced equine manual therapy practitioner (NR) for signs of neck pain. The practitioner was blinded to whether the subject was a neck pain or control subject. The palpatory examinations were carried out in a quiet area away from distractions, with a handler at the head of the horse. The handler allowed the horse to move the head and neck without restriction. Prior to focusing on the cervical spine, the practitioner carried out a superficial manual palpation over the entire body of the horse on left and right sides, using long soft strokes to allow the horse to become accustomed to the practitioner's touch. Soft-tissue irritability and cervical spine joint range of motion assessment techniques adapted from human practice were used to identify sensitivity/dysfunction from the atlanto-occipital joint to the cervicothoracic junction. Techniques included detection of muscle irritability of superficial and deep neck musculature through manual tissue tension evaluation and specific tissue provocation testing (for example: brachiocephalic response test); mobilizations, translations and glides of cervical intervertebral joints in different planes of motion for passive evaluation of intervertebral range of motion; dynamic assessment of gross motion in flexion, extension, lateral bending and rotation of the cervical spine, and range of motion testing of the cervicothoracic junction through specific range of motion tests (for example: sternal lift). In each horse the palpations were conducted in the same sequence on the left and right sides of the cervical spine into the cervicothoracic region. Each session was recorded on video, focusing on the horse's head, neck and thoracic limbs and on the practitioner's body position and hand placement during the evaluation. The assessment sessions were all of similar length: once the entire region had been examined on both sides and the practitioner was sufficiently confident that each provocation

technique had been carried out, the session terminated. Where a specific test or technique provoked a reaction of sensitivity, this test or technique was repeated multiple times to ascertain whether the behavioral response could be provoked repeatedly. The average time for the manual assessment was 19.34 minutes per horse. Following the testing of each horse, the manual therapy practitioner decided whether the subject would be placed in the category of neck pain or control subject. After blinded examination of all the subjects, the veterinary case records were obtained from the equine practice.

The videos were subsequently analysed by the manual therapy practitioner and also blindly by an experienced equine behaviorist (CH), for evidence of specific behavioral manifestations in response to the manual assessment. Both assessors analysed the videos independently. Specific aversive behaviors were identified by both assessors (Appendix E). Each assessor counted the number of occurrences of each behavior throughout the video recording for each subject. The sum of each of the individual behaviors was added to form a total sum for responses that were subsequently divided into two different groups of behavioral responses. A Spearman's rank correlation coefficient test quantified agreement between the two observers for paired scores for each subject in each of the two groups of behavioral responses.

5.4 RESULTS

Based on the specific behaviors observed during videographic assessment, aversive behaviors were divided into two groups (Appendix E). Withdrawal responses included behaviors such as rapidly moving away from or towards the practitioner with the head and neck and tossing and shaking of the head and neck. Anxiety responses included pinning of ears and showing of the

sclera. There was a strong agreement between both observers for evidence of withdrawal ($r=0.78$) (Fig.5.1) and anxiety ($r=0.77$) (Fig. 5.2) responses.

The data show a high degree of variability in neck pain subjects. Adversive behaviors were overtly displayed by two out of the five of the neck pain subjects. Both groups of responses were noted more frequently in the clinically diagnosed neck pain cases ($n=5$) than in the control cases ($n=5$), with a mean number of total responses of 237.60($SE=75.18$) versus 57.60($SE=18.22$), respectively, but difference was not statistically significant.

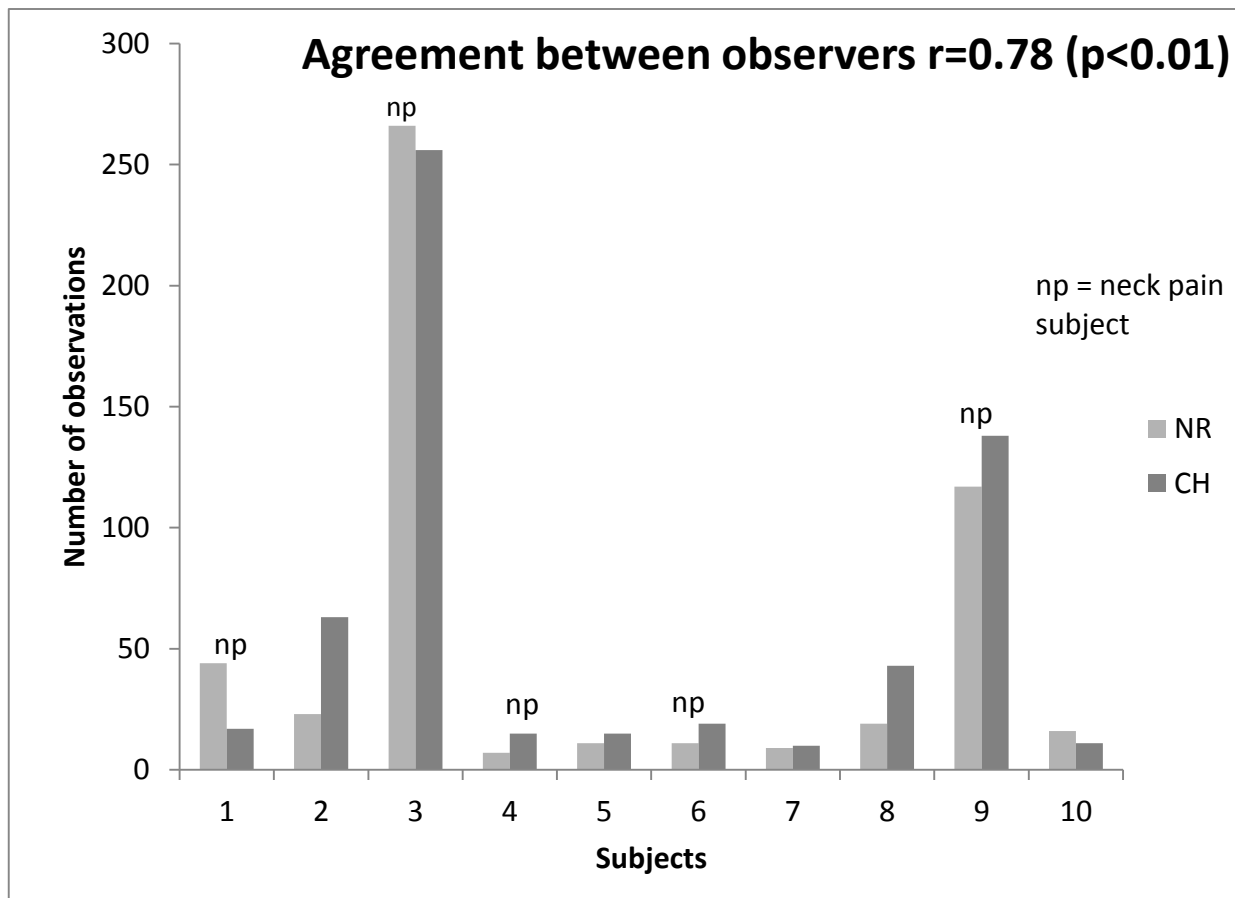


Figure 5.1: Agreement between independent observers for identification of withdrawal responses during manual assessment of the cervical spine and cervicothoracic junction in control subjects and horses with neck pain. NR and CH are independent examiners; NP refers to neck pain versus control subject.

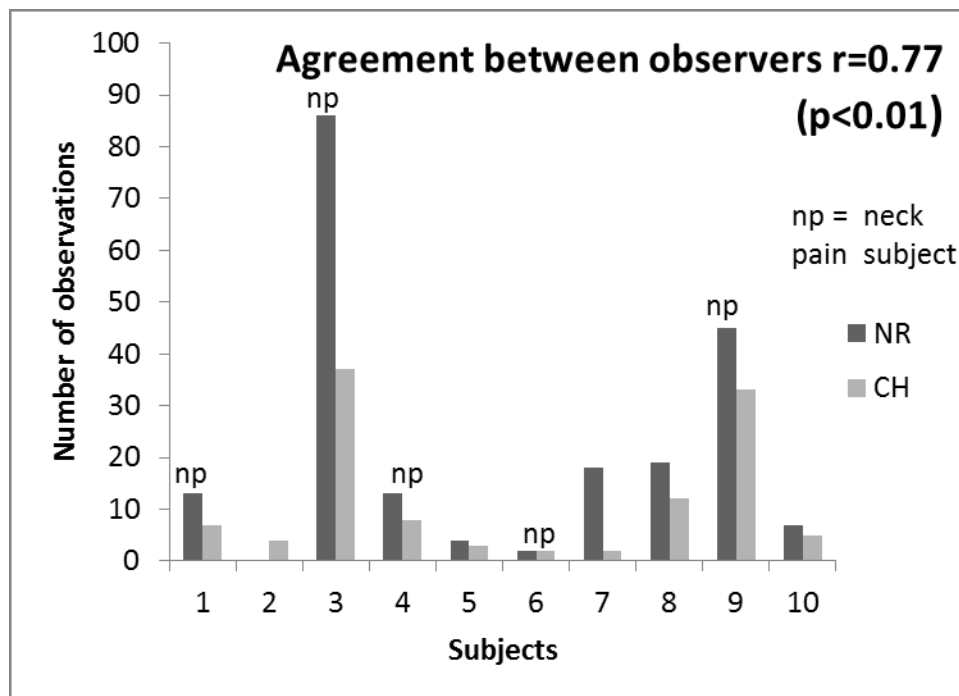


Figure 5.2: Agreement between independent observers for identification of anxiety responses during manual assessment of the cervical spine and the cervicothoracic junction in control subjects and horses with neck pain. NR and CH are independent examiners; NP refers to neck pain versus control control subject.

The manual therapy practitioner correctly placed each subject into the category of neck pain or control subject, based on the manual palpatory assessment (Figure 5.3). It was not possible for both examiners to correctly place each subject into the category of neck pain or control subject, based on videographic evaluation of the manual palpatory assessment (Figure 5.3).

subject	NR*	CH**	Clinician diagnosis
1	Y	Y	Y
2	N	Y	N
3	Y	Y	Y
4	Y	N	Y
5	N	N	N
6	Y	N	Y
7	N	maybe	N
8	N	N	N
9	Y	Y	Y
10	N	N	N
* neck pain classification according to blinded manual palpation assessment			
** neck pain classification according to blinded video assessment			

Figure 5.3: Categorization of neck pain versus control subject by two independent examiners based on manual palpatory assessment (NR) and videographic assessment of manual palpatory assessment (CH) of the cervical spine and the cervicothoracic junction. NR and CH are independent examiners. Y refers to neck pain subject; N refers to control subject.

5.5 DISCUSSION

This pilot study demonstrated that specific aversive behaviors could be elicited during manual clinical assessment techniques in the cervical and cervicothoracic regions, which could be used

as an adjunct in clinical examination to identify horses with neck pain. Objective measurement of pain in animals has been long recognized as a challenge, and assessment of pain in animals cannot be based on a direct comparison of mechanisms and behavior observed and measured in humans. People with pain have the ability to self-report and give verbal feedback on the intensity of experienced pain during examination (Bateson, 1991; Short, 1998). These are key factors that cannot be incorporated in pain testing in animals. The relationship between pain and behavior in horses has been recognized by the veterinary professional as an adjunct factor for consideration in clinical examinations (Short, 1998; Taylor *et al*, 2002; Houpt and Mills, 2006; Driessen and Zarucco, 2007; Bussi res *et al*, 2008) where behavioral alterations such as changes in eye expression, specific movements with the head and withdrawal movements are recognized as potential expressions of pain. The specific reactive withdrawal behaviors that were identified in our study concur with findings from other studies where palpation or nociceptive testing techniques were used to identify focal areas of sensitivity or dysfunction in the equine spine which resulted in specific behavioral manifestations including evasive and withdrawal responses when a nociceptive threshold was reached (Haussler and Erb, 2006; Varcoe-Cocks *et al*, 2006; de Heus *et al*, 2010).

As self-measurement or self-reporting of pain is not possible in animals (Anand and Craig, 1996; Mogil, 2009), it is suggested that increased magnitude of pain measurement responses, including behavioral changes, indicate a greater significance of perceived pain to the animal (Rutherford, 2002). In this study, two of the subjects with diagnosed neck pain displayed more overt manifestations of sensitivity to manual palpation than control subjects. The lack of a statistically significant difference in the amount of behavioral responses from neck pain versus control subjects could be due in part to the small sample group in this pilot study, but the individual pain

neuromatrix of each horse must also be considered, as some of the neck pain subjects did not display overt behavioral reactions to manual assessment.

It is essential that normal behavior is understood in order to interpret any behavioral changes where these may be related to pain (Taylor *et al*, 2002; Pritchett *et al*, 2003). It is not known, however, whether these behaviors can truly be identified as pain, as paresthesia or as avoidance mechanisms to mechanical allodynia (Mogil, 2009) from manual palpation/stimulation. Nociceptive and mechanical receptors are found in the skin, musculature, connective tissues and joints throughout the equine cervical and cervicothoracic segment, and these structures were all addressed in the manual assessment.

5.6 LIMITATIONS

Based on the small group size, the difference in the number of aversive behaviours observed between neck pain and control subjects was not significant. A similar study with a larger group is warranted to investigate whether similar withdrawal and anxiety behaviours can be observed over time and/or by different practitioners during manual examination of horses with neck pain. The subjects in this study were tested on one occasion by one practitioner. The list of behaviors in the ethogram that was produced from the findings of this study is not exhaustive. Only dynamic responses to palpation were included, but static observations of (alterations in) posture, avoidance or withdrawal movements with the limbs during assessment as well as alterations in habits of eating, sleeping and social interaction should be included in future studies. Proficiency of assessment techniques and interpretation of reactions can vary between examiners, and the

individual pain neuromatrix (cortical pain activation) (Mosely, 2003) of each subject may also account for variations in intensity of expressions of discomfort or pain. Finally, reactions to manual palpation are not indicative of the severity of discomfort or pain due to the lack of ability of the animal to give verbal feedback or self-report on the intensity of discomfort or pain.

5.7 CONCLUSIONS

Although aversive behaviors in this pilot study were displayed more frequently during manual clinical assessment of horses with neck pain, larger study numbers are necessary to quantify a true significance. Each subject was correctly identified as a neck pain or control subject according to blinded manual assessment, but observations of behavioral manifestations alone were not sufficient to place each horse into its respective category of neck pain or control subject. A future study suggests repeated blinded randomised testing sessions on the same day and/or over several days to determine intra-examiner reliability, as well as blinded randomised testing by more than one practitioner to determine inter-examiner reliability. The relationship between equine behavior and discomfort or pain is recognized in clinical settings. An increased understanding of specific behaviors related to equine spinal dysfunction, including the cervical segment, could support clinical examination and diagnostic imaging findings.

APPENDIX

APPENDIX: Ethogram of behaviors identified during manual clinical assessment of the equine cervical and cranial thoracic region

BEHAVIOR	DESCRIPTION
WITHDRAWAL RESPONSES	
Neck/Head toss	Horse moves head quickly out of 'neutral' position; oscillation of neck; some movement in medio-lateral plane
Neck/Head raise	Head held higher than 'neutral' with nose extended upward and extension of the neck
Neck/Head down	Head held lower than 'neutral' with nose pushed forward and extension of neck
Neck/Head shake	Dorsoventral movement in vertical plane: head and/or neck
Neck/Head turn	Lateral flexion of head and/or neck towards practitioner or handler: a fast move with display of threat
Neck/Head tilt	Deviation of head and/or neck from midline to left or right side
ANXIETY RESPONSES	
Ears pinned back	Ears pressed caudally against the poll area of the neck
Change in eye	Open wider, showing of sclera

Figure E1: Ethogram of behaviors identified during manual clinical assessment of the equine cervical and cranial thoracic region

BIBLIOGRAPHY

BIBLIOGRAPHY

Anand, K. J. S., Craig, K. D. (1996) New perspectives on the definition of pain. *Pain* 67, 3-6.

Ashley, F. H., Waterman-Pearson, A. E., Whay, H. R. (2005) Behavioural assessment of pain in horses and donkeys: application to clinical practice and future studies. *Equine Vet. J.* 37, 565-575

Beck, C., Middleton, D., Maclean, A., Lavelle, R. (2002) Osteochondrosis of the second vertebra of a horse. *Equine Vet. J.* 34, 210-212.

Bateson, P. (1991) Assessment of pain in animals. *Anim. Behav.* 42, 827-839.

Bussi res, G., Jacques, C., Lainay, O. Beauchamp, G., Leblond, A. et al. (2008) Development of an orthopaedic pain scale in horses. *Res. Vet. Sci.* 85, 294-306.

de Heus, P., van Oosaenen, G., van Dierendonck, M. C., Back, W. (2010) A pressure algometer is a useful tool to objectively monitor the effect of diagnostic palpation by a physiotherapist in warmblood horses. *J. Equine Vet. Sci.* 29, 310-321.

Driessen, B., Zarucco, L. (2007) Pain: from diagnosis to effective treatment. *Clinical Techniques in Equine Practice**, 6, 126-134. *Title discontinued from 2008.

Dyson, S. (2002) Poor performance: cannot or will not? In: Conference on Equine Sports Medicine and Science – the Elite Dressage- and Three-Day Event Horse, October 2002, Saumur, France. Ed. By Dr A. Lindner. Lensing Druck: Dortmund, 43-54.

Dyson, S. J. (2003) The cervical spine and soft tissues of the neck. In: Ross, M. W. and Dyson, S. J. (Eds) *Diagnosis and management of lameness in the horse*. W.B. Saunders, St. Louis, pp. 523-531.

Fureix C, Menguy H, Hausberger M (2010) Partners with Bad Temper: Reject or Cure? A Study of Chronic Pain and Aggression in Horses. *PLoS ONE* 5(8): e12434.

Goff, L. M. (2009) Manual therapy for the horse: a contemporary perspective. *J. Equine Vet. Sci.* 29, 799-808.

Haussler, K. K. (1999b) Chiropractic evaluation and management. *Vet. Clin. N. Am. - Equine* 15, 195-208.

Haussler, K. K., Erb, H. N. (2006) Mechanical nociceptive thresholds in the axial skeleton of horses. *Equine Vet. J.* 38, 70-75.

Haussler, K. K. (2009) Review of manual therapy techniques in equine practice. *J. Equine Vet. Sci.* 29, 849-869.

Houpt, K. A., Mills, D.S. (2006) Science: overviews. Why horse behaviour is important to the equine clinician. *Equine Vet. J.* 38, 386-387.

Humphreys, B. K., Delahaye, M., Peterson, C. K. (2004) An investigation into the validity of cervical spine motion palpation using subjects with congenital block vertebrae as a 'gold standard'. *BMC Musculoskel. Dis.* 15,19.

Jeffcott, L. B. (1980) Disorders of the thoracolumbar spine of the horse- a survey of 443 cases. *Equine Vet. J.* 12, 197-210.

Loeser, J. D., Melzack, R. (1999) Pain: an overview. *The Lancet* 353, 1607-1609.

McDonnell, S. M., Haviland, J. C. S. (1995) Agonistic ethogram of the equid bachelor band. *Appl. Anim. Beh. Sci.* 43, 147-188.

Moseley, G. L. (2003) A pain neuromatrix approach to patients with chronic pain. *Manual Ther.* 8, 130-140.

Murray, R. C., Dyson, S. J., Tranquille, C., Adams, V. (2006) Association of type of sport and performance level with anatomical site of orthopaedic injury diagnosis. *Equine Vet. J.* (Supplement) 36, 411 – 416.

Olbrich, V. H., Mosing, M. (2003) A comparison of the analgesic effects of caudal epidural methadone and lidocaine in the horse. *Vet. Anaesth. Analg.* 30, 156-164.

Ricardi, G., Dyson, S. J. (1993) Forelimb lameness associated with radiographic abnormalities of the cervical vertebrae. *Equine Vet. J.* 25, 422-426.

Paulekas, R., Haussler, K. K. (2009) Principles and practice of therapeutic exercise for horses. *J. Equine Vet. Sci.* 29, 870-893.

Price, J., Seago, C., Welsh, E. M., Waran, N. K. (2003) Preliminary evaluation of a behavior-based system for assessment of post-operative pain in horses following arthroscopic surgery. *Vet. Anaesth. Analg.* 30, 124-137.

Pritchett, L. C., Ulibarri, C., Roberts, M. C., Schneider, R. K., Sellon, D. C. (2003) Identification of potential physiological and behavioral indicators of postoperative pain in horses after exploratory celiotomy for colic. *Appl. Anim. Beh. Sci.* 80, 31-43.

Short, C. E. (1998) Fundamentals of pain perception in animals. *Appl. Anim. Beh. Sci.* 59, 125-133.

Sullivan, K. A., Hill, A. E., Haussler, K. K. (2008) The effects of chiropractic, massage and phenylbutazone on spinal mechanical nociceptive thresholds in horses without clinical signs. *Equine Vet. J.* 40, 14-20.

Taylor, L. L., Romano, L. (1999) Veterinary chiropractic. *Canadian Vet J* 40, 732-735.

Varcoe-Cocks, K., Sagar, K. N., Jeffcott, L. B., McGowan, C. M. (2006) Pressure algometry to quantify muscle pain in racehorses with suspected sacroiliac dysfunction. *Equine Vet. J.* 38, 558-562.

Mogil, J. S. (2009) Animal models of pain: progress and challenges. *Nat. Rev. Neurosci.* 10, 283-294.

Rutherford, K. M. D. (2002) Assessing pain in animals. *Anim. Welfare*, 11, 31-53.

Taylor, P. M., Pascoe, P. J., mama, K. R. (2002) Diagnosing and treating pain in the horse: where are we today? *Vet. Clin. N. Am. - Equine* 18, 1-19.

CHAPTER 6

SUMMARY, CONCLUSIONS AND RECOMMENDATIONS FOR FUTURE RESEARCH

6.1 SUMMARY

The combined objective of this series of studies was to investigate neck pain in the horse from anatomical, clinical and behavioral perspectives. Equine back pain has been investigated more widely in the past decade, and diagnosis and treatment of thoracolumbar dysfunction has improved greatly based upon findings from biomechanical and clinical studies. The cervical spine has received much less attention and although it is more widely accepted that neck pain has a negative effect on equine athletic performance, there are however numerous gaps in the current understanding of cervical spinal dysfunction in the horse. These include a lack of detailed definition of the perivertebral stabilizing musculature of the cervicals spine, incomplete knowledge of the distribution of osseous degenerative lesions in the APAs of the equine cervical and cranial thoracic spine, the inability to objectively measure size of the perivertebral musculature in the equine cervical spine and a limited understanding of specific aversive equine behaviors that may be associated with pain originating from dysfunction in the cervical spine. In this thesis I have addressed some of these gaps in knowledge.

Chapter 2 described the gross morphology and architecture of *m. multifidus cervicis* and *m. longus colli* in the horse, based on anatomical dissections in 15 horse cadavers. *M. multifidus cervicis*, an extensor muscle of the equine cervical spine, has direct attachments onto the articular process articulations (APAs) of the vertebrae in the cervical spine. The muscle crosses between

one and four intervertebral joints in an arrangement of three distinct layers, made up of five fascicles in total. *M. multifidus* continues into the thoracolumbar spine in the same morphological arrangement as observed in the cervical spine. *M. longus colli*, a flexor muscle of the equine cervical and cranial thoracic spine, has direct attachments onto the transverse processes in the cervical spine, and onto the ventral vertebral bodies and the joint capsule of the costovertebral joints in the cranial thoracic spine. The muscle crosses between one and four intervertebral joints. In the cervical spine, *m. longus colli* has an arrangement of three distinct layers made up of five fascicles in total, a virtual mirror image of *m. multifidus cervicis*. In the thoracic spine, the muscle consists of one large, well-defined muscle belly that continues to T5/T6. Based on their structure, *m. multifidus cervicis* and *m. longus colli* may play a key role in intersegmental spinal dynamic stability and proprioception in the cervical spine of the horse. Both muscles had the largest cross-sectional area at the levels of C4 and C5, which may indicate that this is a region in the cervical spine where dynamic stability is most required. Based on the human neck pain studies, these muscles may be associated with dysfunction and/or pain in the equine cervical spine.

Osteoarthritis (OA) is a recognized clinical condition in the equine cervical spine but the prevalence and distribution of OA in the APAs is not well-documented. This was investigated in Chapter 3. In a post-mortem study, the cervical and cranial thoracic vertebrae (from C1 to T7) of 53 horses of different ages and sizes were evaluated for the presence of OA of the APAs. It was found that OA was symmetrically present on the left and right sides and that OA lesions were more severe and more prevalent in older and larger horses. This factor supports the administration of bilateral injections in APAs for clinical treatment of OA in the equine cervical

spine. Degenerative OA lesions were more severe in the mid-cervical and cervicothoracic regions than in the cranial cervical or cranial thoracic regions.

The role of deep spinal stabilizing muscles in neck pain has been widely cited in human studies, specifically with reference to *m. multifidus* and *m. longus colli*. Ultrasound (US) imaging of both muscles is a validated technique for repeatable measurement of the cross-sectional area (CSA) of both muscles in people. Objective measurement of the muscle CSA is of particular interest in clinical therapeutic settings, as atrophy or left:right asymmetry of the CSA of *m. multifidus* and *m. longus colli* at specific levels in the human cervical spine are linked with pain or dysfunction at the same spinal level. The loss of function of these muscles leads to intervertebral instability and has a negative effect on neuromotor control, specifically on head and neck position sense. Specific rehabilitative programs are aimed at increasing muscle size and symmetry to reduce recurrent episodes of neck pain, and US is a useful tool for objective measurement of muscle CSA over time. Chapter 4 investigated the possibility of using US to measure the CSA of *m. multifidus* and *m. longus colli* in the equine cervical spine. In this study I developed a technique using US for CSA measurement of *m. multifidus cervicis* and *m. longus colli* at specific levels in the equine cervical spine. The technique for muscle CSA measurement using US was developed in a post-mortem study using magnetic resonance (MR) as the ‘gold standard’ for comparison of repeatability in image acquisition and CSA measurement. In Study 2, intra- and inter-operator repeatability of US image acquisition and CSA measurement were determined from US CSA measurements of *m. multifidus cervicis* and *m. longus colli* obtained in the live, standing horse. Results from both studies show that US is a repeatable technique for CSA measurement of *m. multifidus cervicis* and *m. longus colli* at specific levels of the equine cervical spine, according to a specific protocol for image acquisition and analysis. Ultrasound could be used as an objective

measurement tool in future studies as a means of functional evaluation of therapeutic rehabilitative exercise intervention for horses with neck pain.

A common challenge in equine diagnostic procedures is the inability to self-report from the patient. As such, there is an increased trend to include observations of behavioral manifestations in clinical examinations of the horse. Specific manual provocation tests are commonly used to determine sensitivity in musculoskeletal examinations. Manifestations of sensitivity, such as withdrawal responses and alterations in facial expressions may be an indication of perception of pain. An ethogram is a list of specific behaviours that can be observed repeatedly over time and by different examiners. As there are currently no published ethograms that clearly identify, define and describe behaviors observed in examination of horses with dysfunction or pain in the cervical spine, the study in Chapter 5 identified specific behaviors that may be elicited by horses with neck pain, during a standardized manual examination that is commonly used in clinical and therapeutic practice. Although only considered a pilot study because of the small number of subjects, it was possible to identify certain distinct aversive behavioral responses to manual palpation assessment and mobilization techniques in the cervical spine and cervicothoracic junction of horses with neck pain. Real time feedback from manual palpation assessment techniques is commonly used in human clinical settings to evaluate patients with neck pain, and similar manual palpation techniques that were applied to the horse were sufficient to correctly place each horse into its respective category of neck pain versus control subject. The relationship between equine behavior and discomfort or pain is recognized in clinical and therapeutic settings, and an increased understanding of specific behaviors related to equine spinal dysfunction, including the cervical segment could support clinical examinations. Although behavioral observations alone were not sufficient in this pilot study to place subjects into their

respective category of neck pain or control, observation of these behaviors and the use of manual palpation assessment and mobilization techniques could be applied in evaluation of progress in clinical treatment and/or therapeutic or rehabilitative programs specifically aimed at restoring optimal function of the equine cervical spine.

6.2 CONCLUSIONS

The following conclusions were obtained from this series of studies:

- The multi-fascicular morphology of the equine *m. multifidus cervicis* and *m. longus colli* is consistent with a function of providing dynamic segmental stability and support in the equine cervical spine.
- OA lesions of the articular process articulations are most severe in the mid-cervical vertebrae (C3-C4) followed by those at the cervicothoracic curvature (C5-T1). Severity of OA does not differ between left and right sides but increases with age and size of the horse.
- Ultrasonography can be used in the live horse for repeatable CSA measurement of *m. multifidus* and *m. longus colli* in the mid-cervical spine.
- Manual palpation techniques can be used as an adjunct to clinical examination to identify neck pain in horses, based on correct placement of subjects into their respective category of neck pain or control, based on a manual clinical assessment only. Aversive behavioral manifestations elicited during manual examination, such as specific movements with the head/neck (withdrawal responses e.g. head toss, bite threat) and altered expressions of the

eyes/ears (anxiety responses e.g. pinned ears, sclera showing) may be observed in horses with neck pain, but based on this pilot work, these behavioral observations alone were not sufficient to place subjects into a category of neck pain or control.

6.3 RECOMMENDATIONS FOR FUTURE RESEARCH

This series of studies highlights the need for further research into the phenomenon of equine neck pain. Examination is warranted of osseous degenerative lesions of the entire cervical vertebra. A key concept in human neck pain studies is that of total joint complex failure, namely, lesions to the articular process articulations and the associated vertebral end plates and intervertebral disc. It is not known in the horse whether there is an association between osseous lesions in the articular process articulations and concurrent degenerative changes in the associated vertebral end plates and intervertebral discs.

Future studies using ultrasound imaging to measure muscle CSA suggest investigation into the symmetry and size of *m. multifidus cervicis* and *m. longus colli* in neck pain and control subjects, to determine whether there is an association between OA lesions and alteration in muscle size of these stabilizing muscles in the equine cervical spine. If localized muscle atrophy can be detected in neck pain subjects, the effect of rehabilitative therapeutic exercises can be investigated by using US to measure CSA of *m. multifidus cervicis* and *m. longus colli*. This is a widely-used technique in rehabilitation of human neck pain patients.

Many gaps remain in the knowledge of cervical dysfunction in the horse, but the findings from these studies can aid in the building of an objective foundation for future research into the complex phenomenon of equine neck pain.