GROSS AND MICROSCOPIC ANATOMY OF THE DIGESTIVE AND URINARY SYSTEMS AND HISTOLOGY OF THE REPRODUCTIVE SYSTEM OF THE NUTRIA, *MYOCASTOR COYPUS BONARIENSIS* (GEOFFROY).

Thesis for the Degree of Ph.D.
MICHIGAN STATE UNIVERSITY
John Alexander Wagner
1961

This is to certify that the

thesis entitled

GROSS AND MICROSCOPIC ANATOMY OF THE DIGESTIVE
AND URINARY ORGANS AND HISTOLOGY OF THE
REPRODUCTIVE ORGANS OF THE NUTRIA,
MYOCASTOR COYPUS BONARIENSIS (GEOFFROY).

presented by

John A. Wagner

has been accepted towards fulfillment
of the requirements for

Ph.D. **degree in** ZOOLOGY

R. A. Fennell
Major professor

Date September 13, 1961

O-169

GROSS AND MICROSCOPIC ANATOMY OF THE DIGESTIVE AND URINARY SYSTEMS AND HISTOLOGY OF THE REPRODUCTIVE SYSTEM OF THE NUTRIA, MYOCASTOR COYPUS BONARIENSIS (GEOFFROY).

By

John Alexander Wagner

A THESIS

Submitted to
Michigan State University
in partial fulfillment of the requirements
for the degree of

DOCTOR OF PHILOSOPHY

Department of Zoology

1961

[illegible] / [illegible] /
8/22/62

ABSTRACT

In recent years there has been an increased interest in conservation studies in the United States. Despite this fact, there has been no carefully planned program for studies from an anatomical and histological viewpoint on the nutria, which was introduced into this country in 1937. The present study represents a contribution to the knowledge of the gross and microscopic anatomy of the digestive and urinary systems and histology of the reproductive system of the nutria, designated as Myocastor copyus bonariensis, Geoffroy, a hystricomorph rodent.

Eight adult animals were dissected and fifteen drawings were made of various dissections. Forty photomicrographs were made of various histological sections.

The oral cavity was small and was always closed anteriorly by the protrusion of the anterior tip of the tongue. The oral cavity presented a trichous postincisal subdivision. The teeth were twenty in number, and monophyodont. The pharynx was mainly nasopharynx and the laryngeal pharynx was absent. The posterior border of the soft palate was free and was in contact with the epiglottis. Palatine ridges were absent in the hard palate.

The stomach was lenticulated with its anterior end curved to form a prominent arch. The small intestine could not be

divided into subdivisions except on an arbitrary basis. Numerous lymph nodules were present in the walls of the small intestine.

The large intestine consisted of a large spiralled and sacculated cecum, a sacculated large colon and non-sacculated small colon.

The liver and gall bladder were very large compared to the rabbit, guinea pig and chinchilla.

Histologically the epithelium of the mucosa of the tongue was highly keratinized. Filiform papillae were the most numerous. The parotid salivary gland was serous while the submaxillary and sublingual were mixed.

Paneth cells were found in the depths of the crypts of Lieberkuhn. The distal surface of the epithelium of the intestinal mucosa exhibited a prominent striated border. The trabeculae of the spleen was not too prominent. The characteristic brush borders of the proximal convoluted tubules were not observed.

The ductus deferens lacked an ampulla. Elastic fibers were absent in the ovary. The glans penis contained a baculum. The epithelium of the glans penis formed numerous spines.

ACKNOWLEDGEMENTS

For the numerous and various kinds of assistance offered during the investigation of this problem, the author feels keenly indebted to the members of his dissertation committee: Doctors M. Lois Calhoun, William B. Drew, Thomas W. Jenkins, and R. A. Fennell, Chairman.

The author is especially indebted to Dr. R. A. Fennell for making it possible to secure the specimens used in this investigation and to Dr. Horace Whitten of Waubun Laboratories for trapping and embalming them.

The author is likewise indebted to Dr. James C. Braddock, who so kindly consented to serve as chairman during Dr. R. A. Fennell's leave of absence. Thanks and appreciation are due also to Dr. Karl A. Stiles, Head of the Zoology Department, and Dr. John R. Shaver for their assistance and counseling.

Further, the author has a feeling of indebtedness to Dr. Madan Bharadwaj for his assistance in histological aspects; Miss Lois Waterman and Mr. Hal Hepler for checking parts of the manuscript; and Mr. Lee Virn Leak, Research Assistant, for aiding in compiling data. Thanks are also due to the author's four undergraduate students, Messers Gary and Terry Dardas, George Rogers and Ronald Scheuenstuhl, all of Bay City

Junior College for their encouragement and interest during this investigation.

Many thanks are due to Dr. L. J. Kaasa, Pathologist for Midland Hospital, for making available the facilities of that institution and to Mr. Lowell L. Andrews, Cytologist at Midland Hospital for his invaluable assistance in histological technique.

Mr. Claude Schrantz, Art Instructor at Kolb School, Bay City, deserves thanks for making the drawings. Mrs. Bernadette Henderson shall always be remembered for constant encouragement and skillful counseling in the Department of Zoology.

The author's wife shall long be remembered for essential comforts and fortitude during this investigation.

Finally, the author acknowledges his indebtedness to Dr. Eric J. Bradner, Dean of Bay City Junior College, for his encouragement and leaves of absences from the college while the investigation was in progress.

VITA

John Alexander Wagner

candidate for the degree of

Doctor of Philosophy

Dissertation: Gross and Microscopic Anatomy of the Digestive and Urinary Organs and Histology of the Reproductive Organs of the Nutria, *Myocastor coypus bonariensis* (Geoffroy).

Outline of Studies:

Major subject: Zoology

Minor subject: Anatomy

Biographical items:

Born: January 7, 1923, Sipsey, Alabama

Undergraduate Studies: Lane College, Jackson, Tennessee, 1940-1942; Southern University, Baton Rouge, Louisiana, 1946-1948, B.S., 1948.

Graduate Studies: Duquesne University, Pittsburgh, Pennsylvania, 1950-1951, M. S., 1951; The University of Chicago, Chicago, Illinois, Summer 1954, 1955-1956.

Experience: Jr. Biologist, U.S. Public Health Commission Tokyo, Japan, 1948-1950; Head, Department of Biology, Benedict College, Columbia, South Carolina, 1951-1953; Associate Professor of Biology, South Carolina State College, Orangeburg, South Carolina, 1953-1956; Head, Department of Biology, Bay City Junior College, Bay City, Michigan, 1956-June 1961; Chairman, Science Division, Delta College, June 1961-present.

Member: American Association for the Advancement of Science, Beta Kappa Chi, American Society of Bacteriologists and Alpha Kappa Mu.

CONTENTS

LIST OF FIGURES

LIST OF FIGURES - Continued

I. INTRODUCTION

Osgood (1943) stated that the coypu has five recognized geographical races which together have an extensive natural range in southern South America. The species occurs in coastal areas and in large rivers approxiamtely 15° South latitude in Southern Brazil, Paraguay and Bolivia to the Pacific coast of Tierra del Fuego. He recognized subspecies as follows: *Myocastor coypus coypus*, central Chile; *Myocastor coypus melanops*, southern Chile; *Myocastor coypus santacruzae*, southeastern Argentina; *Myocastor coypus bonariensis*, northeastern Argentina and Uruguay; and *Myocastor coypus popelairi*, southeastern Bolivia. Allen (1942) maintained that there are at present only three living races recognized; *Myocastor coypus coypus*, the typical form of Chile at lower altitudes; the race *bonariensis* of northern Argentina, Uruguay, Paraguay and southern Brazil and *Myocastor coypus santacruzae* of southeastern Argentina. According to Lowery (1943) the subspecies in Louisiana and Texas is probably *Myocastor coypus bonariensis*, a form native to northern Argentina, Uruguay, Paraguay, and South Brazil.

The occurrence of nutria (*Myocastor coypus*), sometimes known as the swamp beaver, South American beaver, and coypu in the catches of Louisiana trappers in recent years has been a source of great interest to managers of fur and game farms, fur tradesmen, and the general public. This new source of fur has been of special interest to those who are concerned with increasing fur production in the United States.

According to Osgood (1943) the coypu (also called "nutria") is a native of Chile. The earliest record of nutrias imported to the United States was in 1899. Will Frakes (cited by Osgood, 1943) brought from South America one mature male and three young female nutrias to Elizabeth Lake, California. As a matter of record, Frakes sent a specimen to the National Museum, Washington, D. C. in 1900.

The coypu was introduced into Louisiana by E. E. McIlhenny of Avery Island, Louisiana (cited by Lowery, 1943). Eight pairs were imported by McIlhenny from Argentina during the winter of 1937. The animals were originally kept in an especially constructed enclosure at Avery Island where they reproduced prolifically. Within two years after nutrias escaped from a pen at Avery Island, they had populated the marsh from Mississippi to southeastern Texas.

According to Ashbrook (1943) nutrias were first trapped on the Sabine National Wildlife Refuge during the season 1941-1942, and on Laccasine in the winter of 1943; both Federal refuges are located in Cameron Parish, Louisiana. Nutrias are now established as a part of the mammalian fauna of Louisiana.

On first sight a nutria on land looks like a stunted beaver with a long round tail. It is clumsy and possesses an unsightly fur covering. The head resembles that of a guinea pig. The mammary glands which are covered by coarse fur are on the back. The choice fur is on the stomach. The distinguishing characteristics of the male are a larger and stronger body, and coarser head and neck than those of the female. A full grown male weighs from 20-25 pounds, while the average female weighs 18-22 pounds.

Careful studies should be made of this form in order to supply more general zoological information. Sauborn in his account of the mammals of Uruguay (Allen, 1942) stated that coypus have been so heavily exploited for their fur that they are now quite scarce in settled districts of Argentina. He further stated that they had been under heavy hunting and trapping pressures on account of the value of the fur and called attention to the fact that in consequence they had disappeared from many parts of Argentina. The export of fur is now under government control and there are farms in Argentina for breeding. Presently there are 160 breeding farms

in Michigan. Ensminger (1955) wrote that a cooking experiment had recently been concluded at Louisiana State University. It was stated that the nutria is one of the cleanliest animals in the state and was being eaten throughout the marsh area.

Allen (1942) included the nutria among the extinct or vanishing mammals of the western hemisphere. Ashbrook (cited by Allen, 1942) however, stated that the nutria is not in as great danger of extermination as the Chinchilla, but that strict conservation laws are necessary. There is the added circumstance that the nutria is much more prolific than the Chinchilla.

A report on the comparative takes of fur animals in Louisiana prepared by the Louisiana Wildlife and Fisheries Commission (1940-41) showed that recently there had been an annual increase in the number of nutria taken. During the 1956-1957 trapping season 543,160 nutria were trapped which brought a total of $814,740.00. It should be emphasized that the price of the pelts varied each year and that the nutrias found in Louisiana were wild. Their pelts did not bring a price equal to that paid for those bred in captivity.

Schacher (1956) reported that numerous diseases have been found to affect the nutria, some apparently common to man.

Thus, gross anatomical and microscopic studies would be useful as a standard of comparison for the study of the various morphological changes due to disease.

Despite the fact that the nutria has been an object of considerable interest and discussion during the past few years in the United States, up to the present time there have been only two other studies published here from an anatomical and histological viewpoint. Hillemann, Gaynor and Stanley (1958) and Stanley and Hillemann (1960) confined their study to the anatomy of the genital system and histology of the reproductive organs. Most of the other publications have dealt with breeding, ecology, external features and natural studies of the nutria in coastal Louisiana.

Only a limited number of investigations have been concerned with morphological and histological features of the nutria, and these have been done largely in Europe. Walther (1931) described some of the general features. De Girolamo (1948), (1953), described the dentition and reported on the histology of the islets of Langerhans in the pancreas. Preuss (1953) considered the anatomy and histology of the ovaries. Schwarze and Hoffman (1954) reported on the distinquishing characteristics of the skeletons of domestic and wild rabbits, hares and nutria. Quaglio (1955) confined his study to the histopathology of cirrhosis of the liver. Koch (1956) confined his report to the anatomy of the lungs of the nutria. Rosati (1956) reported on the anatomy of the digestive system, specifically the post-diaphragmatic tract. Slebodzinski (1957) described the genital system. Potter and Billello (1960) described the external features.

It is the purpose of this study to present the gross and microscopic anatomy of the digestive and urinary systems and histology of the reproductive system of the nutria, designated as _Myocastor_ _coypus_ _bonariensis_ (Geoffroy), and known by the fur industry as the coypu or nutria. This study is not a comparative study, but references will be made to other mammals as an aid to understanding.

II. MATERIALS AND METHODS

The nutrias used in this study were obtained from the Waubun Laboratories, Schriever, Louisiana.

Eight specimens (Myocastor coypus bonariensis); four males and four females were live-trapped in the marshes of Louisiana. These animals were embalmed by Dr. Horace Whitten of Waubun Laboratories.

Fifteen figures of dissections and forty photomicrographs of histological sections substantiate the various descriptions. The figures are copies of india ink tracings of original drawings made at the time of dissection. No attempt was made to conform to exact enlargement, but the various organs of any figure are drawn proportionately.

The various structures illustrated in the figures are labelled with Artype and a key accompanies each.

A dissection microscope was employed as a means of checking dissected structures, especially the various ducts of glands. The microscope was equipped with 10X ocular lenses, and both IX and 3X objective lenses.

A graphic view, 4 x 5 inch camera was used for photography of the gross specimens.

A survey of the digestive, reproductive and urinary organs were made in order to verify gross interpretations.

Histological sections were made of the digestive, reproductive and urinary organs. Sections of the aforementioned organs were fixed in formalin or Zenker's fluid, and dehydrated by a Technicon.* The tissues were embedded in Tissuemat, and sectioned at 3 microns.

The following staining methods were used: Haematoxylin (Ehrlich) eosin; Van Gieson's picric-acid fuchsin for connective tissue; Masson's (Gomori's modification) stain for connective tissue; periodic-acid Schiff reaction, MacManus (1948); Biebrich Scarlet with picro anilin blue and Wilder's reticulum stain.

---

*The Technicon Company, Chauncey, New York.

III. THE ORAL CAVITY

The oral cavity constitutes the cephalic portion of the digestive system. The digestive tract of the nutria commences with an inlet, the mouth, and terminates with an outlet, the anus. It is modified grossly into the oral cavity, pharynx, esophagus, stomach, intestines, and anus. The major digestive glands include the liver, pancreas and salivary glands.

A. The Lips and Cheeks

1. The Lips

The lips (labia oris) are defined as fleshy folds forming the margin of the mouth (Barnhart, 1950). The labia oris of the nutria consisted of two musculo-membranous folds (fig. 1) capable of completely covering the incisors and the cephalic end of the oral cavity. The angles of the lips when retracted extended caudally to the posterior margin of the upper and lower incisors i.e., under these conditions the angles of the lips were located in the region of a broad diastema between the incisors and molars.

The lateral surfaces of the lower lip encircled the incisors and met posteriorly in a distinct narrow groove which partially supported the ventral aspect of the tongue. On the buccal surface of the lower lip, on both sides of the lower incisor teeth were two raised folds or swellings which measured approximately 10 x 30 millimeters. Figulla (cited by Koch, 1953) referred to these structures as "lip plates" or "lip swellings". When the mouth was closed the lip plates were adjacent to each other, and as a consequence the vestibule was almost completely separated from the oral cavity. Broman found that the plates were controlled by a diagonal muscle (Weber, 1927).

Small median ventral folds of mucous membrane extended from the lower lip to the mucosa of the mandible to form the _fraenula labii inferioris_. The latter was thin, triangular in shape and the distance from its point of attachment (apex) between the lower incisors to the lips was approximately ten millimeters.

The borders of the upper lip were adjacent to and covered the gingivae and incisors. The edges of the lips which remained free (inflexum pellitum, Weber, 1927) had a tendency to meet behind the incisors to form a median raphe. The width of the upper lip was greater than that of the lower lips, and the cheek pouches of the former were prominent. Those portions of the upper lips posterior to the incisors were covered with hairy skin similar to the description given by Potter, Hermann and Rabb (1956) for the guinea pig. The groove formed by the fusion of the right and left upper lips was smaller than the corresponding groove formed by the fusion of the lower lips.

2. The Cheeks

Dorland (1947) defined the cheeks as the fleshy portions of the sides of the face. Anatomical works are somewhat vague as to the limitations of the cheek (Gray, 1956, Buchanan, 1953, and Cunningham, 1951, for the human; Miller, 1952, for the dog). Reighard and Jennings (1935) described the cheeks of the cat as extending from the lips caudad to the ramus of the mandible. Sisson and Grossman (1954) stated that the cheeks of the domestic animals formed the sides of the mouth, and were continous in front with the lips, and attached to the alveolar borders of the bones of the jaws.

Wolfer (1955) described the cheeks of the chinchilla as including all structures from the integument to the mucous membrane of that portion of the face which bounded the mouth laterally from the lip to the fauces and to the pharyngeal entrance.

Observations made during this course of study demonstrated that the mouth of the nutria was similar to that described for chinchilla by Wolfer (ibid.). The cheeks were attached to the alveolar borders of the upper and lower jaws, and included all structures which formed the sides of the mouth and extended forward to join the lips.

The mucous membrane of the cheeks exhibited roughened longitudinal folds along the anterior and dorsal surfaces. On the other hand, longitudinal folds along the lateral surface of the cheeks, although continous with those in a more dorsal position, were coarse in texture in contrast to the relatively smooth mucous membrane of other mammalian species.

The outer surface of the cheek was covered with fur similar to that found in other body regions. In addition, prominent mystacial vibrissae were present at the labial ends of the cheeks (fig. 2).

Wilcox (1950) found that the vibrissae of chinchilla were long, heavy, sensory hairs completely separated from one another. Wolfer (loc. cit.) found that in some specimens of chinchilla the mystacial vibrissae were separated from one another, but in other specimens the vibrissae were paired in follicles and in no specimen did he find a complete absence of paired vibrissae. Observations made in this study on nutria are in general agreement with those cited by Wolfer for the chinchilla.

Other observations made in this study demonstrated that the vibrissae of males and females were essentially the same. Two groups of vibrissae were identified in the nutria. One was located along the margin of the upper lip and extended posteriorly for a distance of about 100 millimeters. On the other hand the other group was located posterior to the angle of the lips along the lateral surface of the cheeks. Although single vibrissae predominated some follicles did exhibit paired vibrissae. When two were found in the same follicle there was considerable variation in length and thickness of the individual vibrissae. Maximum length of vibrissae was about 100 millimeters whereas in the chinchilla it measured approximately 144 millimeters (Wolfer, *op. cit.*).

The color of vibrissae of nutria was subject to considerable variation. Usually the shorter member of a pair was white, while the longer one varied from white to brown.

B. The Vestibule

The *vestibule* was divided into the *incisal vestibule* and *molar vestibule*.

1. *Incisal vestibule*. The boundaries of the incisal portion of the vestibule were the incisors, the gingivae and the lips. The incisal vestibule was separated from the molar

vestibule by the fold of the upper lip which formed an unbroken ring around the incisors. Wolfer (op. cit.) indicated that the circumscribed vestibule was continuous with the oral cavity post-incisal recess and oral cavity proper when the lobes of the inflexum pellitum separated to admit the lingual apex, since the lower lip did not fuse caudal to the incisors. In the nutria this did not hold true inasmuch as the lower lip fused around the incisors and met posteriorly in a distinct narrow groove which partially supported the ventral aspect of the tongue.

2. Molar vestibule. The very narrow space located between the cheeks and the molars was the molar vestibule. It was continuous with the oral cavity. The teeth had no interspace; thus there was no inter-molar communication with the oral cavity.

C. The Postincisal Recess

The space immediately caudal to the incisors was the postincisal recess. It was lined with modified integument, rather than mucosa, because of the labial infolding and of the buccal bristle pad caudal to the commissurae labis oris. The recess opened into the oral cavity proper at the level of the first molar teeth. Rostrally the recess was bounded by the labia and the incisors, dorsally by the reflexes, incisive papillae, hard palate and joined the oral cavity proper. The recess was lined laterally by the buccal bristle pad ventrally by the inflexes.

Beddard (1909) found that the oral cavity of rodents was divided into two chambers by a hairy ingrowth behind the incisors. Wolfer (op. cit.) referred to the first chamber of the chinchilla as the postincisal recess and the second, and much larger chamber, as the oral cavity proper. In this investigation I shall use the terminology of the latter investigator.

D. The Oral Cavity Proper

The mouth cavity extended from the lips to the pharynx and became wider caudally. It was very small and was always closed anteriorly by the protrusion of the anterior tip of the tongue. The inlet into the mouth cavity was the oral fissure and the outlet was the isthmus of the fauces. The isthmus of the pharynx was short and narrow. The mucous membrane lining the mouth was continuous on the buccal surface of the lips and caudally with the mucosa lining the pharynx.

The chief structures of the oral cavity proper consisted of the palate, the floor, and in addition the molar teeth and tongue.

1. *The Palate* (figs. 3 and 4)

In the case of all mammals the nasal cavity is separated from the mouth cavity by the palate. Wolfer (*op. cit.*) divided the palate of the chinchilla into three well defined regions. For example, the rostral region occupied the area of the superior diastema and contained the principal structure termed incisive papilla; the middle region occupying the area between the first and second molars and caudal or posterior portion of the palate which is the soft palate. He designated the rostral and middle regions of the palate as the hard palate.

Freund (cited by Koch, 1953) separated the hard palate into an anterior *regio incisiva*, a middle *regio rugarum* and a caudal *regio plana*. The latter continues without a margin into *Velum palatinum* (soft palate). According to Koch (1953) the usual division of the palate into three parts as described by Freund (cited by Koch, 1953) did not apply to the nutria. The *ossa incisiva* of this species was not considered as a part of the oral cavity, and furthermore the rugae *palati* were absent.

In this investigation the palate was divided into the hard and soft palate (fig. 4). These findings were in agreement with Koch (*op. cit.*). The hard palate of the nutria was continuous with the soft palate behind and was bounded in front and on the side by the alveolar arches. Its basis was formed by processes of the premaxilla, maxilla and palatine bones. There was a large incisive papilla behind the incisors approximately twenty millimeters in length. Between the incisive papillae and anterior to the molars were two pairs of soft folds covered by mucous membrane. The median raphe was indistinct and the ridges were concentrated in the area between the molars. Wolfer (op. cit.) indicated that the middle region of the chinchilla palate was characterized by four or five chevron-like palatal ridges or rugae. Palatine ridges were missing in the nutria.

The hard palate in the nutria measured approximately thirty-five millimeters in length. Rostrally it was five millimeters wide and flared caudally to reach a width of fifteen millimeters at the posterior end. Koch (1953) indicated that the width of the hard palate increased from about one-half centimeter at the level of the third molar to reach a width of one and one-half centimeters and a length of three centimeters at the level of the fourth molar.

The anterior margin of the soft palate was located in the triangular area between the hard palate and the last pair of molars. The length of the palate was approximately twenty millimeters, and its posterior border was adjacent to the distal end of the epiglottis. The soft palate which was continuous with the hard palate separated the nasopharyngeal region from the oral cavity. The surface of the oral cavity was covered by mucous membrane.

The anterior pillar of the soft palate was a short, thick fold which passed to the lateral and posterior border of the tongue. The latter border was free, concave and thin and was in contact with the epiglottis. The same relationship exists in man and the horse (Sisson and Grossman, 1954). Koch (*op. cit.*) referred to the concave free margin as the *Arcus palatinus*.

In Equidae, Carnivora and Rodentia the *Arcus palatinus* extends from the margin of the tongue to the epiglottis. This arrangement indicates that regurgitation is through the nasal cavity if it does occur in this species. Under normal conditions mouth breathing does not take place in this species (Koch, 1953).

The mucous membrane covering the posterior border of the soft palate extends along the inferior and lateral wall of the pharynx and terminates into an oblique fold ("posterior pillars," Sisson and Grossman, 1954) near the opening of the esophagus. The space between the anterior and posterior pillars was occupied by _faucial tonsils_ which were reddish elongated structures approximately 15 x 5 millimeters. According to Griffith and Farris (1949) tonsils are misssing in rats. Barge (cited by Bolk _et_. _al_. 1937) who studied lymphoid tissue in rodents stated that palatine tonsils in all rodents are poorly developed or entirely missing. Koch (_op_. _cit_.) maintained that palatine tonsils did not exist in the nutria. No palatine tonsils were observed in this investigation.

Moser (1868) indicated that the form of the soft palate was subject to considerable variation. Ellenberger and Baum (1943) and Koch (_op_. _cit_.) gave the following measurements for lengths of the soft palate in various species of mammals:

Horse	(_Equus caballus_)	11.0 - 12.5 cm
Cow	(_Bos taurus_)	8.5 - 12.2 cm
Pig	(_Sus scrofa domesticus_)	5.8 - 6.4 cm
Sheep	(_Ovis aries_)	6.0 cm
Goat	(_Capra hircus_)	4.8 cm
Dog	(_Canis familiaris_)	4.0 - 6.0 cm
Cat	(_Felis domestica_)	1.8 - 2.6 cm
Guinea pig	(_Cavia coboya_)	1.0 cm
Nutria	(_Myocastor_)	3.0 - 3.5 cm

2. The floor of the mouth consisted of three general regions. The anterior postincisal area was lined by oral mucosa and inflexes of the lips. It presented a more or less V-shaped depression for the lingual apex. Between the lower molars was the middle division of the oral floor. The oral mucosa

lining this area was reflected from the molar gingivae and the under surface of the body of the tongue. The caudal portion of the floor of the mouth differed from the middle portion in that the body of the tongue gradually receded beneath the oral mucosa. Caudal to this level the root of the tongue and surrounding membrane formed the terminal portion of the floor.

The mucosa of the mouth along with the integument that folded in from an outer surface, and connective tissue covered the mylohyoid, geniohyoid, digastric muscles, blood vessels, cranial nerve fibers, salivary glands, other than the parotid.

3. <u>The Teeth</u> (figs. 5 and 6)

The teeth of the nutria were twenty in number. According to the procedure of Diamond (1952) the mature dental formula =

$$2\left(I\ \frac{1}{1}\ C\ \frac{0}{0}\ P\ \frac{0}{0}\ M\ \frac{4}{4}\right) = 20.$$

It is evident from the formula that there were two upper and two lower incisors which were arranged in a simplicidentata manner.

The incisors were of the gliriform, gnawing, or rodent type, i.e., they did not exhibit true roots. In mammals, the shapes of the molar and premolar teeth vary according to their feeding habits and type of food eaten. The molars of nutria are capable of continuous eruption since their pulp chambers remain open in mature individuals. Their crowns were lophodont in form similar to those described by Wolfer (op. cit.) for the chinchilla. According to Burt (1946) this type of crown is common to herbivorous rodents. Beddard (1909) maintained that the teeth were monophydont and that this condition was commonly found in rodents.

The incisor teeth (fig. 5) were comparatively large and the roots were embedded in the alveolar border of the premaxillaries and the mental portion of the mandible. The root constituted two-thirds of the whole length of the incisor tooth and curved downwards and backwards in the alveolar cavity. They were long, strong, curved teeth, with sharp chisel-like edges. Wolfer (1955) indicated that the length of the greater curvature of the chinchilla incisor tooth was approximately twenty millimeters; while in the nutria the length was approximately sixty millimeters. Each incisor tooth measured about sixty millimeters; the crown twenty millimeters; and the root approximately forty millimeters.

The dental surface was completed on the buccal side and was triangular in shape with the apex towards the gum line. The upper and lower incisors were about equal in size and met at the anterior border of the dental surface.

The labial surfaces were pigmented. The color ranged from an orange in young animals to a brownish-orange in some adult animals. Koch (1953) described the pigmentation of the chinchilla as a bright yellow-orange. Schour (1953) indicated that this pigment was contained in the outer portion of the dentine in the rat incisors. Watson and Avery (1954) stated that the dentine of rodent incisors generally contained two layers, the outer constituting about one-fifth the thickness of the dentine. No comment was made concerning the nature of the pigment. Griffith and Farris (1949) indicated that the pigmentation in the incisors of rats was a yellow-orange which deepened with age, and the pigmentation was first seen in the rat at four weeks of age. On the contrary, the pigmentation was seen in the nutria at birth.

The present investigation revealed that the pigmentation did not extend below the alveolar ridges more than a millimeter. Several attempts to remove the pigment from the incisors indicated that the pigment was not just a surface film, but appeared to be a constituent of the enamel.

The molar teeth formed the sides of the dental arch, and the first two molars were raised above the alveolar ridges while the surfaces of the teeth showed a zig-zag arrangement. The color was a darkish gray with the exception of the roots which were white. The root measured approximately eight millimeters while the crowns measured three millimeters. According to Koch (op. cit.) the first molar had two roots and all others had three. In contrast to the latter, Naglier (cited by Koch, 1953) indicated that the fourth molar had four roots, and the medial root was longer and wider.

The molars examined in this investigation revealed that all the molars were essentially alike; the first molar was smaller and the last larger. There was no neck and the molars had a cylindrical form. These findings were in agreement with Koch (ibid.). Wolfer (1955) did not find any reports on the rate of eruption of the chinchilla molars, but according to Walther (1940) the first two molars of the nutria were erupted at the time of birth. The third appeared in the third month and the fourth did not appear before the fifth month. According to Griffith and Farris (op. cit.) the first molar of the rat (which is the largest of the three) erupted on the 19th day, the second on the 22nd day, and the third on the 35th day respectively.

All observations made during the course of this study suggested that the teeth were specialized for a herbivorous diet.

4. The Tongue

The tongue was a highly muscular organ situated between the rami of the mandible and lying on the floor of the mouth. In embalmed specimens its length was found to range from sixty-two millimeters to sixty-five millimeters. From the rostral tip to the caudal end the width varied considerably, but the overall width increased from the apex to the root, giving the tongue an "S" shaped appearance. The narrowest portion was about five millimeters and the widest about nineteen millimeters. Wolfer (op. cit.) indicated that the tongue of the chinchilla had a general wedge-like appearance, and its length was found to range from thirty to thirty-five millimeters.

The dorsal portion presented several distinctive regions, namely, the apex, the intermolar constriction, the intermolar eminence, and the radix or root.

When the mouth was closed, the tongue filled the entire oral cavity, with the apex protruding outside. The apex was free, triangular, and wedged-shaped and measured about ten millimeters. It rested on the diastemal region of the floor of the mouth on the two folds, or lip swellings, of the lower lip. Except for the indistinct and very loose frenulae the apex of the tongue was entirely free from attachments.

The second portion, or intermolar constriction, was located between the first lower molars. This portion of the tongue was bilaterally compressed approximately nine millimeters due to the closeness of the right and left molars. The constriction imparted a curve at the front half of the tongue. Wolfer (op. cit.) indicated that this portion of the tongue in the chinchilla was bilaterally compressed about three millimeters.

The succeeding and more posterior portion of the tongue began at the level of the second lower molar and widens caudally. It exhibited a swelling or noticeable elevation on the dorsal surface. This region was designated as the intermolar eminence due to a noticeable elevation. This was the thickest region of the tongue.

The dorsum, or upper surface of the tongue, was covered by numerous papillae. Wolfer (op. cit.) indicated ten distinguishable papillae modifications. In the nutria three distinct types were recognizable, namely: filiform, circumvallate and foliate. The bulk of the tongue was covered by compact filiform papilla. The circumvallate, which were two in number, were found on the posterior part of the dorsum, one on each side of the median plane, about five millimeters apart. The foliate papillae were situated along the posterolateral border of the tongue. They were somewhat hidden from the dorsal aspect by the lateral margin of the tongue.

The caudal end of the dorsum of the tongue widens and was confluent with the floor of the fauces. The level of this region was depressed below that of the preceding so that the back of the tongue presented a rounded declining slope. This region was designated as the radix or root of the tongue.

The tongue was held in place by the sling-action of the mylohyoid muscle. The intrinsic musculature consisted of fibers which ran longitudinally, vertically, and transversely, blending with the extrinsic muscles. In the nutria the muscles of the tongue were described as styloglossus, a long, thin muscle which extended along the lateral part of the tongue; hyoglossus, a wide, flat muscle which was located in the lateral part of the root and body of the tongue; and the genioglossus, a fan-shaped muscle which extended parallel to the median plane of the tongue.

The lingualis, pars verticalis; lingualis, pars longitudinalis superior; lingualis and pars longitudinalis superior described in the chinchilla by Wolfer (op. cit.) was not demonstrated in the nutria.

E. The Salivary Glands

The salivary glands described in this investigation are located in the same general areas in which similar glands are found in other mammals.

1. Parotid gland. The largest of the serous glands was the parotid glands which were situated ventral and caudal with relation to the pinnae of the ear and behind the ramus of the mandible. The parotid glands were bounded externally by the integument, the superficial cervical portion of the platysma muscle, and by the parotido-auricularis muscles. The latter was a ribbon-like muscle which adhered to the surface of the parotid gland.

The gland was somewhat rectangular, with the long axis being in a craniocaudal direction. Measurements showed that it was approximately forty millimeters long, and at various places along the axis, the width was between ten to fifteen millimeters or more from dorsal to ventral. Wolfer (1955) indicated that the parotid gland in the chinchilla was approximately thirty millimeters long.

The excretory duct of the parotid gland follows a course very similar to that indicated for the mink (Mustella vision) by Kainer (1954), the fox squirrel (Sciurus niger) by Jenkins (1956) and the chinchilla (Chinchilla langera) by Wolfer (*op. cit.*). The duct arose along the ventral border of the gland, and received various sub-branches (3-4) as it curved upward and rostrad beyond the cranial border of the gland; and then it passed craniad in the fascia of the masseter muscle to open in the vestibule of the second and third upper molars. Koch (*op. cit.*) found that the excretory duct opened at the level of the first upper molar.

According to Krause (cited by Koch, 1953) the parotid gland was smaller than the mandibularis (submaxillary) in *Cavia* (guinea pig). Koch (*op. cit.*) indicated that this gland in the nutria was larger than the mandibularis (submaxillary) which was in agreement with my findings.

2. *Submaxillary glands*. The paired submaxillary glands (submandibular, of Buchanan, 1953) were lenticuloid to ovoid organs located below the floor of the mouth, and lateral to the rostral end of the larynx. They filled out the cavity between the jugulomandibularis muscle and larynx respectively. The submaxillary glands measured approximately thirty millimeters in length and fifteen millimeters in width. Wolfer (*op. cit.*) found the submaxillary gland of the chinchilla to measure approximately thirteen millimeters in length.

The lobules of the gland were much more closely bound together than were the parotid lobules, and the ventral surface of the gland were smooth and convex. The glands were covered superficially by the integument, and by the superficial portion of the platysma muscle.

The duct of the submaxillary gland arose in the substance of the gland by an irregular main canal with a variable number of tiny side branches. It passed cranially close to the mandible, and opened into the mouth near the base of the frenulum on the floor of the oral cavity.

Garrod (cited by Fahrenholz, 1937) indicated that the submaxillary gland in the mutria and several other members of the order Rodentia was larger than the parotid gland and extended into the thoracic region. According to Fahrenholz (ibid.) and Koch (op. cit.) the submaxillary was smaller than the parotid which was in agreement with my findings.

3. Sublingual glands. The submaxillary duct received the ducts of two and sometimes three diminutive lobulated salivary glands. Greene (1935) stated that these glands have been designated as major sublingual glands in rats even though they were more closely associated with the submaxillary gland and its duct. In the rat the most rostral salivary gland beneath the tongue was designated by Greene (ibid.) as the minor sublingual gland. In the human there was only one sublingual gland; it was located near the

mandibular symphysis in essentially the same location as the minor sublingual gland of the rat (Greene, ibid.). According to Wolfer (1955) the sublingual gland in the chinchilla near the mandibular symphysis was much larger than the sublingual near the submaxillary gland. There is a trend at present to designate the gland now known as the submaxillary gland as the submandibular gland (Buchanan, 1953) which adds to the confusion of terminology. Thus if one wishes to refer to the sublingual glands in relationship to the submaxillary gland it must be known if one means the submandibular gland of more modern usage.

The present author employs the names sublingual major and sublingual minor. The sublingual glands were elongated and conical in shape and measured approximately 15 millimeters x 15 millimeters and lay medial and close to the submaxillaries beneath the mucous membrane of the mouth. The one lying nearest the submaxillary was termed sublingual major, and the next sublingual gland, rostrad, the sublingual minor. The glands were located between the body of the tongue and the mandible. Their ducts left the ventral surface of the glands and passed along with the submaxillary duct and opened into the mouth along with the submaxillary ducts.

There were no buccal parotid glands in the nutria described as molar glands in the chinchilla by Wolfer (op. cit.). These findings were in agreement with Koch (op. cit.).

IV. THE PHARYNX

The pharynx had the usual funnel-shaped form. It was a relatively long and arching musculo-membranous tube which connected the nasal cavity and the larynx. The laryngeal end of the pharynx served as a cross-channel between the oral cavity and the esophagus during the act of deglutition.

Complex folds which bounded the oral-pharyngeal aperture overlapped the crest of the epiglottis and thus effectively closed the passageway between the fauces and the pharynx.

The entire pharynx was practically nasopharynx. It extended from the nasal cavity along the hard palate and the entire length of the soft palate to the faucial aperture of the ventral wall of the pharynx. It received the posterior nares and the ostia of the eustachian tube.

The very limited laryngeal end of the pharynx was designated as the oropharynx. It received the openings from the mouth, the larynx, and from the esophagus; it was delimited from the long nasopharynx by the faucial-pharyngeal folds, and by the esophageal-pharyngeal folds. There was no laryngeal recess of the pharynx, and hence no laryngopharynx since the esophageal orificeoccurred at the level of the crest of the arytenoid cartilages of the larynx. The esophagus began abruptly from the caudal side of the oral pharynx.

The cavity of the pharynx was approximately twenty-three millimeters in length. Wolfer (1955) indicated that the cavity of the pharynx of the chinchilla was approximately thirty-five millimeters in length.

V. THE ESOPHAGUS

The esophagus (figs. 3, 8 and 12) of the nutria resembled that of the dog, chinchilla, cat, and rat, both in general structure and in its relationship to other organs. It was a thin-walled muscular tube about 160 millimeters in length. Wolfer (ibid.) in his study of the chinchilla indicated that the esophagus of the chinchilla was about seventy-five millimeters.

As in the case of the guinea pig and beaver its musculature was transversely striated in the downward direction towards the cardia (Koch, 1953).

The cervical portion of the esophagus was approximately thirty millimeters in length, and extended from the caudal end of the pharynx to the level of the first rib. It was located dorsal to the trachea, and shifted slightly to the left in respect to the latter. The esophagus extended caudad along the ventral surface of the left _M_. _longus_ _colli_, pars cervicalis or obliquus superior.

The thoracic portion of the esophagus was about 100 millimeters in length. It continued to shift to the left as it coursed through the chest and was crossed ventrally by the left bronchus.

The esophageal hiatus (ventral) was located to the left of the midline and to the left of the aortic hiatus from which it was separated by a diaphragmatic crus or pillar. The esophagus was attached at the esophagus hiatus by connective tissue.

The abdominal portion of the esophagus was about thirty millimeters in length, and the entire portion was surrounded ventrad, mediad, and laterad by the left lobe of the liver. The entrance of the esophagus into the stomach was through a circular fold which was directed posteriorly against the inside with the distal surface in contact with the lining of the stomach wall.

VI. THE ABDOMINAL CAVITY

The region of the trunk which was caudal to the diaphragm was designated as the abdominal cavity. In contrast to the thorax which was laterally compressed, the abdomen was rounded, flattened somewhat dorso-ventrally, and had a greater volume.

The most extensive portion of the digestive tract was within the abdominal cavity, namely: All structures from the abdominal portion of the esophagus to the rectum, as well as the liver, gall bladder and pancreas.

A. The Non-Digestive Organs of the Abdominal Cavity

1. The Spleen (fig. 12)

The spleen of the nutria was a brownish-red organ located at the left side of the abdominal cavity in close relation to the stomach and pancreas.

The spleen had two surfaces, two borders, and two extremities. The lateral surface was flat in adaptation to the diaphragm with which it was in contact with a small part lying against the abdominal wall in the area of the last rib. The median surface presented a broad, thickened, longitudinal ridge giving the organ a pyramidal appearance in cross section. It was attached from the ridge of the medial surface to the greater curvature of the stomach by the gastrosplenic part of the omentum. Martin (1835) indicated that the shape of the spleen was prismatic and similar to the muskrat.

The anterior border was smooth and was related (in apposition) to the diaphragm and the greater curvature of the stomach. On the posterior border it was smooth and presented a notch at its sternal end.

The dorsal (vertebral) extremity was rounded and smooth, fitting into the interval between the left crus of the diaphragm sac of the stomach and the left kidney. It was touched also by the left extremity of the pancreas. The apex was notched and varied in position. It was generally found opposite the costal arch.

The spleen was supported by folds of the omentum. The portion of the mesogaster which passes on to the greater curvature of the stomach is called the greater omentum. That portion of the omentum extending from the stomach to the spleen is the gastrosplenic ligament.

The spleen was approximately fifty to seventy millimeters in length and eighteen millimeters in width. In contrast, Wolfer (*op. cit.*) indicated that the spleen of the chinchilla was about eighteen millimeters long and six millimeters wide. According to Koch (*op. cit.*) its weight was dependent upon the size of the animal and varied from about 2.0 to 6.8 grams.

2. The Urinary Organs

The urinary organs of the nutria (fig. 7) consisted of paried kidneys and ureters, a single urinary bladder and the urethra.

The kidneys were compact, smooth, lenticular, and encased in fatty fascia. They were paired and were situated retroperitoneally on the posterior abdominal wall, one on each side of the vertebral column. Koch (*op. cit.*) indicated that the kidneys of the nutria were almost at the same elevation. The present investigation revealed that the left kidney was about forty millimeters from the diaphragm while the right kidney was about twenty-five millimeters; thus the left kidney was approximately fifteen millimeters lower than the right kidney. The right kidney was located from vertebral levels two to four, or five, and the left from vertebral levels three to five. The kidney measured approximately forty millimeters in length, twenty-five millimeters in breadth, ten millimeters in thickness, and weighed approximately twenty-four grams.

The suprarenal gland was adjacent to and partly surrounded the anterior pole of the kidney. It was about one-fifth the size of the kidney. This was in marked contrast to the size of the same gland in the rabbit, rat and cat, where it was much smaller in relation to the size of the kidney.

The lateral border of the kidney was convex. The medial (hilus) surface was concave and received the renal blood vessels and ureter. The ureter originated at the well formed pelvis of the kidney and traveled in the same direction as in other domestic animals.

The urinary bladder in both sexes was morphologically similar. It was small and according to Koch (_op_. _cit_.) corresponded in its position to that of the carnivores with its vertex (top) projecting out over the pubic bone into the abdominal cavity. On the inner surface of the bladder projecting from the mouth of the ureters were two _uretericae_ which extended into the urethra for a short distance and formed a _vesicae_ which joined the _crista_ _urethralis_ of the urethra.

The male urethra exhibited at the end of the *crista urethralis*, the *colliculus seminalis* with the two ejaculatory openings situated in grooves. These grooves, which were visible in the form of two small proturberances on the ventral surface of the urethra, led into a short hollow cavity. According to Koch (*op. cit.*) and Gerhardt (cited by Bolk *et al.* 1937) these findings were similar in the guinea pig and beaver, however Tullberg (cited by Koch, 1953) did not agree in the case of the beaver.

The terminal portion of the male urethra passed through the penis and opened on the ventral surface at the base of the terminal papillae. In the female the urethra did not open into the vagina but joined the urinary aperture near the vaginal orifice. Gerhardt (cited by Bolk *et al.* 1937) indicated that there was a definite urethral opening in addition to the vagina in all female hystricomorphs.

B. The Digestive Organs of the Abdominal Cavity

The abdominal digestive organs include the minor (abdominal) portion of the esophagus, the stomach, small intestine, cecum and other portions of the large intestine, the pancreas, liver and biliary structures.

1. The Stomach (figs. 8 and 9)

Grossly the stomach exhibited indistinct cardiac, fundic, body, and pyloric portions. The pyloric extremity was smaller and was continuous with the duodenum, and the pyloric sphincter, which was relatively prominent, marked the posterior limit of the stomach.

The stomach was lenticulated and the anterior end was curved upon itself to form a prominent arch which was directed caudally. Near the center of the greater omentum there was a deep indentation which was also found in the hamster (Koch, 1953). The stomach was located in the left half of the intrathoracic part of the abdominal cavity. Cranially on the right side it touched the liver and pancreas; on the left side it touched the liver, diaphragm and spleen.

The dorsal surface was in contact with the transverse colon and extended over the ventral surface, the combined double loop of the cecum and ileum.

The stomach was connected with the surrounding viscera through peritoneal folds. The gastrosplenic ligament connected the cardia portion of the greater curvature with the left crus of the diaphragm. The lesser omentum connected the lesser curvature with the liver. The gastrosplenic ligament passed from the left part of the greater curvature to the hilus of the spleen and was continuous with the greater omentum.

According to Rosati (1956) the stomach of the nutria was more voluminous than the rabbit even though the same lenticulated form was exhibited in both animals. However in nutria it differed in that the anterior end was curved on itself (fig. 9). The volume of the stomach was about 600 cubic centimeters in contrast to fifty cubic centimeters for the chinchilla as described by Wolfer (op. cit.). The stomach was approximately 115 to 120 millimeters in diameter at its widest point.

The mucosa of the stomach was usually light red in color and at the esophageal end there were prominent folds, whereas the fundus exhibited a smooth surface almost to the pyloric sphincter. The latter was folded and due to the arrangement of the underlying muscles the orifice leading into the duodenum had a diameter of about thirty millimeters.

2. The Intestines and Cecum (figs. 10, 11 and 12)

The intestines were differentiated into a small and a large intestine. The small intestine of the nutria was about 249 centimeters in length. Wolfer (1955) indicated that the large intestine of the chinchilla had the greatest length, in the nutria the length of the small intestine was roximately three times greater than that of the large estine. According to Wolfer (ibid.) the small intestine the chinchilla measured approximately 100 centimeters length, and the large intestine about 150 centimeters ng or roughly one and one-half times as long as the small testine. Rosati (op. cit.) in his description found the all intestine to be about 330 to 340 centimeters long. the other hand Walther (1940) indicated that the small testine measured 286 centimeters.

The small intestine exhibited an abundance of lymphatic dules which are uniform in distribution from pylorus to e cecum. The individual nodules formed prominent bulges the exterior surface of the intestine. In this respect ey were similar to the nodules described by Titkemeyer d Calhoun (1955) for the dog.

The cecum of the nutria was relatively long and had a reater width than other regions of the intestine. It was acculated and continuous with the large colon which was ery similar in appearance except that its diameter was less nd it was not spiralled. The small colon was distinguishble due to the bead-like swellings of the wall as a result f fecal contents and there were no sacculations.

a. <u>The small intestine</u> (figs. 10, 11 and 12)

The entire length of the small intestine was illustrated in figure 11. Most of the small intestine was located in several complex loops dorsal to the large intestine, and at the right of the midline.

The small intestine was not divisible into distinct regions except on an arbitrary basis. There was no clear-cut line of demarcation between the duodenum and jejenum. Likewise there was a gradual transition between jejenum to ileum.

The duodenum was about twenty-five to thirty centimeters long and formed a C-shaped loop with the convexity directed to the right. The first part of the duodenum formed an S-shaped curve. The first curve of the S was in contact with the right and diaphragmatic lobes of the liver. The pancreas was attached to the concavity of the second curve approximately sixty millimeters from the pylorus. The duodenum was of a greater caliber than either the second or third portions.

The duodenum curved dextrad and caudad along the abdominal wall. At the level of the cecum it curved craniad and joined the second and longer portion which was the jejenum. The latter was highly coiled and longer than the terminal half (the ileum) which ended abruptly on the cranial surface of the cecum.

The mesenteric portion of the small intestine was connected with the dorsal abdominal wall by the great mesentery which was a wide fan-shaped fold of peritoneum (fig. 13) through which vessels and nerves reached the bowel.

The large intestine (figs. 10, 11 and 12)

The large intestine extended from the terminal part of the ileum to the anus. It was approximately 133 centimeters in length, and its width was about one and one-half times that of the small intestine. It was sacculated and divisible into cecum, colon, and rectum.

1'. *The cecum* (figs. 10, 11 and 12)

The cecum was a large sacculated sac interposed between the small intestine and large intestine. It extended transversely across the abdominal cavity ventral to the distal portion of the abdominal aorta. The cecum was prominent, having an average length of approximately forty-three centimeters. Wolfer (*op. cit.*) indicated that the cecum of the chinchilla measured approximately six and one-half centimeters in length. The cecum was spiralled as in the guinea pig and chinchilla, Martin (1923) and Wolfer (*op. cit.*). According to Rosati (1956) and Koch (1953) the *sacculus rotundus* of the rabbit was not present in the nutria.

Two longitudinal bands of muscles (taeniae) restricted the amount of distension of embalmed cecums. The blind end or apex of the cecum was somewhat less restricted in size and conical in outline, but did not form a discrete appendix. The orifice of the cecum was greatly restricted. The cecum of the nutria did not exhibit an internal surface with the characteristic spiral fold found in the rabbit.

2'. The large colon (figs. 11 and 12)

The large colon proper commenced near the ileocecal junction and was largely confined to the right of the abdominal cavity. Its length was about fifty centimeters. It encircled the ventral surface of the cecum and traveled craniad to the region of the lower right ribs where it formed two U-shaped loops. The first twenty-eight to thirty centimeters of the large colon was sacculated due to two longitudinal bands or taenia coli. Potter *et al*. (1956) indicated that the colon of the guinea pig was greatly sacculated and referred to the sacculations as "haustra." The large colon had a variable diameter from two and one-half to three centimeters in contrast to one and one-half centimeters in the chinchilla (Wolfer, 1955).

The greater portion of the large colon was supported by a mesentery which originated from the outer curvature of the duodenum.

3'. The small colon (figs. 11 and 12)

The small colon commenced as the distal arm of a loop of the large colon and was continued at the pelvic inlet by the rectum. Its length was about thirty centimeters and it was about one and one-half centimeters in diameter. Wolfer (*ibid.*) stated the length of the small colon in chinchilla was approximately seventy to one hundred and fifteen centimeters in length and about five millimeters in diameter. There were no longitudinal bands or sacculations in the small colon which was also true for the chinchilla.

The terminal end of the small colon was the rectum. It was a straight tube approximately eighty millimeters in length and about ten millimeters in diameter. From a morphological point of view it was similar to the rectum of the rabbit with the exception that the distal end was less sacculated (Rosati, *op. cit.*).

The mesentery of the small colon was simple, and arose from along the mid-dorsal line from the superior mesenteric artery caudad to the region of the pelvis.

3. The Pancreas (fig. 12)

The pancreas of the nutria was situated transversely on the dorsal wall of the abdomen with its greater part to the right of the median plane. The pancreas of man forms a rather compact gland, but it was extremely diffuse in the rat (Morrel, 1872, and Greene, 1935).

In nutria the lobules of the pancreas were loosely united. It had a length of about sixty millimeters and width of about ten millimeters. The dorsal surface of the pancreas was partially covered by the peritoneum. On the right side it was adjacent to the ventral surface of the right kidney and the ventral surface of the right caudate lobe of the liver. In the midline it was adjacent to the posterior vena cava. The left surface was in contact with the left suprarenal, left renal artery, left kidney and the visceral surface of the spleen. The pancreatic duct emptied into the duodenum approximately twenty centimeters from the pylorus, whereas in the beaver and rabbit it opened approximately five centimeters from the pylorus (Broman, cited by Weber, 1927).

4. <u>The Liver</u> (figs. 14 and 15)

The number of lobes in the liver among various rodents is controversial. Koch (<u>op</u>. <u>cit</u>.) indicated that the liver of the nutria was divided into five lobes. According to Martin (1835) there were four lobes in the guinea pig and rabbit. Wolfer (<u>op</u>. <u>cit</u>.) described three lobes for the chinchilla. Rosati (1956) indicated that there were three lobes and the present author was in agreement with the latter investigator.

The right lobe was irregularly quadri-lateral in form and was subdivided by a deep fissure into right dorsal (cranial) and caudate lobes. The caudate lobe ended in a pointed caudate process (fig. 14) which encircled the cranial portion of the right kidney. The right lobe measured approximately eighty millimeters in length and fifty millimeters in width in contrast to the caudate lobe which was about forty-five millimeters in length and thirty millimeters in width.

The diaphragmatic or middle lobe was the largest of the three. It was marked by several small fissures. The largest exhibited a prominent apex and formed a recess in which the gall bladder was located. The margin of this fissure was sharp and showed a deep esophageal impression (*impressio oesophagica*) taking up the entire abdominal portion of the esophagus (fig. 14). The middle lobe was approximately one hundred thirty-five millimeters in length and sixty-five millimeters in width.

The left lobe was the smallest of the three lobes and was prismatic in shape with a concave impression its visceral surface for the stomach. It was approximately sixty-five millimeters in length and forty-five millimeters in width.

The liver was very large compared to that of other rodents. It was closely related to the abdominal surface of the diaphragm. The greater part of the liver was located to the right of the median plane. It had a deep red color and weighed approximately 200 to 219 grams.

The diaphragmatic surface was convex and lay partially against the diaphragm and dorsal to the abdominal wall. In the region of the middle lobe the liver was attached to the sternal part of the diaphragm and the abdominal wall by the falciform ligament. The coronary ligament was not observed, and according to Rosati (*op. cit.*) it was absent in the nutria and rabbit.

5. *The Gall Bladder* (fig. 15)

The gall bladder was a pear-shaped sac which was approximately fifty-five millimeters long and was adjacent to the visceral surface of the liver. The neck of the gall bladder was continued by the cystic duct which joined the hepatic duct outside of the portal fissure to form with it the bile duct (*ductus choledochus*). The bile duct was long, measuring about fifty-five millimeters in length and entered the duodenum at its first flexure fifty-five millimeters from the pylorus. The opening of the duct into the duodenum was at the end of a ridge-like fold or papillae and emptied separately from the pancreatic duct.

VII. HISTOLOGY OF THE DIGESTIVE GLANDS AND DIGESTIVE TRACT

1. Salivary Glands (figs. 16, 17 and 18)

The salivary glands may be classified on the basis of their secretions as serous, mucous and mixed glands. This classification is not applicable to all exocrine glands but is particularly used in classifying the salivary glands whose ducts open into the oral cavity and supply it with saliva.

The parotid gland (fig. 16) was encapsulated by a fibroelastic connective tissue which gave off numerous trabeculae which extended into the parenchyma to divide the gland into lobes. The latter was divided into lobules by extensions of connective tissues from the capsule. The main excretory duct opened into the oral cavity in the area of the second and third upper molar teeth. This duct divided into interlobar ducts which in turn divided to form interlobular ducts. Most of the large intralobular ducts were of the striated variety (salivary ducts) and were lined by simple columnar cells in which the nucleus was spherical and centrally located. The basal portion of the cell presented a characteristic striated appearance. The intercalated ducts connected the salivary ducts and were lined by low cuboidal epithelium.

The gland was serous. With hematoxylin-eosin, the cytoplasm of the serous cells and their secretory granules stained red, and the secretions of the mucous cells stained blue. The intralobular ducts which consisted of several orders led outward to join interlobular ducts. Bailey (1958) maintained that the parotid gland of man, dog, cat and rabbit was entirely serous. Krause (cited by Koch, 1953) found that the parotid of the guinea pig consisted of mucous and serous portions.

The submaxillary gland (fig. 17). Bailey (1958) maintained that the submaxillary gland in man and most mammals was a mixed gland, but the proportion of serous and mucous alveoli was not the same in all species. In man, it is preponderantly serous. According to Andrew (1959) the submaxillary is a mixed gland. The latter maintained that in man the serous and mucous alveoli were interspersed within the same lobules, whereas in the rat and cat the gland showed entire lobes of either serous or mucous cells.

Contrary to the widely accepted version that the submaxillary gland is mixed, Koch (1953) revealed that it is serous in the nutria. The findings of the present investigator revealed that it was a mixed gland but predominately serous. Like the parotid glands, the submaxillary glands exhibited a prominent duct system. The salivary ducts were longer and more numerous than in the parotid and the intercalated ducts were short and narrow. The cell's borders were not distinct. The nuclei were spherical and were not confined to any particular location in the cell.

The sublingual gland (fig. 18). The sublingual gland was mixed, however, the vast majority of the acini were of the mucous type. They were capped by a crescent shaped group of serous cells called the demilunes. A large number of the mucous cells exhibited demilunes. Very few serous units were found existing distinctly without mucous cell association. The cell boundaries were discrete. The cytoplasm of the pyramidal cells presented a light bluish-purple appearance when stained with haematoxylin-eosin. The nuclei were generally fusiform in shape and were found along the peripheral border of the cell resting on the thin basement membrane.

The lumen was usually well developed. Numerous polymorphonuclear leucocytes were found in the larger interlobular septa and some were found in the small intralobular septa. Intercalated ducts and striated ducts were less numerous than in man.

2. The Pharynx

The pharynx (fig. 19) was that region of the digestive tract leading from the posterior end of the oral cavity to the esophagus. Prepared sections of tissue revealed that the pharyngeal wall consisted of three layers of tissue, namely, mucosa, muscularis externa and outer fibrous coat.

Mucosa. The lining of the pharynx was stratified squamous epithelium. From a morphological standpoint it was essentially similar to the epithlium lining the pharynx of man. The basal layer of cells which varied between cuboidal and columnar rested on a basement membrane. Intermediate layers of cells were variable in shape, whereas the surface layer of cells consisted of flattened squamous cells. Adjacent to the basement membrane was the lamina propria mucosae. On the basis of staining reactions obtained in this study it consisted of elastic and collagenous fibers. The elastic fibers were arranged in a stringy mass which coursed mainly in a longitudinal direction. Elastic fibers extended from the lamina propria between skeletal muscle bundles and united the lamina propria to the muscularis.

Muscularis externa. The muscle of the pharynx consisted of skeletal muscle fibers which were longitudinally and circularly arranged (fig. 19). The muscle fibers were not arranged to form definite layers but the majority were circularly arranged.

Fibrosa. The fibrosa was a tough fibrous layer containing elastic fiber nets and blood vessels that connected the pharynx to adjacent structures.

3. The Tongue

The mucous membrane of the tongue contained a very thick layer of stratified squamous epithlium which was highly keratinized. The anterior dorsal and anterolateral portions of the tongue presented numerous papillae. The filiform papillae were most numerous and were distributed over the dorsal surface of the anterior two thirds of the tongue. The foliate papillae were situated along the posterolateral border of the tongue and the two circumvallate papillae were located on the dorsum (one on each side near the lateral margin). No taste buds were observed in this investigation and according to Koch (1953) taste buds were absent in the nutria.

In case of the filiform (fig. 20) papillae the mucosa formed the horny cap which covered the outer periphery. The epithelial cap covering the circumvallate and foliate papillae was much thinner than that of the filiform papillae.

The <u>lamina propria</u> was composed largely of loose areolar connective tissue. In the papillary regions of the tongue, the lamina propria projected up into the base of the primary papillae.

The <u>submucosa</u> was absent along the dorsal surface of the tongue, and Bailey (1958) maintained that no submucosa was distinguishable on the dorsum of the tongue in man.

The bulk of the tongue was composed of skeletal muscle fibers, particularly the anterior two-thirds. The muscle fibers were arranged in a fibro-elastic stroma and coursed in three directions, longitudinally, transversely and vertically.

Numerous ramifications of the lingual artery were present in the deeper region of the tongue.

4. The Esophagus

The esophagus (fig. 21) exhibited four distinct layers of tissue, the mucosa, submucosa, muscularis externa and tunica adventitia.

<u>Mucosa</u>. The mucosa was lined by stratified squamous epithelium with a very thick keratinized layer. The thick keratinized layer is probably characteristic of the animals which eat rough fibrous food (Ham, 1953). The base of the

longitudinally folded mucosa was the lamina propria made up of closely woven collagenous fibers with some elastic fibers interspersed. Its well developed papillary body was covered by cornified stratified squamous epithelium (fig. 21).

The basal surface of the muscularis mucosae serves as a line of demarcation between the mucosa and submucosa. It was formed of smooth muscle running in a longitudinal direction. These muscles thickened in the region of the esophagus adjacent to the stomach. The smooth muscle was the thickest in the posterior third of the esophagus.

Submucosa. The submucosa, which was adjacent to the muscularis mucosae, was about one-fourth as wide and consisted of collagenous and coarse elastic fibers. Glands were not identified in this layer. Stiles (1956) maintained that esophageal glands were absent in rodents.

Muscularis externa. The proximal third of the muscularis externa consisted of skeletal muscle, and from the juncture with the pharynx it became progressively more regularly arranged into inner circular and outer longitudinal layers. Trautmann and Fiebiger (1957) maintained that the inner circular layer became thicker toward the stomach in all animals, especially the horse. They further stated that the transition from striated to smooth musculature occurred in the pig just cranial to the cardia and in the cat it occurred at the beginning of the caudal third to fifth of the esophagus. In nutria the upper third of the esophagus exhibited a muscularis externa composed entirely of skeletal muscle; the middle third exhibited a mixture of skeletal and smooth and the posterior third exhibited only smooth muscle.

Tunica adventitia. The adventitia consisted of loose fibro-elastic connective tissue.

5. The Stomach

The wall of the stomach (figs. 22 and 23) consisted of the usual four coats: mucosa, submucosa, muscularis externa and serosa. The mucosa was greatly folded into ridges called rugae. The epithelium was simple columnar. The epithelial surface was indented by the gastric pits which supplied the glands. The surface cells were tall and contained mucus. No glands were observed between the transition zone of the esophagus and cardiac region of the stomach.

The lamina propria in which the glands were located was made up of loose areolar connective tissue. In the glands proper the chief cells and parietal cells were not as prominent as in some mammals. Periodic-acid Schiff positive secretion was distributed on the area of the epithelium which indicated mucin secretion of the gastric surface epithelium (fig. 23).

The muscularis mucosae consisted of a thin layer of smooth muscle in which the fibers coursed in both the circular and longitudinal direction.

The submucosa consisted of loosely arranged connective tissue. It contained blood vessels and nerves. No glands were observed in the submucosa.

Bailey (*op. cit.*) maintained that the muscularis externa of the stomach was usually described as consisting of three layers, an inner oblique, a middle circular, and an outer longitudinal. In nutria the muscularis externa consisted of two distinct layers, an inner thick circular layer and an outer longitudinal layer of smooth muscles.

The serosa consisted of loose areolar tissue covered by mesothelium.

6. The Intestines

1'. *The Small Intestine* (figs. 24, 25 and 26)

The walls of the small intestine were composed of the characteristic four layers; the chief modification was found in the mucosa.

The most distinguishing feature of the intestinal mucosa was the villus. The central core of each villus consisted of delicate loose connective tissue. The lamina propria of the mucous membrane was infiltrated with blood capillaries to a variable extent. Simple columnar epithelium covered the villus and consisted of goblet and columnar absorptive cells, the latter exhibited a cuticular border (striated free border).

Crypts of Lieberkuhn occurred throughout the small intestine. In addition, there were a group of large granular cells, the cells of Paneth (fig. 26) which were found in the depths of the crypts of Lieberkuhn. The nuclei of these cells were near the basement membrane and the cytoplasm between the nucleus and apex of each contained eosinophilic granules.

Like the stomach, the submucosa of the small intestine consisted of loosely arranged areolar tissue. The submucosa was free from glands except in the duodenum, where it contained the glands of Brunner. Brunner's glands were the most distinguishing characteristic of the duodenum. Note periodic-acid Schiff positive secretion of Brunner's gland (fig. 24).

The muscularis mucosae was thin, and consisted of an inner circular and an outer longitudinal layer of smooth muscle.

The muscularis externa consisted of a thick inner circular layer of smooth muscle and a thin outer longitudinal layer of smooth muscle.

The serosa consisted of loose connective tissue covered by a layer of mesothelium.

2. Large Intestine (figs. 27, 28, 29 and 30)

Topographically the large intestine was divided into cecum, large colon, small colon and anus.

The wall of the large intestine like the other layers of the digestive tract consisted of mucosa, submucosa, muscularis externa and serosa.

The large intestine lacked villi. Its mucosa was thicker; its glands of Lieberkuhn were longer and straighter and very rich in goblet cells. The distal surface of the epithelium exhibited a striated border (microvilli, fig. 29). The lamina propria consisted of lympho-reticular tissue.

The muscularis mucosae consisted of an inner circular and an outer longitudinal layer of smooth muscle fibers.

The submucosa was composed of areolar connective tissue which at times showed considerable amounts of adipose tissue.

The muscularis externa consisted of an inner circular layer which was very prominent, but the longitudinal muscles were arranged into two longitudinal bands, the taenia coli. The taenia coli exhibited an abundance of elastic fibers but were sparse in muscular elements.

The outer surface of the colon formed the serosa which showed many elastic fibers in addition to a cellular layer of squamous epithelia which rested on a connective tissue.

7. The Pancreas

The pancreas (fig. 31) was covered with a thin layer of connective tissue but did not have a definite fibrous capsule. It was not a compact organ as found in man, but was rather diffused. On the other hand it was finely lobulated and the connective tissue and interlobular septa were found to contain blood vessels, lymphatic and excretory ducts.

The lumen of the acinus was small, and secretory canaliculi projected between the gland cells. The intercalated ducts (centro-acinar cells) were lined by flat or cuboidal epithelium. The intralobular ducts were lined by a simple columnar epithelium which rested upon a basement membrane. The cells of the epithelium varied in height in accordance with the size of the duct.

The acinar gland was serous and consisted of a single row of pyramidal epithelial cells which were supported by a fine reticular network. In each cell there was an inner zone and a basal zone. The inner zone was coarsely granular and adjacent to the lumen, while the more deeply stained basal zone was toward the basement membrane. The spherical nucleus was located in the basal zone, but a portion of it projected into the inner zone.

The endocrine units, islets of Langerhans, were distributed throughout the parenchyma. They varied in size and appeared to be smaller than the islets found in other mammals, especially man. They were well supplied with blood vessels.

8. The Spleen

The spleen (figs. 32 and 33) was covered by a serous membrane, beneath which was a fibro-muscular capsule. Trautmann and Fiebiger (1957) maintained that in the horse and ox, the muscle fibers were arranged in layers; in other domestic animals they were interwoven. According to Ham (1953) in some animals there is much more smooth muscle in the capsule of the spleen than in man and its contraction can materially assist the smooth muscle of the trabeculae in contracting the spleen. Unlike most mammals the serosa was not intimately attached to the capsule in the nutria, but loosely attached.

The capsule of the nutria exhibited more smooth muscle than that found in man. Branching and invagination of the inner wall resulted in the trabeculae which penetrated the parenchyma; however the trabeculae were not too prominent in nutria. According to Trautmann and Fiebiger (op. cit.) there were two quantitative types of mammalian spleens. The "storage" spleen of the horse, dog, and cat is relatively large, rich in trabeculae and poor in white pulp. The contrasting is the "defense" spleen which is small and has few trabeculae and muscle fibers but abundant lymphatic tissue. In nutria the trabeculae were fibro-muscular (smooth) in nature and contained numerous elastic fibers.

The splenic parenchyma was a mixture of red pulp and white pulp. The white pulp was typical lymphatic tissue. On the other hand the red pulp was more diffuse and was not as dense as the former. Each splenic corpuscle (white pulp) contained a small artery of variable position. The artery was not visible in every corpuscle because some sections were cut parallel to the artery, not through it. The spaces between the white pulp and the trabeculae were filled by the red pulp. This contained, in addition to the arterial branches that emerged from the white pulp, the sinusoids. The sinusoids were not as well developed as they are in man. The red pulp contained numerous erythrocytes and lymphocytes.

9. The Gall Bladder

The wall of the gall bladder (figs. 34 and 35) consisted of three layers, namely mucosa, muscularis externa, and serosa.

The <u>mucosa</u> was thrown into numerous low folds and near the neck of the gall bladder small glands were identified (fig. 35). The epithelium consisted of simple columnar cells with oval nuclei situated in the basal zone.

The <u>lamina propria</u> mucosae consisted of a dense connective tissue and scattered vascular plexuses.

The muscularis externa consisted of an inner longitudinal and an outer circular layer of smooth muscle fibers with collagenous and elastic fibers interspersed between the muscles.

Just external to the muscularis externa was a fibrous connective tissue and outside of this was a subserous layer of connective tissue containing blood vessels.

VIII. HISTOLOGY OF THE URINARY AND REPRODUCTIVE ORGANS

1. The Kidney (figs. 36 and 37)

Yadava and Calhoun (1958) maintained that the capsule of the pig, horse, ox, goat, dog and cat consisted of two distinct layers. The outer thick layer contained dense collagenous fibers and a few elastic fibers. The inner layer was composed of loose collagenous and reticular fibers with smooth muscle cells interspersed between.

The outer surface of the kidney of nutria was covered by a thin fibro-muscular capsule consisting of two layers. The thin outer layer exhibited dense collagenous fibers and the thin inner layer consisted of smooth muscle fibers and less collagenous tissue adjacent to the parenchyma of the kidney. Gomori's modification of Masson's stain failed to reveal any elastic fibers.

The structural and functional unit of the kidney was the nephron. It consisted of the renal corpuscle, the proximal convoluted tubule, the loop of Henle and the distal convoluted tubule.

The renal corpuscle. Each nephron originated as a spherical expansion (Malpighian or renal corpuscle) which consisted of a Bowman's capsule which enclosed a tuft of capillaries, the glomerulus. Each renal corpuscle showed a vascular pole, marked by the point where glomerular vessels enter and leave, and nearly opposite to this was the urinary pole, where the dilated uriniferous tubule invested the glomerulus to form the Bowman's capsule.

Bowman's capsule consisted of an inner visceral layer covering the glomerulus and an outer parietal layer. The former which adhered to the capillaries did not appear as a distinct layer of cells but consisted of clumps of simple squamous epithelial cells. The epithelium of Bowman's capsule exhibited a periodic acid-Schiff positive basement membrane (fig. 36).

The proximal convoluted tubule. The proximal convoluted tubule was lined by a row of simple cuboidal cells with spherical nuclei and granular cytoplasm. The brush border which characterized the convoluted tubules of other mammals was not identified in nutria. The cells of the proximal tubule did not give a PAS reaction. The central part of the lumen portion of the tubule presented a foamy appearance. The proximal convoluted tubule pursued a looped and tortuous course in the vicinity of the renal corpuscles from which it originated. It then entered the medullary ray, became straight, and continued as the descending limb of the loop of Henle.

The loop of Henle. The loop of Henle consisted of a descending and an ascending arm. It was divided into a thick and a thin segment. The greater part of the loop within the medulla was the thin segment which consisted of flattened epithelium with prominent nuclei which projected into the lumen. The epithelial lining of the descending thick segment of Henle's loop resembled that of the proximal tubule; the epithelium of the ascending tubule resembled that of the distal tubule. The diameter of the thin segment was approximately the size of a blood capillary and was smaller than either the proximal or distal tubules.

The distal convoluted tubule. The distal convoluted tubule was composed of two segments, the pars recta and pars convoluta. The pars recta formed the thick ascending limb of Henle's loop. The distal convoluted tubules were lined by cuboidal epithelium and the cells were smaller in size. The nuclei were more closely spaced than in the proximal tubule. The cells of the distal convoluted tubules reacted strongly with the PAS reagent and the staining reaction was more intense in the distal portions of the epithlial cells. The lumen was well defined and was clear in contrast to the foamy appearance of the lumen in the proximal tubules.

Macula densae. The part of the distal tubule which was in contact with the afferent glomerular vessel on the side adjacent to the arteriole was designated the macula densae. It was comprised of closely packed nuclei in tall thin elliptical cells. The macula densae constituted about half of the distal convoluted tubule as seen in cross section. It consisted of a single layer of cells which were usually larger than the rest of the cells of the distal tubule. The nucleus was spherical and exhibited a dark stained nucleolus.

The collecting tubule. The collecting tubule consisted of the arched collecting tubule, the straight collecting tubule and the papillary duct.

The arched tubules were located in the cortical labyrinth and were short stems that branched from the sides of the straight collecting tubules located in the medullary ray. The arched collecting tubule was lined by a simple cuboidal epithelium with distinct cell boundaries. The lumen was wider than that of the distal tubule. The nuclei were spherical or oval.

The straight collecting tubules were parallel and directed toward the papilla and made up most of the substance of the pyramid. They ultimately became continuous with the pyramid to form the papillary ducts. The straight collecting tubule was lined by simple cuboidal epithelium which became wider and taller toward the papillary duct. The nuclei were larger than the arched collecting tubule.

The papillary duct was the same general structure as that of the straight collecting tubule. It was lined by a simple, tall columnar epithelium. The nuclei were larger, spherical and situated almost in the center of the cell.

2. The Ureter (figs. 38 and 39)

The epithelium of the ureter was typical transitional epithelium with a wide variety of cell forms. The cells of the basal layers were cuboidal while the superficial layer consisted of oval, cuboidal and spindle-shaped cells often containing several nuclei. The basement membrane was not evident with the lens system used in this study.

In 1841 Henle (Bremer and Weatherford, 1944) gave the name "transitional" to this epithelium because he believed it to be an intermediate form between stratified and simple columnar epithelium. Investigations made subsequent to this period demonstrated that differences in appearance of the epithelium seemed to be correlated to the degree of distention.

The lamina propria consisted of mostly collagenous fibers and few elastic fibers as shown by prepared sections using Biebrich Scarlet and Van Gieson's stain. No glands were evident in the propria of nutria.

The muscularis externa consisted of thin bundles of smooth muscle fibers and formed an inner longitudinal layer, a middle circular, and a thin outer longitudinal layer. The muscles were interspersed by collagenous bundles. The ureter contained only longitudinal muscle fibers near the opening into the bladder.

The loosely arranged adventitia consisted of collagenous fibers, large blood vessels and nerves. The blood vessels were directed mostly longitudinally and formed a dense subepithelial capillary network.

3. The Bladder (fig. 40)

The bladder was lined by transitional epithelium. Stiles (1956) indicated that the cells of the surface layer were cuboidal and pear-shaped in the human bladder. In nutria the cells lining the surface of the bladder epithelium showed variations, but in general exhibited the shape of elongated cubes, usually ovoid and in some cases spindle-shaped. The cells of the basal layer were the same as that of the ureter. Binucleated cells were frequently observed.

Bremer and Weatherford (1944) indicated that capillaries were often found within the basal layer of the epithelium of the human bladder. No capillaries were observed in the bladder epithelium of nutria.

The lamina propria consisted of loosely arranged collagenous and elastic fibers (Masson's Trichrome Stain) containing many capillaries and sometimes lymph nodules. The elastic fibers were more numerous towards the submucosa. There was no distinct submucosa and no glands.

Moore and Calhoun (1957) maintained that the muscularis mucosa of the bladder of domestic animals differed extensively, and that it was best developed in the horse. There was no evidence of a muscularis mucosa in nutria.

The muscularis externa was very thick and constituted about two-thirds of the bladder wall. It consisted of an external and internal longitudinal layer and a middle circular layer. The latter was the thickest and showed the most continuity. The connective tissue of the muscularis externa was composed of loose collagenous tissue with a few elastic fibers. Numerous blood vessels of various sizes were found coursing through the muscle layer.

A serosa was present on the vertex and lateral wall of the bladder. It was composed of mesothelium and a submesothelial layer which consisted of collagenous fibers. At the neck of the bladder, the serosa was replaced by an adventitia which contained blood vessels and nerves.

A. The Male Genital Organs

1. The Testis (fig. 41)

The testis was enclosed by a thick fibrous capsule, the tunica albuginea, which in turn was covered by the visceral layer of the tunica vaginalis. Van Gieson's stain revealed that the latter was composed of collagenous connective tissue which contained few blood vessels and elastic fibers. The free surface of the tunica vaginalis was covered by mesothelium while its attached surface blended into the underlying tunica albuginea.

The seminiferous tubules (175-180 μ) were highly convoluted with lumina of varying sizes. The wall of a seminiferous tubule consisted of collagenous and fibro-elastic fibers with a thin basement membrane. Loose collagenous fibers occupied the interstices among seminiferous tubules. Interstitial cells were found in small clusters located in the spaces adjacent to the seminiferous tubules. Surrounding the basement membrane was an epithelium consisting of Sertoli cells and spermatogenic cells.

The Sertoli cells were few in number and were tall, slender, radially arranged cells which extended from the basement membrane to the lumen. The cell borders were indistinct. The nuclei were ovoid with finely dispersed chromatin and were generally situated in the basal portion.

The spermatogenic cells lay between the cells of Sertoli and from three to seven layers occupied the space between the basement membrane and the lumen. The spermatogonia made up the basal layer and also included part of the second layer of cells. The primary spermatocytes were next to the spermatogonia on their inner side followed by the similar but smaller spermatocytes.

The spermatids adjoined the lumen of the tubule and were variable in number. They were recognized by their small size and location. They became transformed into the mature spermatozoa.

2. The Epididymis (fig. 42)

Grossly the epididymis was composed of cauda, corpus and caput epididymis. The epididymis of nutria was similar to that of the rat. In the specimens which I have examined the rete testis communicated at the anterior pole of the testis with five ductuli efferentes. The ductuli efferentes were approximately 0.3 millimeters in diameter and were lined with tall pseudostratified columnar epithelium cells which varied in height. On their inner surface they were supported by discontinuous basal cells and their free surfaces were sterociliated. The lumen was uneven, possibly due to the alternation of tall and short groups of columnar cells with cells of a cuboidal type. The epithelium rested on a basement membrane surrounded by a lamina propria of thin collagenous fibers containing a few capillaries and some smooth muscle fibers.

The ductuli efferentes opened into the caput epididymis which was a single and highly coiled channel attached to the anterolateral surface of the testis. The epithelium of the caput was simple cuboidal, possessed long stereo cilia on the apices of the epithelial cells. The corpus epididymis although highly convoluted was smaller than the caput. The epithelium of the corpus consisted of pseudostratified non-ciliated epithelium with a few small basal cells. The cauda epididymis was located at the caudal end of the testis. Its epithelium was pseudostratified with varying cell heights and was surrounded by a thick wall of collagenous fibers containing many circular, smooth muscles.

3. Ductus deferens (fig. 43)

The walls of the ductus deferens consisted of a mucosa, muscularis externa, and an adventitia.

The mucosa exhibited three or four longitudinal folds. It was lined by pseudostratified columnar epithelium. The epithelium was surrounded by a stroma containing elastic fibers and collagenous fibers which formed the lamina propria. There was no ampulla in the deferens ducts of nutria as found in man and other mammals.

The muscularis externa consisted of a thin and discontinuous inner longitudinal layer of smooth muscles. The middle layer was thicker and composed of an intermingled mass of circular, oblique, and longitudinal fibers. A thin but well defined layer of longitudinal muscle lay on the outer surface of the middle layer.

The adventitia consisted of elastic and collagenous fibers containing numerous blood vessels and scattered, branched, longitudinal muscle fibers.

4. The Prostate gland (figs. 44 and 45)

The prostate gland was made up of an aggregation of branched tubular glands. The glands were situated dorsolateral to the urethra and opened on either side into the urethra through the colliculus seminalis. Stanley and Hillemann (1960) failed to describe the prostate gland, and according to the anatomical location it was referred to as prostate gland in this investigation.

The gland was a lobulated compound tubular structure surrounded by a vascular capsule of loose areolar connective tissue containing numerous smooth muscle fibers in its inner layer. The broad septa from the capsule penetrated the interior to form the stroma which contained smooth muscle fibers. These fibers were circularly arranged and interspersed with collagenous fibers. The glandular epithelium was underlaid by a very thin lamina propria of collagenous tissue interspersed with elastic fibers.

The epithelium exhibited many variations in different glands. Glands which possessed a small amount of secretion within the lumen were smaller in diameter and were highly folded. The epithelium was tall, simple columnar and possessed a heavy granular cytoplasm. Glands which possessed an abundance of secretion in the lumen were of greater diameter. The epithelium was cuboidal or squamous and devoid of folds or slightly folded.

5. Seminal vesicles.

The seminal vesicles were paired and lay anterior to the prostate glands.

The entire gland was covered by a serosa consisting of loose areolar connective tissue. A thick muscularis surrounded the lamina propria. It consisted of smooth muscle fibers coursing in an oblique, circular, and longitudinal pattern. Numerous reticular fibers, a small amount of collagenous fibers, and very few elastic fibers were interspersed throughout the muscularis layer.

The lamina propria consisted of a delicate layer of collagenous connective tissue with very few elastic fibers.

The epithelium of the gland was similar to that of the prostate gland and was thrown into numerous folds. The secretions into the lumen of the gland were mostly eosinophilic and formed blebs and cracks upon fixation.

Loose areolar connective tissue was located between adjacent portions of the glands. The epithelium varied from tall columnar to low cuboidal.

6. Bulbo-urethral gland (fig. 46)

In nutria the paired bulbo-urethral glands were located at the base of the tail on either side of the anus. These findings were in agreement with Hillemann et al. (1958).

The gland was surrounded by skeletal muscle fibers. The underlying capsule contained smooth and skeletal muscle along with collagenous connective tissue surrounding the duct.

The terminal portion of the gland may be tubular or in the form or cyst-like dilations. It was lined by simple columnar epithelium. The majority of the columnar cells

were of the mucous type. The dark staining nuclei were flattened against the base of the cell. The epithelium rested on a thin lamina propria of collagenous connective tissue. Stanley and Hillemann (1960) maintained that the entire epithelium was thrown into many anastomosing folds lined with secretory epithelium which was in agreement with my findings.

7. The Male Urethra.

The proximal portion of the urethra was lined with transitional epithelium similar to that of the bladder. The surface of the epithelium was irregular. In the membranous and cavernous portions the epithelium was stratified cuboidal or columnar.

The lamina propria consisted of collagenous connective tissue and elastic fibers and was poorly vascularized. It was surrounded by a thick layer of longitudinal smooth muscle. Glands were not observed in the lamina propria of the nutria in the present investigation.

The muscularis externa consisted of an inner longitudinal and outer circular layer of smooth muscle. Surrounding the muscularis externa was an adventitia containing large blood vessels.

8. The Penis (figs. 47 and 48)

The penis was divided into body and glans. The corpora cavernosa penis made up the body and consisted of a capsule or tunica albuginea, a system of trabeculae, and true erectile tissue. The tunica albuginea was a thick membrane composed of collagenous and elastic fibers. Elastic fibers were quite numerous. The interior of the body consisted of a network of large spaces or lacunae lined by endothelium. These were separated by fibrous trabeculae. The trabeculae formed a median septum which was not continuous throughout the body.

The trabeculae exhibited an abundance of smooth muscle fibers which were arranged circularly and longitudinally. Between the trabeculae lay the spongy erectile tissue proper which consisted of a fine framework of cords continuous with the trabeculae and albuginea with various shaped communicating spaces. Scattered adipose tissue was present in the corpora cavernosa penis.

Morphologically the corpus cavernosum urethrae was similar in structure to the corpus cavernosum penis; however the albuginea of the corpus cavernosum urethrae was thin. The trabeculae were also thin. Between the trabeculae

were spaces increasing in size toward the albuginea that were lined with endothelium and usually filled with blood.

The tip of the penis was made up of the glans, which may be indistinct in some species. In the nutria the glans penis contained a baculum somewhat cylindrical in shape. It was approximately twenty millimeters in length and two to three millimeters in diameter.

The erectile tissue of the glans was separated from the cavernosum tissue and was very rich in elastic fibers. Most of the elastic tissue in the glans penis surrounded the vascular spaces in the erectile tissue. Blood vessels in the erectile tissue had thick muscular walls.

The lamina propria underlying the epithelium of both glans and prepuce consisted of dense collagenous connective tissue.

The skin of the penis and prepuce exhibited a thick keratinized stratified squamous epithelium. The epithelium of the glans projected into spines (fig. 48).

B. The Female Genital Organs

1. The Ovary (figs. 49, 50 and 51)

A section of the ovary reveals two zones, a broad outer layer, the cortex; and a central deeper portion, the medulla or zona vasculosa.

r

a

c

l

s

ma

th

we

te

In nutria the ovary was covered with an epithelial surface (germinal epithelium) which consisted of cuboidal to cylindrical cells. Beneath the germinal epithelium was a thick tunica albuginea (20-25mm) which was located on the extension of connective tissue drawn out from the stroma. It consisted of cellular elements in a matrix of collagenous and reticular fibers. No elastic fibers were observed.

The stroma consisted of spindle-shaped connective tissue cells and connective tissue fibers. Vestiges of fetal structures, the <u>rete ovarii</u> were present and occurred as epithelial strands or tubules in the region of the hilum (fig. 49).

Beneath the tunica albuginea and at a distance of approximately 20-120u lay the primary follicles with a diameter of approximately twenty-five millimeters. The primary follicles were not evenly distributed. The surrounding epithelium of the follicle was single layered and consisted of spindle-shaped nuclei.

The follicles were divided into primary, secondary and mature or Graafian follicles. The histological details of the follicles in different stages of development fairly well followed the pattern described in most histological textbooks (figs. 49, 50 and 51).

2. The Oviduct (fig. 52)

The wall of the oviduct presented three layers: mucosa, muscularis externa and serosa. The lining consisted of an epithelial layer of large ciliated cylindrical to columnar cells. The epithelium of the ampulla was thrown into large folds resembling fingers which transversed most of the lumen (fig. 52). The lining of the isthmus contained three to four longitudinal folds and possessed tall pseudostratified columnar cells. The epithelium of the last portion, pars uterina consisted of low columnar or cuboidal type cells.

The lamina propria lacked glands and was composed of rich cellular connective tissue which was compact in the isthmus and loosely arranged in the folds of the ampulla.

The muscularis externa consisted chiefly of bundles of circular smooth muscle fibers; however, isolated longitudinal and oblique bundles did occur in some places. The muscularis was thicker in the isthmus portion.

The outer serosa was united to the muscular layer by a very thin layer of connective tissue.

3. The Uterus (figs. 53 and 54)

The mucosa (endometrium) was lined by simple cuboidal to columnar nonciliated cells. Tubular glands consisting of an epithelium similar to that of the surface projected into the lamina propria. Stanley and Hillemann (op. cit.) maintained that in the non-pregnant uterus, these glands were short and lay immediately under the luminal epithelium, but in early pregnancy and shortly after ovulation they were much longer and coiled toward the muscle layer.

The lamina propria (endometrial stroma) contained the glands and consisted of thick collagenous tissue and dense elastic fibers (fig. 54).

The muscularis (myometrium) consisted of a thick inner circular layer and a thin outer longitudinal layer of smooth muscles which contained irregular strands of dense collagenous connective tissue and large vessels.

The serosa consisted of dense collagenous connective tissue in addition to a mesothelium which extended around the uterus outside the longitudinal muscles.

4. The Vagina and Urethra (fig. 55)

The mucosa of the vagina showed longitudinal folds or rugae and was lined by stratified squamous epithelium which rested on the lamina propria.

The lamina propria was made up of dense connective tissue which was rich in elastic fibers. In addition there were lymphoid tissues and aggregations resembling lymph nodules.

The muscularis layer consisted of weakly developed circular and longitudinally arranged smooth muscles.

There was no serosa except for the anterior portion. A loose adventitia containing large vessels, nerves and ganglia lay peripheral to the muscle layers.

The distal portion of the urethra was lined by stratified squamous epithelium. In the middle region of the urethra the epithelium underwent a transition to stratified cuboidal or columnar and continued in this manner until approximately 1 - 1.5 millimeters from the bladder, where a transitional epithelium commenced and continued into the bladder. The mucosa was thrown up into three or four low folds. A few coiled tubular glands opened into the posterior portion of the urethra. The epithelium of these glands consisted of simple cuboidal cells. These glands differed in structure from those described in man as glands of Littré (Bailey, 1958).

The lamina propria was highly vascular and contained a plexus of thin-walled veins. Stanley and Hillemann (op. cit.) indicated that there was an aggregation of lymphocytes commonly seen immediately under the epithelium. In this investigation a few lymphocytes were observed.

There were distinct variations in the musculature. The upper portion of the urethra exhibited a well developed layer of longitudinal smooth muscle which surrounded the lamina propria and was covered by thick connective tissue. Outside of this lay another layer of longitudinal smooth muscle. In the middle region no smooth muscle was found, but instead circularly arranged skeletal fibers interspersed with a fairly thick lamina propria. Longitudinal arranged fibers were also found outside of the circular ones. The caudal portion exhibited very few muscle fibers.

IX. SUMMARY

The gross and microscopic anatomy of the digestive and urinary systems and histology of the reproductive system of the nutria were presented.

Eight adult nutrias of various ages were dissected and used in this study.

Fifteen drawings and forty photomicrographs accompany the descriptions.

The lips consisted of two musculo-membranous folds which surrounded the opening of the mouth. The lateral surfaces of the lower lip encircled the incisors and met posteriorly in a distinct narrow groove which partially supported the ventral aspect of the tongue.

Two types of vibrissae were found on the lateral and ventral surface of the head. The mystacial vibrissae which were the largest and most numerous, were described in detail.

The oral cavity was small and was always closed anteriorly by the protrusion of the anterior tip of the tongue. It consisted of anterior and posterior divisions.

The dental formula in nutria was $2\ (\mathrm{I}\ \frac{1}{1}\ \mathrm{C}\ \frac{0}{0}\ \mathrm{P}\ \frac{0}{0}\ \mathrm{M}\ \frac{4}{4})$. The occlusal surfaces of the molars presented distinct ridges and grooves.

Palatine ridges were absent in the hard palate. The posterior border of the soft palate was free, thin, and concave and was in contact with the epiglottis.

The muscular tongue exhibited three portions and a distinct intermolar eminence. Three types of papillae, namely, filiform, foliate and circumvallate were found on the dorsal surface of the tongue.

The pharynx was mainly nasopharynx and the laryngeal pharynx was absent. Parotid, submaxillary and sublingual glands were present, the largest being the parotid. Buccal parotid glands (described as molar glands in the chinchilla) were absent.

The stomach was lenticulated with its anterior end curved to form a prominent arch directed caudally. No definite subregions of the small intestine could be made except on an arbitrary basis. The small intestine exhibited an abundance of lymph nodules.

The large intestine consisted of a large, spiralled, and sacculated cecum, sacculated large colon and non-sacculated small colon.

The pancreas was lobulated and diffused. The liver was large compared to the chinchilla, rabbit and guinea pig. The coronary ligament of the liver was absent. The gall bladder was pear-shaped and very voluminous for the size of the animal.

The male urethra exhibited features similar to those of the guinea pig and beaver.

Histologically the following observations were noted:

1. The parotid salivary gland was serous while the submaxillary and sublingual glands were mixed.

2. The tongue lacked fungiform papillae and taste buds were not observed.

3. Esophageal glands were absent in the submucosal layer of the esophagus.

4. The digestive tract presented no outstanding features from other mammals, however cells of Paneth were found in the depths of the crypts of Lieberkuhn which is not true for all animals. The distal surface of the intestinal mucosa exhibited a pronounced striated border (microvilli).

5. The islets of Langerhans were small.

6. The capsule of the spleen exhibited more smooth muscle than described for the spleen of the guinea pig. The serosa of the spleen was not intimately attached to the capsule.

7. The trabeculae of the spleen were not prominent.

8. The mucosa of the gall bladder exhibited numerous folds and small glands were present in the neck region.

9. The outer surface of the kidney was covered by a thin fibro-muscular capsule and the epithelium of Bowman's capsule was periodic acid-Schiff positive. Brush borders which are characteristic of the proximal convoluted tubules in other mammals were not observed.

10. There was no evidence of a muscularis mucosae in the bladder of nutria and glands were not observed.

11. Elastic fibers were absent in the ovary. Elements of the rete ovarii were identified.

12. The epithelium of the caput epididymis was simple cuboidal with long stereo cilia while the corpus and cauda epididymis possessed pseudostratified non-ciliated cells.

13. The ductus deferens lacked an ampulla.

14. Elastic fibers were abundant in the glans penis. The penis contained a baculum. The epithelium of the glans penis formed numerous spines.

LITERATURE CITED

Allen, Glover M. 1942. Extinct and Vanishing Mammals of the Western Hemisphere. Amer. Comm. for Internat'l Wildlife Protection. Special Publ. No. 11: 386.

Andrew, Warren. 1959. Textbook of Comparative Histology. Oxford University Press.

Ashbrook, Frank G. 1948. Nutria's grow in the U. S. Jour. Wildlife Management, 12: 87-95.

Bailey, F. R. 1958. Textbook of Histology. Revised by W. M. Copenhaver and D. D. Johnson. Williams and Wilkins Co., Baltimore.

Barnhart, C. 1950. The American College Dictionary. Harpers and Brothers. New York.

Bremer, J. L., and Weatherford, H. L. 1944. A Textbook of Histology. Blakiston Co., Philadelphia.

Bolk, L., Göppert, E., Lubosch, W. and Kallius, E. 1937. Handbuch der vergleichenden Anatomie der Wirbeltiere, Urban and Schwarzenberg, Berlin and Wein.

Beddard, Frank E. 1909. Mammalia Order IX. Rodentia. Macmillan and Co., St. Martins Street, London, pp. 458-507.

Buchanan, T. 1953. Manual of Anatomy. Bailliere, Tindal and Cox. London.

Burt, William H. 1946. The Mammals of Michigan. The University of Michigan Press, Ann Arbor, Mich. pp. 18-19.

Cunningham, Daniel J. 1951. Cunningham's Textbook of Anatomy. Edited by Brash. Digestive System Chapter. Oxford University Press, London.

De Girolamo, A. 1948. Dentition in the nutria. Morphology and Structure. Zootec. Vet., Milan 3: 192-202.

De Girolamo, A. 1953. Histology of the islets of Langerhans in the pancreas of nutria. Boll. Soc. Ital. Biol. Sper, 29: 1827-29.

Diamond, Moses. 1952. Dental Anatomy, Chapter 2, pp. 11-19. The Macmillan Co., New York.

Dorland, W. A. 1947. The American Illustrated Medical Dictionary. W. B. Saunders Co., Philadelphia and London.

Ellenberger, W., and Baum, H. 1943. Handbuch der vergleichenden Anatomie der Haustiere, Verlag Von August Hirschwald, Berlin.

Ensminger, Allan B. 1955. The Economic Status of Nutria in Louisiana. Fur and Refuge Division, La. Wildlife and Fisheries Comm., New Orleans, La.

Fahrenholz, in: Bolk, L., Göppert, E., Lubosch, W. and Kallius, E. 1937. Handbuch der vergleichenden Anatomie der Wirbeltiere, Urban and Schwarzenberg, Berlin and Wein.

Gray, Henry. 1956. Anatomy of the Human Body. The Digestive Apparastus, Lea and Febiger, Philadelphia. pp. 1235-1338.

Grant, H. C. 1935. Anatomy of the Rat. Transactions of the American Philosophical Society, Vol. 27, Philadelphia.

Griffith, J. and Farris, Edmond J. 1949. The Rat in Labroatory Investigation. J. B. Lippincott Company, 530pp.

Ham, A. W. 1953. Textbook of Histology. J. B. Lippincott Company, Philadelphia.

Hillemann, Howard Gaynor, Alta I., and Stanley, Hugh P. 1958. The genital systems of nutria (Myocastor coypus). Anat. Rec. 130: 515-531.

Jenkins, Thomas W. 1956. The anatomy of the cerebrospinal nerves of the fox squirrel, Scirurus niger rufiventer (Geoffroy). Anat. Rec. 126: 241-250.

Kainer, Robert A. 1954. The gross anatomy of the digestive system of the mink. Part I. The head and the foregut. Am. Jour. Vet Res. 15: 92-90.

Koch, T. 1953. Bietrage Zur Anatomie des Sumpfbibers. S. Hirzel Verlag. Leipzig, 168pp.

Koch, T. 1956. Zur Anatomie der Lunge des Sumpfbibers. Zbl. Vet. Med. 3: 287-298.

Louisiana Wildlife and Fisheries Co. Fur and Refuge Div. 1940-41. "Comparative Takes of Fur Animals in Louisiana".

Lowery, George H. 1943. Checklist of the mammals of Louisiana and adjacent waters. Occasional Papers of the Museum of Zoology, No. 13, Nov. 22. La. State University, Baton Rouge, La. p. 248.

MacManus, J. F. 1948. Histological and histochemical uses of periodic acid-Schiff. Stain Tech. 23: 99-107.

Martin, Paul. 1923. Lehrbuch der Anatomie der Haustiere. Band II. Anat. des Schweine, Hundes und Katze und Anat. der Impfsaugetiere, Stutgart Verlag von Schickhardt und Ebener, p. 308.

Martin, W. 1835. Visceral and osteological anatomy of the coypus (Myopotamus coypus). Proc. Zool. Soc. Part III. Edited by Richard Taylor, London.

Miller, M. E. 1952. Guide to the Dissection of the Dog. Edward Brothers, Ann Arbor, Mich.

Moore, R. D. and Calhoun, M. Lois. 1957. The histology of the bladder and the proximal urethra of the domestic animals. Anat. Rec. 127: p. 338.

Morrel, G. H. 1872. Comparative Anatomy and Dissection of the Mammalia. Part I, pp. 180-208. Longman and Co., London.

Moser, 1868. Gaumsensegel des Menschen, Vergleichen mit dem der Saugetiere. Diss. Tubingen.

Osgood, Wilfred H. 1943. The mammals of Chile. Field Museum, Nat. Zool. Ser. 30: 131-134.

Potter, G., Hermann, C. L. and Rabb, E. L. 1956. Anatomy of the digestive system of the guinea pig. Bios. 37: 232-234.

Potter, G. and Billello, L. J. 1960. External features of nutria. Turtox News, 38: 166.

Preuss, B. 1953. Makroskopische und mikroskopische Anatomie des ovariums bei Myopotamus. Hermann Daniel, Buchdruckerei und Verlag, Balingen, Germany.

Quaglio. 1955. Histology of cirrhosis of the liver in nutria. Atti. Soc. Ital. Sci. Vet. Palermo, 9: 389-393.

Reighard, J. and Jennings, H. S. 1935. Anatomy of the Cat. Henry Holt and Co., Inc., New York.

Rosati, P. 1956. Anatomical study of the digestive system of the nutria: The post-diaphragmatic tract. Acta. Med. Vet. Napoli, 2: 483-497.

Schacher, John F. 1956. Final report on parasites of Louisiana mammals with emphasis on nutria (Myopotamus coypus) and otter (Lutra canadensis ssp.). Research supported by Fur and Refuge Division. Louisiana Wildlife and Fisheries Comm.

Schour, Issac. 1953. Noyes' Oral Histology and Embryology. Lea and Febiger, Philadelphia. pp. 44-46; 377-402.

Schwarze, E. and Hoffman, G. 1954. Unterscheidungs merkmale an skelett Von Hauskaninchen, Hase und Sumpfbiben. II. Den Becken gürtel. Lebensmitteltierarzt, 5:175-176.

Sisson, Septimus and Grossman, James. 1954. The Anatomy of the Domestic Animals. W. B. Saunders Co., Philadelphia. pp. 260, 397, 524, 917.

Slebodzinski, A. 1957. The genital system of the female nutria. Med. Vet. Varsovie 8: 275-278.

Stanley, H. P. and Hillemann, H. 1960. Histology of the reproductive organs of nutria (Myocastor coypus). The Journal of Morphology, 106: 277-300.

Stiles, K. A. 1956. Handbook of Histology. Blakiston Div., McGraw-Hill Co., New York.

Titkemeyer, C. and Calhoun, M. Lois. 1955. A comparative study of the structure of the small intestines of domestic animals. Am. Jour. Vet. Research, 16: 152-157.

Trautmann, A. and J. Fiebiger. 1957. Fundamentals of the Histology of Domestic Animals. Translated and revised by Habel, R. E., and E. L. Biberstein. Comstock Publishing Associates, Ithaca, New York.

Walther, A. R. 1931. The South American Swamp Beaver (Nutria). F. C. Mayer, Munchen.

Walther, A. R. 1940. Der Sumpfbiber. F. C. Mayer, Munchen.

Watson, Michael and Avery, James K. 1954. The development of the hamster lower incisor as observed by electron microscope. Amer. Jour. Anat. 95: 109-161.

Weber, Max. 1927. Die Saugetiere. Band I, Anatomischen Teil, Verlag von Gustaw Fischer, Jena. pp. 234-302.

Wilcox, H. H. 1950. Histology of the skin and hair of the adult chinchilla. Anat. Rec. 108: 385-398.

Wolfer, Robert K. 1955. A Regional Anatomy of the Head, Neck, Thorax and Abdomen of the Chinchilla, _Chinchilla lanigera lanigera_ (Bennett). Unpublished Ph. D. Thesis, Michigan State University, 229pp.

Yadava, R. P. and Calhoun, M. Lois. 1958. Comparative histology of the kidney of domestic animals. Amer. Jour. Vet. Research, 19: 958-968.

Figure 1. The Nutria with the Lips Closed.

a. Fraenula labbii

b. Superior incisor

c. Median raphe

d. Superior labium

e. Tip of tongue

f. Aperture of oral cavity proper

g. Inferior incisor

h. Inferior labium

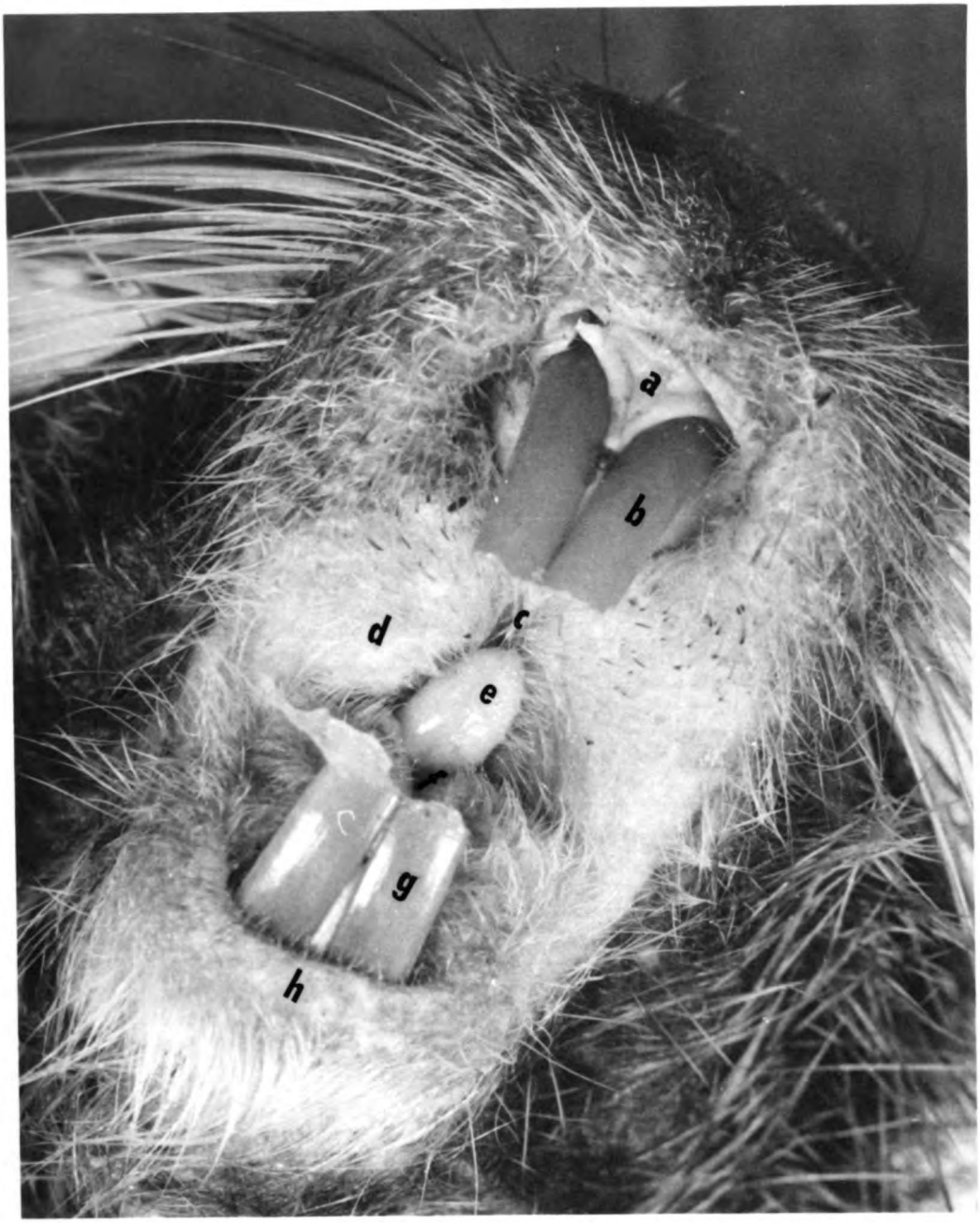
a
b
c
d
e
f
g
h

Figure 2. Position of the Facial Vibrissae

a. Mystacial

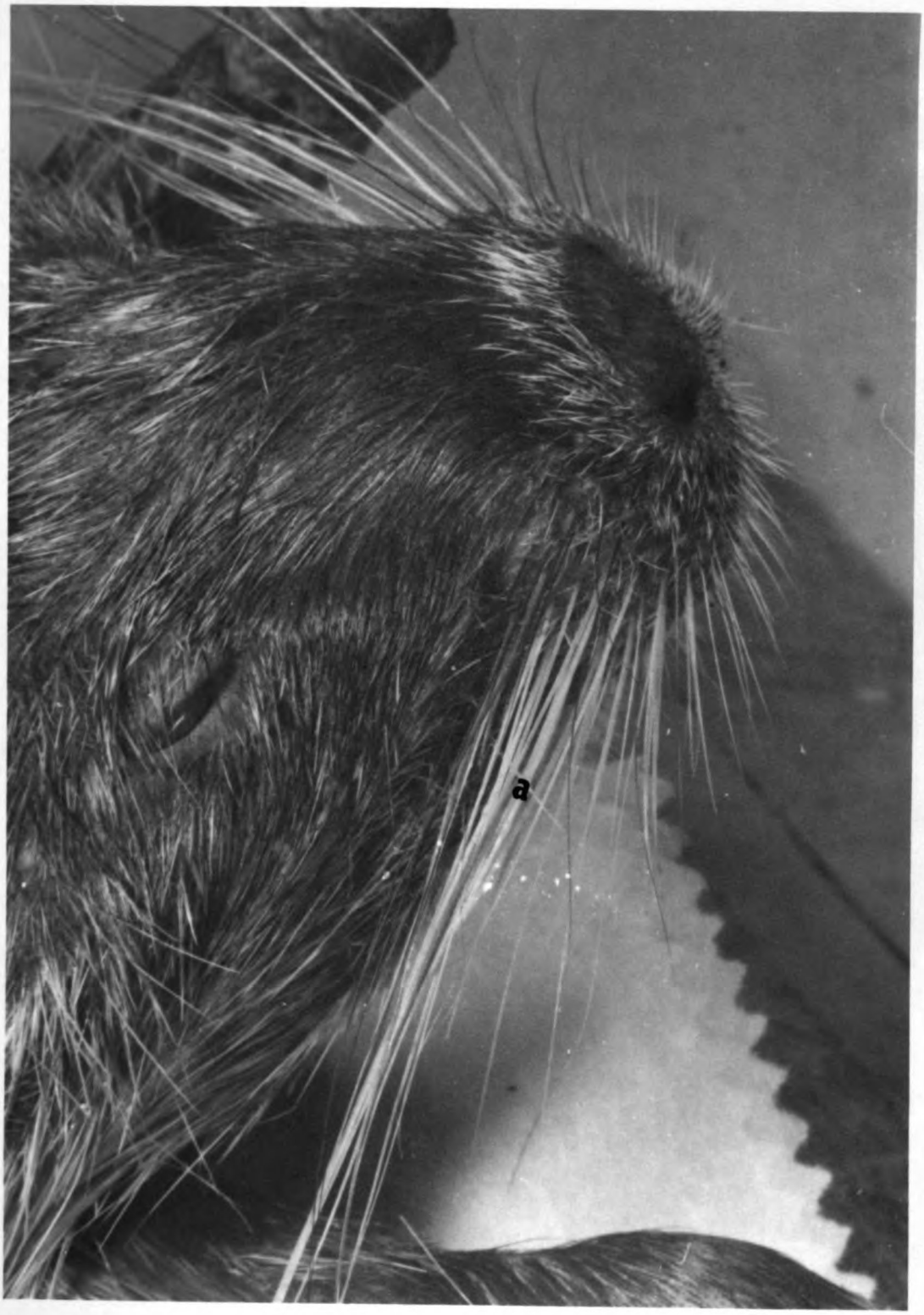
a

Figure 3. Sagittal Section Through the Head.

a. Cheek swelling

b. Inflexum pellitum

c. Nasal septum

d. Palatine process of the maxilla

e. Isthmus faucium

f. Palatine process of the palatine bone

g. Esophagus

h. Tongue

i. Olfactory bulb

j. Cerebrum

k. Cerebellum

l. Medulla oblongata

m. Cribriform ethmoid plate

n. Trachea

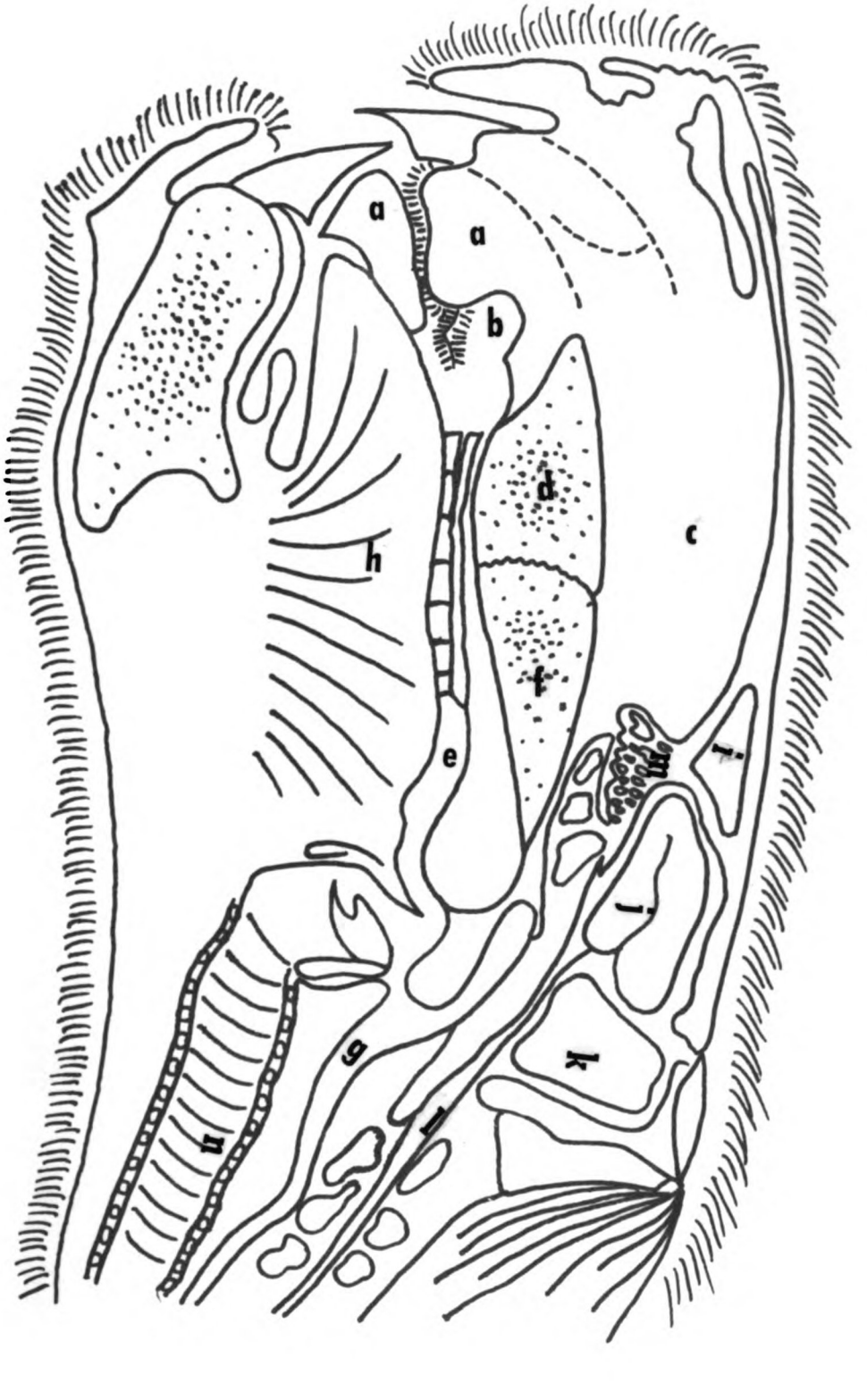
a
a
b
d
c
h
f
e
m
i
j
g
k
l
n

Figure 4. A Ventral View of the Palate of the Nutria

a. Superior incisor

b. Median raphe

c. Postincisal recess

d. Incisive papillae

e. Zygomatic arch

f. Hard palate (Mucosa)

g. Molar tooth

h. Soft palate (Mucosa)

i. Spinal cord

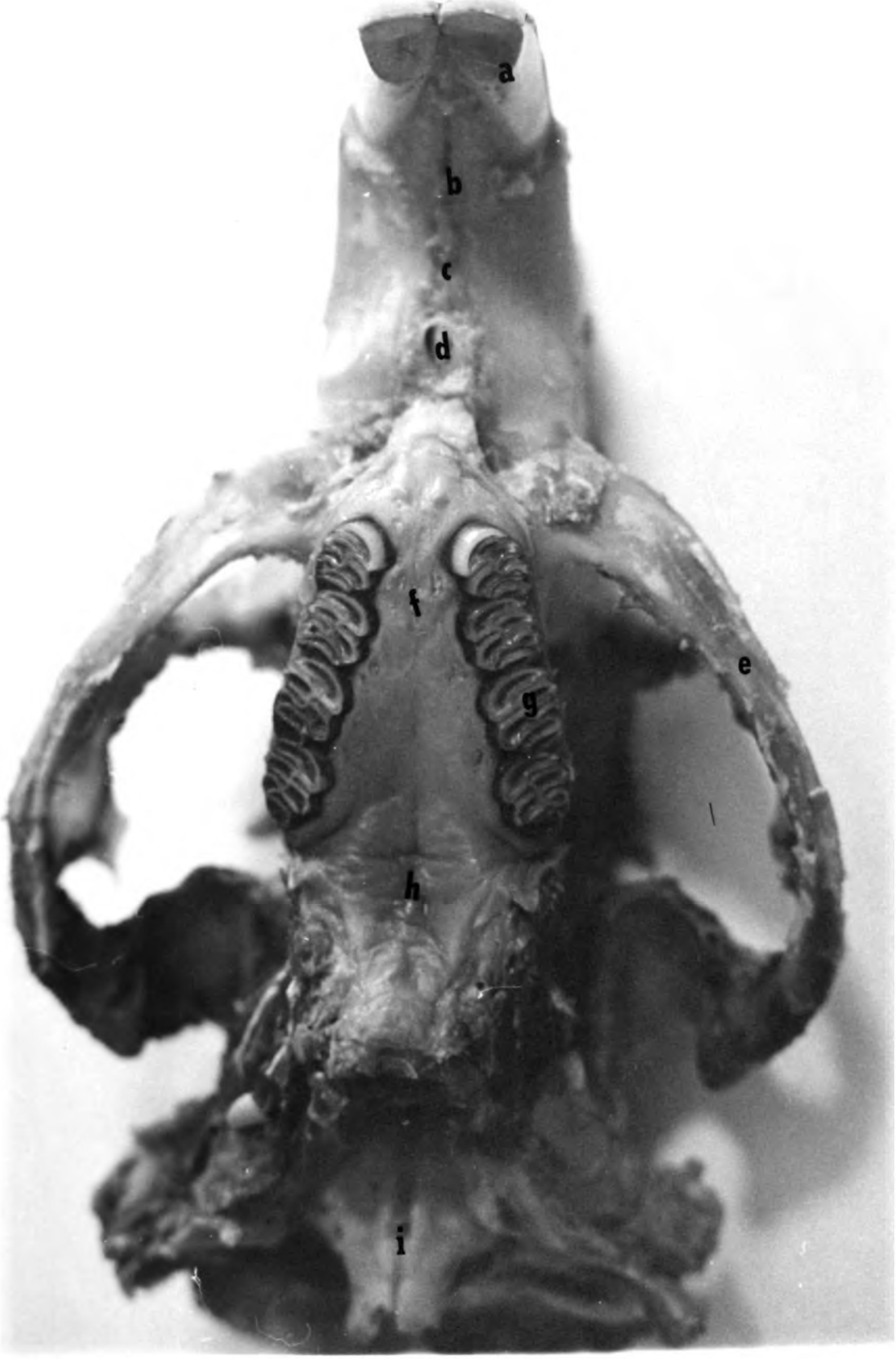
a
b
c
d
e
f
g
h
i

Figure 5. The Medial Surface of the Right Half of the Mandible with the Embedded Portions of Teeth Outlined and Distal End of Incisor Exposed.

a. Incisor

b. Mandibular process

c. Molar

d. Coronoid process

e. Condyle

f. Ramus of mandible

g. Angular process

h. Pterygoid spine

Figure 6. Drawing of Occlusal, Mesial Surface of Molars

a. First molar

b. Second molar

c. Third molar

d. Fourth molar

Figure 7. Ventral View of Urinary Organs

a. Right kidney
b. Renal vein
c. Posterior Vena Cava
d. Abdominal aorta
e. Adrenal gland
f. Left kidney
g. Ureter
h. External iliac artery
i. Urinary bladder
j. Urethra

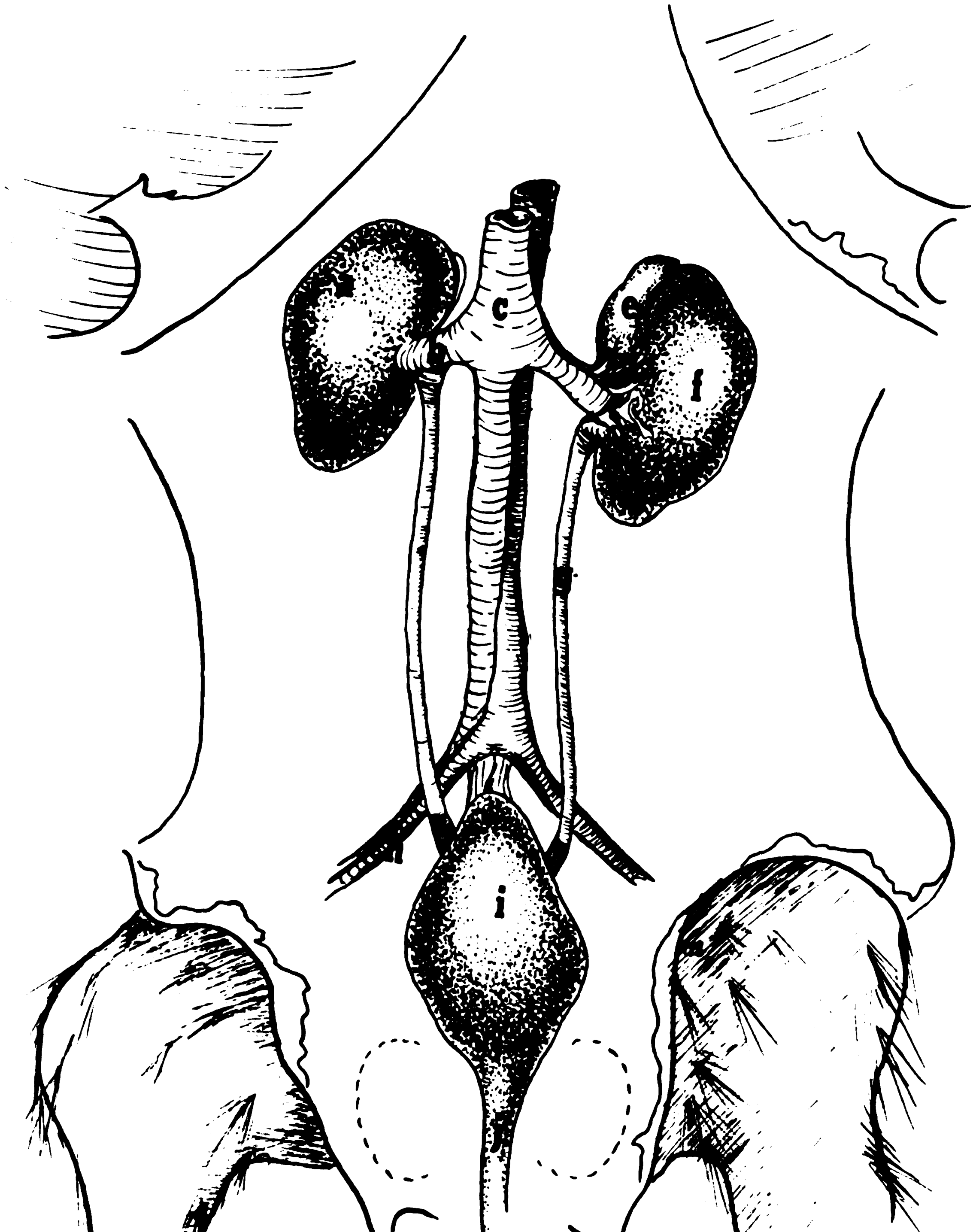
c
e
f
i

Figure 8. Ventral View of Stomach

a. Esophagus

b. Cardiac portion

c. Fundic portion

d. Pyloric

Figure 9. Dorsal View of Stomach

a. Cardiac portion (curved upon itself forming a prominent arch)

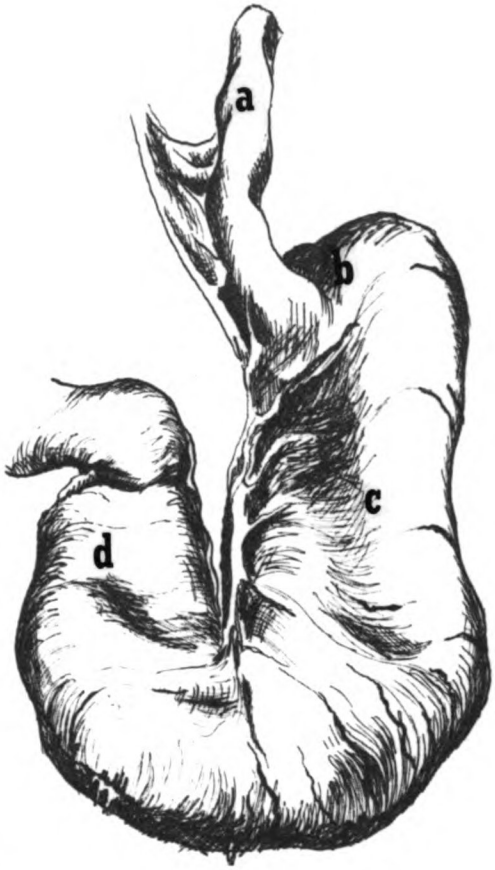
a
b
c
d


a

Figure 10. Dissection Showing Arrangement of Digestive Organs Intact.

a. Liver

b. Small Intestine

c. Large Intestine

d. Cecum


a
b
c
d

Figure 11. Dissection Showing Intestinal Tract.

a. Duodenum

b. Jejenum

c. Ileum

d. Ileo-caecal valve

e. Caeco-colic valve

f. Cecum

g. Large colon (Proximal)

h. Large colon (Terminal)

i. Small colon

j. Rectum

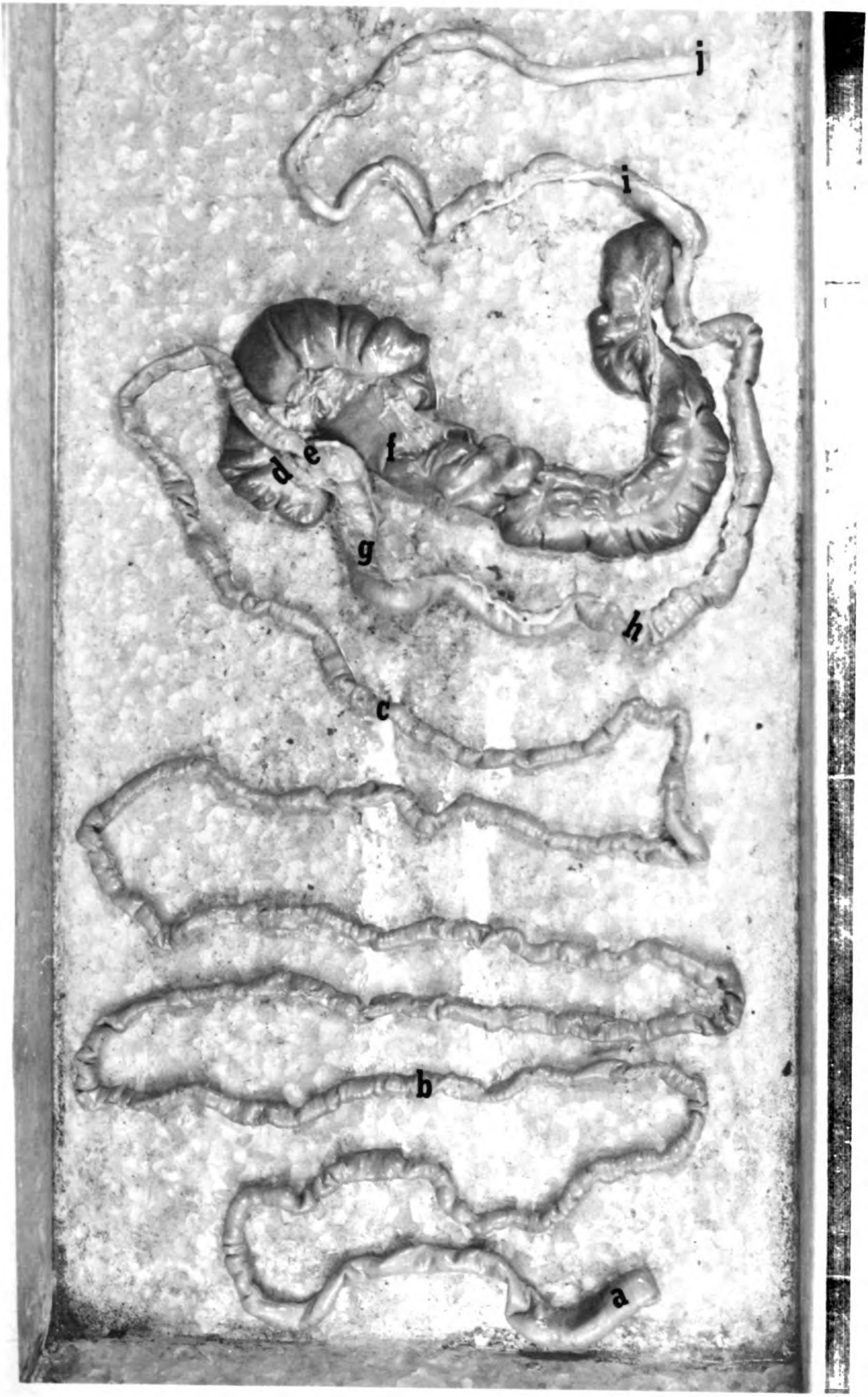
j
i
d
e
f
g
h
c
b
a

Figure 12. Drawing Showing the Relationship of the Alimentary Tract.

a. Esophagus

b. Stomach

c. Spleen

d. Pancreas

e. Duodenum

f. Jejenum

g. Ileum

h. Cecum

i. Large colon (Proximal)

j. Large colon (Terminal loop)

k. Small colon

l. Rectum

m. Anus

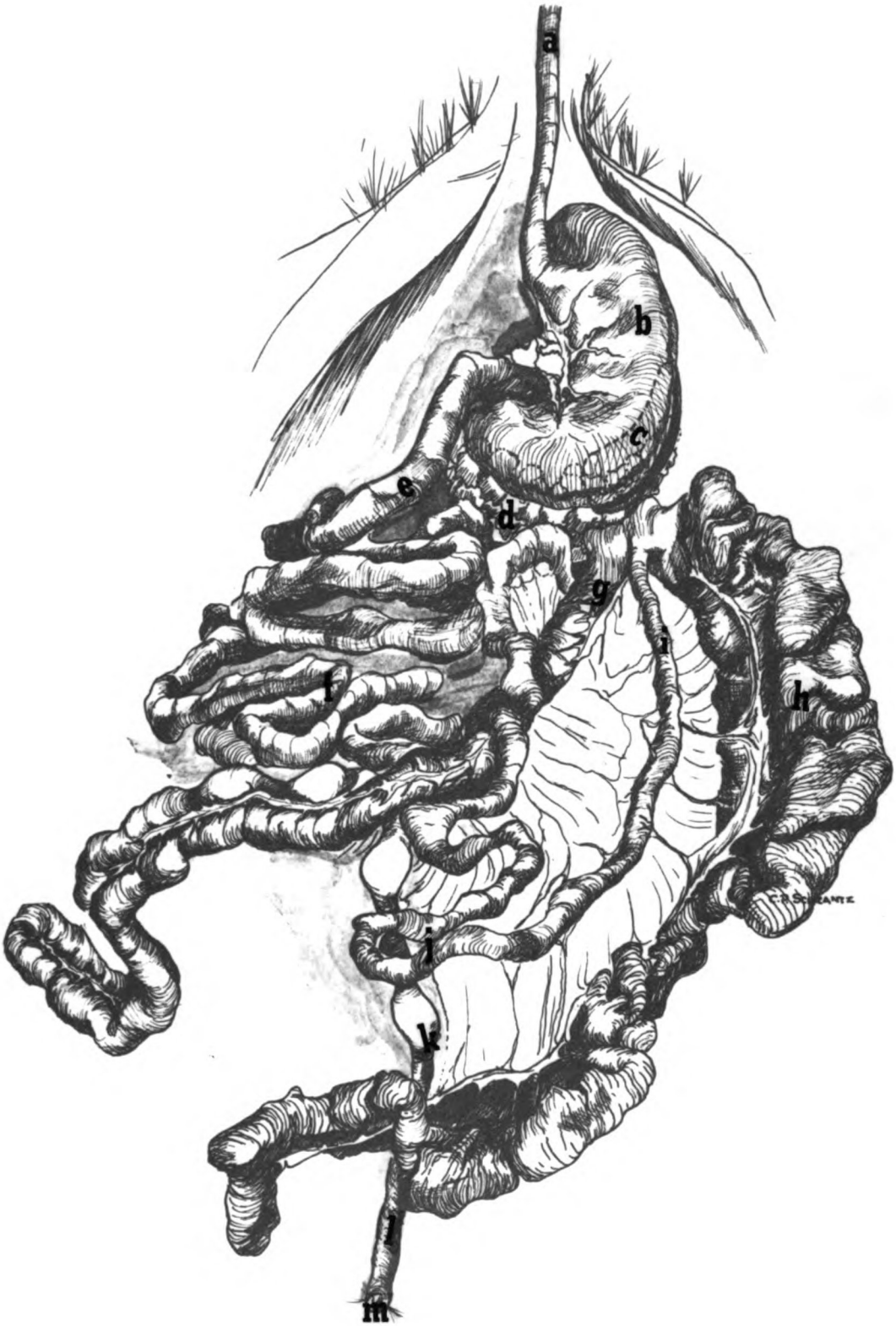
a
b
c
e
d
g
i
f
h
C.P. SCHRANTZ
j
k
l
m

Figure 13. Drawing to Show Fan-Shape Fold of Mesenteric Fold of Small Intestine.

a. Small Intestine

b. Superior mesentery artery

c. Lymph node

d. Mesentery

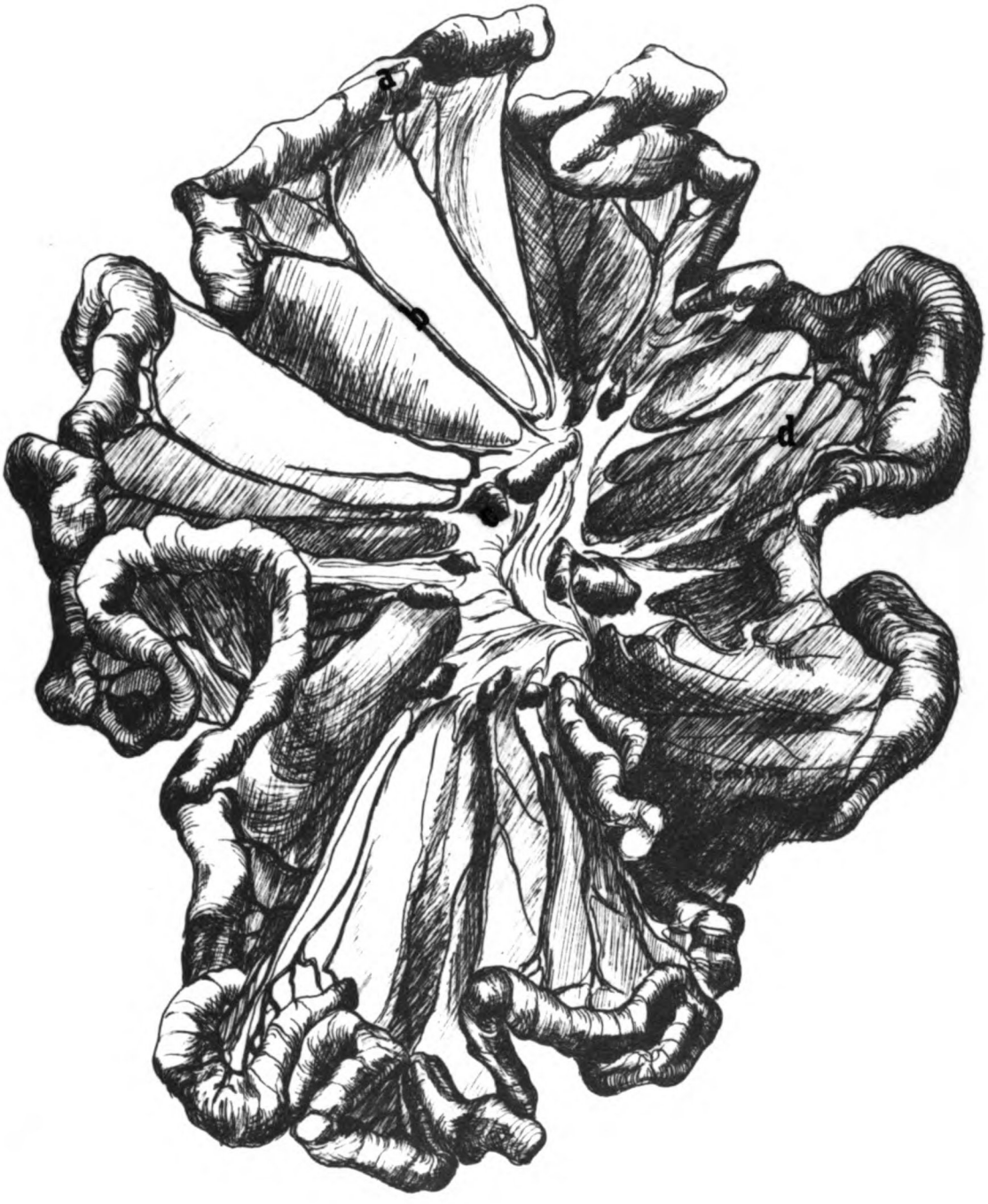
a
b
c
d

Figure 14. Ventral View of Liver

a. Falciform ligament

b. Esophageal notch

c. Portal fissure

d. Diaphragmatic lobe of liver

e. Right caudate lobe

f. Right dorsal lobe

g. Left lobe

Figure 15. Caudal View of Liver

a. Diaphragmatic lobe of liver

b. Gall bladder

c. Left lobe

d. Right dorsal lobe

e. Kidney impression

f. Adrenal impression

g. Right caudal lobe

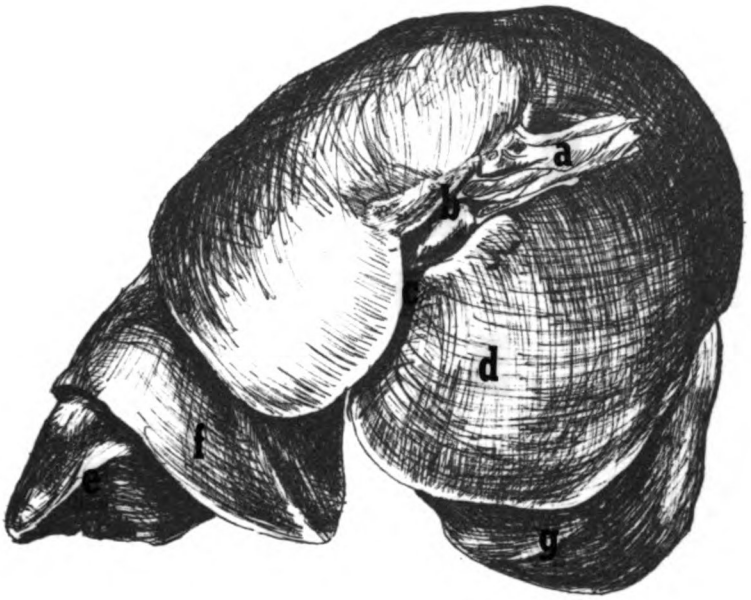
a
b
c
d
f
e
g

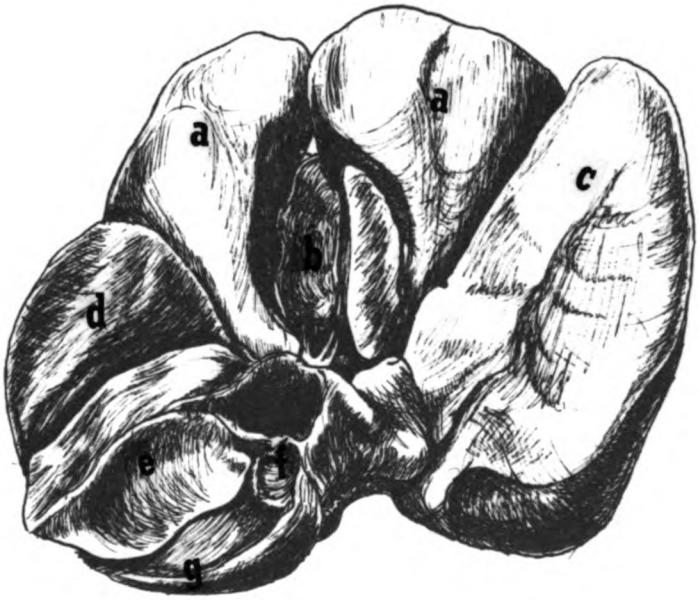
a
a
c
b
d
e
f
g

Figure 16. Section of Parotid Gland. H. and E. 540x.

A. Interlobar duct

B. Interlobular septum

C. Serous acinus

D. Intralobular duct


A
B
C
D

Figure 17. Longitudinal section of submaxillary gland. H. and E. 540x.

A. Striated tubule (salivary duct)

B. Serous acinus

C. Intralobular septum

D. Mucous acinus

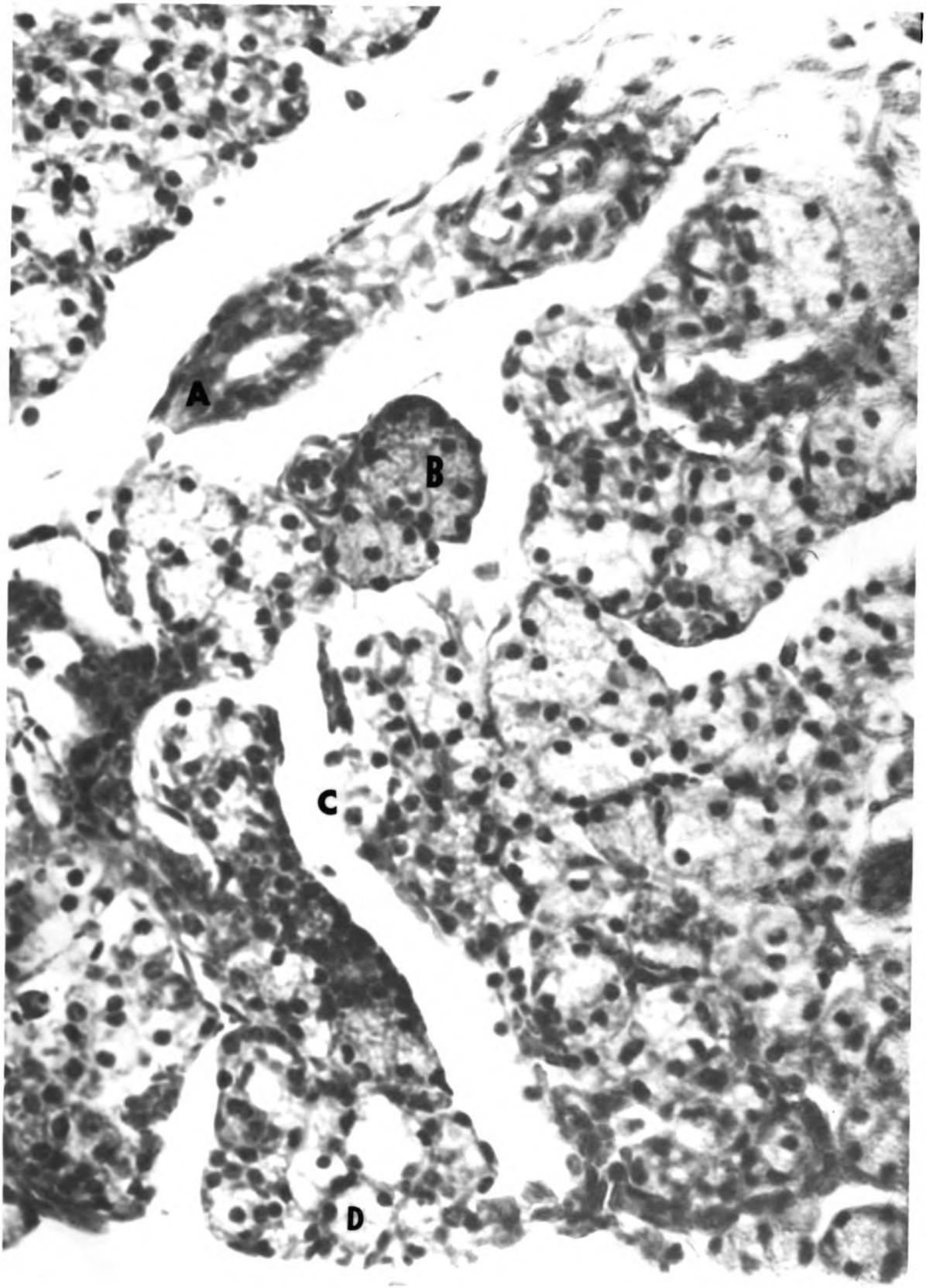
A
B
C
D

Figure 18. Section through sublingual gland. H. and E. 540x.

A. Mucous acinus

B. Intralobular duct

C. Serous acinus

D. Interlobular septum

E. Interlobular duct

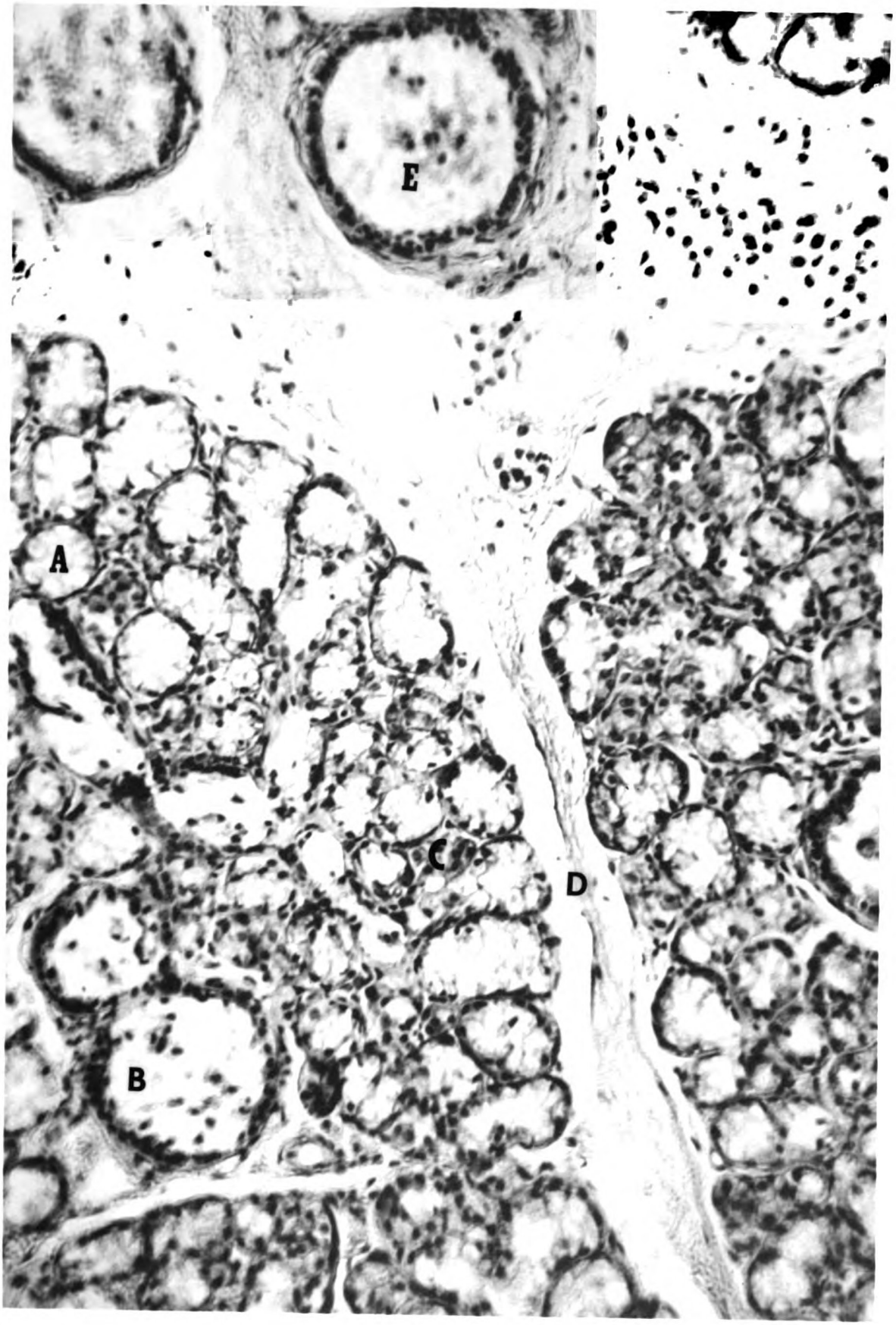
E
A
C
D
B

Figure 19. Transverse section through the oro-pharyngeal wall. H. and E. 850x.

A. Stratified squamous epithelium

B. Lamina propria

C. Skeletal muscle


A
B
C

Figure 20. Transverse section through the anterior portion of the tongue. H. and E. 540x.

A. Filiform papilla

B. Stratified squamous epithelium

C. Lamina propria mucosae

D. Skeletal muscle

E. Vein

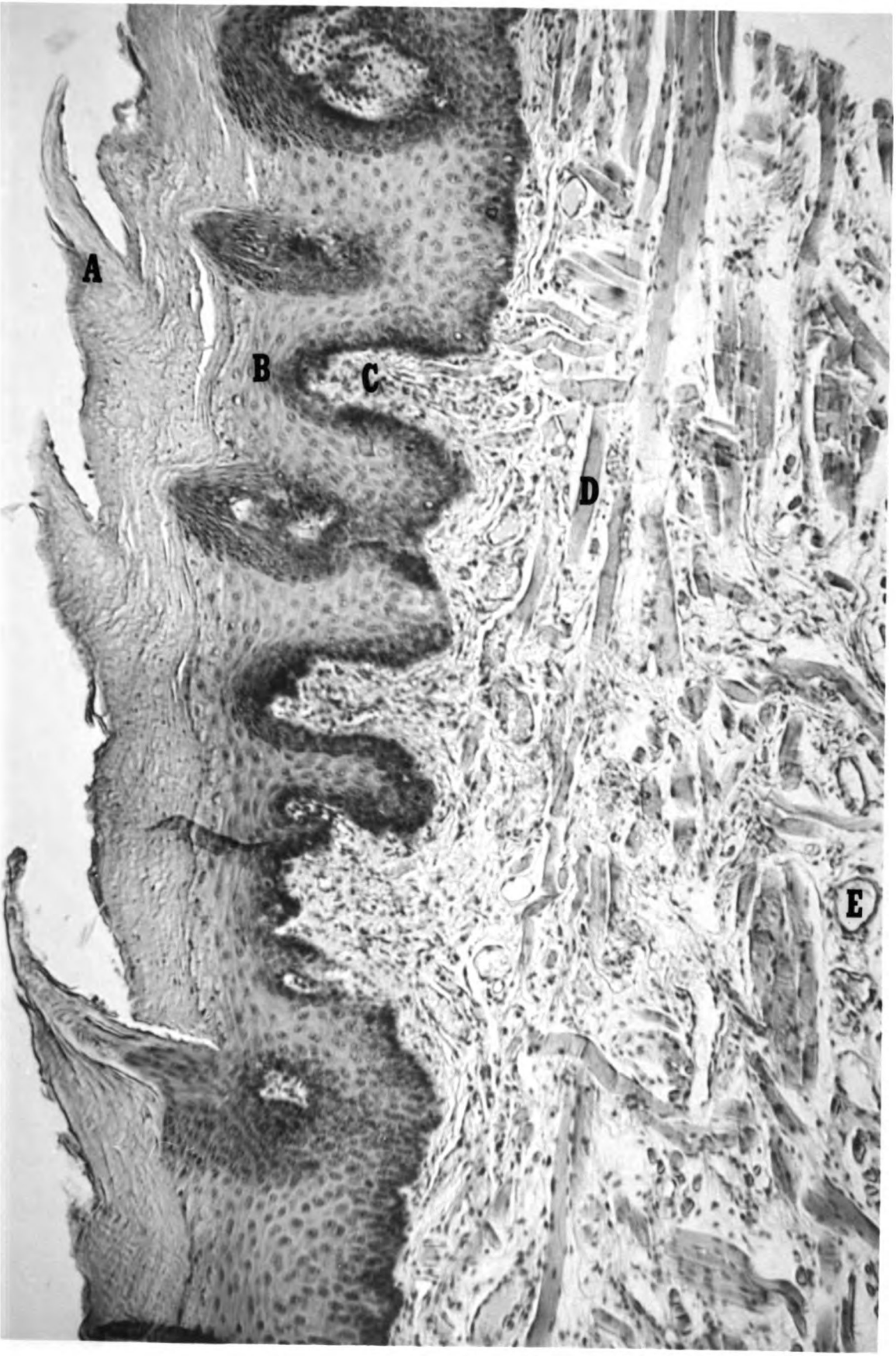
A
B
C
D
E

Figure 21. Transverse section through posterior part of esophagus. H. and E. 42x.

A. Stratified squamous epithelium

B. Lamina propria

C. Mucosa

D. Muscularis mucosae

E. Circular layer of the muscularis externa

F. Submucosa


F
E
C
A
B
D

Figure 22. Section of cardiac region of the stomach. Masson's. 540x.

A. Muscularis externa

B. Submucosa

C. Muscularis mucosae

D. Cross section of cardiac gland

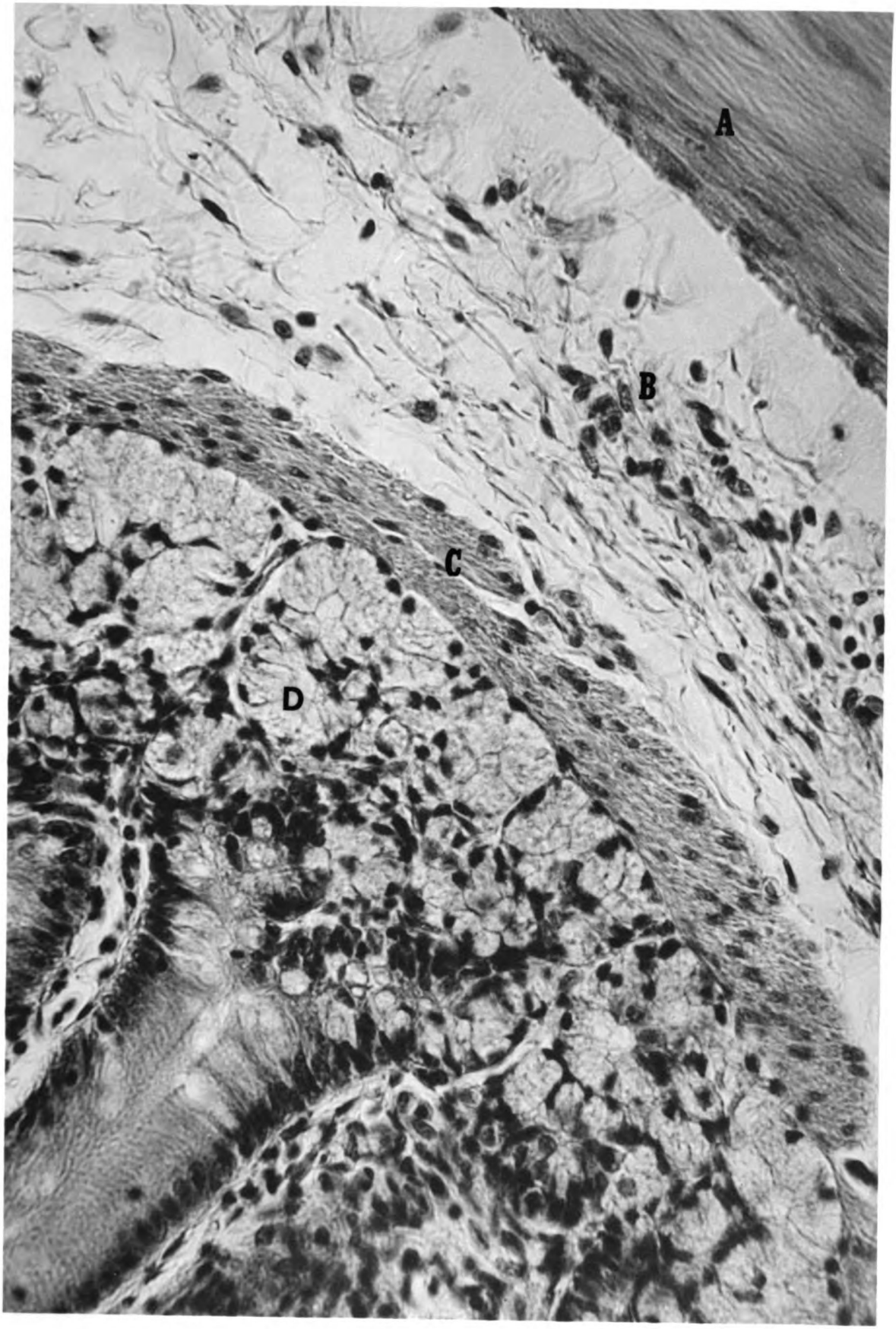
A
B
C
D

Figure 23. Transverse section of stomach showing rugae. Periodic acid-Schiff. 35x.

A. Serosa

B. Muscularis externa

C. Submucosa

D. Muscularis mucosae

E. Mucosa

F. PAS positive surface epithelium

G. Rugae

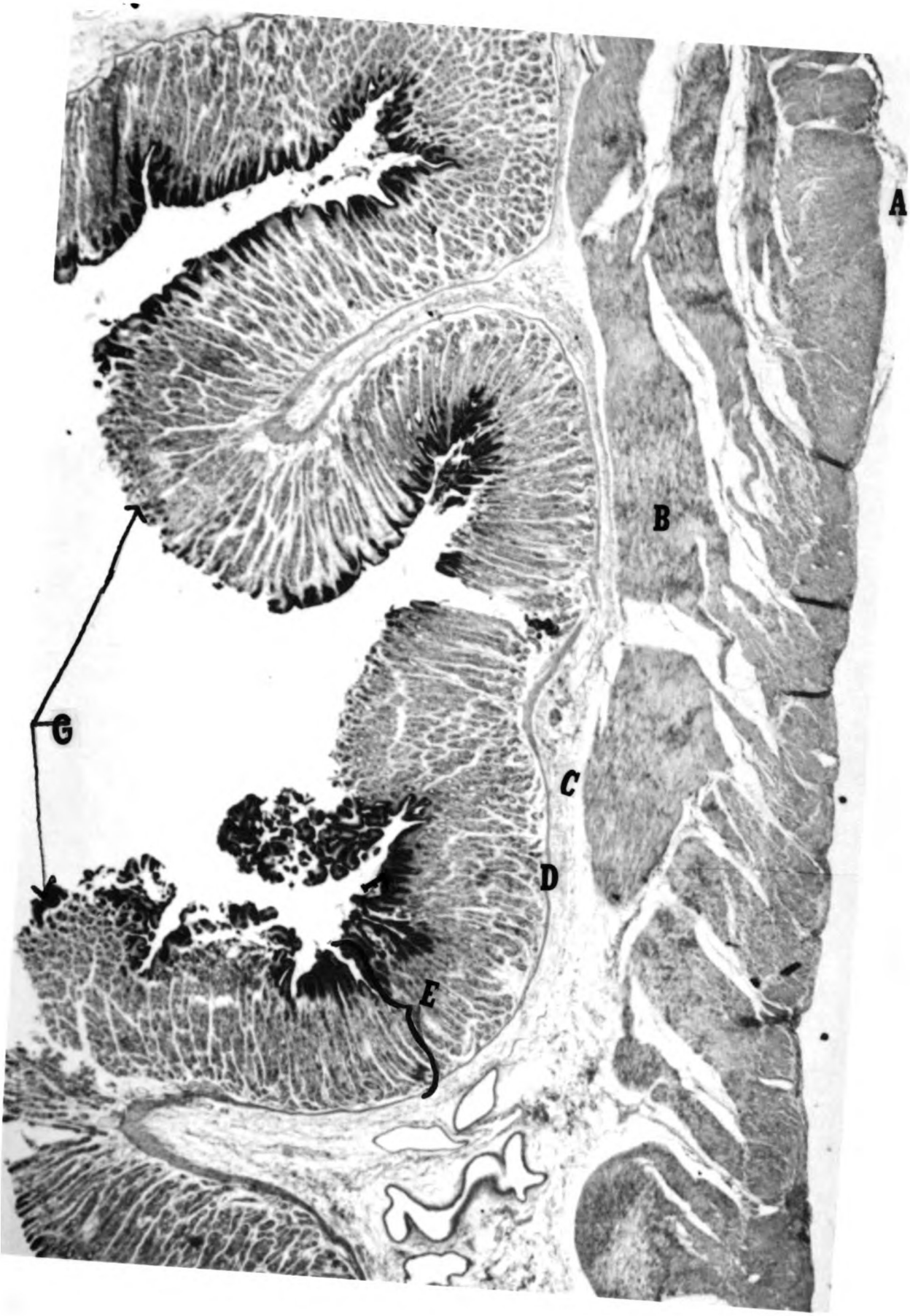
A
B
G
C
D
E

Figure 24. Longitudinal section of duodenum. Periodic-acid Schiff. 100x.

A. Circular layer of the muscularis externa

B. Submucosa

C. Brunner's gland in submucosa

D. Muscularis mucosae

E. Crypt of Lieberkuhn

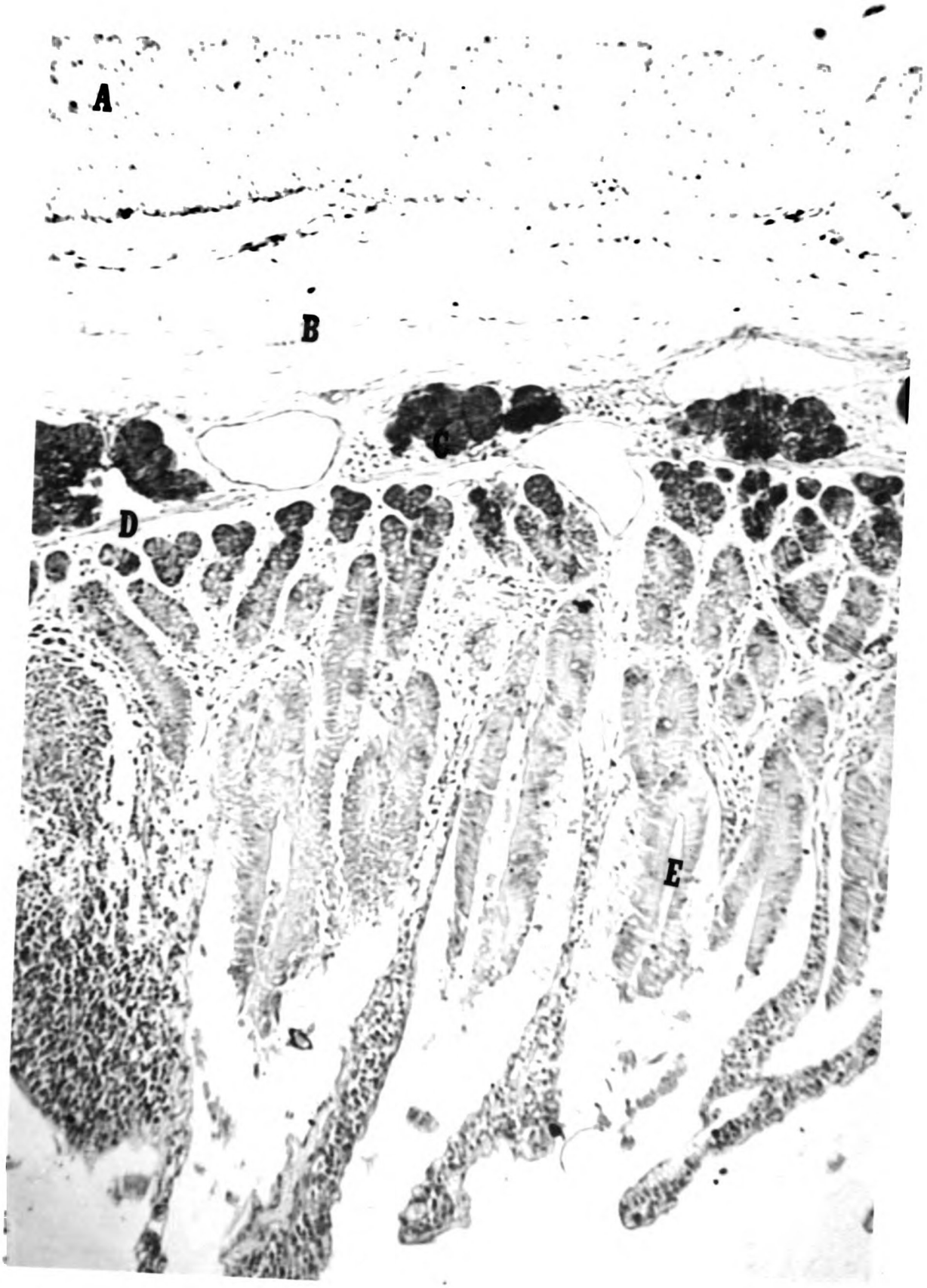
A
B
C
D
E

Figure 25. Section of duodenum showing crypt of Lieberkuhn with surrounding lamina propria, goblet cells and Brunner's gland. Periodic acid-Schiff. 540x.

A. Brunner's gland

B. Lamina propria

C. Goblet cell

D. Crypt of Lieberkuhn


A
B
C
D

Figure 26. A Crypt of Lieberkuhn with surrounding lamina propria. Periodic acid-Schiff. 1440x.

A. Lamina propria

B. Goblet cell

C. Paneth cells

D. Crypt

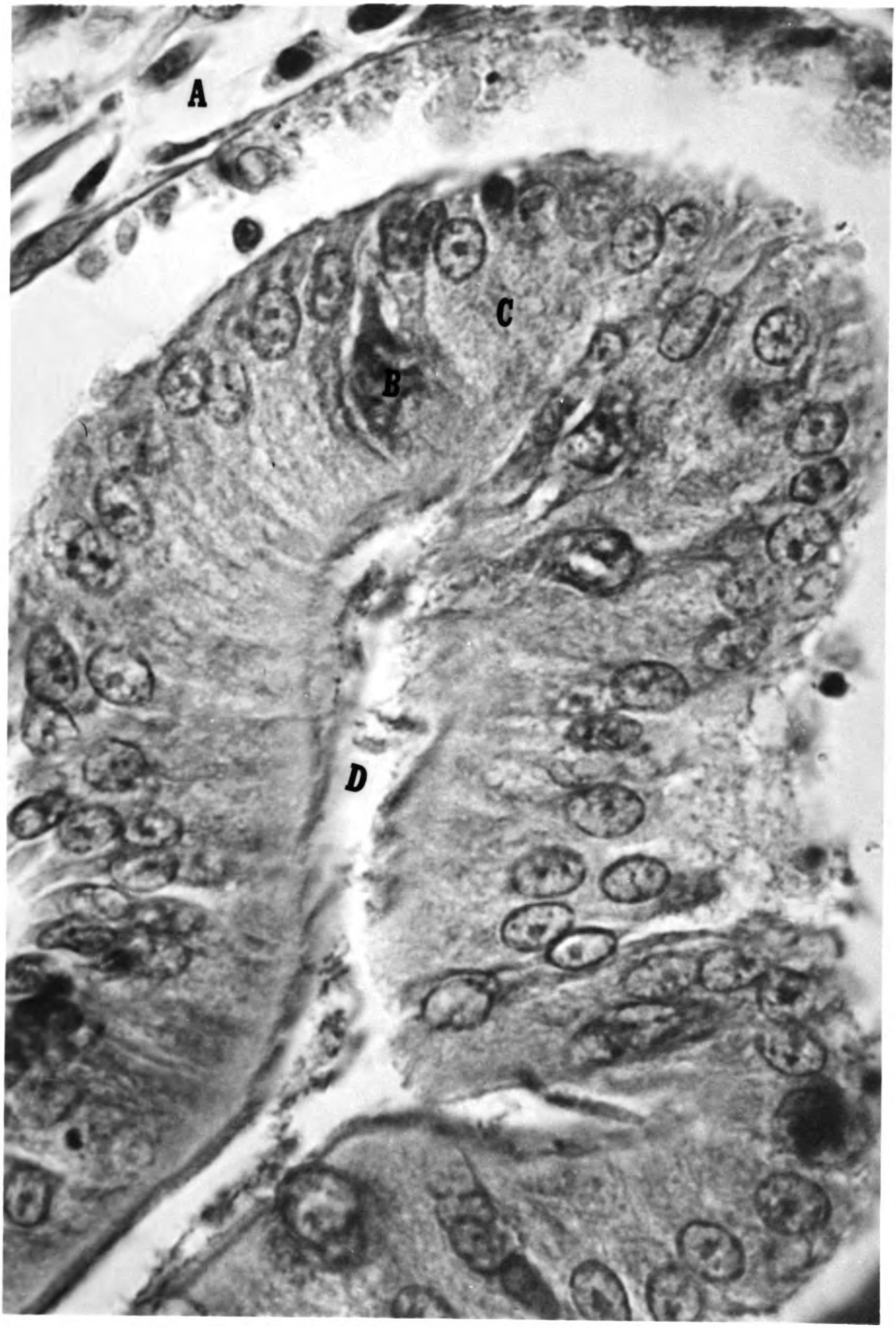
A
B
C
D

Figure 27. Transverse section of large intestine. H. and E. 70x.

A. Muscularis externa

B. Submucosa

C. Muscularis mucosae

D. Mucosa

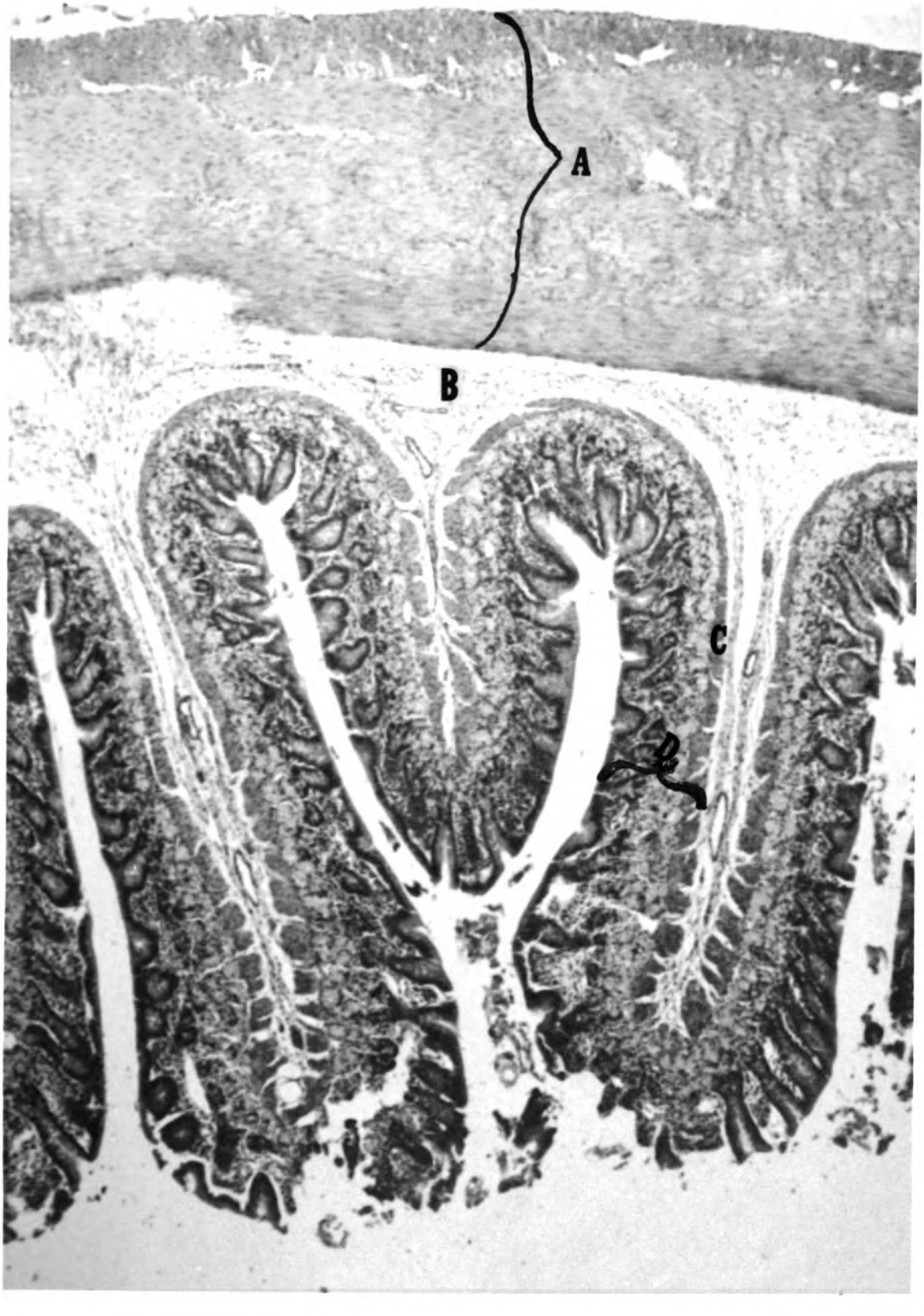
A
B
C
D

Figure 28. Section of large intestine (small colon) Periodic acid-Schiff. 100x.

A. Muscularis externa

B. Submucosa

C. Muscularis mucosae

D. Mucosa

E. Epithelium showing goblet cells

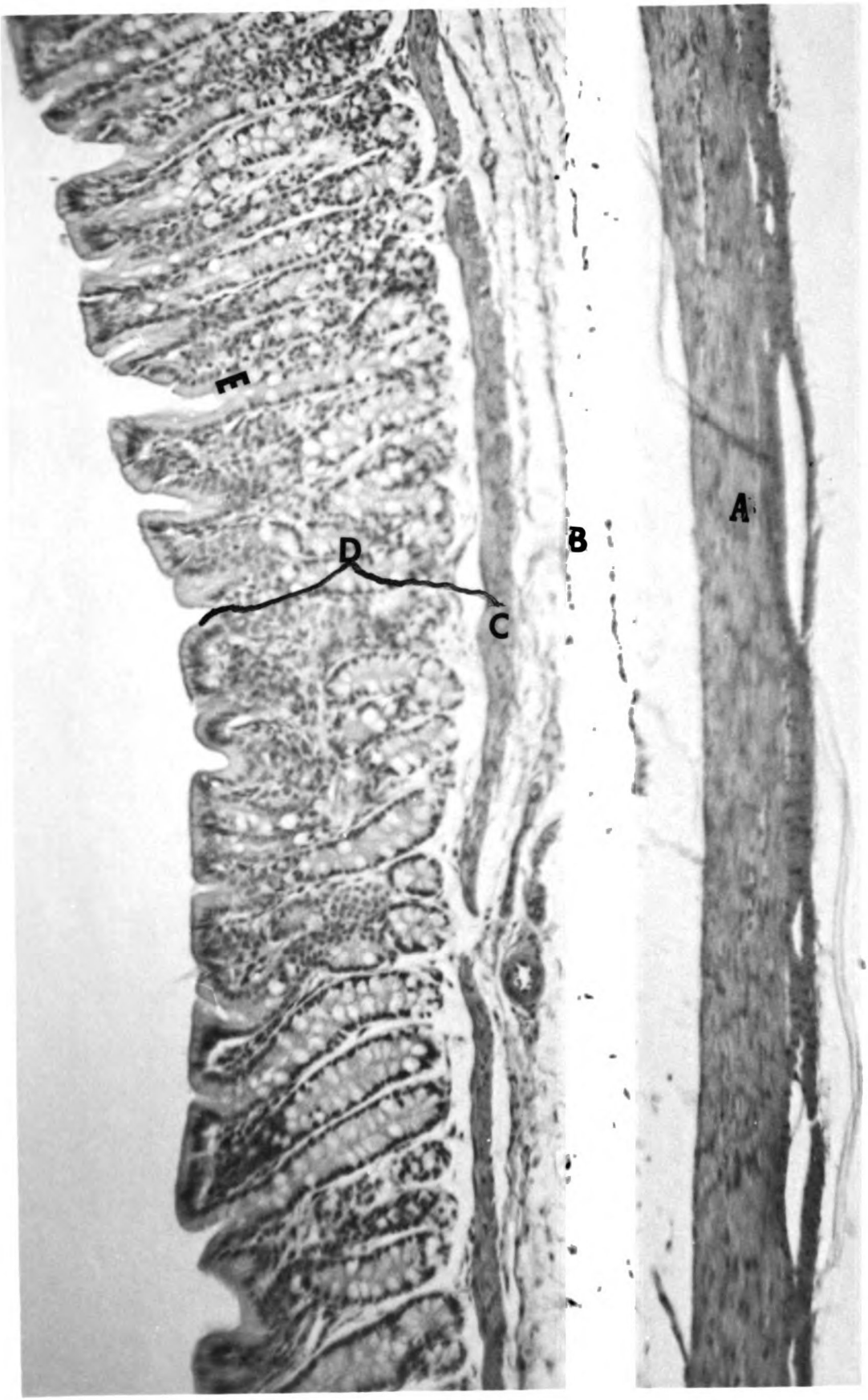
E
D
C
B
A

Figure 29. Section of large intestine showing goblet cells, crypts and epithelium with striated border (microvilli). Periodic acid-Schiff. 540x.

A. Goblet cell

B. Crypt

C. Epithelium with striated border (microvilli)

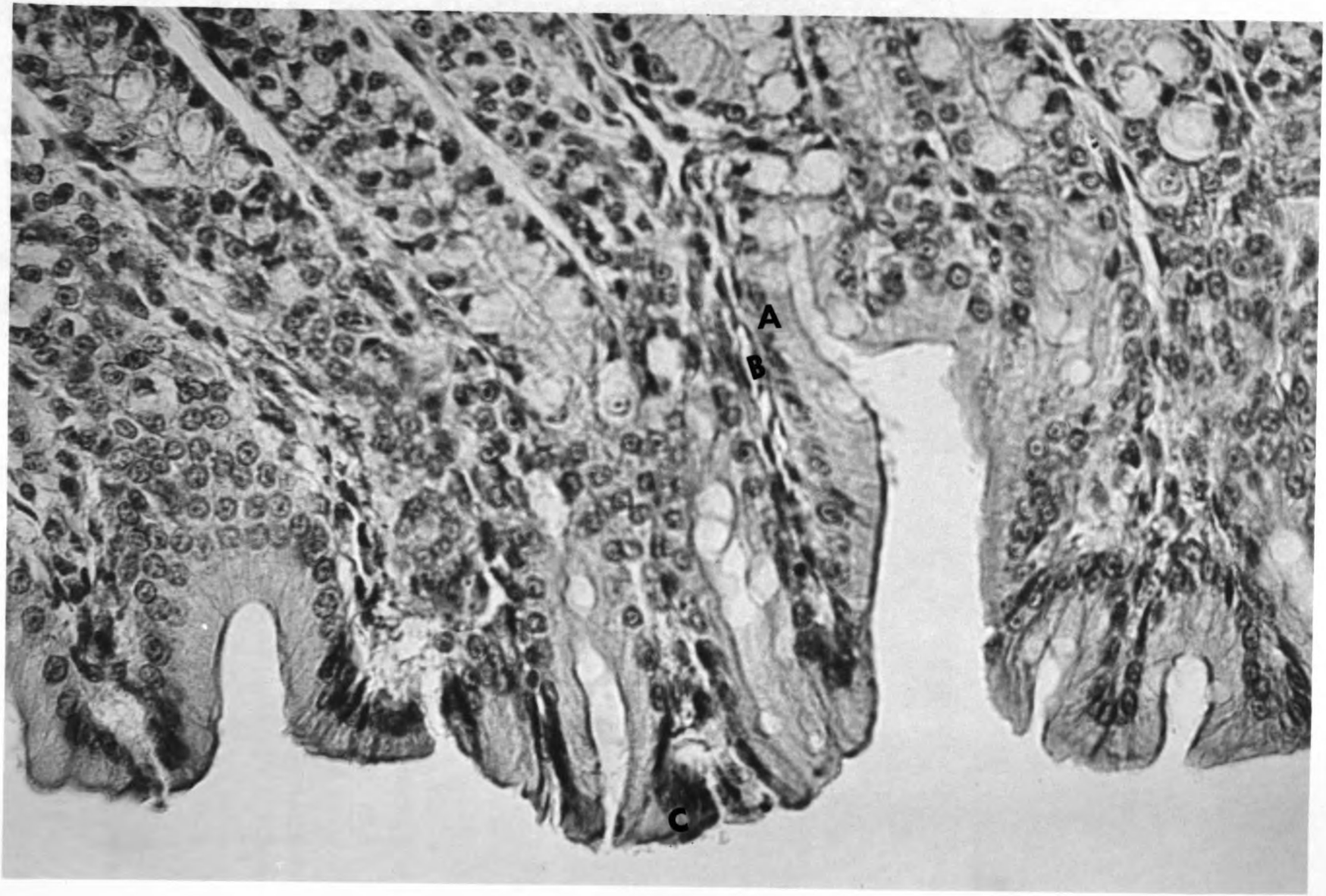
A
B
C

Figure 30. Longitudinal section of proximal cecum. H. and E. 200x.

A. Serosa

B. Muscularis externa

C. Submucosa

D. Muscularis mucosae

E. Mucous membrane.

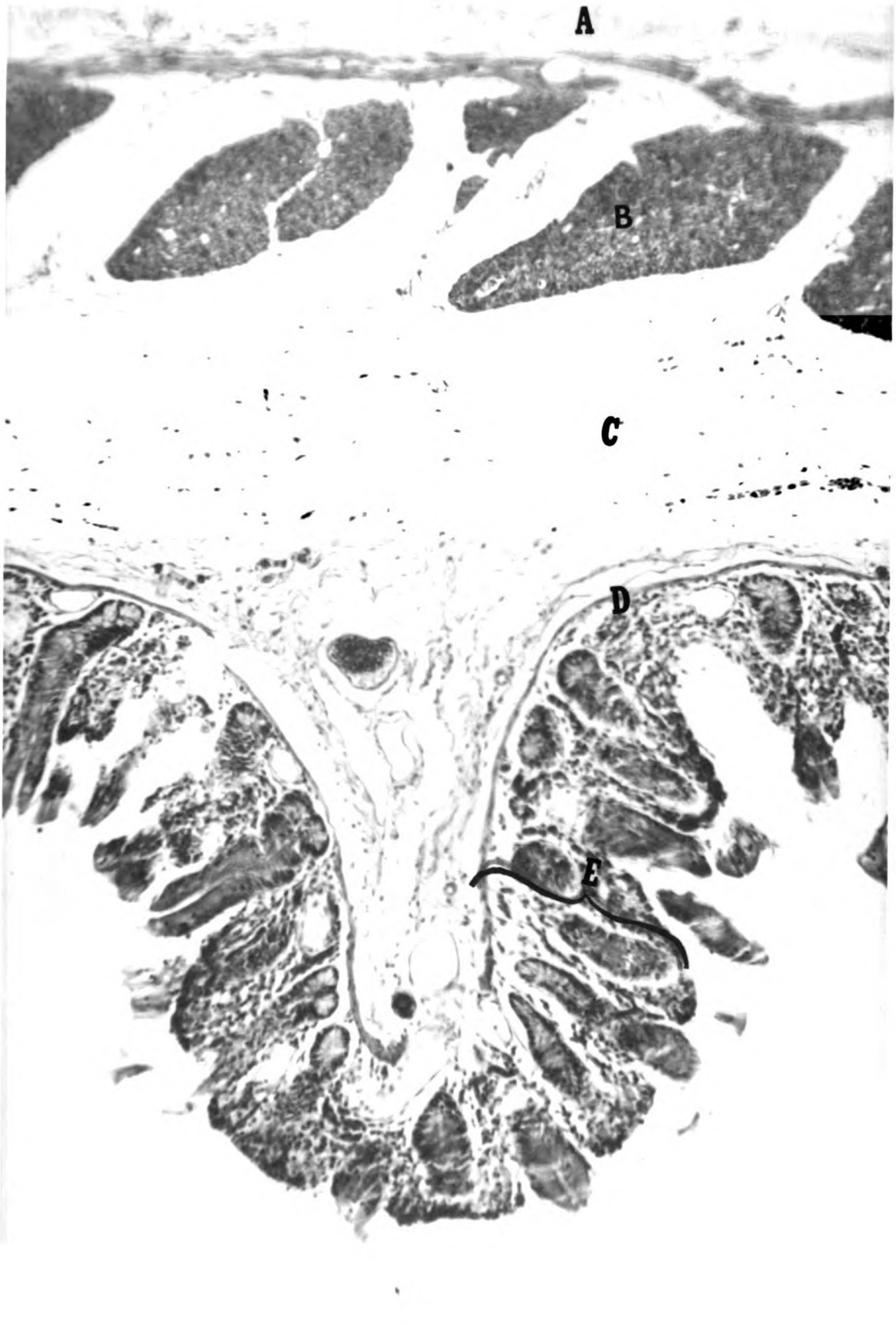
A
B
C
D
E

Figure 31. Section through pancreas. H. and E. 540x.

A. Intralobular septum

B. Islet

C. Acinus

D. Intralobular duct

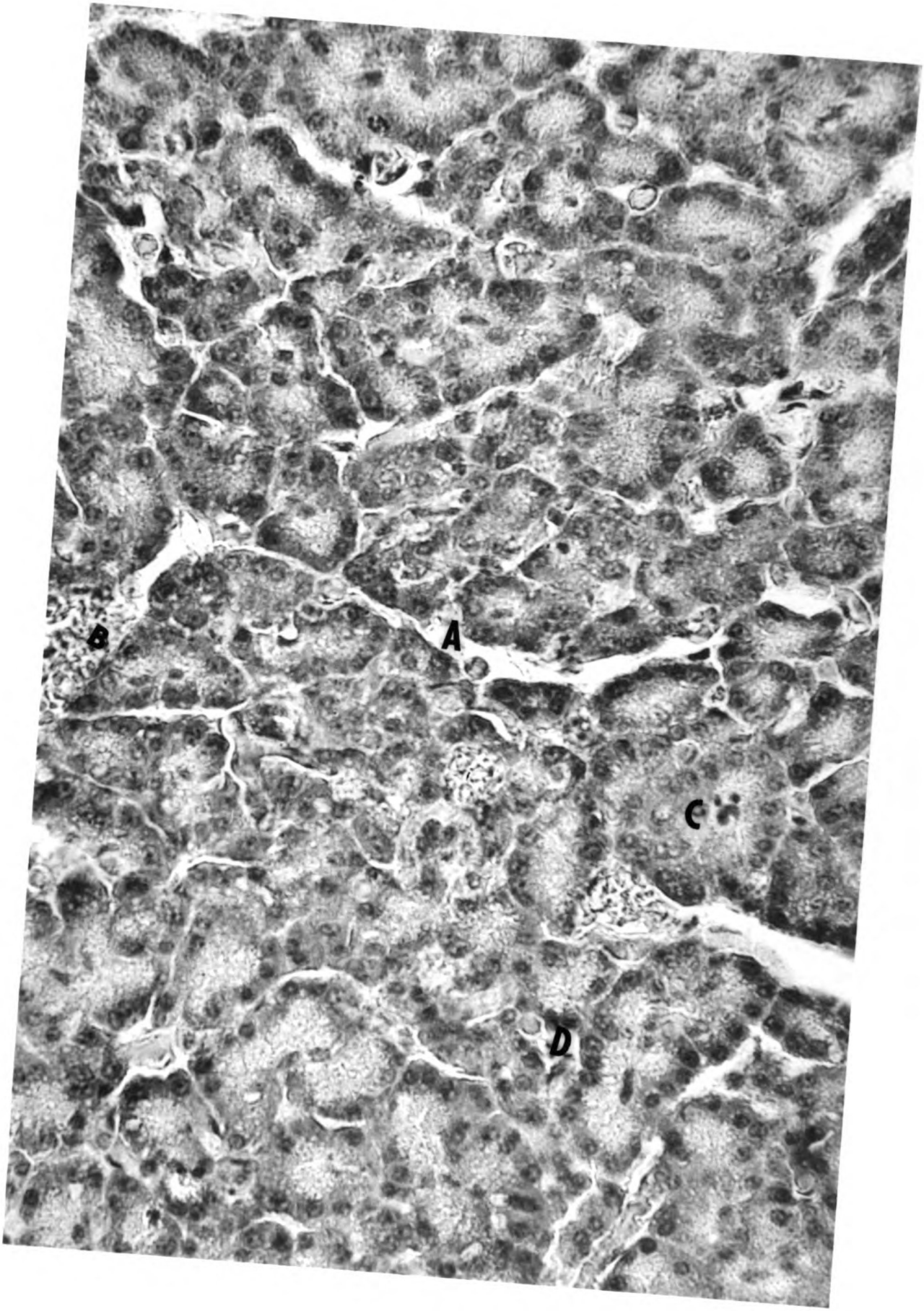
B
A
C
D

Figure 32. Section of Spleen. H. and E.

A. Serosa

B. White pulp

C. Red pulp

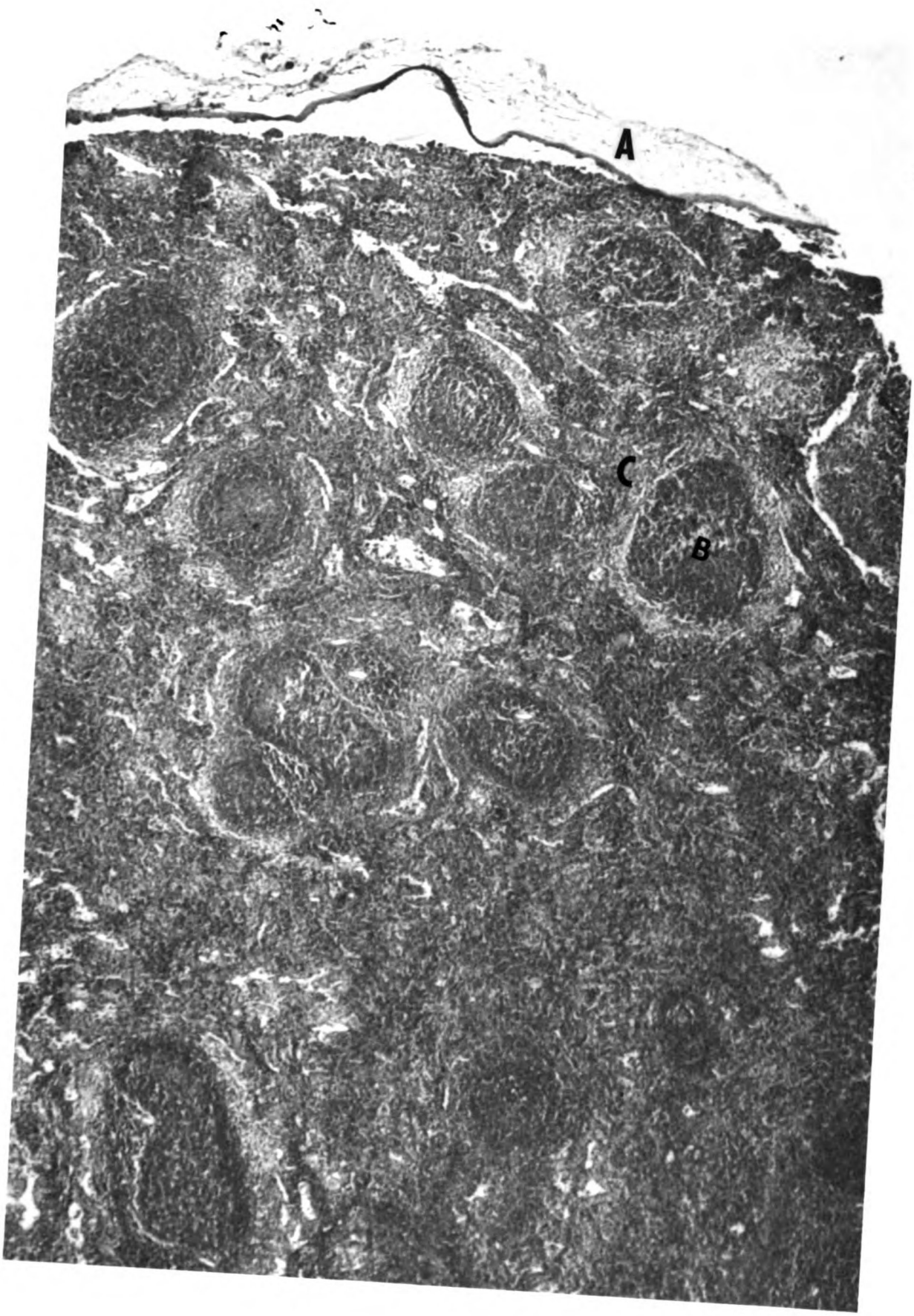
A
C
B

Figure 33. Section of spleen showing capsule, white pulp and trabeculae. (Serosa removed). H. and E. 540x.

A. Capsule

B. Trabeculae

C. White pulp

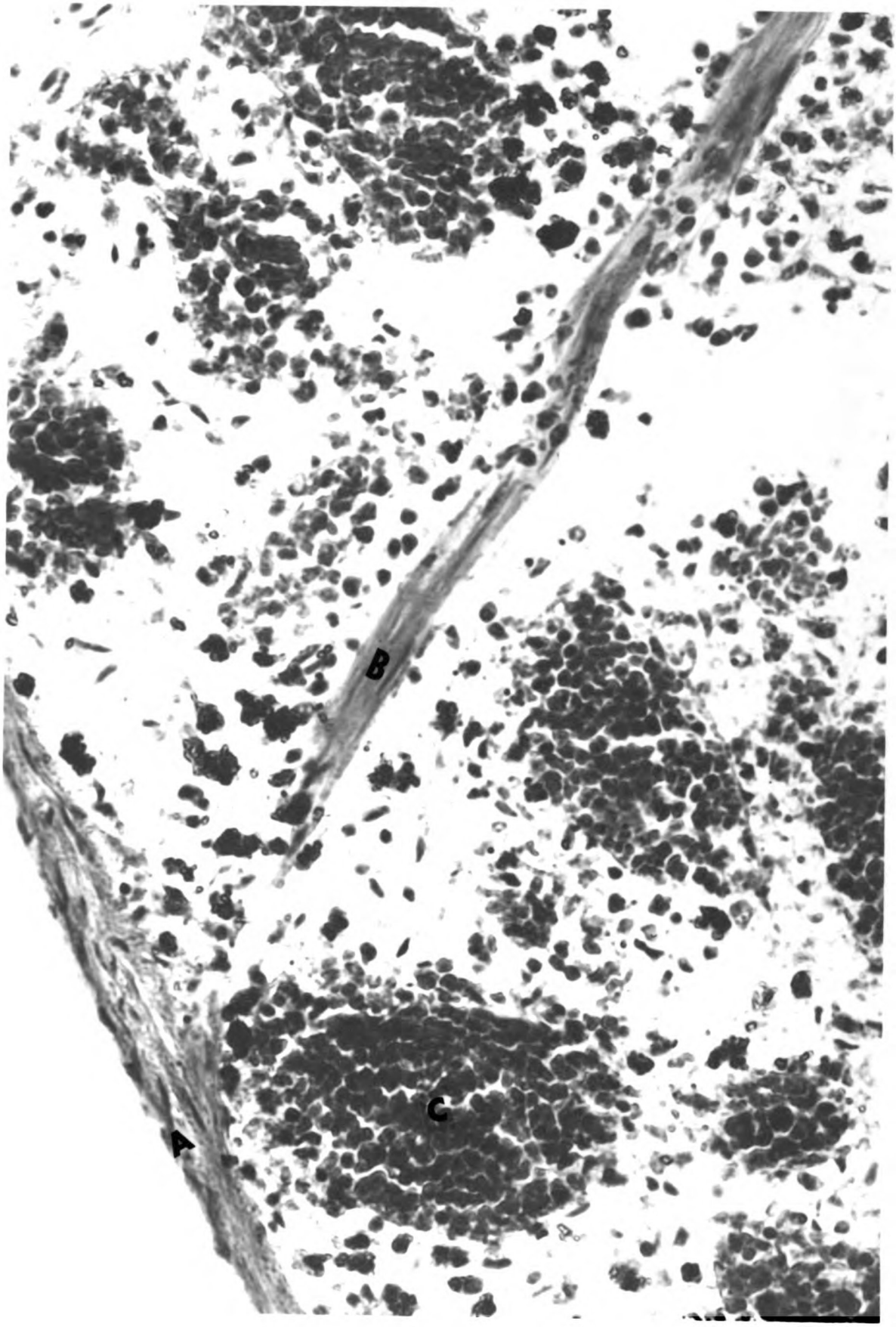
B
C
A

Figure 34. Section through gall bladder. H. and E. 540x.

A. Simple columnar epithelium

B. Lamina propria

C. Smooth muscle


A
B
C

Figure 35. Section through gall bladder showing gland (A). H. and E. 540x.


A

Figure 36. Section through kidney showing glomerulus. Periodic acid-Schiff. 850x.

A. Intralobular artery

B. Collecting tubule

C. Parietal layer of Bowman's capsule

D. Bowman capsule cavity

E. Visceral layer of Bowman's capsule

F. Glomerulus

G. Capillary


A
B
C
F
E
D
G

Figure 37. Section through kidney showing collecting tubules with PAS positive basement membrane. Periodic acid-Schiff. 540x.

A. Basement membrane (PAS positive)

B. Proximal tubule

C. Distal tubule

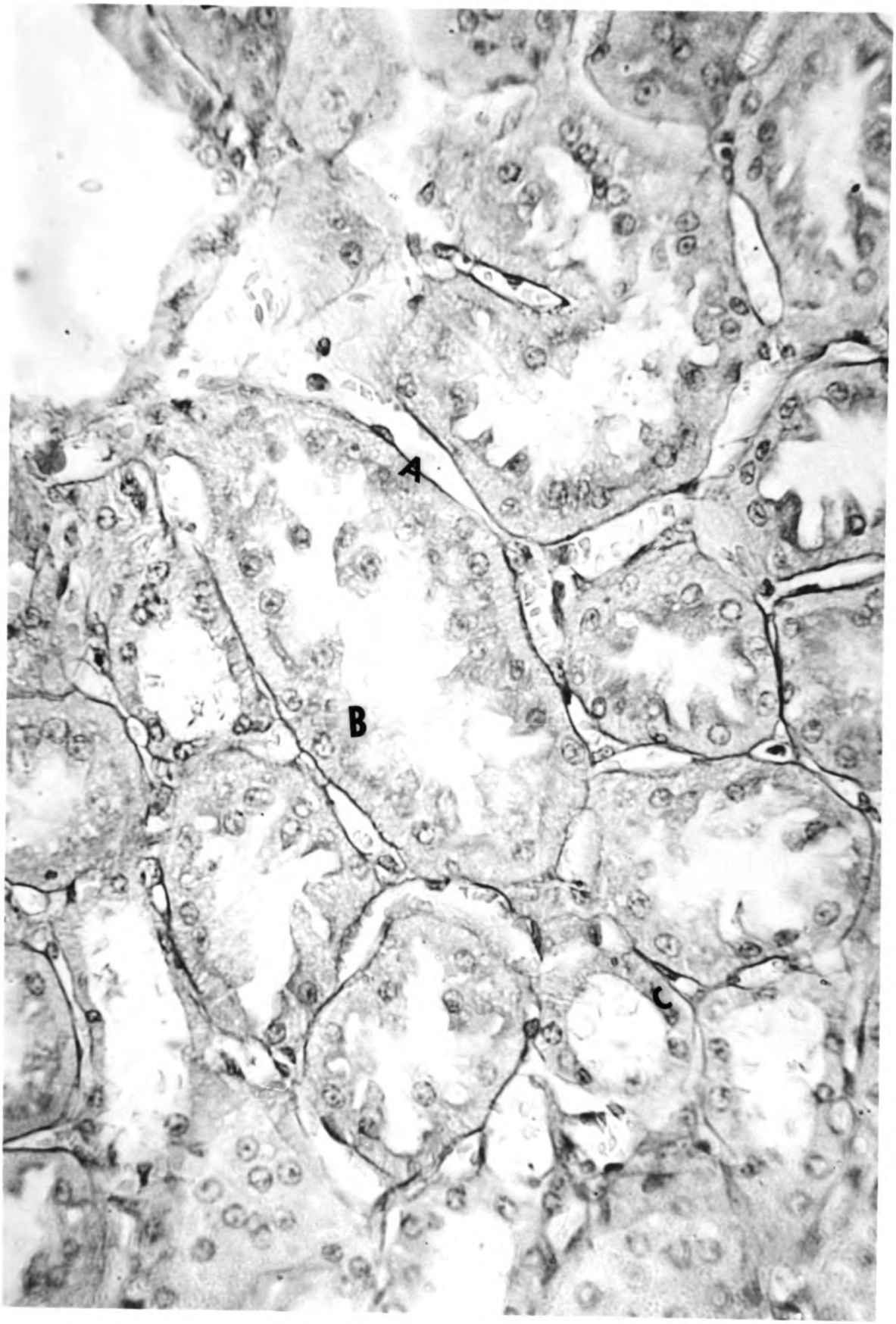
A
B
C

Figure 38. Longitudinal section through the ureter. H. and E. 270x.

A. Connective tissue

B. Transitional epithelium

C. Inner longitudinal smooth muscle

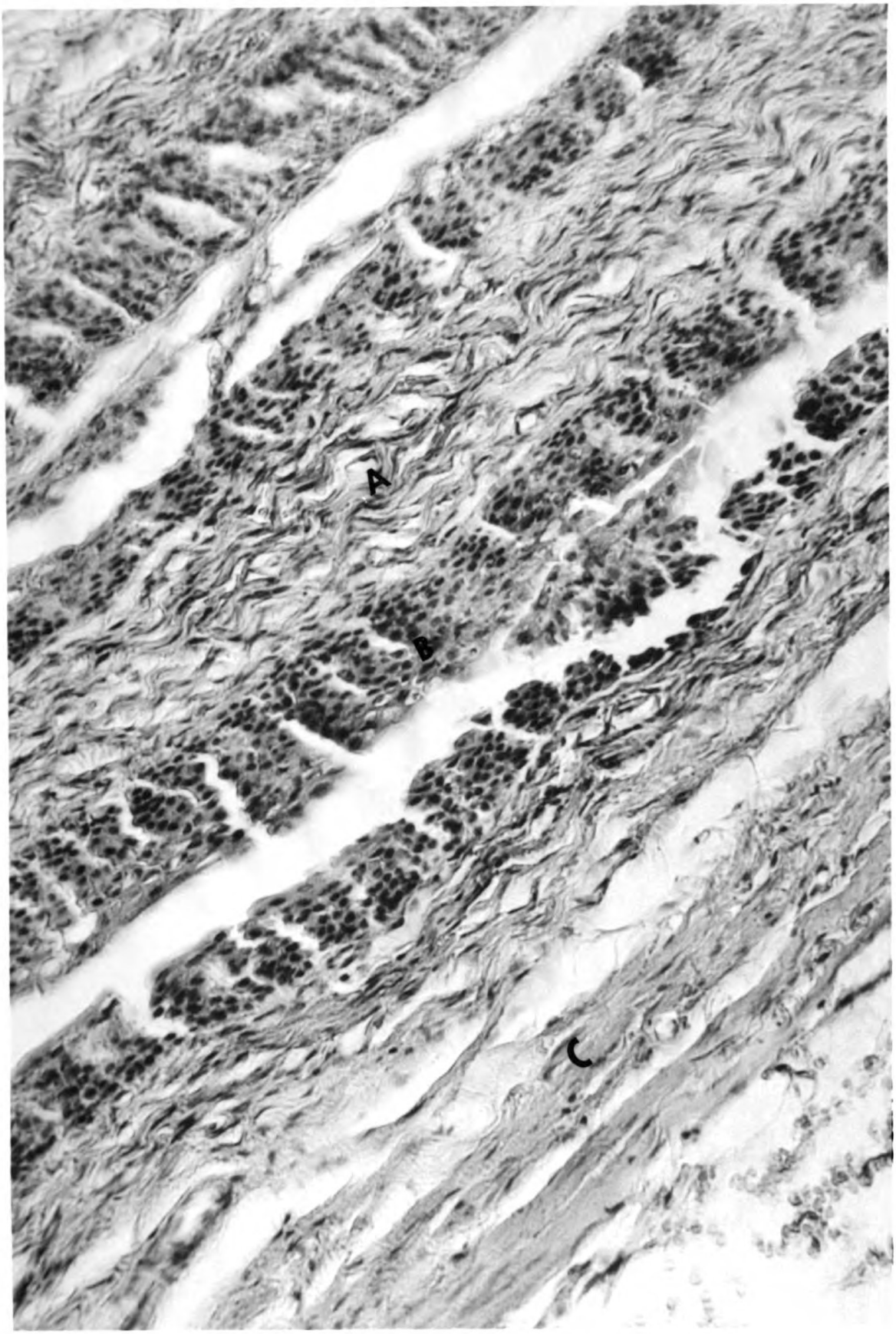
A
B
C

Figure 39. Cross section of ureter. H. and E. 540x.

A. Transitional epithelium

B. Lamina propria

C. Inner longitudinal smooth muscle

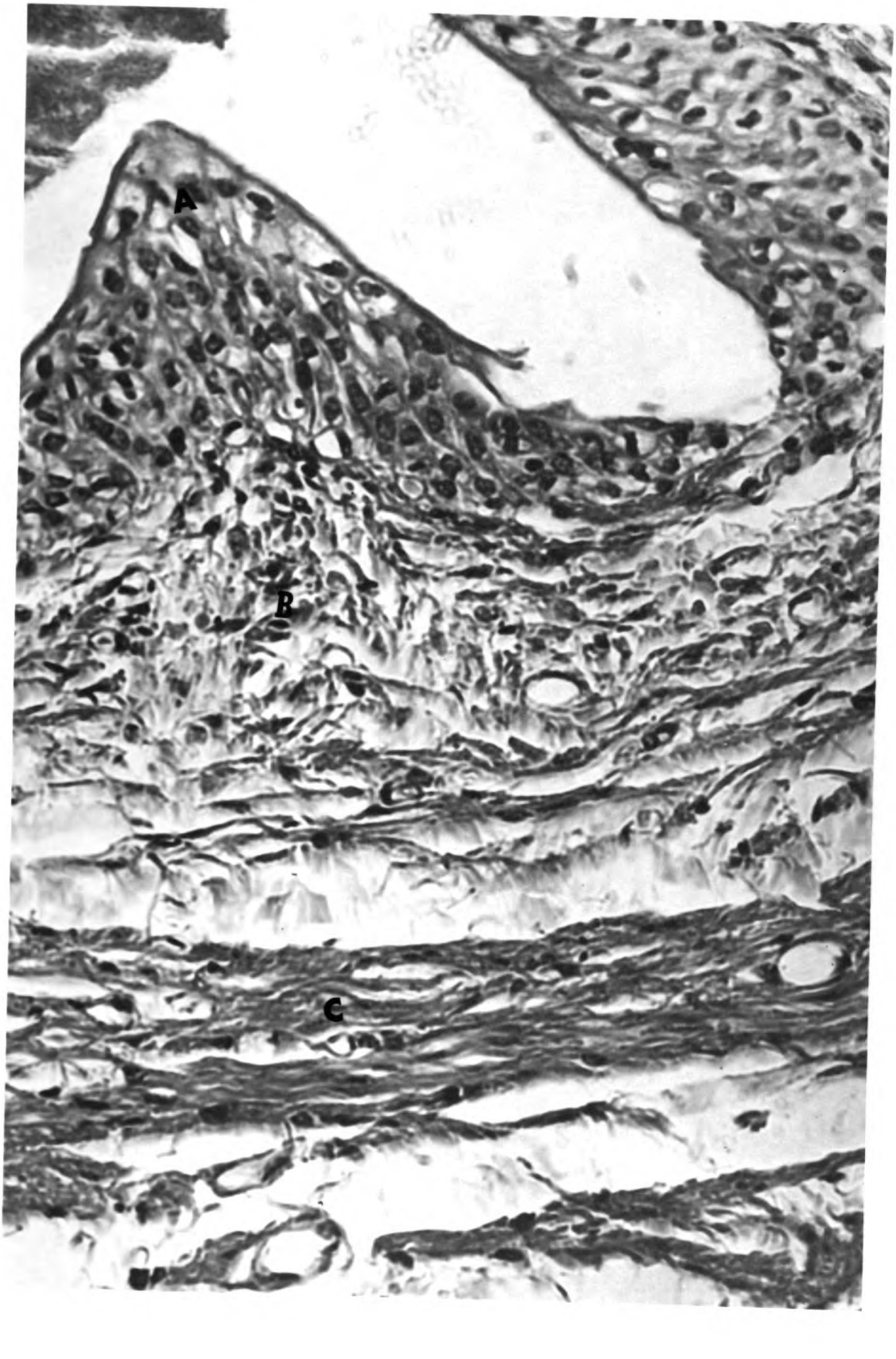
A
B
C

Figure 40. Section through urinary bladder. Masson's. 540x.

A. Transitional epithelium

B. Lamina propria

C. Blood vessel


A
B
C

Figure 41. Section through testes. H. and E. 540x.

A. Basement membrane

B. Lumen of seminiferous tubule

C. Spermatogonium

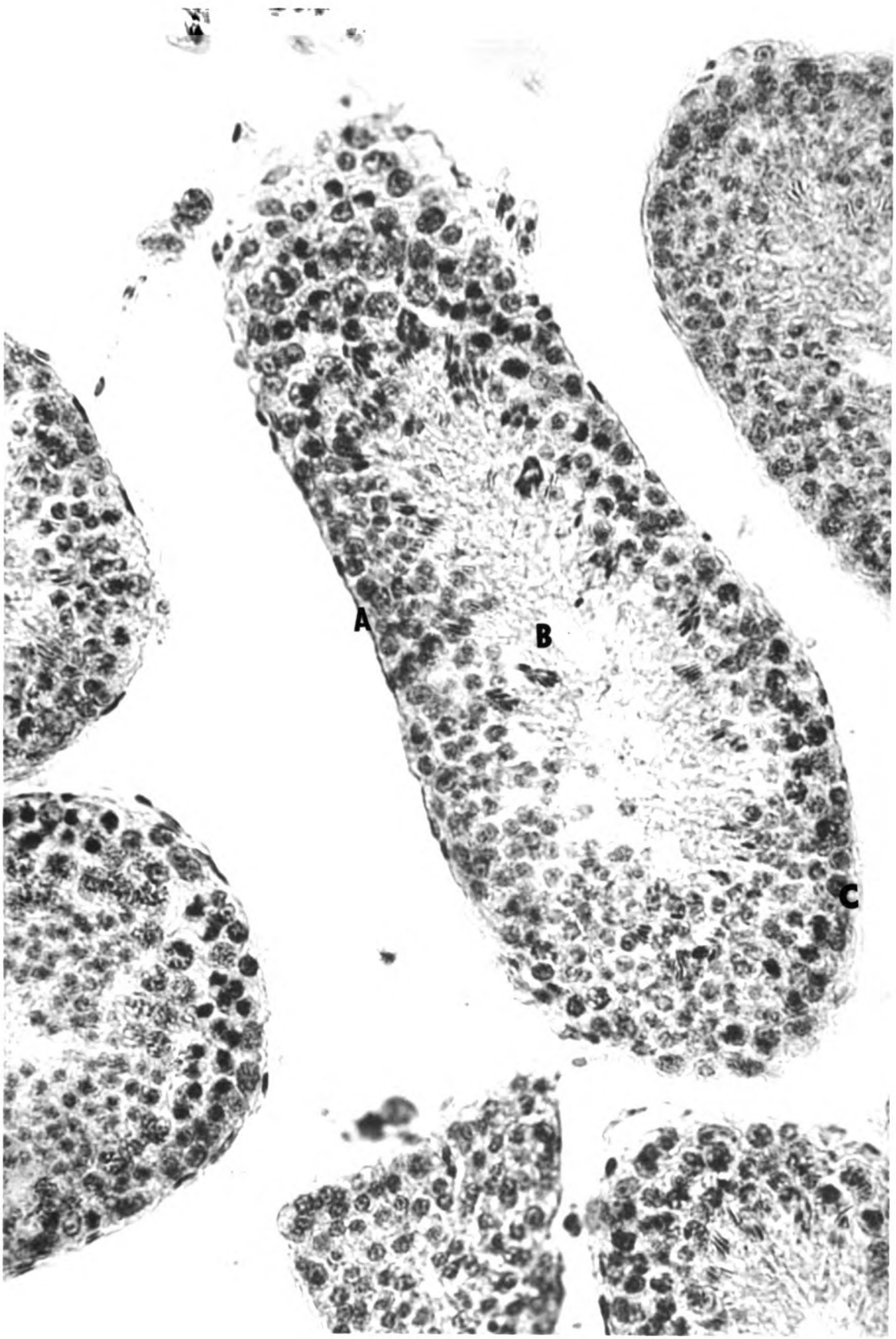
A
B
C

Figure 42. Section of ductus epididymis showing sterocilia of tall epithelium lining cells (A) and large blood vessel (B). H. and E. 540x.

Figure 43. Transverse section of ductus deferens. Van Gieson's. 125x.

A. Lumen

B. Pseudostratified columnar epithelium

C. Lamina propria

D. Inner longitudinal muscles

E. Middle muscle layer

F. Outer muscle layer

G. Adventitia

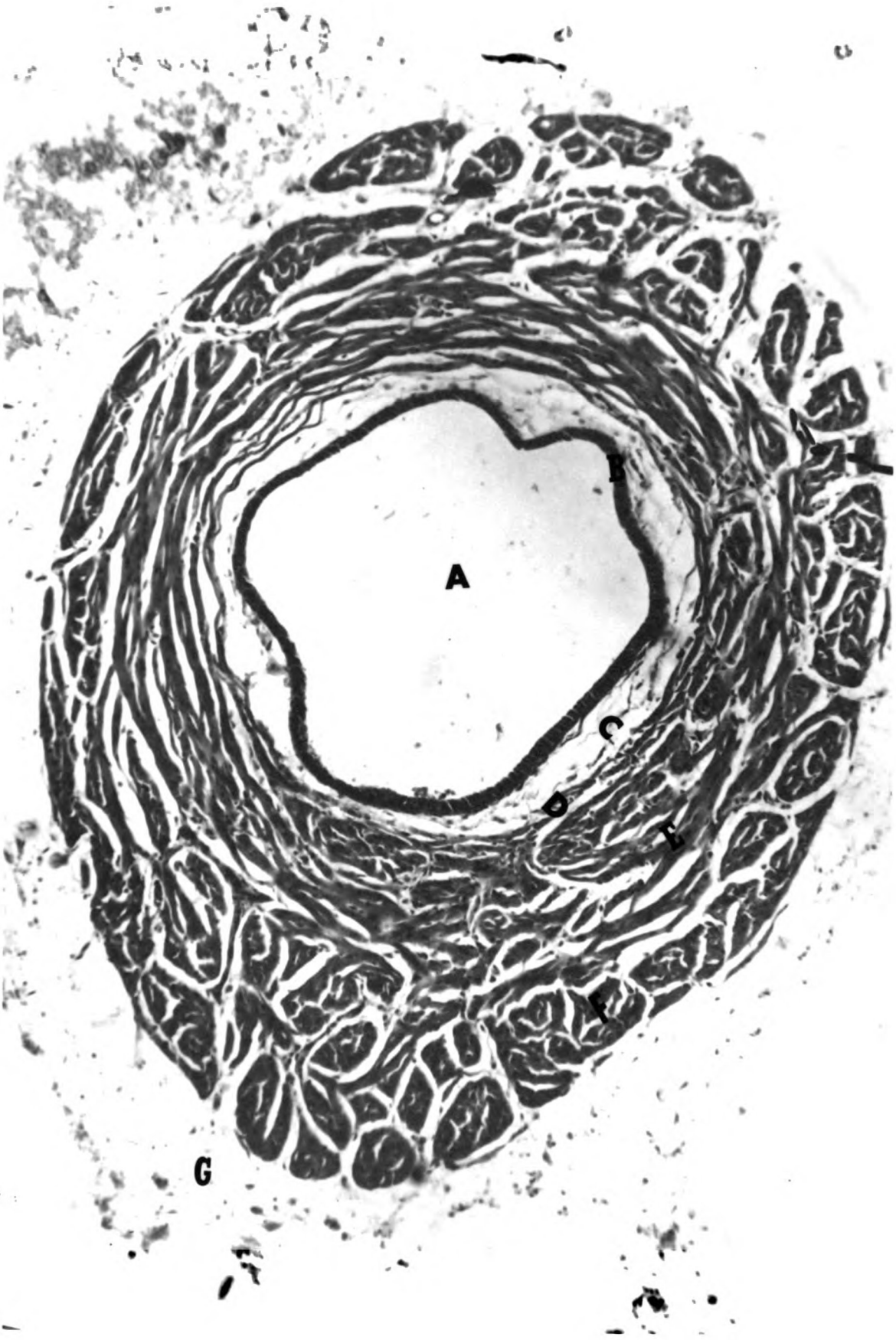
A
B
C
D
E
F
G

Figure 44. Section through prostate gland showing highly folded simple columnar epithelium (A) and smooth muscles in the stroma of the gland (B). H. and E. 125x.


A
B

Figure 45. Section of prostate gland showing tall columnar cells with actively secreting epithelium (A). H. and E. 540x.


A

Figure 46. Section through a portion of the bulbourethral gland showing striated muscle (A) and collagenous connective tissue (B). H. and E. 350x.

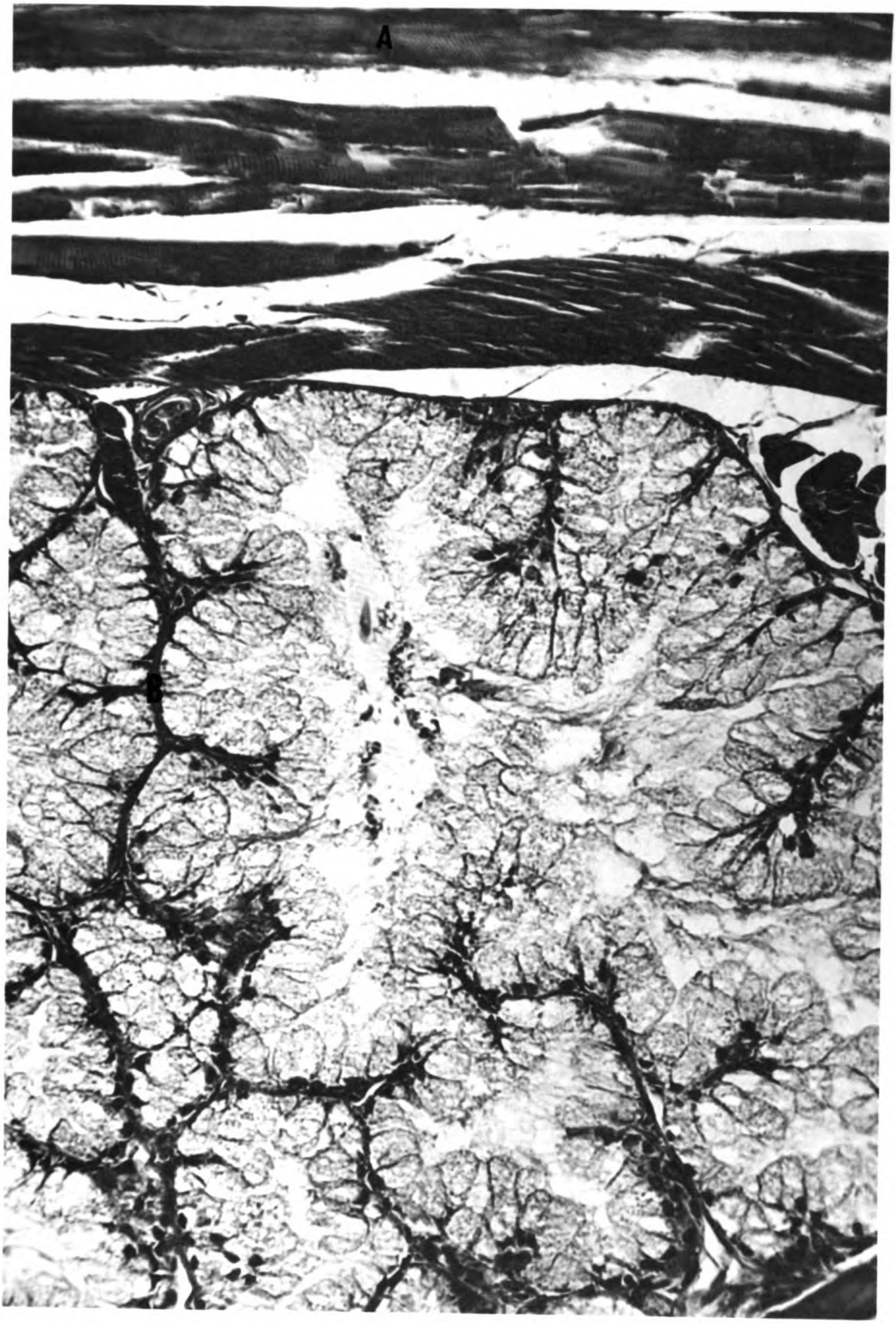
A
B

Figure 47. Section of penis. H. and E. 25x.

A. Adventitia

B. Tunica albuginea

C. Trabeculae

D. Corpus cavernosum

E. Lumen of urethra

F. Corpus cavernosum urethra


A
B
C
D
E
F

Figure 48. Section through penis showing the epithelium with spines (A). H. and E. 540x.


A

Figure 49. Transverse section of ovary. H. and E. 55x.

A. Follicle

B. Cortex

C. Medulla

D. Fetal remnants (rete ovarii)

E. Blood vessel

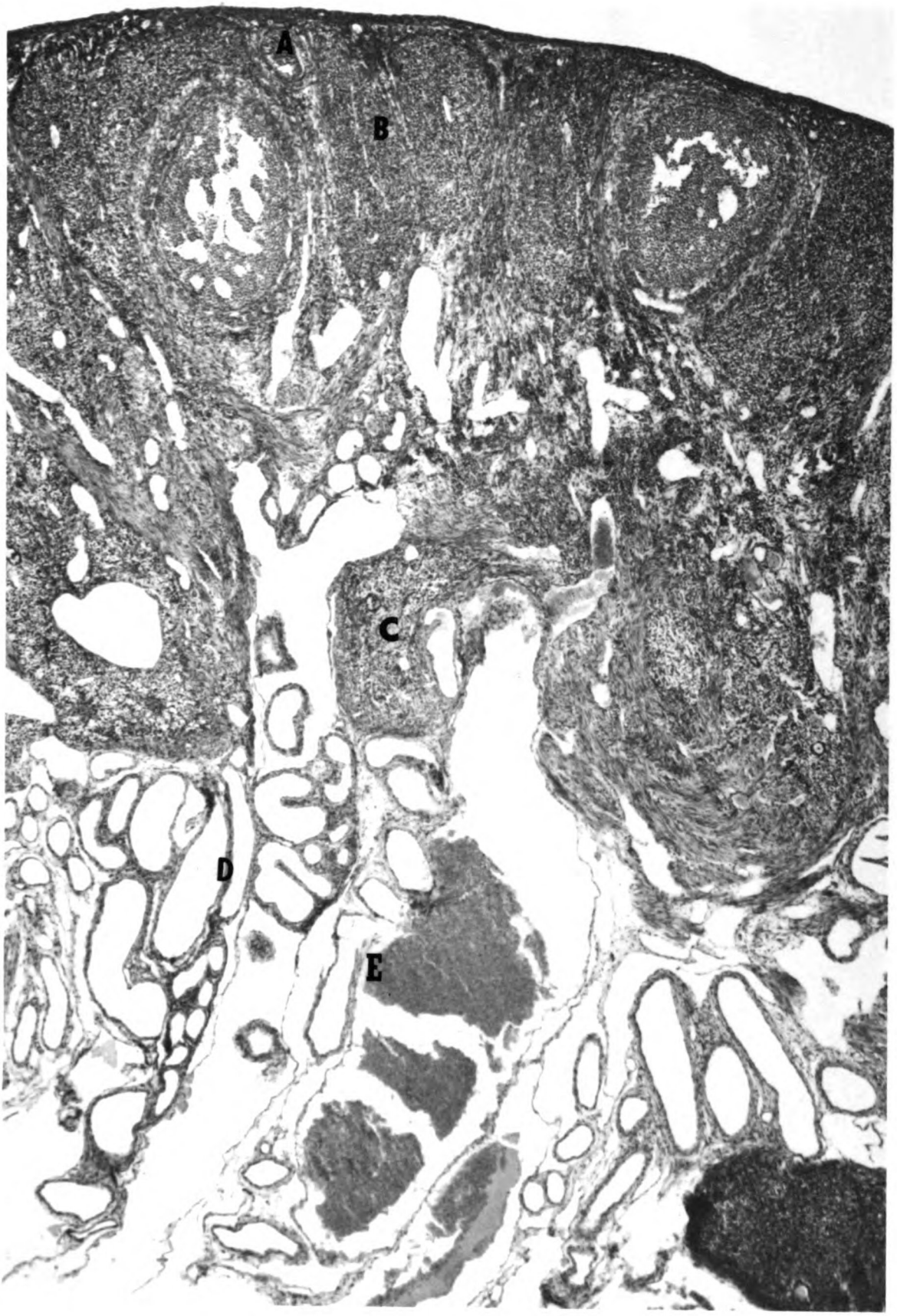
A
B
C
D
E

Figure 50. Section through ovary showing Graafian follicle with ovum. H. and E. 540x.

A. Luteal cells

B. Theca folliculi

C. Follicular liquid

D. Cumulus oophorus (follicular epithelial cells)

E. Zona pellucida

F. Connective tissue

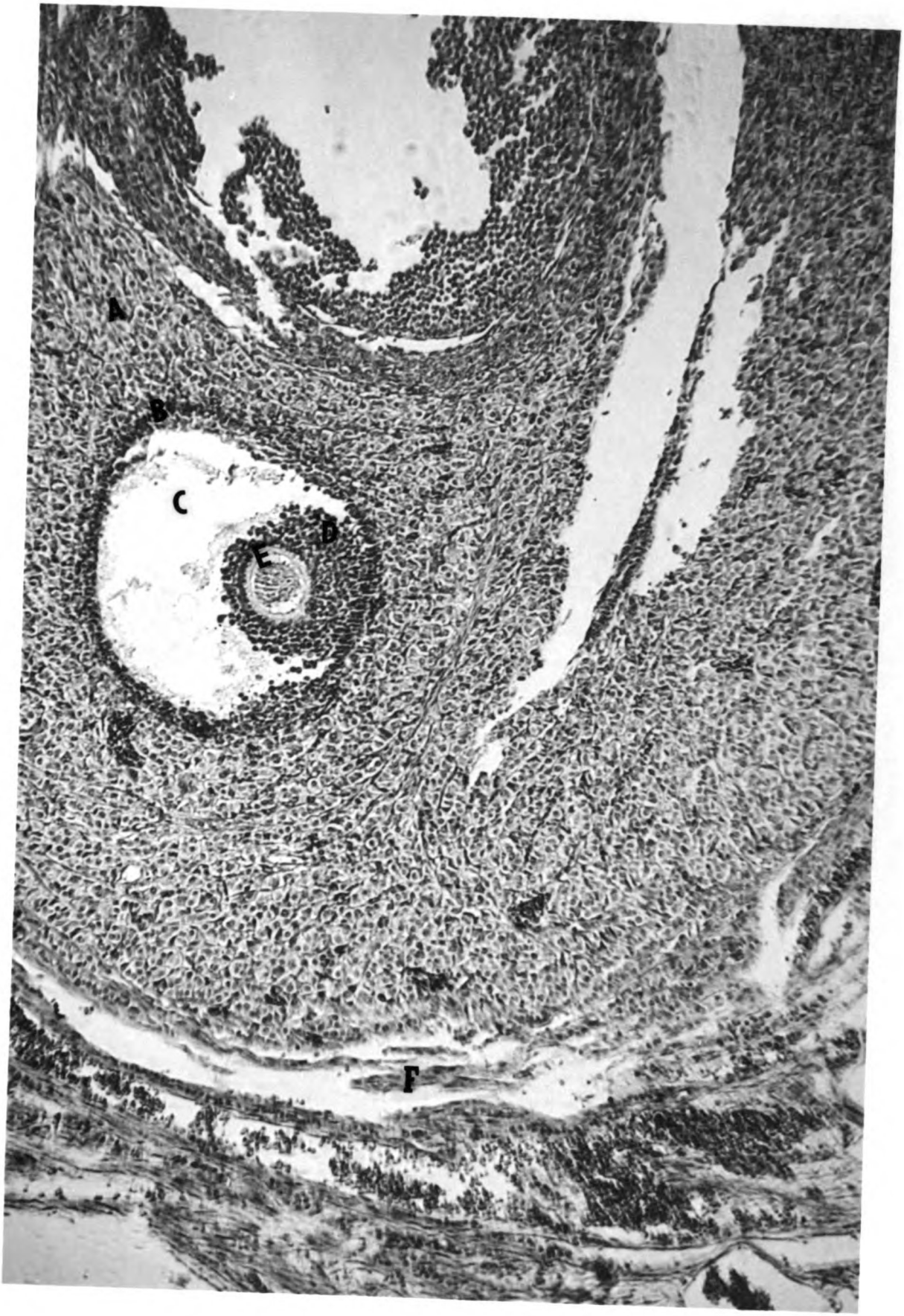
A
B
C
D
E
F

Figure 51. Section through ovary showing corpus luteum. H. and E. 540x.

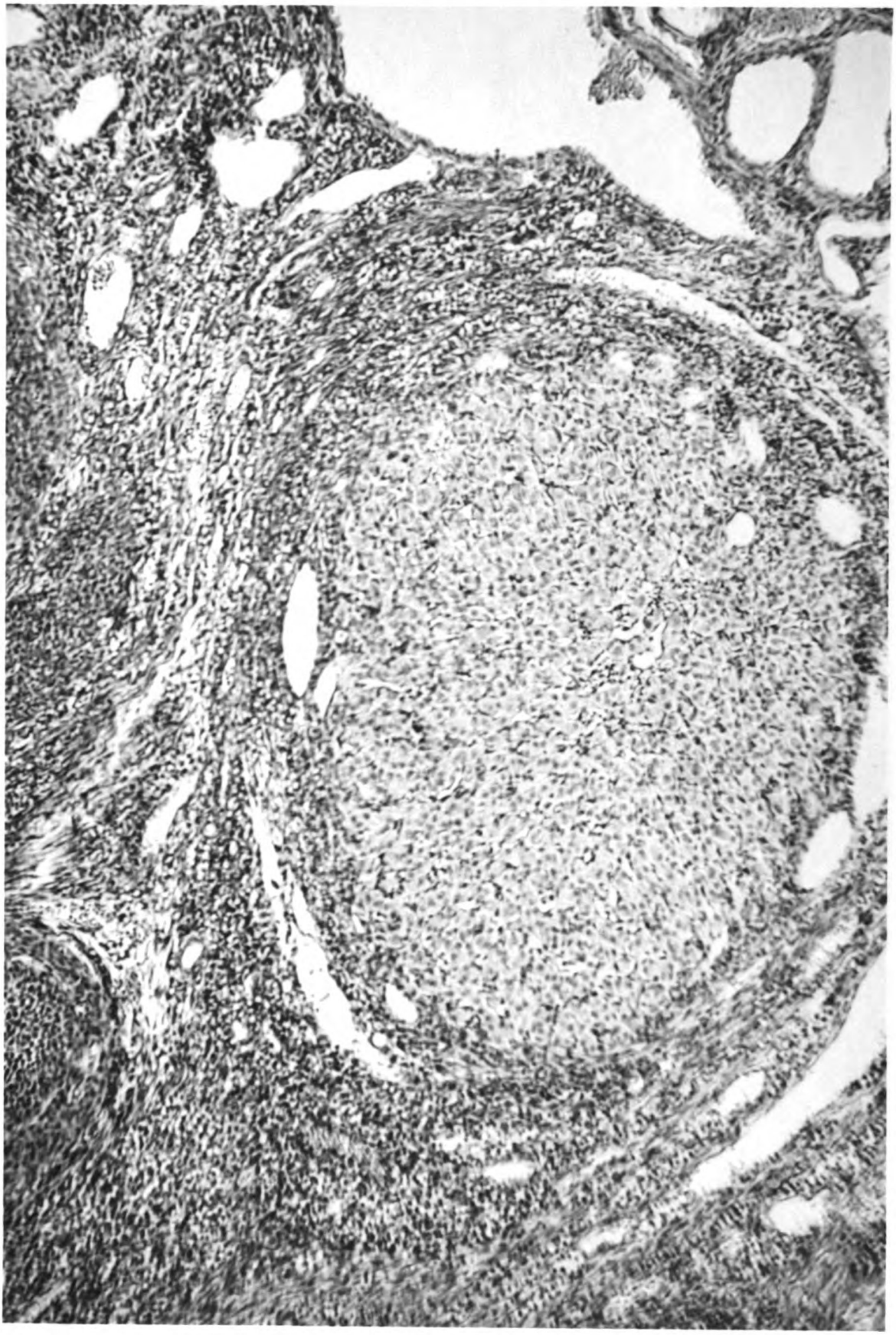

Figure 52. Section through a portion of the ampulla of the oviduct. H. and E. 540x.

A. Folds of mucous membrane covered with ciliated epithelium and containing blood vessels

B. Artery

C. Connective tissue

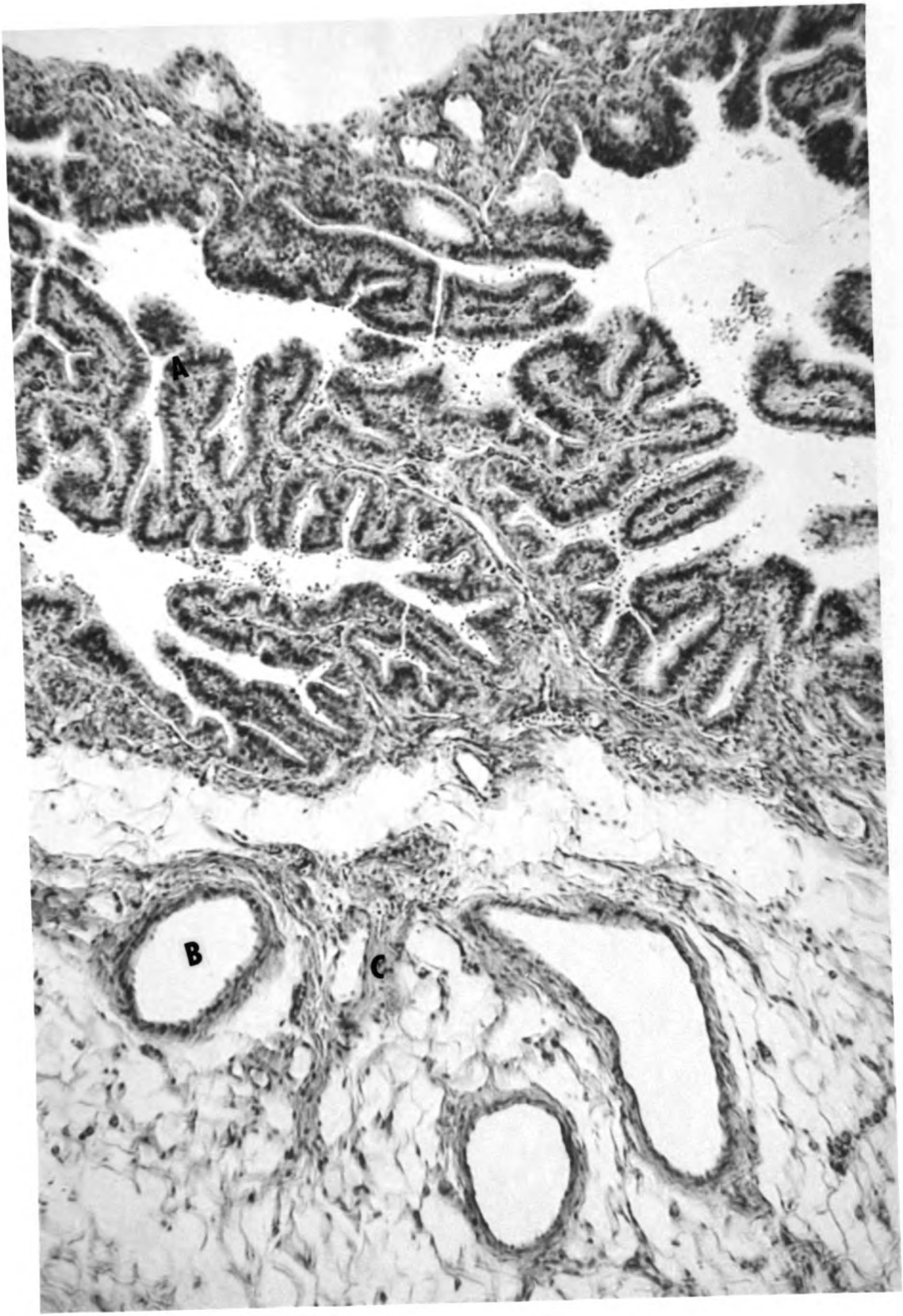
A
B
C

Figure 53. Section through the uterine horn. H. and E. 72x.

A. Broad ligament

B. Longitudinal smooth muscle

C. Lamina propria

D. Glands

E. Simple cuboidal epithelium


A
B
C
E
D
2

Figure 54. Section through uterus showing glands (A) in lamina propria (B). H. and E. 540x.

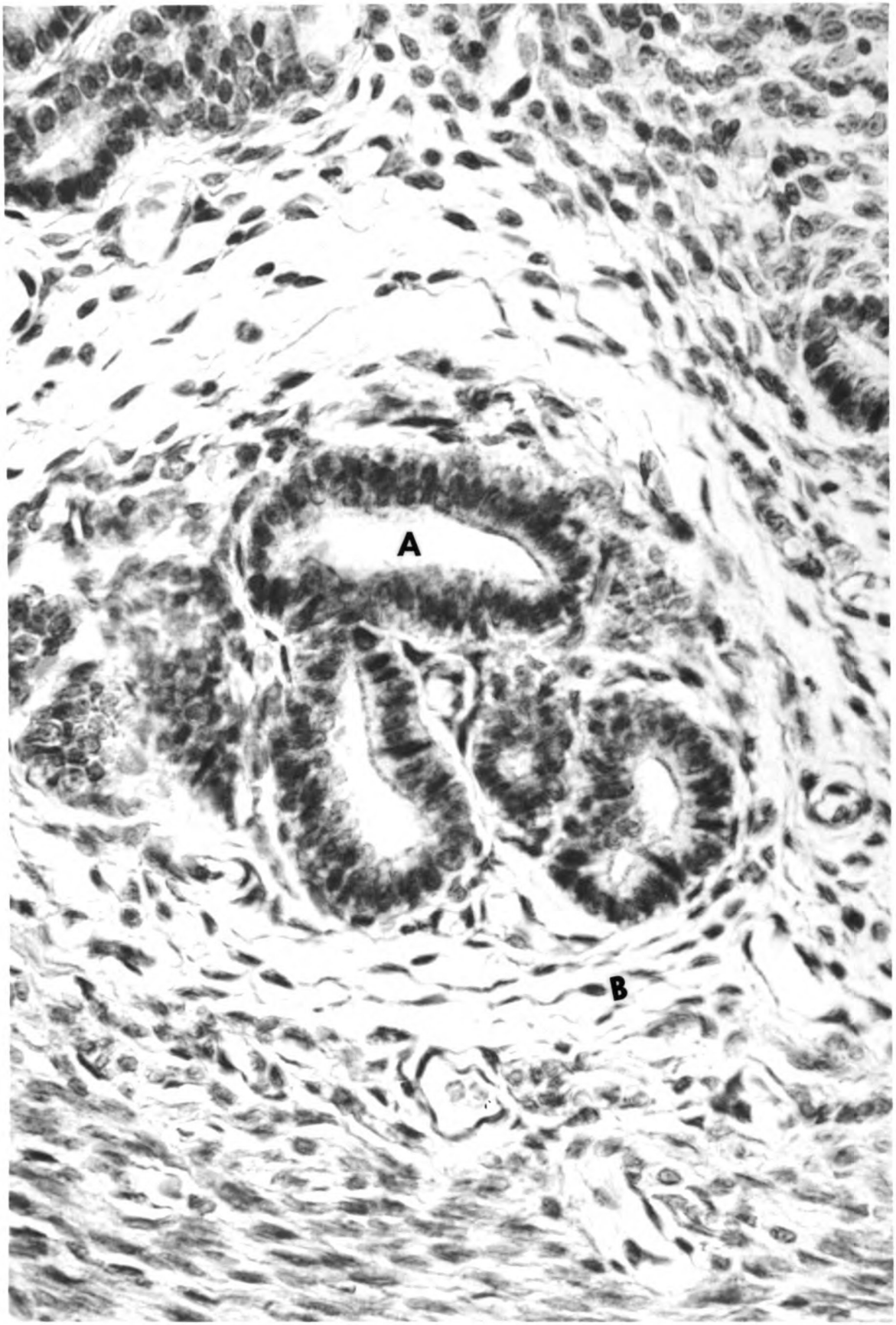
A
B

Figure 55. Section through vagina showing stratified squamous epithelium (A) and lamina propria (B). H. and E. 540x.

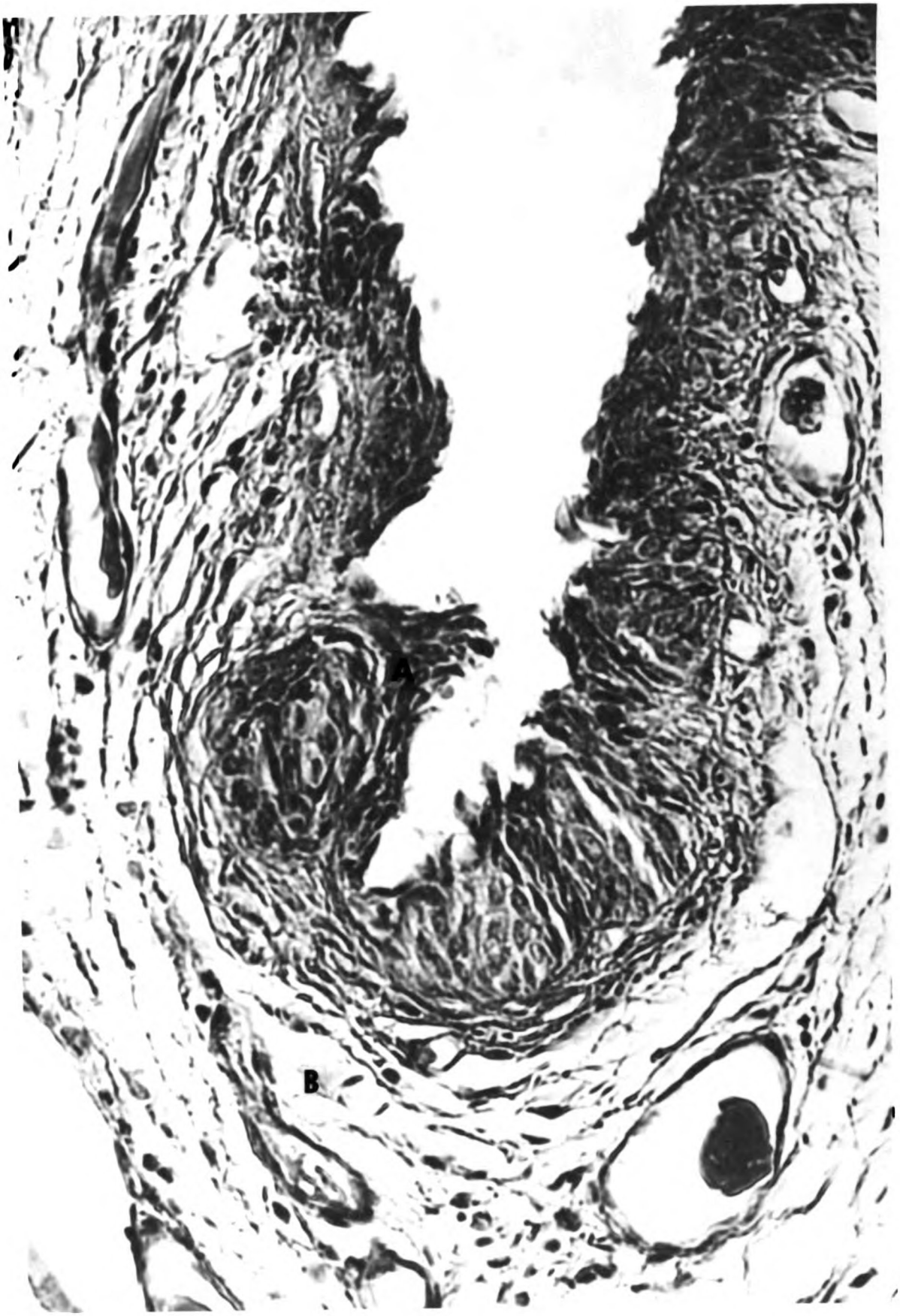
A
B