3 1293 10064 2796

LIBRARY
Michigan State
University

This is to certify that the

thesis entitled

EFFECTS OF THE GENE *WH*
ON REPRODUCTION IN THE SYRIAN HAMSTER
MESOCRICETUS AURATUS

presented by

Susan C. James

has been accepted towards fulfillment
of the requirements for

Masters degree in Zoology

James H. Asher, Jr.
Major professor

Date November 8, 1979

O-7639

EFFECTS OF THE GENE WH ON REPRODUCTION IN THE SYRIAN HAMSTER, *MESOCRICETUS AURATUS*

By

Susan C. James

A THESIS

Submitted to
Michigan State University
in partial fulfillment of the requirements
for the degree of

MASTER OF SCIENCE

Department of Zoology

1979

ABSTRACT

EFFECTS OF THE GENE WH ON REPRODUCTION IN THE SYRIAN HAMSTER, MESOCRICETUS AURATUS

By

Susan C. James

The mutant gene Wh, Anophthalmic white, in the Syrian hamster, Mesocricetus auratus, is a highly pleitropic gene causing aplasia of the eye, lack of coat skin and eye pigmentation and infertility in male animals homozygous for this gene. Since the cause of infertility was unknown, the anatomy and histology of the testis was investigated.

At the gross anatomical level, testis were severely atrophic. Light and electron microscopic investigations revealed that the testis were aspermic and possessed abnormalities in the Leydig cells, Sertoli cells and developing germ cells. It was concluded that the infertility in eyeless homozygotes may be due to: (1) a defect at the level of the testis, (2) a defect at the level of the pituitary, or (3) lack of eyes and non-function of the visual pathway.

Since infertility may be due to (2), light and electron microscopic examination of the pituitary was also undertaken. Mutant glands contained a 40% reduction in cell number, were highly vacuolated and contained numerous specialized junctional complexes and atypical cilia. These abnoumalities may represent abnormalities in embyronic cellular differentiation caused by Wh.

I dedicate this thesis to Mom and Dad.

ACKNOWLEDGMENTS

I would like to express my sincere appreciation and gratitude to Dr. James H. Asher, Jr. for chairing my graduate committee. His encouragement and guidance were invaluable.

I would like to thank Dr. Gary Hooper, Dr. Harold Hafs and Dr. John Shaver for serving on my committee. A special thanks to Dr. Hooper for his patience and expert advice in electron microscopy and to Dr. Hafs for his thoughtful criticism of this thesis.

Special thanks are due to Dr. Shirley Siew for her encouragement, instruction and unending interest in all of my undertakings.

I wish to thank Linda Chaney and Karen Baker for their friendship and extend a special acknowledgment to Linda for her enthusiasm and continuing encouragement, critical evaluations and stimulating discussions which have given me better insight into the problems discussed in this thesis.

Thanks to my friends Bruce, Anna and Bob for their unending patience and hours of entertainment throughout the course of this endeavor.

Last, but certainly not least, a very special thanks to my parents, Richard and Patricia James, for their encouragement and material assistance. Their interest and advice will always be deeply appreciated.

TABLE OF CONTENTS

LIST OF TABLES

CHAPTER 2

LIST OF TABLES

CHAPTER 3

Table | Page

LIST OF FIGURES

CHAPTER 2

LIST OF FIGURES

CHAPTER 3

Figure Page

CHAPTER 1

THE MAMMALIAN TESTIS AND PITUITARY CONTROL OF TESTIS FUNCTION

A. General Morphology and Function of the Testis

The mammalian testis as described by Bloom and Fawcett ('75) is a compound tubular gland which is enclosed in a tough fibrous coat referred to as the tunica albuginea. Fibrous septa divide the organ into about 250 pyramidial compartments each called a lobule testis. Each lobule testis consists of one to four highly convoluted seminiferous tubules. At the apex of the lobule testis, its seminiferous tubule or tubules pass directly into the first segment of the system of excretory ducts each referred to as a tubule recti. The recti are confluent with the rete testis, a plexiform system of epithelium lined spaces in the connective tissue. The seminiferous tubules are cylindrical, and when stacked together create a series of three-sided spaces. A loose connective tissue containing fibroblasts, mast cells, macrophages and perivascular mesenchymal cells, extends inward from the tunica to fill the intersticies among the tubules. In addition, the spaces contain epithelioid cells, or interstitial cells of Leydig. Each testis is suspended in the scrotom at the end of a long vascular pedicle, the spermatic cord, which consist of the excretory ducts of the testis, blood vessels, and nerves supplying the testis on that side. The epididymis, an elongated organ closely applied to the surface of the testis, is made of the convoluted proximal part of the excretory duct system and is the site of accumulation and storage of spermatozoa (Bloom and Fawcett, '75).

The testis is known to serve two functions. The first function involves the synthesis and secretion of testosterone by the endocrine component of the testis or interstitial cells of Leydig. The second involves the development and maturation of germ cells in the exocrine portion of the testis or epithelium of the seminiferous tubules.

Interstitial Tissue

The endocrine component of the testis, or interstitial cells, was first described by Leydig (1850) as modified connective tissue. Their function in producing male sex hormones was suggested as early as 1903 by Bouin and Ancel. It is now generally accepted that these cells produce the majority of the steriod hormone testosterone (Means, '76). The interstitial tissue of the rodent testis is sparse while the bulk of the intersticies is filled with large lymphatic sinusiods. Leydig cells are seen clustered around blood capillaries. The ultrastructure of Leydig cells is consonant with their function of steroid synthesis (Christensen, '65; Setchell, '78a). Leydig cells are irregularly polyhedral in shape, measuring 14-20 μm in diameter, and contain a large spherical nucleus with a small amount of peripherally disposed heterochromatin and one or two prominent nucleoli. Leydig cytoplasm contains a well developed Golgi complex, abundant mitochondria, lipid droplets and vacuoles (Christensen, '65). In common with other steroid secreting endocrine cells, Leydig cells possess an extensive system of branching and anastomosing smooth endoplasmic reticulum, which is known to contain enzymes necessary for several steps in the synthesis of androgenic steroids (Christensen, '65; Setchell, '78a).

Seminiferous Tubules

The exocrine portion of the testis, or seminiferous tubules, are lined with a complex stratified epithelium composed of two categories of cells: (1) a fixed population of non-proliferating supporting cells or Sertoli cells, and (2) a proliferating and differentiating population of germ cells or spermatogenic cells.

Sertoli cells, as described by Sertoli (1865), are columnar epithelial cells which are fixed to the basement membrane or basal lamina of the seminiferous tubules and perform a supportive and nutritive function during the maturation of spermatogenic cells. A number of specific functions have now been ascribed to Sertoli cells including secretion of fluid, phagocytosis, aiding the maturation and release of spermatozoa and synthesis of intratubular androgen-binding protein (Setchell, '78b). These cells form an elaborate system of thin processes that extend towards the lumen of the tubule surrounding the spermatogenic cells and filling the intersticies among them. Sertoli cytoplasm contains numerous slender elongate mitochondria, numerous lipid droplets, primary and secondary lysosomes, a small Golgi zone, free polysomes and a well developed agranular endoplasmic reticulum. The Sertoli nucleus is large and ovid in shape with one or more deep infoldings or lobulations in its surface and consists of homogenous nucleoplasm. Sertoli nuclei also contain a large and highly characteristic nucleolar complex, consisting of a central mass and two laterally associated basophyllic bodies (Dym, '73).

Spermatogenic cells are of several morphologically distinguishable types including spermatogonia, spermatocytes, spermatids, and spermatozoa. These are not ontogenetically distinct cells types, but are clearly distinguishable successive stages in the continuous process of differentiation of male germ cells. Continual proliferation of the seminiferous epithelium is confined to spermatogonia and spermatocytes near the basal lamina. Neogenesis of succeeding generations of cells in this region displaces the more mature forms towards the lumen of the tubule as they differentiate.

Spermatogonia arise from gonocytes of the fetal testis. They are large diploid cells which lie against the boundary tissue of the tubule and divide mitotically (Setchell, '78c). Studies by Rowley _et al_., '71 have revealed four types of human spermatogonia consisting of dark type A (AD), pale type A (AP), type B (B), and a new type A (AL). Subcellular criteria used in distinguishing these four cells types include: (1) shape of the nucleus, (2) density of nucleoplasm, (3) type and placement of nucleoleus, (4) structure of mitochondrial cristae, (5) association of endoplasmic reticulum with the mitochondria, (6) amount of glycogen, and (7) presence of filamentous structures in the cytoplasm (Rowley _et_ al., '71). As diploid spermatogonia proliferate, some daughter cells are retained as future progenitors (stem cells), while others develop into primary spermatocytes. With the last mitotic division of spermatogonia (Type B), pre-leptotene spermatocytes are produced (Clermont, '72; Steinberger and Steinberger, '75).

Primary spermatocytes initially resemble spermatogonia, but as they move from the basal lamina towards the luman, they accumulate cytoplasm and become larger (Setchell, '78c). Immediately after their formation, they enter prophase of the first meiotic division, characterized by the formation of filaments (synaptonemal complexes) within the nuclear chromatin (Bloom and Fawcett, '75). The reticulum of the nucleus of the primary spermatocyte is reorganized into the diploid number of very long slender threads characteristic of the leptotene stage of meiosis. Homologous threads undergo pairing and thickening during the zygotene stage, then gather in a boquet-like arrangement around the synaptonemal complex. Paired threads shorten and thicken to form four obvious chromosomal strands or a tetrad, typical of the pachytene stage. Duplicated chromosomes in pachytene can be identified as dyads held together by centromeres. During diplotene and diakinesis, chromosomes complete their process of shortening, and the synaptonemal complexes disappear. At the end of prophase the nuclear envelop disappears and the tetrads rearrange themselves at the equatorial plane in metaphase I. At anaphase I, centromeres move to opposite poles of the spermatocyte taking both dyads along with them. Anaphase I and telophase I are quickly completed resulting in the formation of secondary spermatocytes carrying the haploid number of chromosomes. Secondary spermatocytes quickly complete the second phase of meiotic division resulting in spermatids which have a haploid set of chromosomes (Bloom and Fawcett, '75).

Spermiogenesis is the term which describes the developmental events leading to the transformation of spermatids into spermatozoa. Each of the relatively small spherical or polygonal spermatids contain a small Golgi apparatus in the juxtanuclear cytoplasm. Several small granules, proacrosomal granules, appear within the developing Golgi complex. Each proacrosomal granule is found to be enclosed within a membrane limited vesicle of the Golgi apparatus. As maturation of the spermatid proceeds, separate granules in the Golgi region fuse together into a single large globule or acrosomal granule which is contained within a membrane bound acrosomal vesicle. The granule and vesicle become adherent to the outer aspect of the nuclear envelop. The point of adherence marks the future anterior tip of the sperm nucleus. The Golgi apparatus remains closely associated with the surface of the acrosomal capsule, continuing to form small vesicles which feed into the membrane of the acrosomal vesicle and contribute to its enlargement. The limiting membrane of the acromomal vesicle increases its area of adherence and forms a thin fold, initially covering the anterior one-third of the nucleus. The bulk of the acrosome remains localized at the anterior pole of the nucleus, but during spermiogenesis its substance gradually spreads in a thin layer into the fold. Condensation of nuclear chromatin causes the spermatid nucleus to transform into a homogeneous dense mass devoid of structure, at which point the acrosome assumes a position covering the anterior two-thirds of the nucleus. Once the acrosome is formed, the remaining Golgi complex migrates posteriorally and is included as part of the residual cytoplasm.

While the early stages of acrosome formation are in progress, centrioles migrate to the opposite end of the spermatid. The distal centriole becomes oriented perpendicular to the cell surface, giving rise to a slender flagellum. Along with a marked elongation of the spermatid, cytoplasmic microtubules arise and become laterally associated to form a manchette (Bloom and Fawcett, '75). The flagellum consists only of the axial filament complex, or axoneme. It contains two central fibrils and nine peripheral doublets, which are continuous with the wall of the distal centriole. During development of the tail, the proximal centriole gives rise to a thin sheet of dense material which arches over its upper surface and eventually develops into the articular surface of the connecting piece, which joins the tail to the nucleus. As spermeogenesis proceeds, the manchette disappears and mitochondria aggregate around the segment of flagellum between the annulus and the nucleus. Simultaneously, a succession of circumferentially oriented ribs are deposited around the tail, distal to the annulus, to form the fibrous sheath of the principal piece. As differentiation proceeds, most of the residual cytoplasm is cast off as the residual body. Only a thin layer of cytoplasm remains to cover the nucleus, middle piece and tail piece.

In summary, the testis is a compound tubular gland which serves two functions, one hormonal, the second reproductive. Interstitial cells of Leydig comprise the endocrine portion of the testis and are responsible for the synthesis and secretion of the steroid hormone testosterone. Seminiferous tubules comprise the exocrine portion of the testis and are lined with a complex stratified epithelium containing Sertoli cells (supporting cells), and spermatogenic cells. Proper division and maturation of spermatogenic cells results in spermatozoa which are extruded from the tubules and stored in the epididymis until ejaculated.

B. General Morphology of the Pituitary Gland

The pituitary gland, or hypophysis cerebrei, is composed partly of nervous tissue, the neurohypophysis, and partly of epithelial tissue, the adenohypophysis. The gland is suspended from the floor of the third ventricle of the brain.

The neurophypophysis as described by Rhodin ('74) is composed of the eminentia medealis (median eminence) of the tuber cinereum, the infundibular stem and the infundibular process. It arises as an evagination from the floor of the diencephalon. It is composed of large numbers of non-myelinated nerve fibers and some neuroglial cells, or pituicytes. The nerve fibers are derived from the cells of the supraoptic and paraventricular nuclei of the hypothalmus. The nerve terminals end in close apposition to the capillaries of the posterior lobe. The hormones secreted by the neurohypophysis include oxytocin and vasopressin. These hormones are produced in the cell bodies of the hypothalmic nuclei, but are stored and liberated by the neurohypophysis (Rhodin, '74).

The epithelial portion of the gland, or adenohypophysis, is composed of the pars distalis, pars tuberalis, and pars intermedia (Rhodin, '74). It develops from an invagination of the oral ectoderm (Rathke's pouch). The pouch loses contact with the oral cavity and forms a vesicle which later becomes a solid cell mass. The anterior lobe, pars distalis and pars tuberalis, consists of five cellular types, which were initially characterized by differential staining affinities of the cytoplasmic granules (Herlant, '64). Each cell type is responsible for the secretion of a characteristic hormone such as somatotropin (GH), prolactin (PRL), adrenocorticotropin (ACTH), thyrotropin (TSH), follicle stimulating hormone (FSH), or lutinizing hormone (LH).

Research into the cellular origins of the anterior pituitary hormones has resulted in the elucidation of five classes of cells characterized by their reactivity to physiological change. At the light microscopic level, Herlant and colleagues demonstrated that the anterior lobe contained two varieties of PAS negative cells (acidophils): (1) GH-secreting alpha cells and (2) PRL-secreting epsilon cells. In addition, three varities of PAS positive cells (basophils) were identified: (1) TSH-secreting delta cells, (2) FSH-secreting beta cells and (3) LH-secreting gamma cells (Herlant, '56; Herlant, '59; Herlant and Canivenc, '60; Herlant and Racodot, '57; Peyre and Herlant, '61). There is yet little evidence as to the cellular origin of ACTH.

Since many cellular structures of interest are beyond the limits of resolution of the light microscope, electron microscopy has proved to be a powerful tool for the investigation of pituitary interactions in complex endocrine states, or in particular, of pituitary influences in certain pathologic conditions. In the normal condition, GH-secreting acidophils are medium sized cells containing a large round nucleus and secretory granules of approximately 3000 to 3500 Å in diameter. LTH-secreting acidophils are large cells with electron lucent cytoplasm and contain a large indented nucleus and secretory granules of approximately 6000 to 9000 Å. TSH-secreting basophils are fairly large cells of polygonal shape, containing a large nucleus and secretory granules of approximately 1000 to 1600 Å in diameter.

Electron microscopic studies have identified gonadotropes (FSH and LH producing cells) in the normal and castrated rat (Farquhar and Rinehart, '54; Yoshimura and Harumiya, '65; Costoff, '73), mouse (Barnes, '62) and hamster (Giroud and Dubois, '65; Dekker, '67). The controversy over cellular autonomy of FSH and LH continues, although the use of immunocytochemical techniques have indicated that one gonadotropic cell contains both FSH and LH (Baker and Gross, '78). Gonadotropes are numerous and distributed throughout the pars distalis, although they form a dense aggregation in the cephalic ventromedial "sex zone." Also, gonadotropes are thought to be more numerous in the male than in the female gland (Baker and Gross, '78). Gonadotropic cells are large and polyhedral, measuring 10 to 15 μm in diameter and contain an eccentrically positioned nucleus. The nucleus is irregular in contour and possesses finely scattered and peripherally clumped heterochromatin and one or two nucleoli. The secretory granules are electron dense and range in size from 750 to 2350 Å. When these cells are in an inactive state, the Golgi and endoplasmic reticulum are rather inconspicuous and poorly developed, whereas in actively secreting cells the Golgi is extensive and contains areas with granules in different stages of formation. The endoplasmic reticulum is usually irregular, consisting of dialated sacs and scattered vesicular areas. The membranes are intermittantly dotted with ribosomes, although some ribosomes are free in the cytoplasm. Mitochondria are generally elongate but, short, rod-like and round mitochondria are also present. Most gonadotropes are found in association with vascular spaces (Farquhar and Rinehart, '54; Dekker, '67; Costoff, '73).

Summarizing, the pituitary gland consists of a neural lobe (neurohypophysis), and an epithelial lobe (adenohypophysis). The anterior lobe of the adenohypophysis, or pars distalis and pars tuberalis, contains five cellular types, determined at the light microscopic level, by differential staining affinities of characteristic cytoplasmic granules. Electron microscopy has elucidated the gross cellular morphology of these cell types on the basis of their response to changes in endocrine states.

C. Hypophyseal Control of Testis Function

The importance of the hypophysis in maintaining gonadal function was demonstrated as early as 1930 by Smith using hypophysectomized rats. After hypophysectomy the gonads atrophied, but were restored to normal appearance and function when pituitary extracts were injected or implants of the gland were made. After Smith's discovery, many attempted to separate the gonadotropins from the other hormones derived from the anterior pituitary. Fevold et al. ('31) were the first to accomplish a partial separation of FSH and LH. They accompanied the above with an intensive study of the biological effects of each hormone, concluding that the action of these two hormones was to promote growth of ovarian follicles and affect the germinal epithelium of the testis. Greep *et al.* ('41) and Fevold ('43) reported that the hormone LH stimulated luteinization of the ovaries and maintained interstitial cells of the testis.

In the male mammal, follicle stimulating hormone was tentatively identified as being responsible for the maintenance of the germinal epithelium within the seminiferous tubules of the testis. Presently, FSH appears to play an important role in the initiation of the spermatogenic process in immature mammals and for the maintenance of testicular function in the adult. The precise mechanisms by which FSH exerts its effects are still unknown, although considerable evidence has appeared, as of late, to identify and sequence the biochemical events initiated by the interaction of FSH with membrane receptors on the Sertoli cell (Means, '77).

The Sertoli cell has been shown to be the primary target for FSH action in the testis, since it is the only cell to possess FSH-specific receptors and responds to FSH stimulation by increasing its level of endogenous cyclic AMP (Steinberger and Steinberger, '77). Specific receptors present on the plasma membrane of Sertoli cells recognize and bind FSH. This binding activates membrane bound adenylate cyclase. Cyclic AMP, formed in response to this stimulus, promotes DNA-dependent RNA synthesis and the formation of proteins, including the androgen binding protein (ABP) (Means, '76). The ABP is transported into the intracellular spaces where it binds androgens. This ABP-androgen complex then interacts with the membrane of a developing germ cell and transfers the androgen to a hypothetical cytoplasmic androgen receptor. The mechanism of action of androgens subsequent to this step are unknown. After delivery of the androgen to the germ cell, ABP is free to bind another androgen, and the process thus is repeated. ABP-androgen complexes are eventually either secreted into the lumen of the seminiferous tubule or broken down by proteolytic enzymes within the germinal epithelium (Steinberger and Steinberger, '77).

It is known that the primary role of LH in the testis is to regulate testosterone secretion from testicular interstitial tissue (Leydig cells). LH most likely affects spermatogenesis by controlling production of the androgen testosterone. Testosterone is required for spermatogenesis, although the precise mechanism by which it exerts its effects is not well understood (Lostroh, '76).

Binding of LH to Leydig cells was demonstrated in rats using labelled hormone both in vivo (deKretsler et al., '69; '71) and in vitro with testis homogenates (Catt et al., '72. Apart from hCG, no other hormones bind to these sites (Setchell, '78a). Stimulation by LH enhances adenylate cyclase activity and the formation of cyclic AMP. A protein kinase frees cholesterol from lipid stores (lipid droplets) and catalyses the formation of a protein which then activates the conversion of cholesterol to pregenenolone. This conversion occurs by splitting off of the long side chain attached to the carbon-17 atom of cholesterol. The reaction requires NADPH and O_2 and occurs in the mitochondria (Setchell, '78a). Pregenenolone is converted to other steroid hormones in the smooth endoplasmic reticulum (Christensen, '65).

In experiments concerned with the restoration of spermatogenesis in testes which have regressed following hypophysectomy, germ cell development proceeded as far as the early spermatid stage in animals treated with testosterone, but FSH was necessary for the completion of spermiogenesis (Steinberger, '71). Spermatogonia persist after hypophysectomy, and do not require exogenous hormone to develop to the pachytene stage of the primary spermatocyte (Lostroh, '76). Testosterone, however, is necessary in the transformation of the prophase to metaphase primary spermatocyte. Thus, with the presence of testosterone alone, spermatocytes complete meiosis to form spermatids (Lostroh, '76). Modest levels of FSH and LH are subsequently necessary for spermatid development while substantial levels of LH, FSH and testosterone are necessary for the transformation of spermatids to spermatozoa (Lostroh, '76). Thus, testosterone, LH and FSH control gametogenesis in the postpubertal male from the prophase of meiotic reduction division through final maturation of spermatozoa.

D. Genes Causing Sterility Including Wh

Setchell ('78d) points out that the normal function of the testis can be directly interrupted by illness, heat, chemical agents such as cadmium acetate or lead salts or drugs such as cyproterone acetate. Likewise, normal function may be secondarily affected by depressing the function of the pituitary with drugs such as 19-norspiroxenone (Setchell, '78d).

In addition to these environmental agents, mutant genes may also interrupt the normal function of the testis, rendering the mutant individual infertile. These mutant genes may act, for example, to inhibit Wolffian duct development (testicular feminization), causing an absence of germ cells in many species including mice (Lyon and Hawkes, '70;

Blackburn *et al.*, '73) and rats (Stanley and Gumbreck, '64; Stanley *et al.*, '73). Mutant genes may directly affect Leydig cell development in the rat as in *vet-rat* (Stanley *et al.*, '73) or seminiferous tubule development as in Sertoli-cell only syndrome (deKrestsler *et al.*, '72). Mutant genes may affect spermiogenesis in the mouse as in *T* (Olds, '71), *hop-sterile* (Johnson and Hunt, '71), *p-sterile* (Hunt and Johnson, '71) and *quaking* (Bennett *et al.*, '71), or in the bull as in *dag-defect* (Blom, '66) and *pseudodroplet* (Blom, '68). Hypothetically, genes might secondarily affect testis function by acting to alter pituitary function.

At least three genes in the Syrian hamster, *Mesocrecetus auratus*, are known to cause infertility: (1) ruby-eyed mutants (*ru*) are known to be sterile due to an inadequate sperm count (Robinson, '68), (2) piebald mutants (*s*) are known to possess urogenital abnormalities and reproductive tract aplasia (Robinson, '68), and (3) Anophthalmic white mutants (*Wh*) do not reproduce but the cause of the infertility is unknown.

Hamsters homozygous for the mutant gene *Wh* are known to possess three distinct characteristics: (1) a complete suppression of pigment, (2) anophthalmia or severe microphthalmia and (3) an interruption in the reproductive system causing infertility (Robinson, '62; '64; Asher, '68). Since infertility exists in anophthalmic males and females without explanation, the question as to what causes infertility may be proposed. Thus, the purpose of this research is to determine why male mutants are sterile. Similarly, since genes are known to affect testis function either directly or indirectly, the purpose of this research is also to determine whether the gene affects testis function alone or whether the pituitary is involved.

CHAPTER 2

EFFECTS OF THE GENE WH ON REPRODUCTION IN THE SYRIAN HAMSTER, MESOCRICETUS AURATUS

A. Introduction

One of the many mutants occurring in the Syrian hamster, *Mesocricetus auratus*, is *Anophthalmic white*. The mutant gene was first described by Knapp and Polivanov ('58) as an autosomal recessive gene (*an*), inherited independently of the albino gene c^d. Studies by Behr and Behr ('59) distinguished heterozygous animals from homozygous wild-type (golden hamsters) and suggested that the gene acted as a partial dominant. With this in mind, they proposed the symbol *Wh* for the mutant gene. Adopting the designation *Wh*, heterozygous animals (*Whwh*) were found to be agouti but possessed white venter fur as opposed to the pale cream venter fur of the wild-type. Later studies by Robinson ('62;'64) described *Wh* as incompletely dominant and indicated that animals homozygous for *Wh* exhibited a complete absence of coat and skin pigmentation while aplasia of the eyes resulted in extreme microphthalmia or anophthalmia.

Hughes and Geerarts ('62) reported that the development of the eye proceeded normally until the last days of fetal development, at which time the action of the gene *Wh* became apparent. Studies by Berman ('64) revealed that the choroid fissure of *WhWh* embryos remained open and the lack of intra-occular pressure was proposed to be the cause of the extreme microphthalmia. Finally, studies by Yoon ('73; '75) suggested that the gene *Wh* caused extreme optic degeneration along with deafness.

Studies of the mutant *Wh* in the AN/As-*Wh* strain have been in progress for the last seventeen years (Asher, '68). As a result of low breeding-capacity and a lack of resistance to environmental stress, this mutant hamster proved to be exceptionally hard to maintain. Throughout the development of the strain (AN/As-*Wh*), a strong interaction was noticed between *Wh* and cream (c). Since the expression of *Wh* was enhanced in the presence of *e* and since homozygous cream (*ee*) hamsters appeared to be more vigorous than the contrasting wild-type golden hamsters, hamsters homozygous for the cream background were selected. Thus, animals described in this study exhibited the following phenotypes:

(1) Normal hamsters (*whwhee*) were cream colored with white spotted bellies and black eyes (Fig. 1);

(2) Heterozygous hamsters (*Whwhee*) were white with black eyes and possessed less ear, eye and skin pigmentation than normal (Fig. 2);

(3) Homozygous mutant hamsters (*WhWhee*) were white, lacked eyes and possessed no ear or skin pigmentation (Fig. 3).

Earlier studies by Asher ('68) indicated that all *WhWh* individuals in the AN/As-*Wh* strain appeared to: be anophthalmic, lack pigmentation, be comatose when sleeping, have a different fur texture, exhibit extreme nervousness, exhibit general growth retardation, have small adrenal glands, and lack proper sexual development.

It was first noted by Knapp and Polivanov ('58) that the anophthalmic male was not able to reproduce. Breeding data from the strain

AN/As-Wh also indicated a lack of reproductive ability of both male and female WhWh individuals. Preliminary histological examination by Asher ('68) suggested that the seminiferous tubules from mutant testes contained no sperm. Therefore, the present study was undertaken to determine whether testicular abnormalities existed and contributed to the infertility of male animals homozygous for the mutant gene Wh.

B. Methods and Materials

The strain used in this study was designated AN/As-Wh by Asher ('68), and is maintained by a system of full-sibling mating where at least one parent is heterozygous for Wh. Hamsters were housed in polycarbonate cages with galvanized or stainless steel tops, cleaned weekly and provided with pine shavings for bedding. Wayne Laboratory and Breeder Chow and water were provided *ad libidum*. Lighting of the animal room was on a regime of 13 hours of light and 11 hours of darkness.

Ten sets of matched-siblings at approximately 135 days of age were employed in this investigation. Activity patterns for each animal were determined on running wheels over a one week period prior to killing. Four hours prior to the calculated onset of running activity, hamsters were weighed, anesthetized with ether, and perfused through the left ventricle with Ringer's solution followed by 0.5 percent cacodylate buffered glutaraldehyde at pH 7.3 (Glauert, '75a). After perfusion, testicular tissue was collected and further processed for both light and electron microscopy.

Light Microscopy

After perfusion, each testis prepared for light microscopic examination was fixed for two hours in Bouin's solution, weighed, cut into small pieces and fixed in Bouin's solution for at least 3 days. Small tissue pieces were dehydrated through alcohols, embedded in paraffin, cut into 5 μm sections and stained with Harris' Hematoxylin and Eosin. Five random sections from each testis were photographed and the photographs were contact printed. Tubule diameter measurements were determined from the contact prints at a magnification of 64X.

Electron Microscopy

Each testis prepared for electron microscopic examination was immediately cut into small pieces and fixed in 0.5 percent cacodylate (0.2 M) buffered glutaraldehyde at pH 7.3 (Glauert, '75a). The tissue was postfixed in 2.0 percent cacodylate buffered osmium tetroxide (Glauert, '75b) and embedded in Epon-Araldite (Mollenhauer, '64). Thick (1 μm) epoxy sections, taken for light microscopy, were stained in a 1.0 percent toluidine blue O solution. Ultra-thin sections were stained in uranyl acetate (Watson, '58) and lead citrate (Reynolds, '63) and examined in the Phillips 300 transmission electron microscope at 60 kV.

C. Results

Homozygous mutant hamsters in this strain were small in comparison to normal and heterozygous siblings, as revealed by mean body weight measurements (Table 2). Along with a general reduction in body size, homozygous mutant individuals possessed testes and epididymi which were reduced in size (Figs. 4-6). Although all mutant testes were hypoplastic, the severity of reduction was not uniform within the genotype as indicated by the large standard deviation in testes weights exhibited in Table 2. Six out of 10 mutant hamsters possessed testes which were severely reduced in size while four possessed testes which approached the normal phenotype. When normalized to body weight (Table 2), abnormal testes were more than proportionately reduced in size suggesting that the general growth retardation was not responsible for the severe reduction seen in testes weight.

Light Microscopy

It was evident from light microscopic examinations of testes from ten normal and ten heterozygous hamsters, that these testes were identical in composition and possessed large seminiferous tubules containing proliferating and differentiating germ cells. Spermatogonia were quite prevalent, lying adjacent to the basal lamina. A myriad of spermatozoa tails were seen filling the lumen of each tubule (Figs. 7-8). By contrast, the most severely affected mutant tissue, found in testes which were severely reduced in size, contained small seminiferous tubules in which spermiogenesis was arrested in the early spermatid stage (Figs. 9-10). Less affected mutant tissue, found in testes which approached the normal phenotype, contained seminiferous tubules with identical composition to normal and heterozygous tubules. Seminiferous tubules from mutant animals were reduced in size as revealed by mean diameter measurements (Table 2).

In order to determine the magnitude of the effect that the gene Wh had on body weight, testis weight and tubule diameter measurements (Tables 1 and 2), an analysis of variance was used (Tables 3 through 7). Since the variances for testis weight, testis weight normalized to body weight and tubule diameter were heterogeneous (Table 8) and since violations of the mathematical assumption of homogeneous variance will result in an underestimate of the true difference between genotypes, the modified f'-statistic of Brown and Forsythe (Gill, '78a) was employed

(Table 9). The Honestly Significant Difference (HSD) test of Tukey (Gill, '78b) was used to determine whether the heterozygous as well as the homozygous mutant individual contributed to the large differences observed in population means (Table 10).

Electron Microscopy

The ultrastructure of normal and heterozygous Leydig cells were identical in morphology and exhibited a classial appearance as described by Christensen ('65). The cells contained a large spherical nucleus with peripherally-disposed heterochromatin, and cytoplasm with a well developed Golgi complex, abundant mitochondria, polysomes, lipid droplets and vacuoles (Fig. 11). In common with other steriod-secreting endocrine cells (Christensen, '65), both normal and heterozygous Leydig cells possessed an extensive system of smooth endoplasmic reticulum (Fig. 12). Ultrastructural examination of all Leydig cells from animals severely affected by Wh suggested that these cells were in a state of degeneration. The nuclei contained clumped masses of peripherally- and centrally-disposed heterochromatin while the cytoplasm contained highly vesiculated agranular endoplasmic reticulum (AER), some mitochondria and lipid droplets (Figs. 13-14).

The ultrastructure of normal and heterozygous Sertoli cells also exhibited an identical and classial appearance as described by Dym ('73). These cells were found next to the basal lamina and contained numerous mitochondria, lipid droplets, a small Golgi zone, free polysomes and well developed agranular endoplasmic reticulum. Developing germ cells assumed their close relationship to Sertoli cells and were enveloped by the extension of the folds of cytoplasm. The lobulated nucleus was large and oval in shape (Figs. 15-16). Sertoli cells from all of the

Table 1. -- Measurements of Hamster Body Weight (g), Testis Weight (g), and Tubule Diameter (mm) from 10 Normal (+/+), 10 Heterozyhous (+/-) and 10 Mutant (-/-) Animals in the AN/AS-*Wh* Strain.

Animal Number (♂)	Generation (F)	Genotype	Age (days)	Body Weight (g)	Testis Weight (g)	Tubule Diameter (mm)
1766	3	whwhee (+/+)	178	101.20	2.18	17.5
1771	3		135	122.80	2.47	18.0
1750	3		219	116.10	2.40	17.5
1821	4		135	102.50	2.27	17.5
1822	4		136	99.90	2.42	18.0
1847	5		138	85.60	1.85	18.0
1867	5		136	94.30	2.32	23.5
1874	5		137	89.60	2.41	18.5
1889	6		141	95.30	2.50	16.5
1890	6		140	90.10	2.06	20.5
1763	3	Whwhee (+/-)	177	108.80	2.27	17.5
1825	3		136	95.50	2.27	18.0
1818	3		136	97.40	2.41	19.5
1797	3		188	106.10	2.22	20.5
1783	3		137	106.20	2.48	19.5
1858	5		136	88.20	1.68	21.0
1861	5		137	89.60	2.41	23.0
1866	5		137	90.50	2.35	18.5
1879	5		149	101.80	2.49	20.5
1883	4		137	92.60	2.34	23.0
1736	3	WhWhee (-/-)	239	95.00	0.18	08.5
1811	3		135	91.90	1.53	18.0
1812	3		136	82.10	0.42	14.0
1816	3		136	84.20	1.59	17.5
1803	4		135	83.40	1.53	19.0
1829	4		137	98.90	0.43	08.0
1782	3		135	91.90	0.19	07.0
1844	5		136	81.10	1.42	17.0
1857	5		135	96.40	0.49	08.0
1860	5		136	78.20	0.25	06.5

Table 2. -- Mean Measurements of Hamster Body Weight, Testis Weight and Tubule Diameters from Table 1.

Genotype (n)	Body (g)	Testes (g)	Testes/Body (%)	Tubule Diameter (mm)
whwhee (10)	99.74 ± 11.20	2.287 ± 0.236	2.31 ± 0.23	18.55 ± 2.02
Whwhee (10)	97.67 ± 7.22	2.292 ± 0.221	2.36 ± 0.25	20.10 ± 1.89
WhWhee (10)	88.31 ± 6.94	0.803 ± 0.592	0.93 ± 0.74	12.35 ± 5.19

All measurements were given as mean ± standard deviation. Seminiferous tubule diameters were taken from contact prints at 64 x magnification.

Table 3. -- Computations for the Analysis of Variance on Adult Body Weight Measurements from Table 1.

	+/+	+/-	-/-	
	101.20	108.80	95.00	
	122.80	95.50	91.90	
	116.10	97.40	82.10	
	102.50	106.10	84.20	
	99.90	106.20	83.40	
	85.60	88.20	98.90	
	94.30	89.60	91.90	
	89.60	90.50	81.10	
	95.30	101.80	96.40	
	90.10	92.60	78.20	
$(y_{i.})$	997.40	976.70	883.10	272119.72 [A]
r_i	10	10	10	30
$(\bar{y}_{i.})$	99.74	97.67	88.31	
S.E.	±11.20	±7.22	±6.94	
s_i^2	125.42	52.14	48.18	
Sum of Squared Observations within A Group				
	100734.86	95915.75	78468.45	275119.06 [B]
Correction Factor for Each Group				
	99480.68	95394.29	77986.56	272861.53 [C]
SS_y	2999.34			
SS_t	741.81			
SS_E	2257.53			
MS_T	370.90			
MS_E	83.61			

Table 4. -- Computations for the Analysis of Variance on Testis Weight Measurements from Table 1.

	+/+	+/-	-/-	
	2.18	2.27	0.18	
	2.47	2.27	1.53	
	2.40	2.41	0.42	
	2.27	2.22	1.59	
	2.45	2.48	1.53	
	1.85	1.68	0.43	
	2.32	2.41	0.19	
	2.41	2.35	1.42	
	2.50	2.49	0.49	
	2.06	2.34	0.25	
$(y_{i.})$	22.87	22.92	8.03	96.55 [A]
r_i	10	10	10	30
$(\bar{y}_{i.})$	2.287	2.292	0.803	
S.E.	±0.236	±0.221	±0.592	
s_i^2	0.0556	0.0487	0.3502	
Sum of Squared Observations within a Group				
	52.86	53.02	9.95	115.83 [B]
Correction Factor for Each Group				
	52.30	52.53	6.45	111.28 [C]
SS_y	19.28			
SS_T	14.73			
SS_E	4.55			
MS_T	7.37			
MS_E	0.169			

Table 5. -- Computations for the Analysis of Variance on Testis Weight as Percent of Adult Body Weight Measurements from Table 1.

	+/+	+/-	-/-	
	2.15	2.09	0.19	
	2.01	2.38	1.66	
	2.07	2.48	0.51	
	2.22	2.09	1.88	
	2.42	2.34	1.83	
	2.16	1.91	0.43	
	2.46	2.69	0.21	
	2.69	2.60	1.75	
	2.62	2.45	0.51	
	2.29	2.53	0.32	
$(y_{i.})$	23.09	23.56	9.29	104.31 [A]
r_i	10	10	10	30
$(\bar{y}_{i.})$	2.31	2.36	0.93	
S.E.	.23	.25	0.74	
s_i^2	.05	.06	0.55	
Sum of Squared Observations within a Group				
	53.79	56.08	13.58	123.45 [B]
Correction Factor for Each Group				
	53.31	55.51	8.63	117.45 [C]
SS_y	19.14			
SS_T	13.14			
SS_E	5.97			
MS_T	6.57			
MS_E	.22			

Table 6. — Computations for the Analysis of Variance on Tubule Diameter Measurements from Table 1.

	+/+	+/-	-/-		
	17.5	17.5	8.5		
	18.0	18.0	18.0		
	17.5	19.5	14.0		
	17.5	20.5	17.5		
	18.0	19.5	19.0		
	18.0	21.0	8.0		
	23.5	23.0	7.0		
	18.5	18.5	17.0		
	16.5	20.5	8.0		
	20.5	23.5	6.5		
$(y_{i.})$	185.50	201.00	123.50	8670	[A]
r_i	10	10	10	30	
$(\bar{y}_{i.})$	18.55	20.10	12.35		
S.E.	±2.02	±1.89	±5.19		
s_i^2	4.08	3.60	26.95		
Sum of Squared Observations within a Group					
	3477.75	4072.50	1767.75	9318	[B]
Correction Factor for Each Group					
	3441.03	4040.10	1525.23	9006.35	[C]
SS_y	648.00				
SS_T	336.35				
SS_E	311.65				
MS_T	168.18				
MS_E	11.54				

Table 7. — F- Test of the Hypothesis that Population Means are Identical for Average Weights of Various Organs.

	Mean Square between classes	df	Mean Square within classes	df	F
Body Weight	370.90	2	83.610	27	4.44*
Testes weight	7.37	2	0.169	27	43.58*
Testes/Body	6.57	2	0.220	27	29.86*
Tubule Diameter	168.18	2	11.540	27	14.57*

*Indicates significance at the five percent level where $F_{2,7} = 3.35$.

Table 8. — Hartleys F_{max}-test for Homogeneous Variance.

	+/+ vs +/-	+/+ vs -/-	+/- vs -/-
Body weight	2.40	2.60	1.08
Testes weight	1.14	6.30*	7.19*
Testes/Body	1.20	11.00*	9.17*
Tubule Diameter	1.13	6.61*	7.49*

*Indicates significance at the five percent level where $F_{max,9,9,}$ = 3.18.

Table 9. -- Modified f'-statistic of Brown and Forsythe to Compare Variances for Population Means which are Heterogeneous in Nature.

	SS_T	d	f	$\hat{v}$
Testes weight	14.73	0.3045	48.37*[(a)]	14.51
Testes/Body	13.14	0.44	29.86*[(b)]	12.57
Tubule Diameter	336.35	23.20	14.50*[(c)]	14.27

*Indicates significance at the five percent level where:

$^{(a)}f_{2,15} = 3.68$

$^{(b)}f_{2,13} = 3.41$

$^{(c)}f_{2.14} = 3.74$

Table 10. — Results from Tukey's Honestly Significant Difference (HSD) Test Comparing Means Summarized in Table 2.

	+/+ vs +/-	+/+ vs -/-	+/- vs -/-
Body weight	0.716	3.96*	3.24
Testes weight	0.385	11.42*	11.45*
Testes/Body	0.338	9.32*	9.66*
Tubule Diameter	1.450	5.79*	7.25*

*Indicates significance at the five percent level where $q_{3,27} = 3.509$.

severely affected mutant testicular tissue again exhibited an appearance suggestive of a degenetative condition. These cells assumed a position further towards the lumen of the tubule due to reduplication and invagination of the basal lamina, and contained some mitochondria, Golgi and endoplasmic reticulum. In addition, these cells contained numerous large osmiophilic and non-osmiophilic lipid droplets, while the absence of more mature germ cells was associated with total vacuolation towards the tubular lumen (Figs. 17-18).

Since light microscopic examination of the germinal epithelium from all animals severely affected by Wh indicated that spermiogenesis was arrested at the early spermatid stage, an electron microscopic examination of germ cell development was undertaken. In the normal condition, early spermatids contained a Golgi apparatus which developed in the juxtanuclear cytoplasm (Fig. 19). Several proacrosomal granules, enclosed within a membrane limited vesicle of the Golgi, fused into a single large acrosomal granule which was contained within a membrane-bound acrosomal vesicle. The acrosomal vesicle, containing the granule, became adherent to the outer aspect of the nuclear envelope, while the Golgi apparatus continued to form small vesicles feeding into the membrane of the acrosomal vesicle. The limiting membrane of the acrosomal vesicle increased its area of adherence, forming a thin fold that initially spread over the anterior one-third of the nucleus. The bulk of the acrosomal granule remained localized at the anterior pole, gradually spreading as a thin layer into the fold (Fig. 19), giving rise to the acrosome. As differentiation proceeded within the Sertoli cytoplasm, condensation of nuclear chromatin along with development and attachment of the tail followed the normal progression of events leading to the formation of spermatozoa (Fig. 21).

Early spermatids from all of the severely affected abnormal tissue lacked the well-defined Golgi apparatus, since the Golgi seemed to degenerate promptly after the formation of the granule at the anterior pole of the nucleus. Commensurate with the normal condition, the limiting membrane of the acrosomal vesicle spread over the anterior one-third of the nucleus. However, spreading of the acrosomal contents did not occur (Fig. 20). The cytoplasm, irrespective of the Golgi, also exhibited major degenerative changes exemplified by the overabundance of large lipid inclusions and lysosomal vacuoles. The marked degeneration seen in the developing germ cells resulted in tubules which were completely devoid of spermatozoa of spermatozoal tails and consisted mostly of cellular debris (Fig. 22).

D. Discussion

Past breeding data indicated that most hamsters homozygous for the gene _Wh_ in the AN/As-_Wh_ strain were sterile. In this investigation, testes from six mutant hamsters were severely affected by the gene _Wh_. These testes exhibited a severe reduction in both size and weight. Testes from four mutant hamsters were only slightly affected by the gene. These testes were atrophic, but morphologically and histologically resembled those of their normal matched-siblings. Thus, the expression of the gene _Wh_ among individuals varied considerably from almost complete atrophy of the testes to almost normal testes. Since the hamsters used in this study were from generations F3 to F5, they should only be identical for 6 to 29 percent of their genome (Falconer, '60). Because of the low percentage of inbreeding, animals could differ by numerous genes, including genes near the _Wh_ locus. Matched-siblings were employed for comparisons between genotypes in order to eliminate possible problems caused by this difference in genetic background, although great variability existed in comparisons made within a genotype. Since the purpose of this investigation was to explore the question of infertility in anophthalmic homozygotes, the remaining discussion will focus on those mutant animals which were most severely affected by the gene Wh.

At the anatomical level, hamsters severely affected by the gene Wh possessed atrophic testes. Seminiferous tubules from atrophic testes were reduced in size, were aspermic and contained germinal cells arrested in the early spermatid stage of spermiogenesis. A highly significant genotypic difference existed in mean testicular weights and tubule diameters (Tables 2 and 7-9). Comparing data for all doses of the gene, the large difference in mean testicular weights and tubule diameters was due to animals which were homozygous for Wh (Table 10).

At the ultrastructural level, major morphological differences in Leydig cells, Sertoli cells and developing germ cells were observed in normal and heterozygous testicular tissue in comparison to mutant tissue.

Studies by Christensen ('65) revealed that the characteristic agranular endoplasmic reticulum (AER) of the steroid-secreting Leydig cell was difficult to preserve for electron microscopy. According to his study, the tendency toward vesiculation of the AER was minimal in tissue fixed with glutaraldehyde without perfusion and was virtually absent in material perfused with glutaraldehyde. The appearance of normal and heterozygous Leydig cells in this study was consistent with those in previous reports on guinea pig (Christensen, '65) and mouse (Christensen and Fawcett, '66). Since abnormal tissue was processed in exactly the same manner, it was concluded that the degenerative condition of this cell type was indicative of abnormal tissue and not an artifact of fixation.

The appearance of normal and heterozygous Sertoli cells in this study was consistent with those in previous reports of monkey (Dym, '73) and human (Schultze, '74). Sertoli cells from abnormal testicular tissue were highly vacuolated and contained numerous osmiophilic and non-osmiophilic lipid droplets.

Spermatogenesis and spermiogenesis proceeded properly in normal and heterozygous tubules, whereas spermiogenesis arrested at the early spermatid stage in mutant tubules. The Golgi phase (Sa) of early spermatid formation was consistent with studies by deKretsler ('69). All Sa spermatids possessed an oval nucleus and a prominent Golgi apparatus which was perinuclear and showed evidence of formation of membrane-bound pro-acrosomal granules. Normal apposition of the acrosomal granule and vesicle to the nuclear membrane took place. The cap phase of the Sb_1 stage (deKretsler, '69) included spreading of the acrosomal vesicle over the anterior pole of the nucleus, forming the head cap. During the cap phase, the acrosomal granule remained anterior and centrally positioned.

It is evident that the arrest of spermatid formation occurred in the acrosomal phase of the Sb_1 stage (deKretsler, '69), exemplified by the failure of the acrosomal granule to spread and fill the head cap (Fig. 20). The Golgi apparatus showed signs of degeneration, suggesting that premature failure of the Golgi, which was no longer capable of feeding vesicles into the head cap, was the cause of infertility in this mutant. This further suggested that continued function of the Golgi apparatus contributed to the acrosomal phase. The significance of this contribution has not been objectively dealt with in the past, since it was commonly thought that the Golgi functions solely in the production of the acrosomal granule. However, the present study suggests that extension of the acrosome is dependent on continued function of the Golgi apparatus throughout the acrosomal phase and the Golgi begins its posterior migration only after proper acrosomal formation has occurred. Similarly, the nucleus of the normal and heterozygous Sb_1 spermatid had started to elongate (Fig. 19), while the nucleus of the mutant Sb_1 spermatid was still oval (Fig. 20). Pedersen and Rebbe ('74) and Holstein _et al_. ('73) reported that the absence of the acrosome in infertile men resulted in a high percentage of round-headed sperm. The results of these studies, along with the present study, also suggest that changes in nuclear shape from oval (Sb_1 spermatids) to pear-shaped (Sb_2 spermatids) may be dependent on normal acrosome development.

Therefore, the present study has confirmed that the primary cause of male infertility in anophthalmic hamsters was the failure of mutant testes to produce spermatozoa. The data showed that abnormalities existed in Leydig cells, Sertoli cells, and in the developing germ cells from the testes of homozygous mutant hamsters. Since the single primary action of the gene is unknown, several hypotheses can be formulated to try to explain the effects of this gene on reproduction in the Syrian hamster. Speculation as to the primary cause of the aforementioned abnormalities might include: (1) a defect at the level of the testes along, (2) a defect at the level of the pituitary (or high regulatory centers) or, (3) a phenomenon of eyelessness.

Studies by Dym ('73) suggested that the production of spermatozoa was largely dependent on the normal function of the Sertoli cell. If this gene acted primarily to alter membrane function in the testes, Sertoli cells might not respond to hormonal stimulation by FSH to trigger the enzymatic or biochemical processes necessary for proper germ cell development. On the other hand, studies by Christensen ('65) proposed that the membrane of the AER in the Leydig cell was the location of enzymes essential to steroid biosynthesis. Vesiculation of the AER along with the virtual absence of lipid droplets and mitochondria, containing villous cristae and an electron dense matrix, might suggest an alteration of the biosynthetic activity in the Leydig cells of severely affected mutant tissue. It is not impossible, but highly improbable, that a pleiotropic gene, affecting pigmentation, eye development and reproduction, exerts its primary effect on the testes alone.

Smith ('27) first reported that the pituitary gland was responsible for the maintenance of gonad function. Studies by Smith ('30) and Greep and Fevold ('36; '37) first indicated that pituitary hormones were essential in spermiogenesis from the spermatocyte stage through the spermatozoa, but not for the earlier stages. Lostroh ('69) reported that spermatogonia persisted after hypophysectomy and did not require exogenous hormone to evolve to the pachytene stage of the primary spermatocyte. Thus, no hormone requirement existed in germ cell development from the spermatogonium to prophase of the primary spermatocyte. Testosterone was found to be necessary to transform the prophase spermatocyte to the metaphase spermatocyte (Lostroh, '76). Modest levels of FSH and LH were necessary for spermatid development while substantial levels of FSH, LH and testosterone were required for maturation of spermatids to spermatozoa (Lostroh, '76). Since germ cell development arrested at the spermatid stage in mutant tubules, one prudent argument might be made for the suppression of gonadotropin secretion from the pituitary gland. This hypothesis is consistent with studies by Steinberger and Dunkett ('65) who indicated that suppression of gonadotropin secretion resulted in incomplete spermatid formation in rat testes. It is also well known that testosterone alone does not promote normal germ cell development in gonadotropin-deficient mammals (Steinberger and Dunkett, '65; Lostroh, '69; utuly and Cutuly, '40). The most advanced germ cell development in hypophysectomized and testosterone treated rats included spermatids, which were randomly distributed in the tubules and appeared abnormal (Lostroh, '69). Commensurate with the observation that mutant Sertoli cells contain numerous lipid droplets were studies by Lynch and Scott ('51) who demonstrated that hypophysectomized animals showed a dramatic increase in lipid accumulation. Therefore, if the gene causes a defect in the maintenance of gonad function, the pituitary gland, or higher regulatory centers may be involved. This possibility is currently under investigation.

A third proposal for the primary effect of this gene on reproduction is that the abnormalities presented were due solely to the lack of vision, due to the failure of proper eye development (Asher, '68) and the absence of the visual pathway (unpublished results). It is well known that light, perceived by the eyes, plays a major role in mammalian production. The reproductive organs of male and female golden hamsters are particularly sensitive to darkness as seen by the rapid involution of these organs when animals were experimentally blinded (Reiter and Hester, '66; Reiter, Hoffman and Hester, '66; Reiter, '68a,b) or exposed to short photoperiods (Hoffman and Reiter, '65; '66). The reduction in testicular size and weight caused by the gene <u>Wh</u> (Tables 2, 7 through 10) was consistent with the aforementioned studies by Reiter and Hester ('66), Reiter, Hoffman and Hester ('66) and Reiter ('68a,b), who first reported a severe reduction in testicular size and weight in experimentally blinded hamsters. Similarly, involution of the seminiferous epithelium, accompanied by a concomitant decrease in tubular size and a thickening of the basement membrane was observed in experimentally blinded hamsters (Reiter, '67) as well as in the genetically blinded (WhWh) hamsters reported here.

Histologically, the atrophic testes of experimentally blinded hamsters exhibited a complete loss of spermatogenesis (Reiter, '67) whereas testes from genetically anophthalmic hamsters exhibited an arrest at the early spermatid stage of psermiogenesis. This result may be due to strain differences, although the cream gene has no apparent effect on reproductive ability in the Syrian hamster. It is also plausible that the technique of electron microscopy has made it possible to more clearly differentiate the developing germ cells in testicular tubules, since normal hamsters in the AN/As-Wh strain which have been experimentally blinded possess tubules identical in composition to those from anophthalmic individuals (unpublished results).

The exact mechanisms whereby light deprivation alters gonal function remains unknown. It has been suggested by Reiter ahd Hester ('66) that the pineal gland, activated by the absence of light, alters the central control of either the synthesis or release of pituitary gonadotropins. Reiter ('68) suggested that the pineal influences reproduction by modifying the neruoendocrine axis, rather than a direct effect on the target organs. Recent studies by Quay ('74) suggest that the pineal gland exerts a retardant effect on hypothalmic-pituitary activity in general.

Since the effects of the gene Wh in the Syrian hamster closely parallel the effects of experimental blinding, the infertility observed in anophthalmic homozygotes (WhWh) is probably caused by the absence of eyes. Much of the evidence presented in this investigation also points to a defect in endocrine control of testes function, which may or may not be related to anophthalmia. Thus, further embryological, anatomical, and physiological examination of this mutant will provide useful information as to the effects of anophthalmia on reproduction, and may further reveal the primary action of the gene Wh in the Syrian hamster.

ABBREIVATIONS

A,	Acrosomal contents
AER,	Agranular endoplasmic reticulum
BL,	Basal lamina
CD,	Cellular debris
e,	Epididymis
FP,	Free polysomes
G,	Golgi
GC,	Developing germ cells
GE,	Germinal epithelium
H,	Heterochromatin
L_1,	Osmiophylic lipid
L_2,	Non-osmiophilic lipid
LP,	Lipofuchsin pigment
M,	Mitochondria
N,	Nucleue
OLM,	Outer limiting membrane of the acrosomal vesicle
PSP,	Primary spermatocyte
S_1,	Early spermatid
S_2,	Late spermatid
SC,	Sertoli cytoplasm
SER,	Smooth endoplasmic reticulum
SG,	Spermatogonia
SH,	Spermatozoal head
SN,	Sertoli nucleus
ST,	Spermatozoal tail
T,	Testis
V,	Vacuole

PLATE 1

EXPLANATION OF FIGURES

1. Homozygous normal hamster of the genotype whwhee.
2. Heterozygous hamster of the genotype Whwhee.
3. Homozygous mutant hamster of the genotype WhWhee. Note the absence of eyes and pigmentation.
4. Testis (T) and epididymis (e) from a homozygous normal hamster.
5. Testis (T) and epididymis (e) from a heterozygous hamster.
6. Testis (T) and epididymis (e) from a homozygous mutant hamster. Note the reduction in testis size.

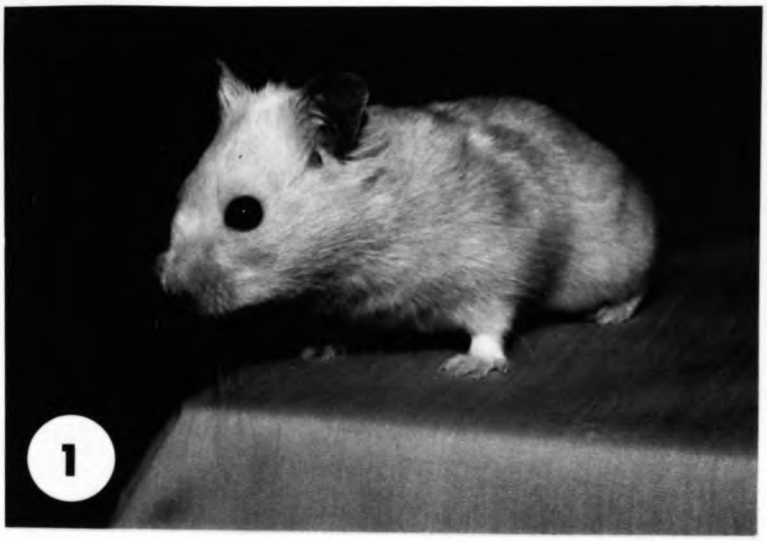
1


4


2

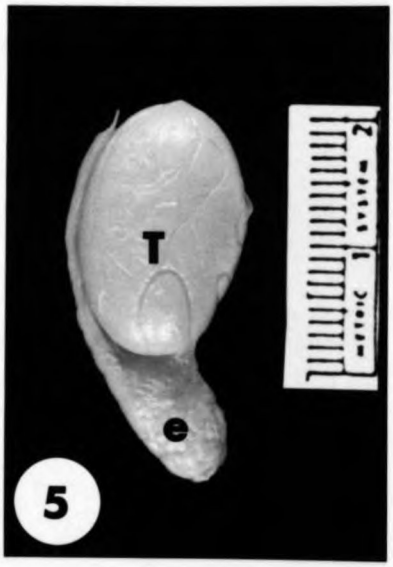
5


3

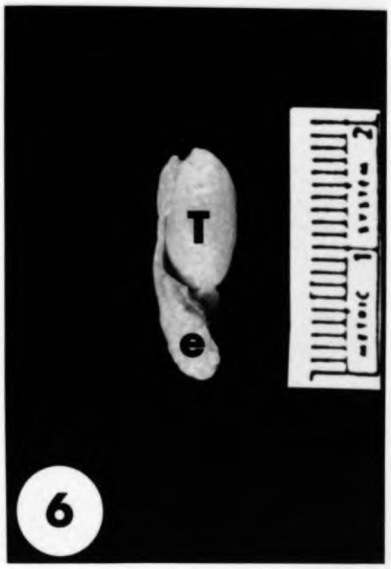
6

PLATE 2

EXPLANATION OF FIGURES

Figures 7 and 9 are 5 μm paraffin sections stained with Hemotoxylin and Eosin. For increased resolution, Figures 8 and 10 are 1 μm Epon sections stained with Toluidine Blue O.

7. Light micrograph of normal/heterozygous seminiferous tubules. The germinal epithelium (GE) proliferates and differentiates within each tubule to form spermatozoa which are seen as heads (SH) and tails (ST) filling the tubular lumen. x 256. (Paraffin, H and E)

8. Light micrograph of normal/heterozygous germinal epithelium from a field comparable to that in the box in Figure 7. Note spermatogonia (SG) and Sertoli nuclei (SN) lying adjacent to the basal lamina (BL), along with maturation of the germinal epithelium to the late spermatid stage (S_2). x 640. (Epon, Toluidine Blue)

9. Light micrograph of mutant seminiferous tubules. Note the reduction in tubular diameter along with the lack of properly differentiated germinal epithelium (GE). x 256. (Paraffin, H and E)

10. Light micrograph of mutant germinal epithelium in a field comparable to that in the box in Figure 9. Note the thickened basal lamina (BL) and the arrest of spermiogenesis in the early spermatid stage (S_1). x 640. (Epon, Toluidine Blue)

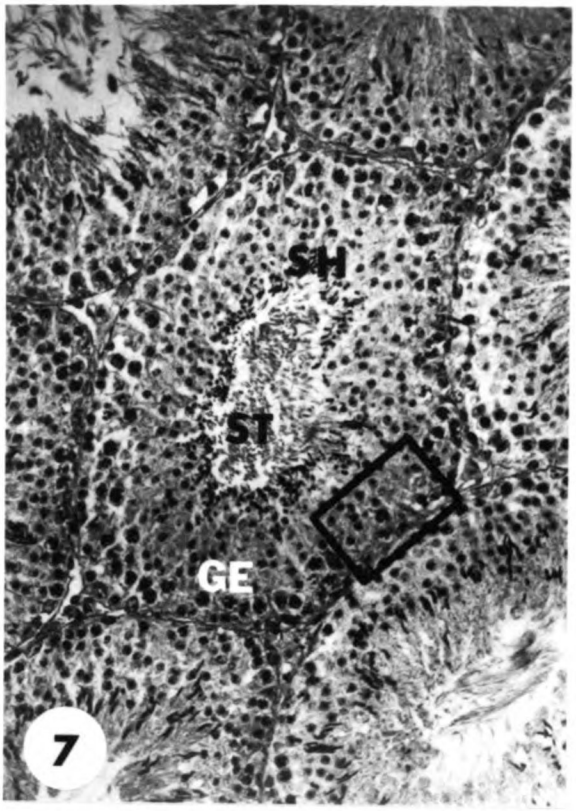
SH
ST
GE
7

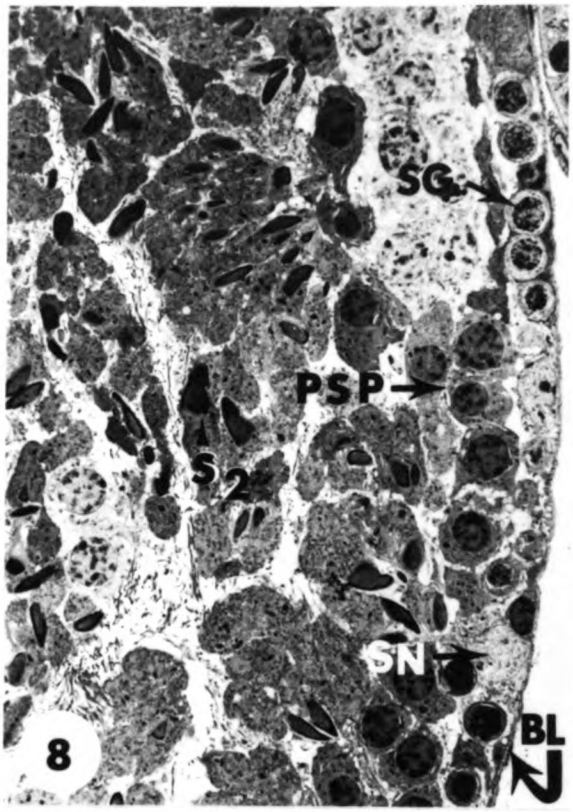
SG
PSP
S2
SN
BL
8


GE
9

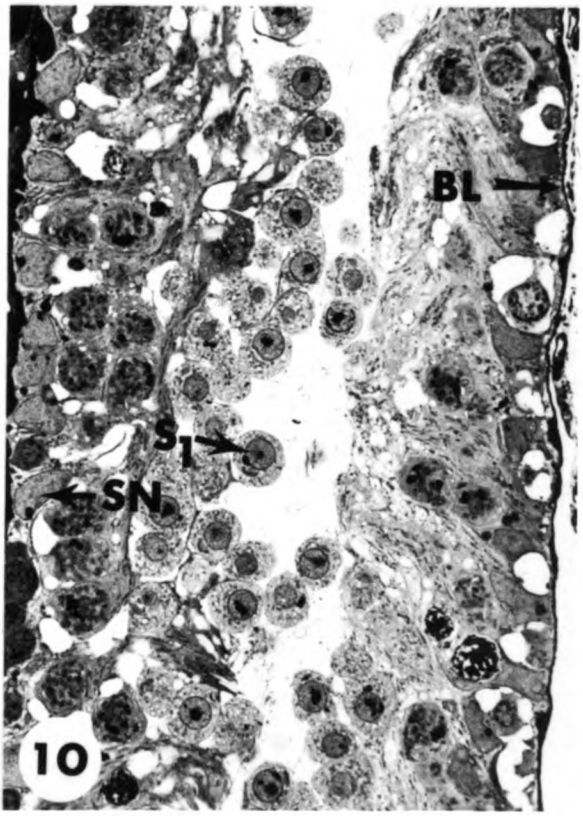
BL
S1
SN
10

PLATE 3

EXPLANATION OF FIGURES

11. Electron micrograph of a normal/heterozygous Leydig cell. Note the abundance of mitochondria (M) and lipid (L_1). x 6,900.

12. Electron micrograph of normal/heterozygous Leydig cytoplasm. Note the abundance of smooth endoplasmic reticulum (SER). x 25,000.

13. Electron micrograph of mutant Leydig cells. Note the degenerative condition of these cells which is exemplified by the clumped nuclear heterochromatin (H) and lack of defined cytoplasmic organelles. x 4,800.

14. Electron micrograph of mutant Leydig cell cytoplasm. Note the vacuolated state of the smooth endoplasmic reticulum (SER) along with the lack of mitochondria and lipid. x 19,750.

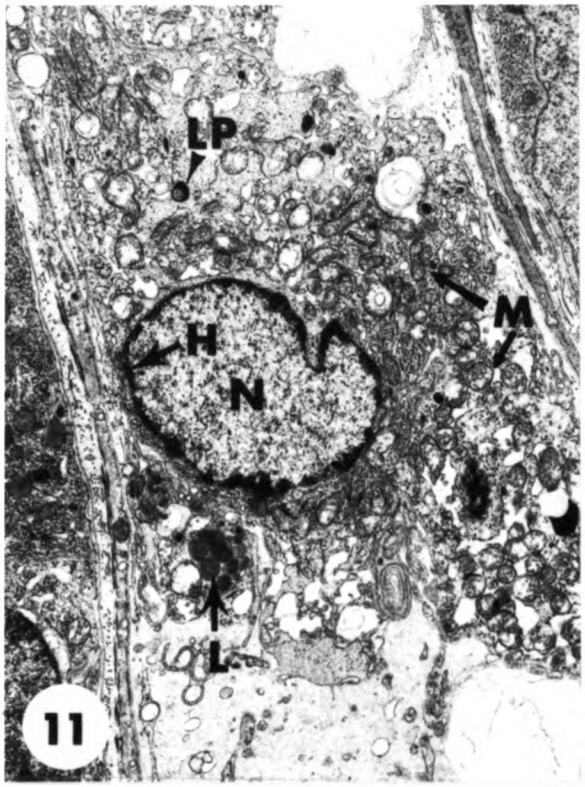
LP
M
H
N
L
11

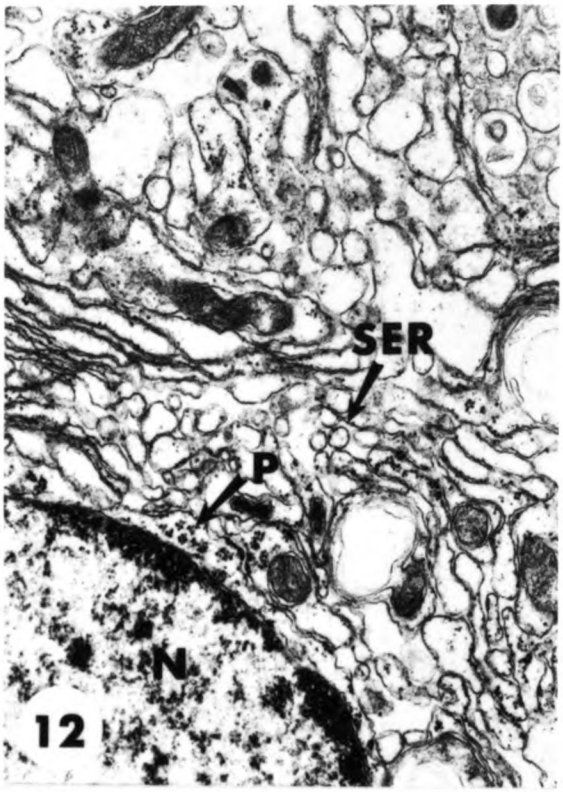
SER
P
N
12

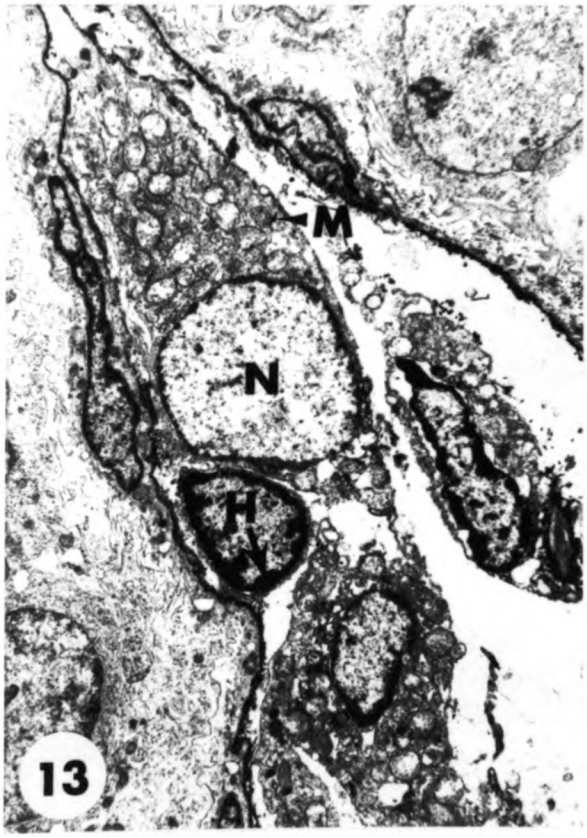
M
N
H
13

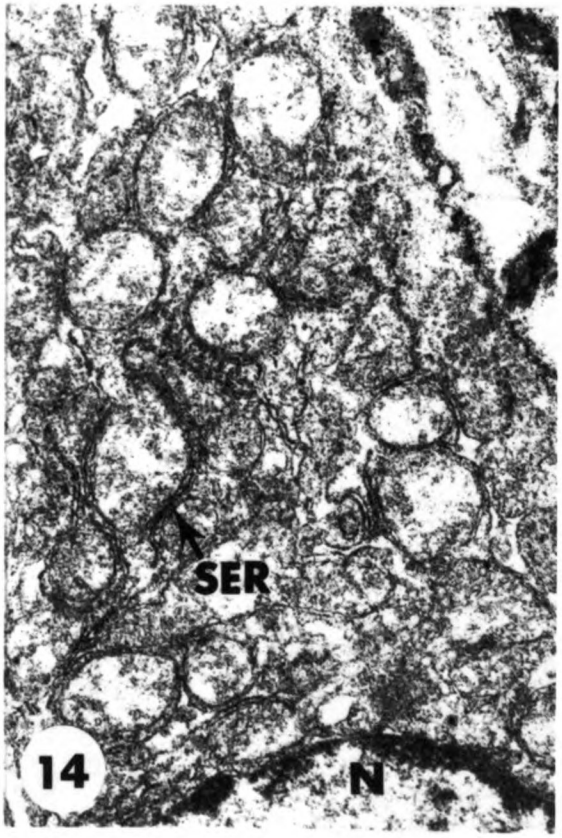
SER
N
14

PLATE 4

EXPLANATION OF FIGURES

15. Electron micrograph of a normal/heterozygous Sertoli cell. The large lobulated Sertoli nucleus (SN) assumes a position next to the basal lamina (BL). Developing germ cells (GC) are found embedded within the Sertoli cytoplasm (SC). x 5,850.

16. Electron micrograph of normal/heterozygous Sertoli cell cytoplasm. x 18,750.

17. Electron micrograph of mutant Sertoli cells. Note the position of the nucleus (SN) next to the basal lamina (BL) which has reduplicated and invaginated (arrow) toward the tubular lumen. Sertoli cell cytoplasm (SC) does not envelope developing germ cells and hence appears vacuolated (V) towards the lumen. x 5,850.

18. Electron micrograph of mutant Sertoli cell cytoplasm. Note the abundance of osmiophilic (L_1) and non-osmiophilic (L_2) lipids within the cytoplasm. x 18,750.


SC
GC
SN
BL
15

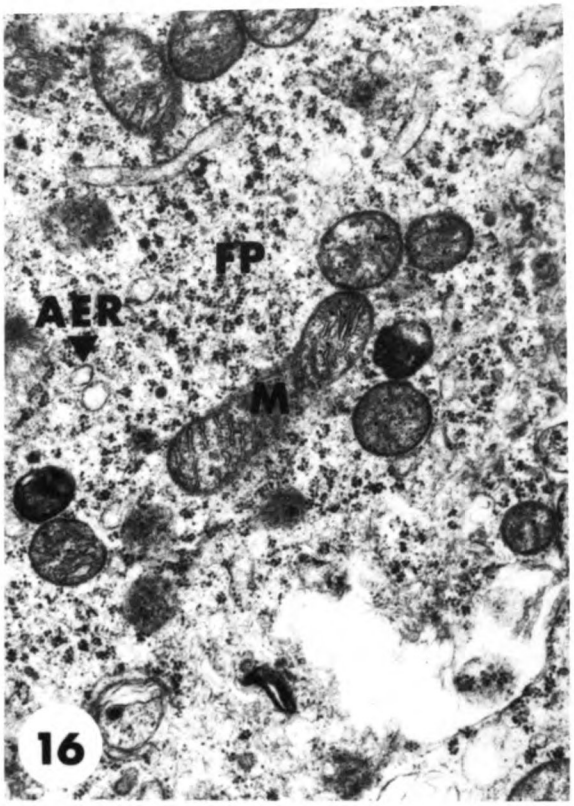
FP
AER
M
16

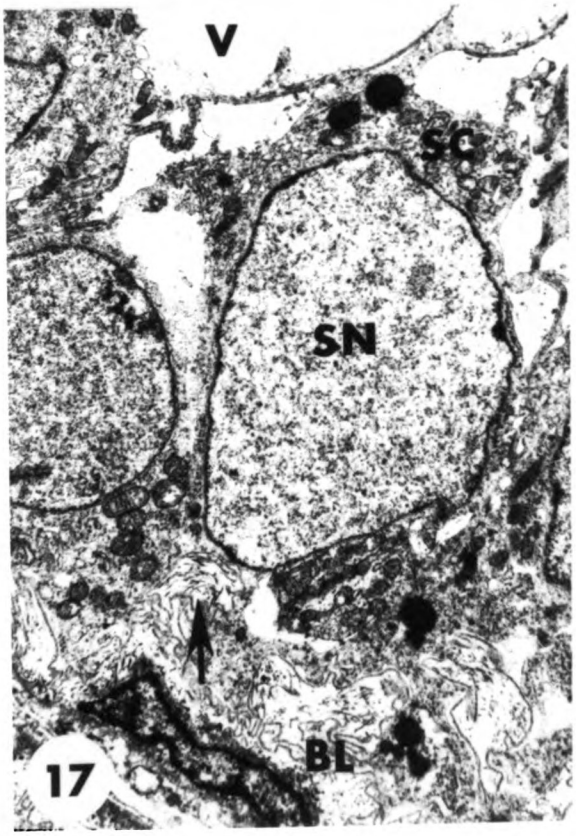
V
SC
SN
BL
17


L2
L1
18

PLATE 5

EXPLANATION OF FIGURES

19. Electron micrograph of an early spermatid from normal/heterozygous testicular tissue. The Golgi apparatus (G) in the juxtanuclear cytoplasm produces material which feeds into the acrosomal vesicle (arrow). x 21,875.

20. Electron micrograph of an early spermatid from mutant testicular tissue. Note the degenerative appearance of the Golgi apparatus (G), vacuolation of the cytoplasm (V) and restriction of the acrosomal contents (A) to the anterior pole of the nucleus. x 21,875.

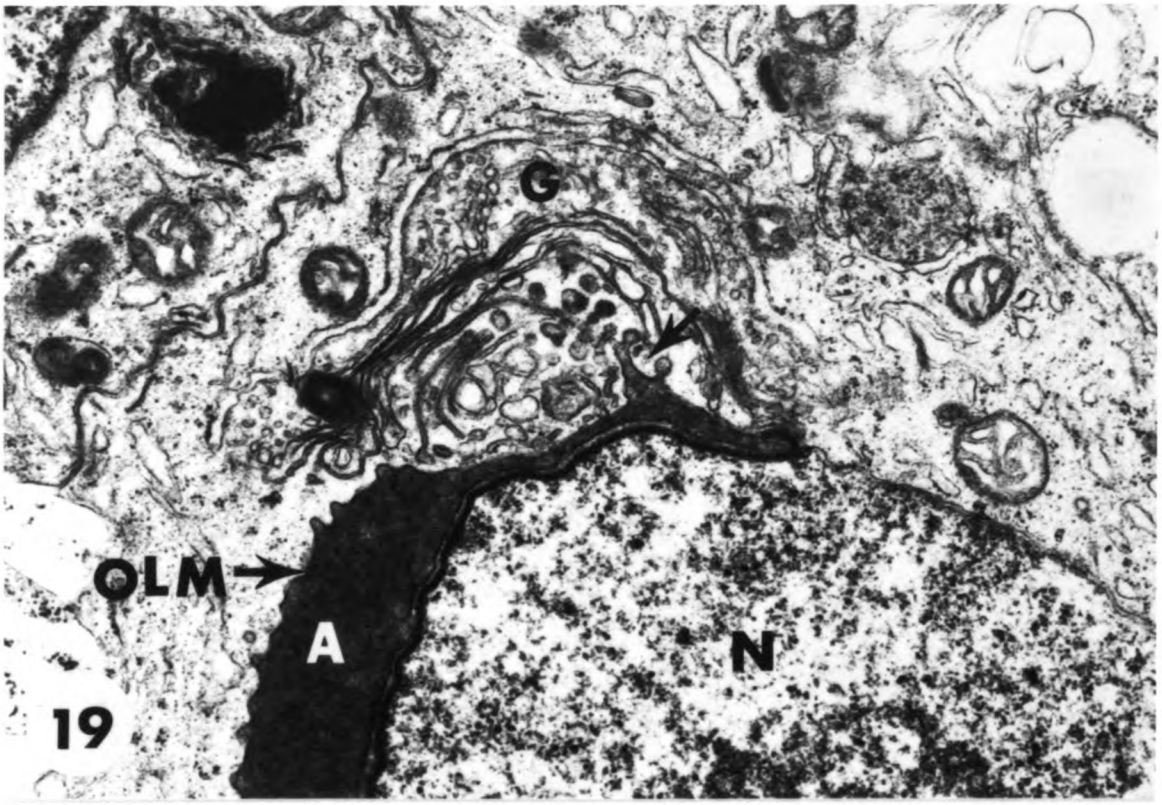
G
OLM
A
N
19

PLATE 6

EXPLANATION OF FIGURES

21. Electron micrograph of normal/heterozygous germinal epithelium towards the tubular lumen. Note spermatozoal head (SH) and tail (ST) enveloped by the Sertoli cytoplasm (SC). x 5,600.

22. Electron micrograph of mutant germinal epithelium towards the tubular lumen. Note that the absence of germ cells was accompanied by tubules filled with cellular debris (CD). x 7,200.

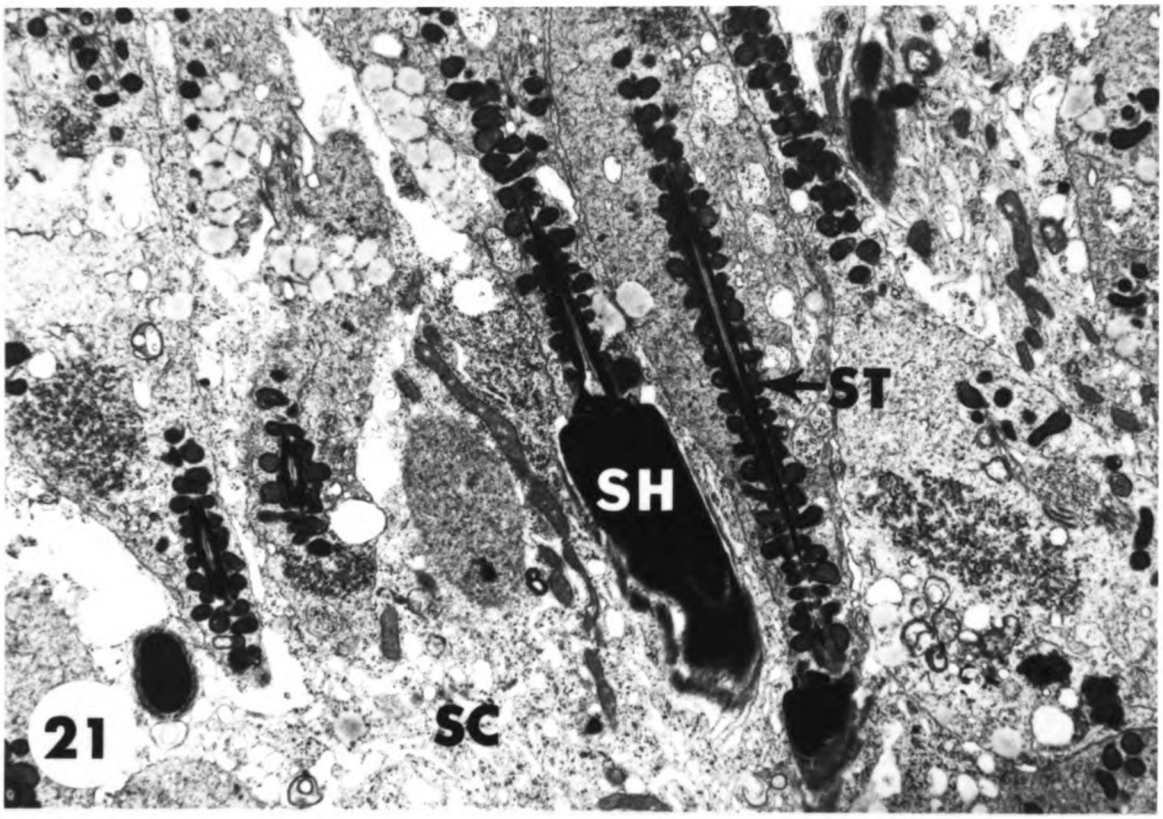
21
SH
ST
SC

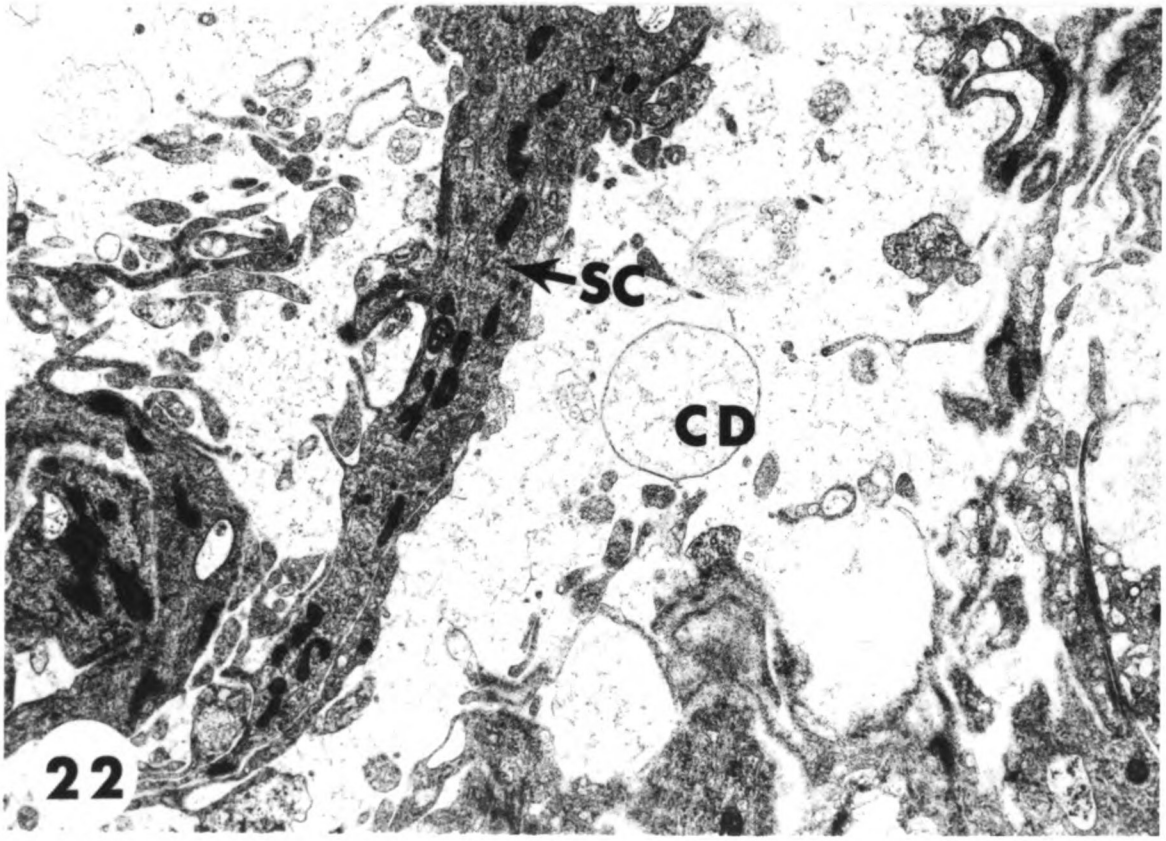
22
SC
CD

CHAPTER 3

AN ELECTRON MICROSCOPIC EXAMINATION OF THE PITUITARY GLAND OF THE SYRIAN HAMSTER MUTANT ANOPHTHALMIC WHITE (Wh)

A. Introduction

Previous studies of the gene Wh, Anophthalmic white, in the Syrian hamster revealed that animals homozygous for this gene were anophthalmic (Knapp and Polivanov, '58; Robinson, '62; '64; Asher, '68; Yoon, '73; '75), exhibited a complete absence of skin and coat pigmentation (Robinson, '62; '64; Asher, '68), exhibited severe growth retardation (Asher, '68; Chapter 2), and lacked reproductive ability (Knapp and Polivanov, '58; Asher, '68; Chapter 2). Along with these obvious defects, earlier studies by Asher ('68) suggested that growth retardation, sexual infantilism and adrenal insufficiency were the result of an improper hormone balance due to improper pituitary function, caused by ammonia toxification during development.

The study in Chapter 2 revealed that most male hamsters homozygous for the gene Wh in the AN/As-Wh strain possessed atrophic testes. These atrophic testes contained small seminiferous tubules, abnormal Leydig and Sertoli cells and possessed germ cells arrested in the early spermatid stage of spermiogenesis. This investigation also suggested that the primary cause of infertility in eyeless homozygotes might be correlated with a defective hypophysis, since it is known that the pituitary is responsible for the maintenance of gonad function (Smith, '27; '30) and that the pituitary hormones FSH and LH are essential to spermiogenesis (Smith, '30; Greep and Fevold, '36; Greep, Fevold, and Hisaw, '37; Lostroh, '76).

Therefore, the present study was undertaken to determine whether abnormalities existed in hypophyses of male hamsters homozygous for the mutant gene *Wh* and whether a correlation existed between the hypophysis and the testicular abnormalities described in Chapter 2. Since the purpose of this investigation was to correlate pituitary and gonal activity, only the "sex zone" (Baker and Gross, '78) of the pars distalis was examined.

B. Materials and Methods

The strain used in this investigation was designated AN/As-*Wh* by Asher ('68) and is maintained by a system of full-sibling mating where at least one parent is heterozygous for *Wh*. Hamsters were housed in polycarbonate cages with galvanized or stainless steel tops, cleaned weekly and provided with pine shavings for bedding. Wayne Laboratory or Breeder Chow and water were provided *ad libidum*. Lighting of the animal room was on a regime of 13 hours of light and 11 hours of darkness.

The same sets of ten matched-siblings at approximately 135 days of age were used in this investigation as were used in the testicular study described in Chapter 2. Activity patterns for each animal were determined on running wheels over a one week period prior to killing. Four hours prior to the calculated onset of running activity, hamsters were weighed, anesthetized with ether, and perfused through the left ventricle with Ringer's solution followed by 0.5 percent cacodylate buffered glutaraldehyde at pH 7.3 (Glauert, '75a). The time from anesthetization to perfusion with fixative took approximately 3 minutes.

After perfusion and removal of the superior part of the cranium, hypophyses were excised and immersed in 0.5 percent cacodylate buffered glutaraldehyde at pH 7.3 (Glauert, '75a). Some of the glands were photographed. With the aid of a dissecting microscope, the pars intermedia and the infundibular processes were carefully separated from the pars distalis and discarded. A mid-sagital cut was made in the pars distalis (B of Fig. 1), along with two cross cuts (A of Fig. 1), to divide the gland into four pieces of tissue (1 through 4 of Fig. 1). Each piece of tissue, which was approximately one millimeter in width, was post-fixed in 2.0 percent cacodylate buffered osmium tetroxide (Glauert, '75b), and embedded in Epon-Araldite (Mollenhauer, '64). Random think and thin mid-sagital sections, found ventromedial to the hypophyseal cleft (shadded boxes in B-B of Fig. 1), were examined.

Thick Epon-embedded sections (1 μm) were stained with a 1.0 percent solution of toluidine blue O, examined and photographed with a Zeiss light microscope. All nuclei were counted and cellular densities were calculated from replicate, 10 x 7 cm plots, taken from photographs printed at 680X magnification. Ultra-thin sections were stained in uranyl acetate (Watson, '58), and lead citrate (Reynolds, '63) and examined in the Phillips 300 electron microscope at 60 kV.

C. Results

In this investigation, no gross anatomical differences existed in the hypophyses of male animals in the AN/As-_Wh_ strain. All glands possessed a pars distalis, pars tuberalis, pars intermedia, infundibular

Fig. 1. A schematic representation of the areas of the hypophysis processed for light and electron microscopy. After removal of the pars intermedia and infundibular process, a mid-sagital cut (B) was made in the pars distalis, along with two cross cuts (A), to divide the gland into four pieces of tissue (1 through 4). Sections were examined from the medial zone, ventral to the hypophyseal cleft (shaded boxes in B-B). P, peripheral zone; L, lateral zone; HC hypophyseal cleft.

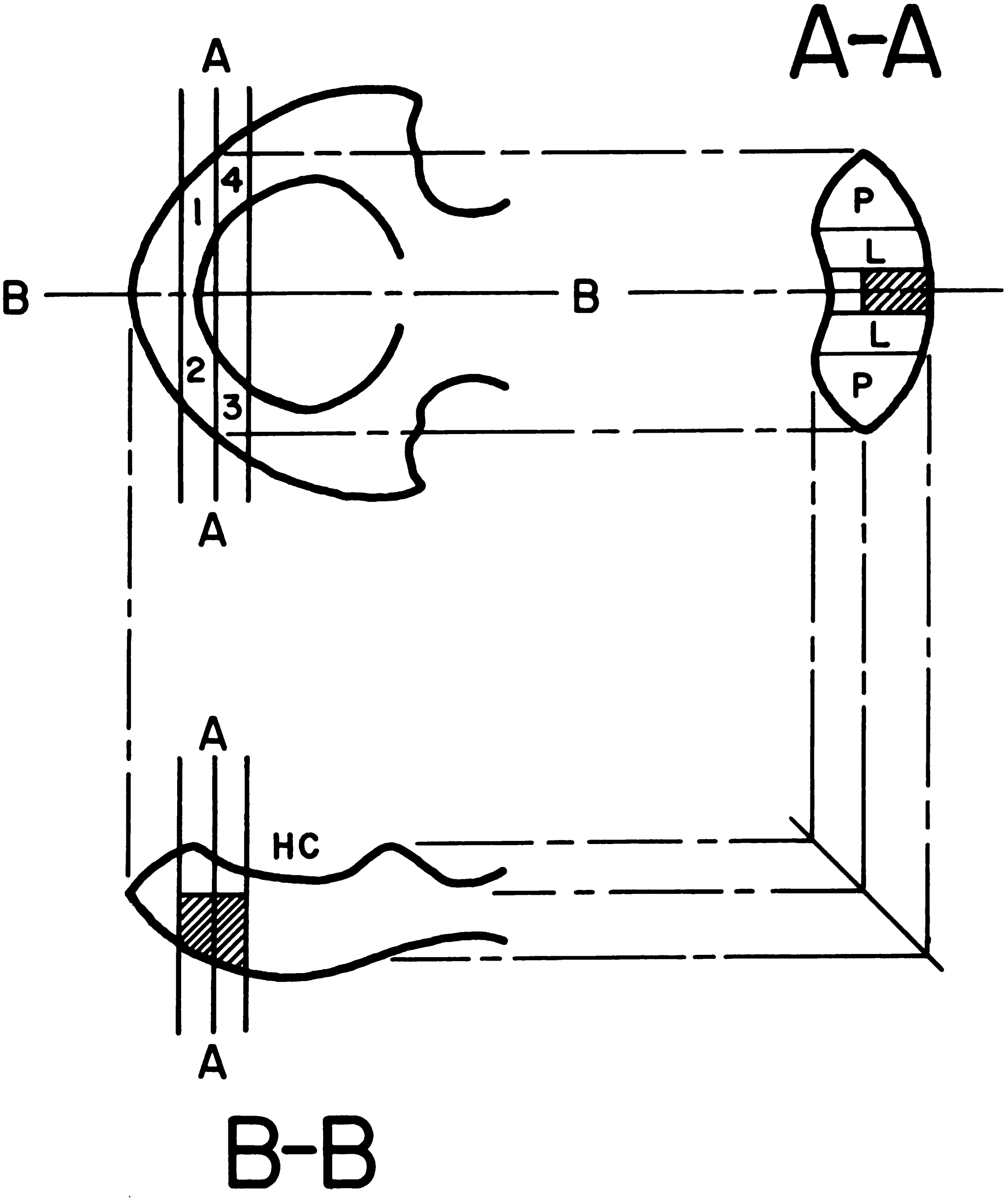
A-A
A
4
1
B
B
2
3
A
P
L
L
P
A
HC
A
B-B

process and infundibular stem (Figs. 2-5). All pars intermedia and infundibular processes were in close apposition to one another and were separated from the pars distalis by the hypophyseal cleft. Unfortunately, no weight measurements were taken to determine if weight differences existed between genotypes.

At the light microscopic level, ventromedial sections of the pars distalis from ten normal and ten heterozygous tissues were identical in composition and contained closely packed cells which were arranged in irregular anastomosing cords, separated by capillary channels. In cross section, these cords were seen as nests or rosettes made up of 8 to 9 cells. Acidophils, basophils, and chromophobes were present in a single cord or rosette. Each cell contained a large centrally or eccentrically positioned nucleus, while acidophilic and basophilic cells possessed darkly stained secretory granules (Fig. 6). Ventromedial sections of the pars distalis from 9 mutant tissues contained some cords or rosettes of cell which approached the normal phenotype. However, many of the cells in this region contained darkly stained nuclei, which were oriented to one side near the cell membrane, and one large cytoplasmic vacuole. These vacuolated structures were greatly enlarged and at the light microscopic level seemed to be completely devoid of cell cytoplasm, secretory granules and cellular organelles (Fig. 7).

Since hypophyses of mutant tissue appeared to contain fewer cells per plot, a comparison of cellular densities was made between genotypes. Mean measurements of cellular densities (Tables 1 through 3) demonstrated that the glands from anophthalmic individuals contained approximately 40 percent fewer cells per plot than did the glands from normal and heterozygous individuals. An analysis of variance (Gill, '78a), comparing means from Table 3, proved that a highly significant reduction in cell number existed in mutant tissue (Table 4). A linear regression analysis (Gill, '78c) was performed to determine whether the reduction in pituitary cell density was correlated with differences in testis size found in homozygous mutant individuals (Chapter 2). When the number of nuclei per plot was regressed against the gram percent body weight of the testis, a significant correlation was observed between the reduction in cell densities of the hypophysis and the severity of testicular involution caused by the gene (Table 5).

At the electron microscopic level, the fine structure of gonadotropes from 10 normal and 10 heterozygous tissues were identical in composition. These cells were large and polyhedral, measuring 10 to 15 μm in diameter, and each contained an eccentrically positioned nucleus. The nucleus was of irregular contour and possessed finely scattered and peripherally clumped chromatin. The secretory granules were uniformly electron-dense, measuring 200 μm maximally, and were randomly distributed throughout the cell. Mitochondria were generally elongate and the Golgi complex was not prominent. Free and attached ribosomes were present and the endoplasmic reticulum was vesiculated, resembling a filagreed pattern throughout the cell. Most of these cells were found in association with vascular spaces (Fig. 8). By contrast, 9 mutant tissues from this region possessed very few cells resembling those from normal and heterozygous tissue. Most of the cells in this region were greatly hypertophied and contained very irregular and indented nuclei, which were oriented to one side of the cell membrane. Electron dense cellular cytoplasm was located next to the nucleus and immediately adjacent to the periphery of the cell membrane, and contained a few lysosomes and mitochondria. Most of the

Table 1. -- Measurements of the Number of Nuclei per 10 x 7 cm Plot from the Ventromedial Zone of the Pars Distalis and Testis Weight as Percent Body Weight from 5 Normal (+/+), 5 Heterozygous (+/-) and 9 Mutant (-/-) Hamsters from the AN/AS-<u>Wh</u> Strain.

Animal Number	Generation (F)	Genotype	Age (days)	Nuclei per 10 x 7 cm Plot	Testis as % Body Weight
1821	4		135	79.0	2.22
1867	5		136	83.0	2.46
1874	5	whwhee	137	79.5	2.69
1889	6	(+/+)	141	77.5	2.62
1890	6		140	79.5	2.29
1825	3		136	86.5	2.38
1818	3		136	78.0	2.48
1797	3	Whwhee	188	75.5	2.09
1861	5	(-/+)	137	75.5	2.69
1883	4		137	75.0	2.53
1736	3		239	41.5	0.19
1811	3		135	59.5	1.66
1812	3		136	55.0	0.51
1816	3	WhWhee	136	52.0	1.88
1803	4	(-/-)	135	42.5	1.83
1829	4		137	68.5	0.43
1782	3		135	56.0	0.21
1857	5		135	31.0	0.51
1860	5		136	41.0	0.32

Table 2. -- Computations for the Analysis of Variance on the Number of Nuclei per 10 x 7 cm Plot from Table 1.

	+/+	+/-	-/-	
	79.0	86.5	41.5	
	83.0	78.0	59.5	
	79.5	75.5	55.0	
	77.5	75.5	52.0	
	79.5	75.0	42.5	
			68.5	
			56.0	
			31.0	
			41.0	
$(Y_{i.})$	398.50	391.00	447.0	80470.12 [A]
r_i	5	5	9	19.0
$(\bar{Y}_{i.})$	79.70	78.20	49.67	
S.E.	±2.02	±1.97	±4.76	
s_i^2	4.08	3.89	22.65	
Sum of Squared Observations Within a Group				
	31776.75	30591.75	23268.00	85636.50 [B]
Correction Factor for each Group				
	31760.45	30576.20	23086.78	85423.43 [C]
SS_Y	5166.38			
SS_T	4953.31			
SS_E	213.07			
MS_T	2476.66			
MS_E	13.32			

Table 3. -- Mean Measurements of Cellular Densities from Table 2*.

	GENOTYPE		
	whwhee	Whwhee	WhWhee
$\bar{y}_{i.}$	79.70	78.20	49.67
i^n	5	5	9
S.E.	±2.02	±1.97	±4.76

*All measurements were calculated from 10 x 7 cm plots taken from photographs at 680X magnification.

Table 4. — Analysis of Variance Comparing Data from Tables 1 thru 3.

Parameter examined	$MS_{Between}$	df	MS_{Within}	df	F
Cellular density	2476.66	2	13.32	16	185.94**

**Denotes significance at the one percent level where $F_{2,16} = 6.23$.

Table 5. — A Linear Regression Analysis Between Genotypes[o] and Within the Mutant Genotype[δ] where the Number of Nuclei per Plot was Regressed 5 Heterozygous (+/-) and 9 Mutant (-/-) Hamsters in the AN/As-<u>Wh</u> Strain. Number of Nuclei per Plot; Gram Percent Body Weight of the Testis.

+/+	+/-	-/-
79.0; 2.22	86.5; 2.38	41.5; 0.19
83.0; 2.46	78.0; 2.48	59.5; 1.66
79.5; 2.69	75.5; 2.09	55.0; 0.51
77.5; 2.62	75.5; 2.69	52.0; 1.88
79.5; 2.29	75.0; 2.53	42.5; 1.83
		68.5; 0.43
		56.0; 0.21
		31.0; 0.51
		41.0; 0.32

[o] Sy.x = 0.64; 4 = 0.77**.

**Indicates significance at the one percent level where r_{17} = 0.573.

[δ] Sy.x = 0.56; r = 0.09.

cells were occupied by huge lumens, containing a colloid-like substance. No secretory granules, Golgi or endoplasmic reticulum were present (Fig. 9).

At the cell boundaries, cellular membranes of adjacent cells in all normal and heterozygous tissue were parallel and separated by an intercellular space of approximately 200 Å in width. This uniform spacing of opposed membranes was interrupted occasionally by some intercellular canaliculi and small desmosomes (Fig. 10). Each adjacent cord of cells was separated from the next by an intercordal or vascular space. Most cell boundaries between adjacent cells in mutant tissue were identical in composition to those of the normal phenotype. However, all nine mutants possessed some boundaries which contained specialized junctions, including tight junctions (zonulae occludens), intermediate junctions (zonulae adherens), and desmosomes (maculae adherens) as described by Fawcett ('66). These specialized junctions were occasionally found between granulated cells in this region (Fig. 11).

Probably the most interesting observation from hypophyses was the presence of many highly ciliated secretory cells within the pars distalis of all homozygous mutant individuals. The ventromedial zone from normal and heterozygous glands in 3 out of 20 cases examined contained cells with a single cilium, basal body, and an associated centriole lying free in the cytoplasm proximal to the base of the cilium. These isolated cilium were located close to the cell membrane and projected into an intercellular space. In each of these comparatively rare cases, the single cilium was bound by an extension of the plasma membrane of the cell, which invaginated along the shaft to the level of the junction between the cilium and the basal body (Fig. 12). The tubules or fibrils in the center of the cilium had a 9 + 0 configuration which continued into the basal body (Fig. 12, inset).

Mutant tissue contained some cells with a single cilium which were identical to the ciliated cells of the 3 cases described above. However, all mutant tissue possessed numerous ciliated cells which contained numerous ciliary shafts and basal bodies cut in cross section and longitudinal section. Ciliated cells were found within cell cords and contained a highly indented, bizarre-looking nucleus. Along with cilia, these cells still possessed mitochondria, endoplasmic reticulum and secretory granules (Fig. 13).

Commensurate with the normal condition, cilia in mutant cells consisted of a cilary shaft and basal body, although no centrioles were observed. Each single cilium was bound by an extension of the plasma membrane of the cell and apparently projected into an intercellular space. Each basal body possessed many rootlets, giving it a "hairy" appearance (Fig. 14). The tubules or fibrils in the center of the cilium had a 9 + 2 configuration which continued into the basal body. The peripheral doublets consisted of three microtubules. The outer two, commonly referred to as subfibre A and subfibre B (Fawcett, '61), were joined by a third microtubule located towards the central core (Fig. 15).

D. Discussion

It is evident from this investigation that the gene Wh did not cause gross anatomical differences in hypophyses of the three genotypes. All glands were of similar size and shape and possessed a pars distalis, pars tuberalis, pars intermedia, infundibular process and infundibular stem. All pars intermedia and infundibular processes were in close apposition to one another and were separated from the pars distalis by the hypophyseal cleft.

Since the purpose of this investigation was to determine whether the gene Wh altered the hypophysis of homozygous hamsters in addition to causing infertility, light and electron microscopy of the ventromedial "sex zone" of the pars distalis (Purves and Griesbach, '55; Costoff, '73; Baker and Gross, '78) was undertaken.

Light microscopic examination of the "sex zone" of hypophyses from 10 normal and 10 heterozygous hamsters were consistent with previous observations on the cytology of the anterior pituitary as reviewed by Herlant ('64). Acidophils, basophils and chromophobes possessed a centrally or eccentrally positioned nucleus and the acidophils and basophils contained darkly stained secretory granules. Mutant tissue from this zone contained some cords or rosettes of cells which approached the normal phenotype. However, most of the cells in this region contained darkly stained nuclei, which were oriented to one side near the cell membrane, and one large cytoplasmic vacuole. These vacuolated cells were greatly enlarged and, at the light microscopic level, seemed to be devoid of cytoplasm, secretory granules and cellular organelles.

In addition to the enlargement of cells in this region, mutant tissue appeared to contain far less cells per plot than did normal and heterozygous tissue. Since the later genotypes were absolutely identical in composition, five random plots from these normals and heterozygotes were compared to plots from all of the mutant tissues. Mean measurements of cellular densities indicated that, when homozygous, the gene Wh caused a 40 percent reduction in pituitary cell number (Tables 1 and

2). When cell density between genotypes was regressed against the gram percent body weight of the testis, a significant correlation was observed between the severity of testicular involution caused by the gene and the reduction in cell density of the hypophysis (Table 3). Thus, hamsters who possessed pituitaries containing cells which were vacuolated also possessed atrophic testes.

Since the cellular structures of interest were beyond the resolution of the light microscope, electron microscopy has proven to be a powerful tool for the investigation of changes in pituitary ultrastructure correlated with changes in endocrine states and to study pituitary influences in certain pathologic conditions (Barnes, '62). The ultrastructure of gonadotropes and the changes they undergo following castration have been reported in the rat (Farquhar and Rinehart, '54; Yoshimura and Harumiya, '65; Costoff, '73), mouse (Yamada and Sano, '60; Barnes, '62), and hamster (Girod and Dubois, '65; Dekker, '67). The appearance of gonadotropes from the 10 normal and 10 heterozygous glands reported here were consistent with the previous studies of gonadotropes from intact hamster glands reported by Girod and Dubois ('65) and Dekker ('67).

Schleidt ('14) observed vacuolation of basophils after castration and designated these castration cells as "signet ring cells." Studies by Dekker ('67) revealed that ten days after castration, hamster gonadotropes began to enlarge. By one month after castration of the rat, the majority of cells were transformed into signet ring cells (Costoff, '73). Studies by Yoshimura and Harumiya ('65) suggested that the development of signet ring cells occurred through the dialation of fusion of the endoplasmic reticulum within the cell, resulting in the gradual formation of a large vacuole.

Electron microscopic examination has revealed considerable differences among cells which with light microscopy were known as signet ring cells (Farquhar and Rinehart, '54). Some cells with one large vacuole had large quantities of cytoplasm containing many mitochondria, granules and smaller Golgi vesicles. Cells of this description resembled more a signet ring. However, some cells consisted of one large vesicle containing uniformly light staining material which entirely replaced the cytoplasm of the cell so that the only other elements remaining were a few short rod-like mitochondria and a few granules concentrated in the Golgi region. These larger vesicles were surrounded by only a few delicate strands of cytoplasm and possessed an indented and darkly stained nucleus (Farquhar and Rinehart, '54).

The exaggerated signet ring cells described above by Farquhar and Rinehart ('54) were the long-term response to castration (35 to 75 days post castration) in the rat. All of the other studies, described above, also attribute exaggerated signet ring formation to long term effects of castration. Since all hamsters homozygous for the gene Wh in the AN/As-Wh strain possessed cells identical in appearance to these exaggerated signet ring cells, the mutant glands not only resembled glands from castrated hamsters, but resembled glands with long term effects of castration. Thus, anophthalmic hamsters must have possessed atrophic testes for quite some time, possibly since the onset of puberty.

Since vacuolation and enlargement of cells in the "sex zone" closely parallel the long term effects of castration, it is possible that abnormalities in this region of the hypophysis were only caused by an interruption in the pituitary-gonadal axis. However, Dekker ('67) and Yoshimura and Harumiya ('65) both reported that all basophilic cells enlarged and concurrently proliferated as the long term response to castration. These results were inconsistent with the present finding that the cells in the ventromedial zone were reduced by approximately 40 percent in anophthalmic individuals. Furthermore, if the infertility caused by Wh was analogous to castration, a strong correlation within the genotype (WhWhee) would be expected between the severity of testicular involution and the severity of vacuolation, enlargement and reduction in cell number in the hypophysis. This was not the case (Table 5). Therefore, it is possible that the morphologic abnormalities of pituitary cells represent a morphologic manifestation of the primary action of this gene in addition to a response to castration.

Since cell membranes and cell surfaces are highly specialized, depending on the cell's functional demands and relationships to neighboring cells, the appearance of small desmosomes, pinocytotic vesicles and cilia in normal and heterozygous tissue was not surprising. Among normal and heterozygous cells, the presence of small desmosomes, located at the boundary of adjacent cell membranes, must represent points of cellular adhesion, offering an area of anchorage for converging cytoplasmic filaments. The presence of many pinocytotic vesicles along these cellular membranes, functioning in either cellular endocytosis or exocytosis, suggested that fluid, possibly cerebro-spinal fluid, must flow between anterior pituitary cells and that the presence of small desmosomes did not interrupt this flow. The quantity of vesicles found along the membrane further suggested that endocytosis and exocytosis were regularly occurring events within anterior pituitary cells and it would seem that normal function of these cells would depend on an intact interaction between the vesicles and the cellular membrane.

Mutant tissue contained many cells with typically opposed membranes, small desmosomes and pinocytotic vesicles as described above. However, the presence of many occluding junctions, intermediate junctions and large desmosomes was unexpected, since these junctions isolate cells from any membrane interaction with their external environment. Specialized junctions also seemed to be associated with cells which were less granulated and possessed extensive areas of free ribosomes.

Throughout the course of general study of the fine structure of the adenohypophysis, ciliated cleft cells (Costoff, '73), ciliated follicle cells (Farquhar, '57; Rennels, '64; Yoshida, '66; Costoff, '73) and ciliated secretory cells (Barnes, '61; Millhouse, '67; Wheatly, '67; Dubois and Girod, '70; Dingemans, '70) have been observed. Barnes ('61) reported that ciliated secretory cells were occasionally found in normal glands but seemed to be more frequent in castrated and lactating animals. These rare ciliated secretory cells, like those few from the normal and heterozygous hamsters reported here, possessed a cilium with a basal body and proximal centriole and possessed a 9 + 0 fibril configuration.

In order to understand the effect on pituitary ultrastructure caused by the gene Wh, the development of the pituitary, beginning with the embyronic epithelium of Rathke's pouch, should be undertaken. It is known that embyronic epithelium, along with typical differentiated epithelium, possess two prevalent features: (1) tight, intermediate and gap junctions and (2) many cilia or microvilli (Fawcett, '65). Barnes ('61) suggested that the presence of cilia in the adult pituitary was not surprising, as long as this glandular tissue retained its embyronic capacity to form cilia. Also, Campbell and Campbell ('71) pointed out that despite the general permance of cell attachments, there are specific and important developmental and pathologic circumstances which lead to their disappearance, especially when epithelial cells differentiate into nonepithelial tissues. Thus, junctional complexes, found in all mutant tissue, were either retained from the embyronic condition or were a result of de-differentiation in the adult condition. Similarly, the abnormal cilia may either represent an initial abnormal differentiation of embyronic ciliated epithelium which is retained in the adult mutant or may represent an abnormal de-differentiation from the adult condition. This suggests that the pituitary may be one site or primary action of the gene Wh which caused abnormal cellular differentiation, exemplified by the formation of abnormal membrane structures. Similarly, eyelessness, caused by the failure of closure of the chroid fissure (Asher, '68), may also be caused by an abnormal membrane differentiation. Cells which possessed junctional complexes in embyronic epithelium may not allow proper cell-cell interactions and the closure of this fissure might thus be obstructed. Furthermore, vacuolation and enlargement in adult hypophyses could be the result of junctional complexes which isolate cells from their external environment. Thus, it is possible that the gene Wh causes a retention of cell junctions and cilia from the embyronic state. This lack of differentiation in the sex zone may have caused, secondarily, a disruption in the pituitary-gonadal axis which resulted in malfunction of the testis. Further anatomical, embyrological and biochemical examinations of this mutant will provide useful information as to the effects of the gene Wh on pituitary morphology and will ultimately reveal the primary action of this gene in the Syrian hamster.

ABBREVIATIONS

B,	Blood capillary in longitudinal section
B_1,	Blood capillary in cross section
BB,	Basal body
C,	Centriole
CM,	Cell membrane
CS,	Colloid-like substance
D,	Desmosome
ER,	Endoplasmic reticulum
GN,	Nucleus of a gonadotrope
IC,	Intercellular canaliculi
IP,	Infundibular stem
ISP,	Intercellular space
L,	Lysosome
LTH,	Nucleus of a lactropic cell
M,	Mitochondria
N,	Nucleus
PD,	Pars distalis
PI,	Pars intermedia
PM,	Plasma membrane
PT,	Pars tuberalis
PV,	Pinocytotic vesicle
R_1,	Rootlets in logitudinal section
R_2,	Rootlets in cross section
S,	Ciliary shaft
SG,	Secretory granules
V,	Cytoplasmic vacuole
VS,	Vascular space
ZA,	Zonulae adherens
ZO,	Zonulae occludens

PLATE 1

EXPLANATION OF FIGURES

1. A schematic representation of the hypophysis of male hamsters from the AN/As-*Wh* strain. Each gland consisted of a pars distalis (PD), pars intermedia (PI), pars tuberalis (PT), infundibular process (IP) and infundibular stem (IS).

2. Hypophysis from a homozygous normal hamster (*whwhee*). x 10.

4. Hypophysis from a heterozygous hamster (*Whwhee*). x 10.

5. Hypophysis from a homozygous mutant hamster (*WhWhee*). x 10.

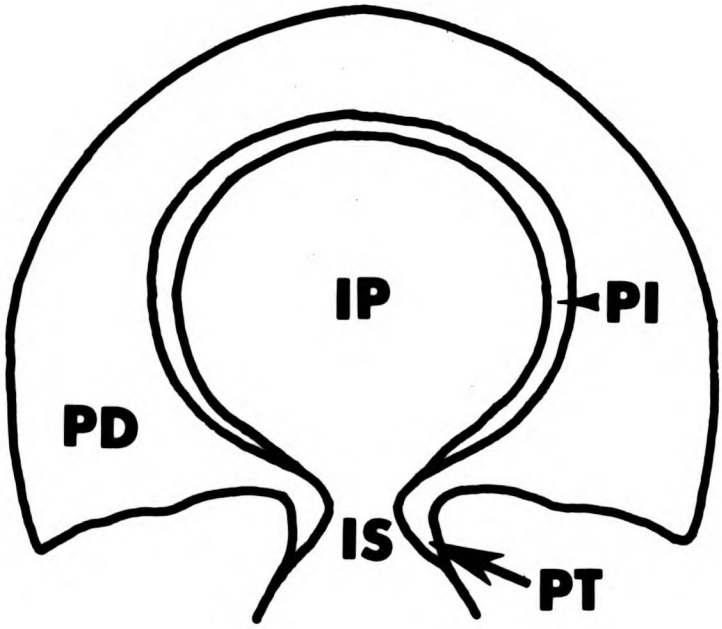

2

3

4

5

PLATE 2

EXPLANATION OF FIGURES

Figures 6 and 7 are light micrographs of 1 μm thick Epon-embedded sections stained with Toluidine Blue.

6. Ventromedial section of the pars distalis representative of normal and heterozygous tissue. Note the closely packed arrangement of cells in cords or rosette patterns. Each cell contained a large nucleus (N) and most cells contained secretory granules (SG). x 1,127. (Light, Toluidine Blue).

7. Ventromedial section of the pars distalis representative of mutant tissue. Note that many of these cells were greatly enlarged and possessed a darkly stained nucleus (N) and one large cytoplasmic vacuole (V). x 1,127. (Light, Toluidine Blue).

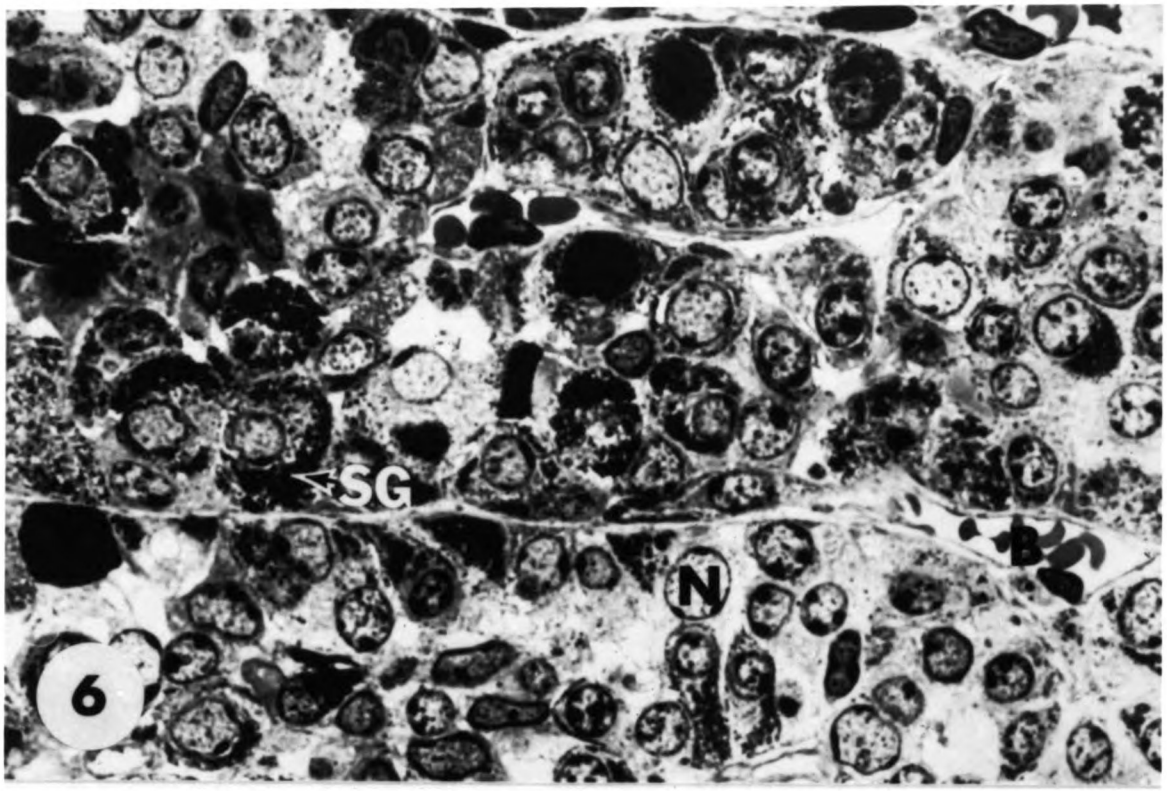
SG
B
N
6

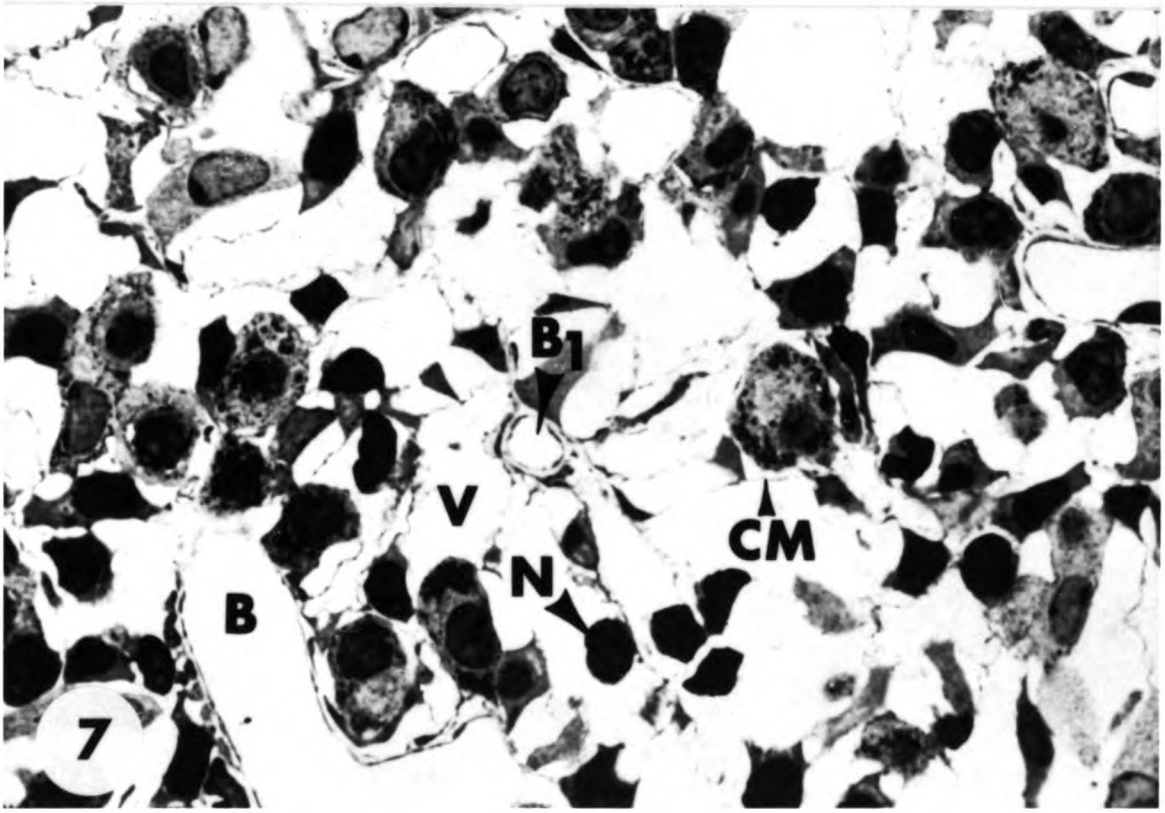
B1
V
CM
N
B
7

PLATE 3

EXPLANATION OF FIGURES

8. Electron micrograph of gonadotropes from the ventromedial zone of normal/heterozygous tissue. Note the large nucleus of irregular contour (GN), containing finely scattered and peripherally clumped chromatin. Secretory granules (SG) were of uniform density and randomly distributed throughout. Mitochondria (M) were generally elongate and the endoplasmic reticulum (ER) was vesiculated. Most gonadotropes were found in association with vascular spaces (VS). x 5,600.

9. Electron micrograph of the most prevalent cell type found in the ventromedial zone of mutant tissue. Note the very irregular and indented nucleus (N) oriented to one side of the cell membrane (CM). Cell cytoplasm was oriented next to the nucleus and immediately adjacent to the periphery of the cell membrane and contained a few lysosomes (L) and mitochondria (M). Most of the cell was occupied by a huge lumen, containing a colloid-like substance (CS). x 5,600.

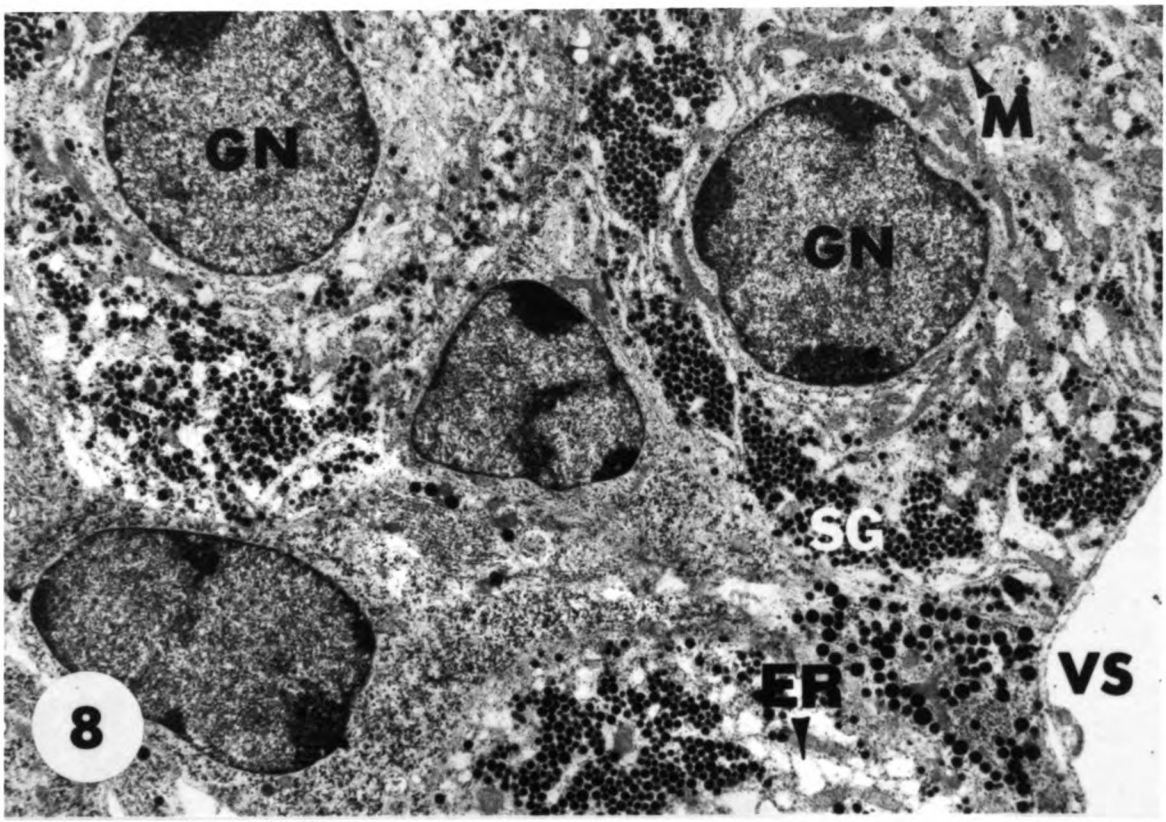
GN
GN
M
SG
ER
VS
8

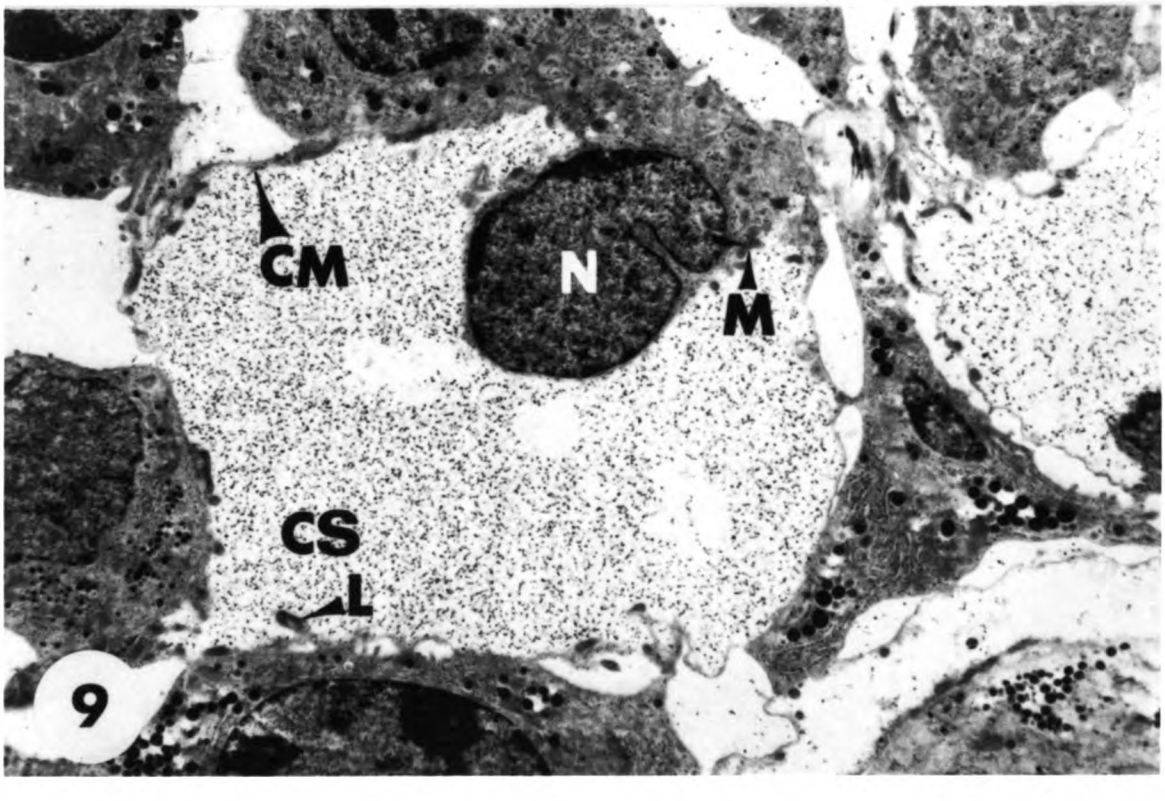
CM
N
M
CS
L
9

PLATE 4

EXPLANATION OF FIGURES

10. Electron micrograph of cellular membranes (CM) of adjacent cells representative of normal and heterozygous tissue. Note that the cell boundaries were parallel and separated by an intercellular space of approximately 200A in width. The uniform spacing of opposed membranes was interrupted by some intercellular canalicule (IC), small desmosomes (D) and pinocytotic vesicles (PV). x 56,000.

11. Electron micrograph of cellular membranes (CM) of mutant tissue containing specialized junctions. Note the presence of zonulae occludens (ZO), zonulae adherens (ZA), and desmosomes (D). x 56,000.

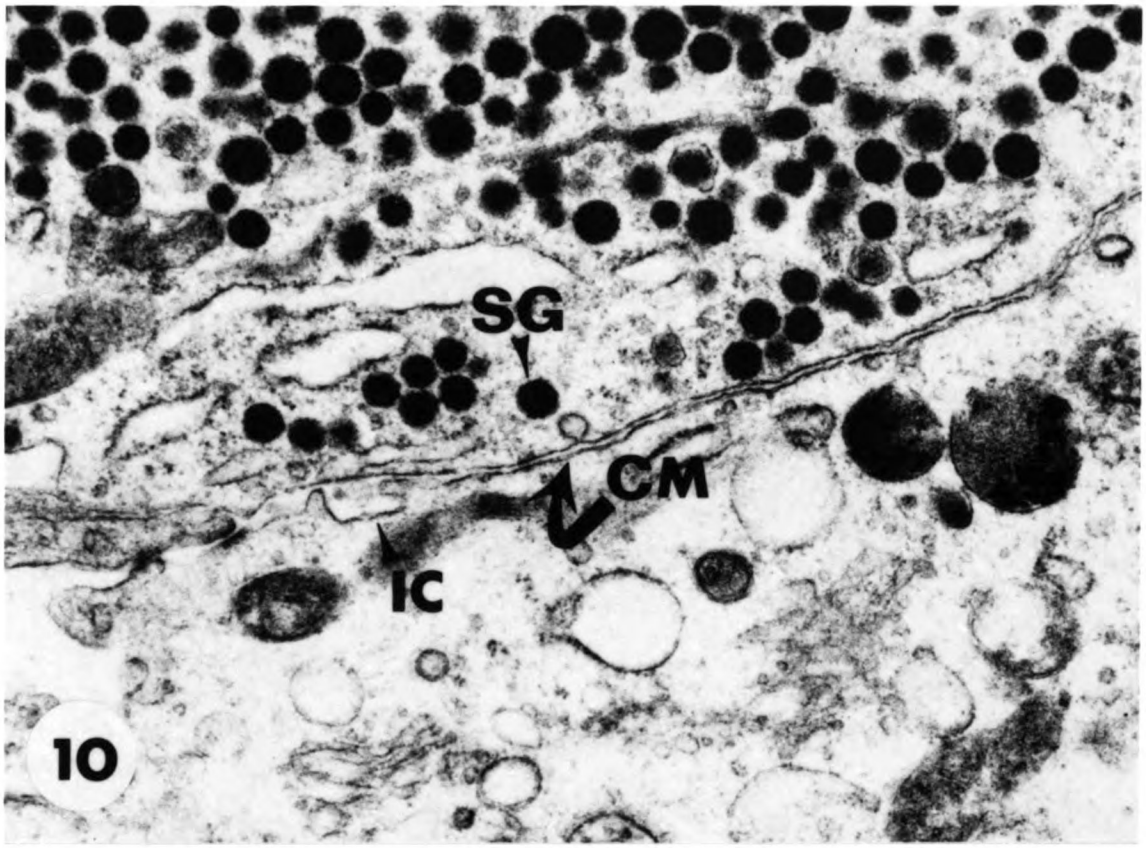
SG
CM
IC
10

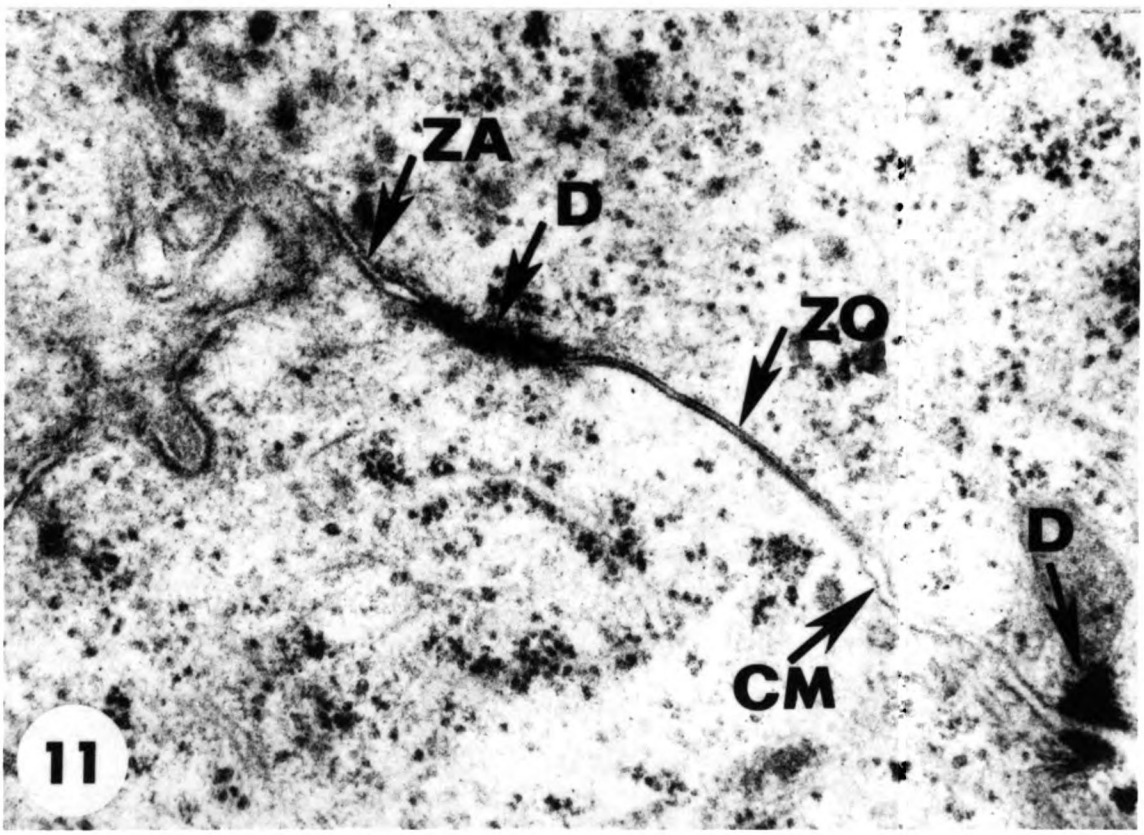
ZA
D
ZO
D
CM
11

PLATE 5

EXPLANATION OF FIGURES

12. Electron micrograph of an isolated cilium, occasionally found in the ventromedial zone of the pars distalis in normal and heterozygous tissue. These cilium consisted of a shaft (S), basal body (BB), and associated centriole (C), and were bound by an extension of the plasma membrane (PM) of the cell, which invaginated to the junction between the shaft and the basal body (arrow)x 32,000.

    Inset: The tubules or fibrils in the center of the cilium had a 9 + 0 configuration which continued into the basal body (BB). x 96,000.

13. Electron micrograph of a portion of a cell cord in mutant tissue, containing one cell which is representative of a lactotropic cell (LTH) and one highly ciliated cell (arrow). Note the bizarre appearance of the nucleus (N) and cilium, cut in cross section and longitudinal section (Box). Highly ciliated cells contained secretory granules (SG), mitochondria (M), and endoplasmic reticulum (ER). x 9,750.

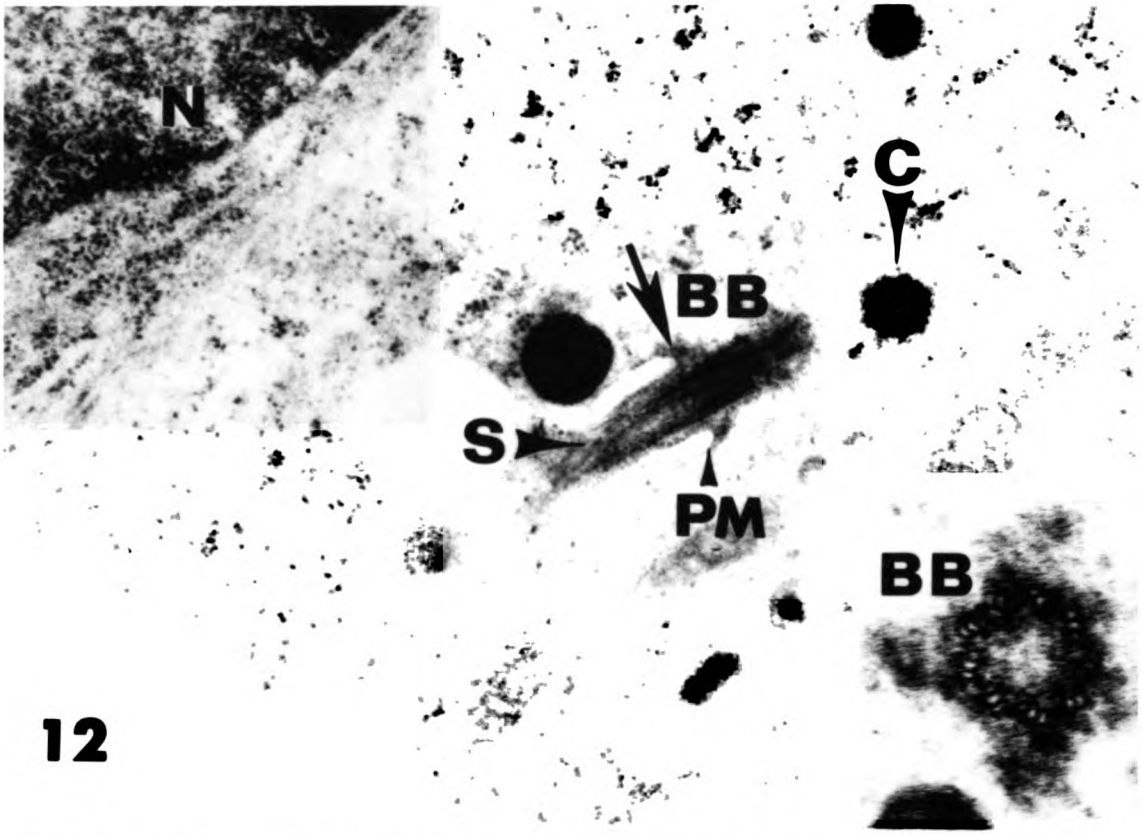

12

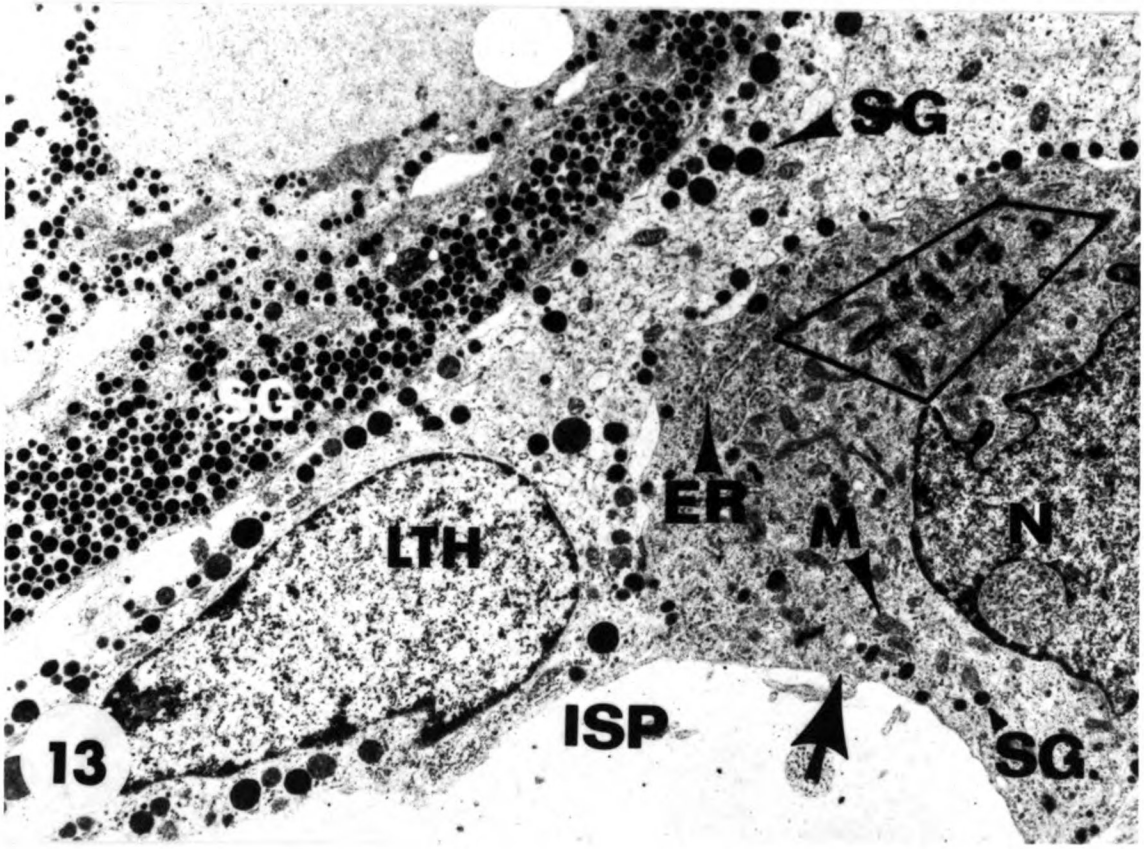

13

PLATE 6

EXPLANATION OF FIGURES

14. Electron micrograph of a field comparable to that in the box in Fig. 13. Cilia in these secretory cells consisted of a ciliary shaft (S), which possessed a 9 + 2 microtubular arrangement (Box), and a basal body (BB). Each basal body contained many rootlets, cut in longitudinal section (R_1) and cross section (R_2), giving them a "hairy" appearance. Each single cilium was bound by an extension of the plasma membrane of the cell (PM), which invaginated along the shaft to the junction between the cilium and the basal body (arrow). x 32,000.

15. Electron micrograph of the box in Fig. 14. The tubules or fibrils in the center of the cilium had a 9 + 2 configuration. Note that the peripheral doublets were modified into triplets with an extra tubule located towards the central core (arrow). x 104,000.

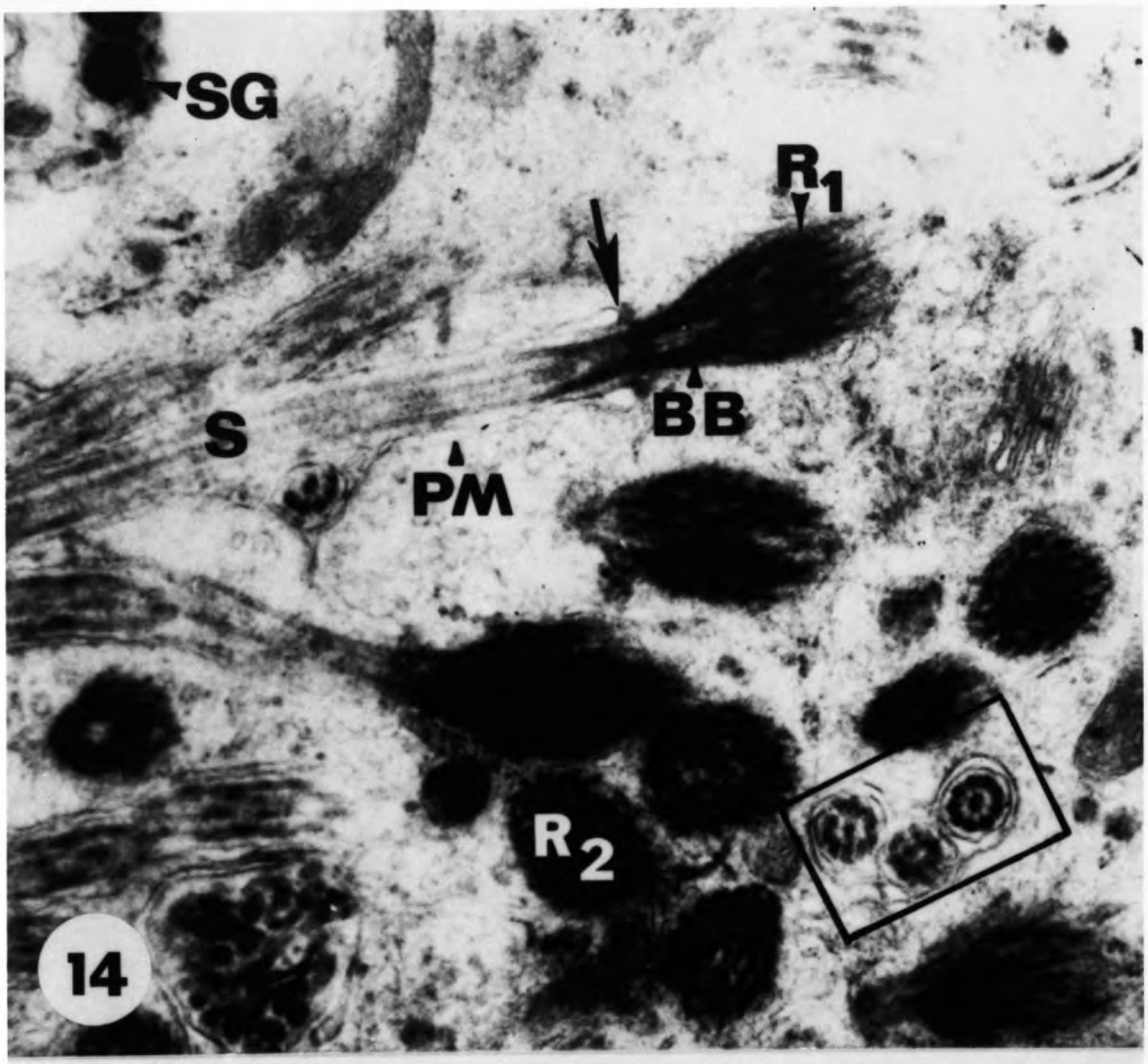
SG
R1
S
PM
BB
R2
14


15

SUMMARY

A. Problem

The gene Wh causing anophthalmia in the Syrian hamster, *Mesocricetus auratus*, is a highly pleitropic gene which has profound effects upon eye development, pigmentation and reproduction. Since male hamsters homozygous for this gene are usually sterile, the objective of this study was to determine: (1) whether testicular abnormalities existed and contributed to the infertility of male hamsters, and (2) to determine whether abnormalities existed in hypophyses of male hamsters. Ultimately, it was hoped that the primary action of the gene Wh might be identified.

B. Methods

In order to determine whether anatomical differences existed in the testes and hypophyses of 10 normal, 10 heterozygous and 10 mutant matched-siblings at approximately 135 days of age, the following parameters were measured: (1) adult body weight, (2) testis weight, (3) tubular diameter and (4) pituitary cells densities. Gross anatomical observations were made upon adult hypophyses.

Histological examinations were made at the light and electron microscopic level of both testicular tissue, including seminiferous epithelium and interstitial tissue, and the rostral ventromedial zone of the pars distalis of the hypophysis.

C. Results

Testes from most homozygous mutant hamsters were hypoplastic and aspermic. Abnormalities were observed in Leydig cells, Sertoli cells and in the developing germ cells. Seminiferous tubules were reduced in size and contained germinal cells arrested in the early spermatid stage of spermiogenesis, possibly due to premature failure of the Golgi apparatus to feed vesicles into the acrosomal vesicle and a subsequent dysgenesis of the acrosome.

Hypophyses from mutant hamsters were of similar size and shape to those of the normal phenotype. Rostral ventromedial sections from the "sex zone" of the gland contained a 40 percent reduction in cell density. Abnormalities in cellular membranes were observed including the unexpected appearance of specialized junctional complexes and atypical cilia.

D. Conclusions

Since the primary action of the gene is unknown, it was postulated that the gene either acts directly to alter pituitary function, via abnormal cellular differentiation, or that the abnormalities were due to a failure of eye development and subsequent lack of the visual pathway.

At this point it is clear that further embryological, anatomical and biochemical examinations of this mutant will provide useful information as to the effects of Wh on the morphological characters described in this study. Careful histological examinations of the early embryonic events leading to eye development and pituitary development are in order, along with a careful investigation as to the effects of blinding on pituitary and testicular morphology in normal animals. If the gene does, in fact, act to alter membrane interactions by means of abnormal cellular differentiation, this mutant will provide one model for the study of cellular differentiation in a mammalian system.

LITERATURE CITED

LITERATURE CITED

Asher, J. H., Jr. 1968. A partial biochemical and morphological description of the action of the gene *Wh* causing anophthalmia in the Syrian hamster, *Mesocricetus auvatus*. M.A. Dissertation. California State College at Long Beach. 350 pp.

Baker, B. L., and D. S. Gross. 1978. Cytology and distribution of secretory cell types in the mouse hypophysis as demonstrated with immunocytochemistry. Am. J. Anat., 153:193-216.

Barnes, B. G. 1961. Ciliated secretory cells in the pars distalis of the mouse hypophysis. J. Ultrastructure Research, 5:453-467.

__________. 1962. Electron microscope studies on secretory cytology of the mouse anterior pituitary. Endocrinology, 71:618-628.

Beher, M., and W. Beher. 1959. A partial dominant for suppression of color in the Syrian hamster, *Cricetus Mesocricetus auratus*. Amer. Nat., 93:201-203.

Bennett, W. I., A. M. Gall, J. L. Southard and R. L. Sidman. 1971. Abnormal spermiogenesis in quaking, a myelis-deficient mutant mouse. Biol. Reprod., 5:30-58.

Berman, M. B. 1964. Genetic basis of microphthalmia and anophthalmia in the Syrian hamster. Masters Thesis. Medical College of Virginia, Richmond, Virginia.

Blackburn, W. R., K. W. Chung, L. Bullock and C. W. Bardin. 1973. Testicular feminization in the mouse; studies of Leydig cell structure and function. Biol. Reprod., 9:9-23.

Blom, E. 1966. A new sterilizing and heredity defect (the "Dag-defect") located in the bull sperm tail. Nature, 209:739-740.

__________. 1968. A new sperm defect - "pseudo-droplets" - in the middle piece of the bull sperm. Nord. Veterinar. Med., 20:279-283.

Bloom, W., and D. Fawcett. 1975. Male reproductive system. In: A Textbook of Histology. W. B. Saunders Co., Philadelphia, pp. 805-857.

Bouin, P., and P. Ancel. 1903. Recherches sur les cellules interstitielles du testicule des mammifères. Arch. Lool. Exptl. Gen., 1:437-523.

Campbell, R. D., and J. H. Campbell. 1971. Origin and continuity of desmosomes. In: Origin and Continuity of Cell Organelles. J. Reinert and H. Ursprung, eds. Springer-Verlag, Berlin, pp. 261-298.

Catt, K. J., T. Tsuruhara and M. L. Dufau. 1972. Gonadotropin binding sites of the rat testis. Biochem. Biophys. Acta, 279:194-201.

Christensen, A. K. 1965. The fine structure of testicular interstitial cells in guinea pigs. J. Cell Bio., 26:911-935.

Christensen, A. K., and D. W. Fawcett. 1966. The fine structure of testicular interstitial cells in mice. Am. J. Anat., 118:551-572.

Clermont, Y. 1972. Kinetics of spermatogenesis in mammals: Seminiferous epithelium cycle and spermatogonial renewal. Physiol. Rev., 52:198-236.

Costoff, A. 1973. Ultrastructure of gonadotropes. In: Ultrastructure of Rat Adenohypophysis - Correlation with Function. Academic Press, N.Y., pp. 26-63.

Cutuly, E., and E. C. Cutuly. 1940. Observations on spermatogenosis in the rat. Endocrinology, 26:503-507.

Dekker, A. 1967. Pituitary basophils of the Syrian hamster: An electron microscopic investigation. Anat. Rec., 158:351-368.

deKretsler, D. M. 1969. Ultrastructural features of human spermiogenesis. Z. Zellforsch., 98:477-505.

deKretsler, D. M., H. G. Burger, D. Fortune, B. Hudson, A. R. Long, C. A. Paulsen and H. P. Taft. 1972. Hormonal, histological and chromosomal studies in adult males with testicular disorders. J. Clin. Endocrinol. Metabl., 35:392-401.

deKretsler, D. M., K. J. Catt and C. A. Paulsen. 1971. Studies on the _in vitro_ testicular binding of iodinated luteinizing hormone in rats. Endocrinology, 99:332-337.

deKretsler, D. M., K. J. Catt, H. Burger and G. C. Smith. 1969. Radioautographic studies on the localization of ^{125}I-labelled human luteinizing and growth hormone in immature male rats. J. Endocrinol., 43:105-111.

Dingemans, K. P. 1969. The relation between cilia and mitoses in the mouse adenohypophysis. J. Cell Biol., 43:361-367.

Dubois, P., and C. Girod. 1970. Ciliated cells of the adenohypophysis - an electron microscopic study. Z. Zell. Mikr., 103:502-507.

Dym, M. 1973. The fine structure of the monkey (Macaca) Sertoli cell and its role in maintaining the blood-testis barrier. Anat. Rec., 175:639-656.

Falconer, D. S. 1960. Introduction to Quantitative Genetics. Oliver and Boyd, London, p. 91.

Farquhar, M. G. 1957. Corticotrophs of the rat adenohypophysis as revealed by electron microscopy. Anat. Rec., 127:291 (Abstract).

Farquhar, M., and J. F. Rinehart. 1954. Electron microscopic studies of the anterior pituitary gland of castrate rats. Endocrinology, 54:516-541.

Fawcett, D. 1961. Cilia and flagella. In: The Cell II. J. Brachet and A. E. Mirsky, eds. Academic Press, New York, pp. 217-297.

__________. 1966. Specializations of the surface for cell-to-cell attachments. In: An Atlas of Fine Structure of the Cell. W. B. Saunders Co., Philadelphia, pp. 365-382.

Fevold, H. L. 1943. The luteinizing hormone of the anterior lobe of the pituitary gland. Ann. N.Y. Acad. Sci., 43:321-339.

Fevold, H. L., F. L. Hisaw and S. L. Leonard. 1931. The gonad stimulating and the luteinizing hormones of the anterior lobe of the hypophysis. Am. J. Physiol., 97:291-301.

Gill, J. 1978a. Design and analysis of experiments in the animal and medical sciences. Iowa State University Press, Ames, Iowa, pp. 136-159.

__________. 1978b. Design and analysis of experiments in the animal and medical sciences. Iowa State University Press, Ames, Iowa, pp. 179-180.

__________. 1978c. Design and analysis of experiments in the animal and medical sciences. Iowa State University Press, Ames, Iowa, pp. 86-113.

Girod, C., and P. Dubois. 1965. Elude ultrastructurale des cellules gonadotropes antéhypophysiares, chez le Hamster doré (Mesocricetus auratus Waterh.). J. Ultrastructure Research, 13:212-232.

Glauert, A. M. 1975a. Fixation, dehydration and embedding of biological specimens. In: Practical Methods in Electron Microscopy. Elsevier North-Holland, New York, pp. 43.

Glauert, A. M. 1975b. Fixation, dehydration and embedding of biological specimens. In: Practical Methods in Electron Microscopy. Elsevier North Holland, New York, pp. 27.

Greep, R. O., and H. L. Fevold. 1937. The spermatogenic and secretory function of the gonads of hypophysectomized adult rats treated with pituitary FSH and LH. Endocrinology, 21:611-628.

Greep, R. O., H. G. VanDyke and B. F. Chow. 1941. Some biological properties of metaketrin and thylakentrin. Amer. J. Physiol., 133: p. 303 (abstract).

Greep, R. O., H. L. Fevold, and F. L. Hisaw. 1936. Effects of two hypophyseal gonadotropic hormones on the reproductive system of the male rat. Anat. Rec., 65:261-272.

Hanke, H., and H. Charipper. 1948. The anatomy and cytology of the pituitary gland of the golden hamster (Cricetus auratus). National Reco-d, 102:123-137.

Herlant, M. 1956. Corrélations hypophysogenitales chez la femelle de la Chayve-Soures, Myotis myotis (Borkhausen). Arch. Biol., 67:

__________. 1959. L'hypophyse de la Taupe au cours de la phase d'activite sexuelle. Académie des Sciences, Paris-Compt. Rend., 248:1033-1036.

__________. 1964. The cells of the adenohypophysis and their functional significance. Int. Rev. Cytol., 17:299-382.

Herlant, M., and R. Canivenc. 1960. Les modifications hypophysaires chez la femelle du Blaireau (Meles meles L.) au cours du cycle annuel. Académie des Sciences, Paris-Compt. Rend., 250:606-608.

Hoffman, R. A., and R. J. Reiter. 1965. Pineal gland: Influence on gonads of male hamsters. Science, 148:1609-1611.

Hoffman, R. A., and R. J. Reiter. 1966. Responses of some endocrine organs of female hamsters to pinealectomy and light. Life Sci., 5:1147-1151.

Holstein, A. F., C. Schirren and C. G. Schirren. 1973. Human spermatids and spermatozoa lacking acrosomes. J. Reprod. Fert., 35:489-491.

Hughes, R. D., and W. J. Geeraetes. 1962. Extreme microphthalmia in the Syrian hamster. Genetics, 47:962 (abstr.).

Hunt, D. M., and D. R. Johnson. 1971. Abnormal spermiogenesis in two pick-eyed sterile mutants in the mouse. J. Embryol. expl. Morphol., 26:111-121.

Johnson, D. R., and D. M. Hunt. 1971. Hop-sterile, a mutant gene affecting sperm tail development in the mouse. J. Embryol. exp. Morphol., 25:223-226.

Knapp, B. H., and S. Polivanov. 1958. Anophthalmic albino: A new mutation in the Syrian hamster, Cricetus (Mesocricetus) auratus. Amer. Nat., 92:317-318.

Leydig, F. 1850. Fur anatomie der männlichen geschlechtsorgane und analdrüsen der saugethiere. Z. Wiss. Zool., 2:1-57.

Lostroh, A. J. 1969. Regulation by FSH and ISCH (LH) of reproductive function in the immature male rat. Entocrinology, 85:438-445.

__________. 1976. Hormonal control of spermatogenesis. In: Regulatory Mechanisms of Male Reproductive Physiology. C. H. Spilman, T. J. Lobl and K. T. Kirton, eds. Excerpta Medica, Amsterdam, pp. 13-27.

Lynch, K. M., and W. W. Scott. 1951. Lipid distribution in the Sertoli cell and Leydig cell of the rat testis as related to experimental alterations in the pituitary-gonad system. Endocrinology, 49:8-14.

Lyon, M. F., and S. G. Hawkes. 1970. X-linked gene for testicular feminization in the mouse. Nature, 227:1217-1219.

Means, A. R. 1976. Mechanisms of gonadotrophic hormone action in the testis. In: Regulatory Mechanisms of Male Reproductive Physiology. C. H. Spilman, T. J. Lobl and K. T. Kirton, eds. Excerpta Medica, Amsterdam, pp. 87-96.

__________. 1977. Mechanisms of action of follicle-stimulating hormone (FSH). In: The Testis. A. D. Johnson and W. R. Gomes, eds. Academic Press, New York, pp. 163-188.

Millhouse, E. W. 1967. Additional evidence of ciliated cells in the adenohypophysis. J. Microscopie, 6:671-676.

Mollenhauer, H. H. 1964. Plastic embedding mixtures for use in electron microscopy. Stain Technol., 39:111-114.

Olds, P. J. 1971. Effect of the T locus on sperm ultrastructure in the house mouse. J. Anat., 109:31-37.

Pederson, H., and H. Rebbe. 1974. Fine structure of round headed human spermatozoa. J. Reprod. Fert. 37:51-54.

Peyre, A., and M. Herlant. 1961. Les modifications cytologiques de l'ante-hypophyse du Desmar (Galemys pyrenaicus G.). Académic des Sciences, Paris-Compt. Rend., 252:463-465.

Purves, H. D., and W. E. Griesbach. 1955. The site of follicle stimulating and luteinizing hormone production in the rat pituitary. Endocrinology, 55:785-793.

Quay, W. B. 1974. Effects of early postnatal pinealectomy on adult brain and divisional pituitary weights in relation to type of illumination. Endocrine Res. Commun., 1:359-371.

Reiter, R. J. 1967. The effect of pineal grafts, pinealectomy, and Denervation of the pineal gland on the reproductive organs of male hamsters. Neuroendocrinology, 2:138-146.

__________. 1968a. Morphological studies on the reproductive organs of blinded male hamsters and the effects of pinealectomy or superior cervical ganglionectomy. Anat. Rec., 160:13-24.

__________. 1968b. Changes in the reproductive organs of cold-exposed and light-deprived female hamsters (Mesocricetus auratus). J. Reprod. Fertil., 16:217-222.

Reiter, R. J., and R. J. Hester. 1966. Interrelationships of the pineal gland, the superior cervical ganglid and the photoperiod in the regulation of the endocrine system of hamsters. Endocrinology, 79:1168-1170.

Reiter, R. J., R. A. Hoffman, and R. J. Hester. 1966. The effects of thiourea, photoperiod and the pineal gland on the tyroid, adrenal and reproductive organs of female hamsters. J. Exp. Zool., 162:263-298.

Rennels, E. G. 1964. Electron microscopic alterations in the rat hypophysis after scalding. Am. J. Anat., 114:71-92.

Reynolds, E. S. 1963. The use of lead citrate at high pH as an electron-opaque stain in electron microscopy. J. Cell Biol., 17:208-212.

Rhodin, J. A. G. 1974. Hypophysis. In: Histology: a text and atlas. Oxford University Press, New York, pp. 428-439.

Robinson, R. 1962. Anophthalmic white: a mutant with unusual morphological and pigmentary properties in the Syrian hamster. Amer. Nat., 96:183-185.

__________. 1964. Genetic studies of the Syrian hamster VI. Anophthalmic white. Genetica, 35:241-250.

__________. 1968. Genetics and Kanpology. In: The Golden Hamster: its biology and use in medical research. R. A. Hoffman, P. F. Robinson, and H. Magalhaes, eds. Iowa State University Press, Ames, Iowa, pp. 41-72.

Rowley, M. J., J. D. Berlin and C. G. Heller. 1971. The ultrastructure of four types of human spermatogonia. Z. Zellforsch., 112:139-157.

Schultze, C. 1974. On the morphology of the human Sertoli cell. Cell. Tiss. Res., 153:339-355.

Sertoli, E. 1865. Dell'esistenzia di particolari cellule ramificate nei canalicoli seminiferi del testicolo humano. Il Morgagni, 7:31-39.

Setchell, B. P. 1978a. Endocrinology of the testis. In: The Mammalian Testis. Cornell University Press, New York, pp. 109-180.

__________. 1978b. Endocrinologycal control of the testis. In: The Mammalian Testis. Cornell University Press, New York, pp. 332-358.

__________. 1978c. Spermatogenesis. In: The Mammalian Testis. Cornell University Press, New York, pp. 181-232.

__________. 1978d. Naturally occurring and induced dysfunctions of the testis. In: The Mammalian Testis. Cornell University Press, New York, pp. 359-432.

Smith, P. E. 1927. The disabilities caused by hypophysectomy and their repair. J. Am. Med. Assn., 88:158-161.

__________. 1930. Hypophysectomy and replacement therapy in the rat. Am. J. Anat., 45:205-274.

Stanley, A. J., and L. G. Gumbreck. 1964. Male pseudohermaphroditism with feminizing testis in the male rat - a sex - linked recessive character. Prog. Endocr. Soc., 40.

Stanley, A. J., L. G. Gumbreck, J. E. Allison and R. B. Easley. 1973. Part I. Male pseudohermaphroditism in laboratory Norway rat. Rec. Progr. Horm. Res., 29:43-64.

Steinberger, E. 1971. Hormonal control of mammalian spermatogenesis. Physiol. Rev., 51:1-22.

Steinberger, A., and E. Steinberger. 1977. The sertoli cells. In: The Testis. A. D. Johnson and W. R. Gomes, eds. Academic Press, New York, pp. 371-399.

Steinberger, E., and A. Steinberger. 1975. Spermatogenic function of the testis. Handbk. Physiol. Section 7, V:1-19.

Steinberger, E., and G. E. Duckett. 1965. Effect of estrogen or testosterone on initiation and maintenance of spermatogenesis in the rat. Endocrinology, 76:1184-1189.

Watson, M. L. 1958. Staining of tissue sections for electron microscopy. J. Biophys. Biochem. Cytol., 4:475-479, 727-734.

Wheatley, D. N. 1967. Cells with two cilia in rat adenohypophysis. J. Anat., 101:379-485.

Yamada, K., and N. Sano. 1960. Electron microscopic observations of the anterior pituitary of the mouse. Okajümas Folia Anat. Jap., 34:449-475.

Yoon, C. H. 1973. Recent advances in Syrian hamster genetics. J. Heredity, 64:305-307.

__________. 1975. Total retinal degeneration in apparent anophthalmos of the Syrian hamster. Inv. Ophth., 14:321-325.

Yoshida, Y. 1966. Electron microscopy of the anterior pituitary gland under normal and different experimental conditions. Meth. Achievum. Expt. Path., 1:439-454.

Yoshimura, F., and K. Harumiya. 1965. Electron microscopy of the anterior lobe of pituitary in normal and castrated rats. Endocrinol. Japon., 12:119-152.

MICHIGAN STATE UNIV. LIBRARIES
31293100642796