

THE LIFE CYCLE OF ISOSPORA FELIS IN THE KITTEN

By

Dorothy Jean Hitchcock

A THESIS

Submitted to the School of Graduate Studies of Michigan  
State College of Agriculture and Applied Science  
in partial fulfillment of the requirements  
for the degree of

DOCTOR OF PHILOSOPHY

Department of Bacteriology and Public Health

Year 1954


ProQuest Number: 10008333

All rights reserved

INFORMATION TO ALL USERS

The quality of this reproduction is dependent upon the quality of the copy submitted.

In the unlikely event that the author did not send a complete manuscript and there are missing pages, these will be noted. Also, if material had to be removed, a note will indicate the deletion.



ProQuest 10008333

Published by ProQuest LLC (2016). Copyright of the Dissertation is held by the Author.

All rights reserved.

This work is protected against unauthorized copying under Title 17, United States Code  
Microform Edition © ProQuest LLC.

ProQuest LLC.  
789 East Eisenhower Parkway  
P.O. Box 1346  
Ann Arbor, MI 48106 - 1346

## ACKNOWLEDGMENT

The author wishes to take this opportunity to express her appreciation to Dr. William D. Lindquist of the Department of Bacteriology and Public Health under whose guidance this study was completed after the death of Dr. Philip A. Hawkins.

Sincere thanks are extended to Miss Harriet Hall, technician, for preparing the tissue sections, to Dr. George R. Burch, Pitman-Moore Company for supplying the feline distemper vaccine, and Miss Esther Smith and Mr. Jack Tadman, who prepared the photomicrographs with the assistance of the writer.

Acknowledgment is also due Michigan State College for providing the author with the opportunity to make this study.

# TABLE OF CONTENTS

	Page
I. INTRODUCTION . . . . .	1
A. Occurrence . . . . .	1
B. Economic Importance . . . . .	1
C. Classification . . . . .	1
D. Life Cycle . . . . .	2
E. Purpose of This Study . . . . .	3
II. LITERATURE REVIEW . . . . .	5
III. MATERIALS AND METHODS . . . . .	9
A. Care and Management of the Kittens . . . . .	9
B. Artificial Infection . . . . .	10
C. Autopsy . . . . .	12
IV. RESULTS . . . . .	14
A. Examination of Normal, Coccidia-free Kittens. . . . .	14
B. Examination of Kittens Sacrificed . . . . .	16
1. Two days following infection . . . . .	16
2. Three days following infection . . . . .	19
3. Four days following infection . . . . .	22
4. Five days following infection . . . . .	25
5. Six days following infection . . . . .	29
6. Seven days following infection . . . . .	35
7. Eight days following infection . . . . .	41
C. Symptomatology and Pathology . . . . .	48
V. DISCUSSION OF RESULTS . . . . .	49
A. Artificial Infections . . . . .	49
B. Kittens Sacrificed . . . . .	50
1. Two days after infection . . . . .	50
2. Three days after infection . . . . .	54
3. Four days after infection . . . . .	57
4. Five days after infection . . . . .	58
5. Six days after infection . . . . .	62
6. Seven days after infection . . . . .	67
7. Eight days after infection . . . . .	69
C. Location of the Parasites . . . . .	81
D. Symptomatology and Pathology . . . . .	82
VI. SUMMARY . . . . .	85
BIBLIOGRAPHY . . . . .	87

## I. INTRODUCTION

### A. Occurrence

The coccidia are widely distributed in wild and domesticated birds and mammals. Of the common domesticated animals only horses are free from this protozoan.

### B. Economic Importance

Although negligible as a human parasite, coccidia cause yearly economic losses in poultry, rabbits, sheep and cattle. It apparently is not a frequent cause of death in kittens. In the temperate zone it probably causes the greatest economic loss among domesticated animals of any of the protozoa (Becker, 1934).

### C. Classification

The term, "coccidia", is applied to those organisms in the phylum Protozoa that are members of the family Eimeriidae which belong to the order Coccidia within the class Sporozoa. The coccidia of domesticated birds, mammals and man belong almost entirely to the two important genera: Isospora and Eimeria. The two genera are readily differentiated

on the basis of their mature oocysts, the former containing two spores each of which contains four sporozoites and the latter with four spores each having two sporozoites per spore. In the dog Eimeria canis has been reported and in cats E. felina. The genus Isospora, more commonly found in cats and dogs, is represented in these hosts by the species --- I. bigemina, I. rivolta and I. felis.

#### D. Life Cycle

The coccidia, in general, possess life cycles which are similar. The oocysts are passed unsegmented in the feces and undergo development or sporulation on the ground. After ingestion of the sporulated oocysts in the food or drink of the animal, the eight sporozoites are liberated from the spores within the mature oocysts by the action of the digestive juices. The sporozoites penetrate the epithelial cells and grow forming trophozoites. The nucleus divides forming a stage called a schizont. Each nucleus has a portion of cytoplasm and the individual units are then called merozoites. With the liberation of the merozoites from the epithelial cells of the host, the first asexual or schizogonous cycle is completed. These merozoites may, on entering new epithelial cells, repeat the asexual cycle or can start the sexual or sporogonous cycle. In the sexual cycle the merozoites grow, mature without nuclear division, and are now

called macrogametocytes. By maturation the macrogamete, female element, is formed. Those merozoites destined to become microgametocytes, grow and nuclear division follows. The hundreds of nuclei each have a portion of cytoplasm and are the microgametes or male element. One microgamete enters the macrogamete in the process of fertilization. A wall develops about the fertilized stage and it is now called an oocyst. The undeveloped oocysts are passed out in the feces of the host animal. This life cycle which occurs in a single host, includes a period of asexual reproduction known as schizogony, followed by sexual reproduction, sporogony, ending in the formation of spores and sporozoites.

#### E. Purpose of This Study

The purpose of this investigation was to study microscopically and describe the morphological stages in the life cycle of I. felis using kittens artificially infected with this single species of coccidium. The number of schizogonous and sporogonous cycles, length of the prepatent period and organs parasitized were also objectives of this study.

A survey of the literature showed that most of the early observations on the morphological stages were on mixed, natural infections of feline coccidia. The first morphological stage observed was the oocyst. This was logical

since it is easily seen by microscope in the feces because of its size. The earliest workers described as one, the now recognized three separate species of the genus Isospora found in the kitten.



## II. LITERATURE REVIEW

The first observations of coccidia in the cat were made by Finck (1854). He noted the sporocysts or "corpuscules gémínés" of a then unidentified species in the substance of the villi of the cat and not in the epithelium of the cat's intestine. These sporocysts measured 7 x 8 u to 9 x 10 u, and were sometimes in pairs within the oocyst wall.

Rivolta (1874) gave an account of finding oviform cells "(cellule oviformi)" of coccidia in the intestinal villi of both cats and dogs, but he described only those stages in the dog. In 1878 he named these bodies in the cat and dog, "Cytospermium villorum intestinalium canis", and realized that he had seen two different stages, the sporocysts and oocysts.

In 1879 Leuckart wrote of seeing coccidial stages in the intestinal epithelium of the cat and dog where complete development took place. He was the only one up to that time to refer to the complete development of the oocysts in the epithelium of the cat. Grassi (1882) stated that this took place in the deeper tissues of the villi. Leuckart (loc. cit.) might have observed oocysts developing inside of a cat which had been dead for some time or he might have been working with a mixed coccidial infection showing large and small oocysts.

"Coccidium Rivolta" was the name given by Grassi in 1882 to a coccidium he described from the intestine of a cat. From a description of the oocysts, it was clear that he was not observing the same coccidium that Finck and Rivolta described.

A report was published by Pachinger (1887) of finding the sporocysts of Isospora of the cat in the esophagus, stomach, and whole length of the intestine of the domestic cat.

Railliet and Lucet (1891) accepted the name of Coccidium bigeminum given by Stiles in 1891, and described three varieties of this parasite as occurring in the dog, cat and pole cat, which they regarded as varieties of C. bigeminum owing to the differences in the size of the oocysts. The varieties were called canis, cati and putori.

Wasielewski (1904) first described Isospora felis under the name of Diplospora bigemina in a detailed account of the formation and sporulation of the oocyst and the morphology of the schizonts and free merozoites in the cat. He noted that this parasite was found in the epithelium of the small intestine and in the submucosa. Reichenow (1921) expressed the opinion that Wasielewski was probably dealing with a mixed infection of coccidia in the cats he examined.

Under the name of Isospora bigemina, Swellengrebel (1913-1914) gave a description of the development of Isospora

felis. For the first time he described the schizogonous cycle in the epithelial cells of the small intestine, and the formation of the microgametocytes, macrogametocytes and oocysts.

Many of the early workers observed the differences in the sizes of the oocysts and noted they fell into three groups. For the coccidium producing the smallest oocysts, Isospora bigemina (Stiles, 1891) was suggested. Grassi (1882) was dealing with oocysts intermediate in size and named this parasite, I. rivolta. Wenyon (1923) proposed the name of I. felis for the coccidium producing the oocysts largest in size.

Wenyon (1923) described and presented pictures of the developmental stages of the asexual cycle from scrapings of the epithelial cells of the villi of the small intestine and caecum from a natural infection of I. felis. He discussed and presented drawings of the maturation of the microgametocytes and macrogametocytes.

Artificial infections of I. felis were studied by Andrews (1926) in 4 week old kittens given 100,000 sporulated oocysts of I. felis. He described the symptomatology but had no discussion of the morphological stages found.

The present study follows Andrew's work in that artificial infections of I. felis were produced in young kittens. The symptomatology was noted, but more emphasis was placed

on the morphological stages found in the life cycle, organs parasitized, and the location of coccidial stages in the different intestinal tissues.

### III. MATERIALS AND METHODS

#### A. Care and Management of the Kittens

The kittens used in this study were obtained from private sources in the area of Lansing, and East Lansing, Michigan. They ranged in age from 28-60 days (average 43.3 days) at the time they were received. At this age they were weaned and less likely to be naturally infected with coccidia. Kittens which are infected or have recovered from Isospora spp. infections are completely immune to reinfection (Andrews, 1926).

On arrival each kitten was given 2 ml of feline distemper vaccine\* and isolated from the colony for 7 days. As soon as feces were available, a total of twelve fecal examinations were done on each kitten by the centrifugal concentration procedure using saturated sugar solution. Since the pre-patent period was established for I. felis in the kitten as 5-6 days (Andrews, 1926), twelve pre-infection fecals were chosen to be examined and they covered a period twice as long as he had indicated. Only those kittens which did not show oocysts in the feces were used in this study. Andrews made no mention of pre-infection examinations and hence did not rule out the possibility of his animals having a natural

---

\* Pitman-Moore Company, Indianapolis, Indiana.

infection. A natural incidence of Isospora spp. of 89 percent was found in some Michigan kittens (Hitchcock, 1953). Of the 304 kittens examined, the 19 used in this study were found free of coccidia and were given the second 2 ml of vaccine 7-10 days following the first vaccination. One hundred and forty-four kittens of the 304 were given a second dosage of vaccine, and were used in an earlier work (Hitchcock, 1953) as they were found to be naturally infected with coccidia. Eleven of the twice-vaccinated kittens died but only two were proven to have distemper. This prophylactic program seems essential to maintain a colony of kittens for research purposes.

All cages were washed and disinfected daily. Every precaution was taken in the care and management of the kittens to prevent the introduction of coccidiosis.

The food, consisting of canned cat food\*, dried dog meal\*\* and whole, pasteurized, homogenized milk, was fed twice daily in clean sterile Petri dishes.

## B. Artificial Infection

The oocysts of Isospora felis used for infecting the kittens were obtained by the sedimentation method from kittens with single natural infections.

---

\* "Kalico" and "Three Little Kittens"  
\*\* Zinn's "Peerless"

Fecal samples collected from these carriers were repeatedly concentrated by the sugar flotation method and examined microscopically for the presence of mixed oocysts. Feces containing only oocysts of I. felis were concentrated and sporulated to be used for the infective material.

During the microscopical examination of the tissue sections no parasitological stages of coccidia other than I. felis were found, which helps to substantiate the evidence that the oocyst suspensions used for infecting contained only I. felis.

These oocysts were sporulated in 2.5 percent potassium dichromate solution. A constant supply of air was bubbled through the oocyst-dichromate mixture for 72 hours at 20-22° C.

Each kitten was infected with 100,000 sporulated oocysts given orally in 1 ml of water. The number of oocysts per ml was determined by taking the average of the number of oocysts counted in four different 0.01 ml samples. The dosage of oocysts of I. felis was established at 100,000 per kitten as this amount had proven fatal in kittens four weeks old (Andrews, 1926). A survey of the literature revealed only this data, thus it was chosen as the dosage which would probably not kill animals approximately nine weeks old. When inoculated the kittens ranged in age from 49-80 days, (average 65.3 days) and the weights ranged from 581 - 1,152 grams, (average 866 grams). Until it was sacrificed, fecal examinations of each animal were done daily when the samples were available.

### C. Autopsy

The infected kittens were killed on the second, third, fourth, fifth, sixth, seventh or eighth days after inoculation. Representative tissues were removed from the junction of the small intestine and the stomach, at the first two inches of the small intestine and every three inches of the remainder of this organ, there being a total of eleven different samples. The caecum was cut into four pieces. Similar portions were removed from every inch and one-half of the large intestine.

Two kittens, which did not show oocysts in the feces after twelve fecal examinations, were sacrificed and the above mentioned tissues removed for staining. These pieces were used to study the normal histology of the intestinal tract.

The portions of the intestine for the microscopical examination were fixed in Zenker's solution, mounted in paraffin, sectioned at a thickness of 7 microns and stained with the routine eosin hematoxylin staining technique.

Scrapings were obtained from four different areas of the fresh mucosal lining of the small intestine, placed in physiological saline, and examined microscopically while warm for oocysts and other protozoa. Any gross lesions were noted.



The entire stained cross-sections were systematically examined using the oil immersion objective. Two or three kittens were used for each time interval and 22 pieces of the small intestine, two of the caecum, and two of the large intestine of each animal were examined. All different morphological stages of I. felis for each kitten sacrificed at the mentioned time intervals were drawn as they appeared in the tissues.

#### IV. RESULTS

##### A. Examination of Normal, Coccidia-free Kittens

Two kittens, not showing oocysts in the feces after fecal examinations done over a period of at least twelve days, were sacrificed and the stained cross-sections of the tissues were used to study the normal histology of the coccidia-free animal before the infected hosts were examined.

The cat has the shortest digestive tract of any of the common animals, only six feet in length (Chauveau, 1872). Vever (1948) found that the ratio of body length to intestinal length of the cat to be one to four. Villi of a greater height than those occurring in any other domesticated animal were found in the cat, having an average height of 963 u. They were very close together, quite slender, and somewhat constricted at their bases. Some of the villi showed branching and were more numerous than in the other mammals. The most numerous and characteristic cells, the columnar epithelial, covering the villi were more compressed in the cat than in any other domesticated animal and reached a height of only 16 u (Titkemeyer, 1951). Some of the nuclei of the epithelial cells seemed to migrate toward the lumen surface. Goblet cells were throughout the gut, but they were more numerous in the caecum and large intestine.

The muscularis mucosae was in two layers, an inner circular and an outer longitudinal, and had a thickness of 15 u. The tunica muscularis consisting of three layers had a thickness of 555 u (Titkemeyer, 1951).

The main difference in the tissues of the infected and non-infected animals was the presence of intracellular stages of I. felis. The epithelial cells, which were parasitized, were at times greatly enlarged, distorted and the nucleus crowded to the side. At times these normal tissues were referred to during the observations of the infected portions of the gut.

## B. Examination of Kittens Sacrificed

1. Two days following infection. Two kittens were sacrificed two days after infecting with 100,000 sporulated oocysts of I. felis. The morphological stages of the coccidium found will be called first generation schizonts. These oval or round stages vary in size from 4-7 u in width to 10-16 u in length depending on the stage of development. In the immature schizonts (Figures 1 and 2) the chromatin material appeared to occur in large irregular clumps, and they became smaller in size and retained their irregular shape as the schizont matured (Figures 3 and 4). The chromatin particles, about 1-2 u in size in the mature schizont, were not associated with definable cytoplasm. The number of chromatin masses, called first generation merozoites, varied between 40 and 60 in number and were difficult to count accurately. No first generation merozoites were recognized free in the lumen of the gut, although mature first generation schizonts were observed opening into the lumen of the small intestine.

Both immature and mature first generation schizonts parasitized only epithelial cells of the small intestine. No coccidial stages were found in the large intestine and the caecum. In one kitten first generation schizonts were found in all sampled intervals, except the first two and one-half inches of the small intestine. In the other kitten no

coccidial stages were found until the middle portions of the small intestine were examined.

At this early time in the life cycle, the immature first generation schizonts seemed to be more prevalent than the mature first generation schizonts.

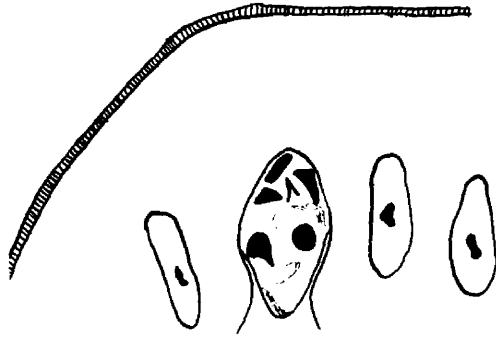
Figures 1 through 79 were drawn to represent the parasite in its relative position to the host's epithelial cells. Scale: 1.5 u equivalent to 3 mm.

### Plate I

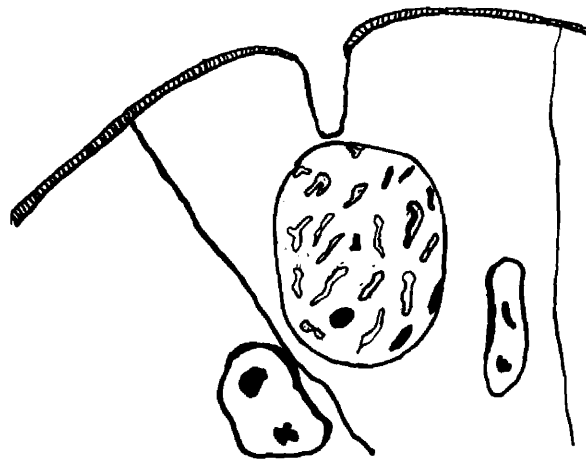
Kittens killed two days after infection.

- Fig. 1. An immature first generation schizont, 4.0 x 8.0 u, in the lower two-thirds of the small intestine.
- Fig. 2. An immature first generation schizont, 7.0 x 10.0 u, in the upper one-third of the small intestine.
- Fig. 3. A mature first generation schizont, 10.5 x 12.0 u, in the middle third of the small intestine.
- Fig. 4. A mature first generation schizont, 7.5 x 16.5 u, in the middle third of the small intestine.

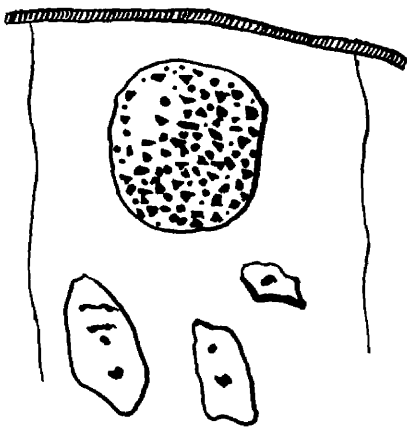
## PLATE I



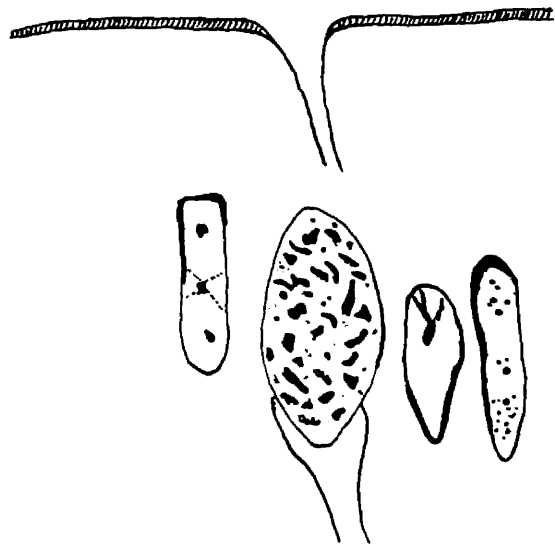
1.



2.



3.



4.

2. Three days following infection. Immature and mature first generation schizonts were found throughout the small intestine and caecum of the two kittens sacrificed three days after infecting with I. felis oocysts. These stages appeared similar to those previously described. In the immature first generation schizont (Figure 5) some of the chromatin masses seemed to be in vacuoles. Others as in the immature first generation schizont (Figure 6) appeared without the vacuole. The mature first generation schizonts (Figures 7 and 8) had first generation merozoites as described in the animals killed at two days.

One of the kittens showed, in the small intestine, 25 inches from the stomach, stages of the second asexual or schizogonous cycle represented by an immature second generation schizont (Figure 9). The nuclei had divided, but not the cytoplasm. The nuclei seemed to be in vacuoles and no karyosomes were observed. Three mature second generation schizonts (Figure 10) were found in the small intestine next to the stomach. Each of the fourteen enclosed second generation merozoites measured 3-5 u. The nuclei appeared in vacuoles and surrounded by a small portion of cytoplasm.

The majority of the stages found at this time were immature and mature first generation schizonts. A very few second generation schizonts were found.

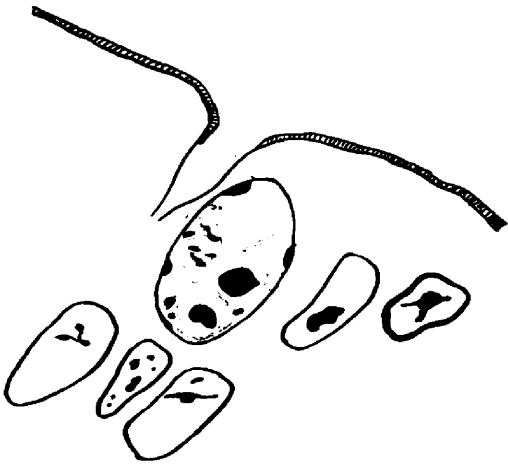


## Plate II

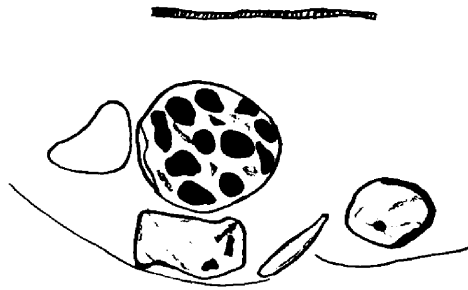
Kittens sacrificed three days after infection.

- Fig. 5. An immature first generation schizont,  
7.5 x 9.0 u, in the middle one-third of the  
small intestine.
- Fig. 6. An immature first generation schizont,  
9.0 x 9.0 u, in the upper one-third of the  
small intestine.
- Fig. 7. A mature first generation schizont,  
6.0 x 13.5 u, in the middle one-third of  
the small intestine.
- Fig. 8. A mature first generation schizont,  
8.0 x 13.5 u, in the small intestine next  
to the stomach.

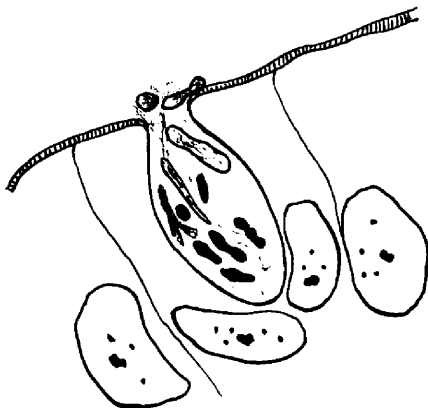
## PLATE II



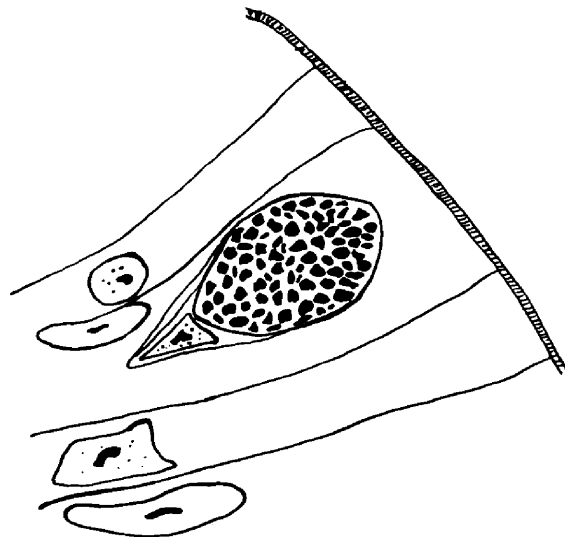
5.



6.



7.



8.

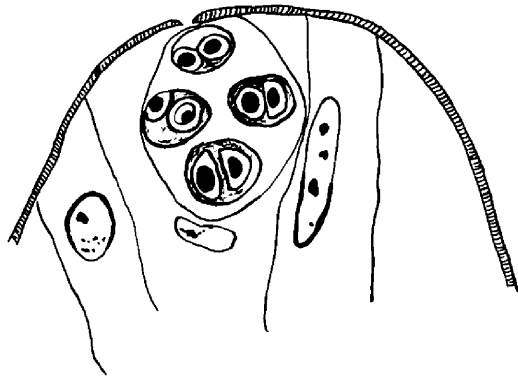
Plate III

Kitten sacrificed three days after infection.

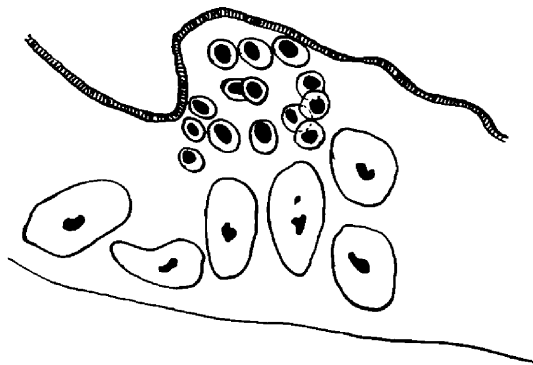
Fig. 9. An immature second generation schizont,  
12.0 x 15.0 u, containing four pair of  
merozoites, 7.0 x 9.0 u, in the caecum.

Fig. 10. A mature second generation schizont,  
containing 14 merozoites, 3-5 u, in the  
small intestine next to the stomach.

## PLATE III



9.



10.

3. Four days following infection. In these hosts, morphological stages of the first schizogonous cycle were found to be similar to those previously described. Immature first generation schizonts (Figure 11) and mature first generation schizonts (Figures 12 and 13) were found.

In only one of the three kittens examined were second generation asexual stages found. Figure 14 is a second generation trophozoite with a single nucleus, 2 u in diameter, and set in a vacuole. The nucleus of the host cell was crowded to one side. The second generation trophozoite divided, forming two crescent shaped merozoites, each with its own separate nucleus and cytoplasm (Figure 15).

The first generation schizonts were found throughout the caecum and the small intestine, whereas the second generation trophozoites and schizonts were found in the small intestine starting ten inches from the stomach.

The majority of the coccidial stages found on the fourth day were first generation asexual stages. Only a few second generation asexual stages were found in one of the kittens examined.

## Plate IV

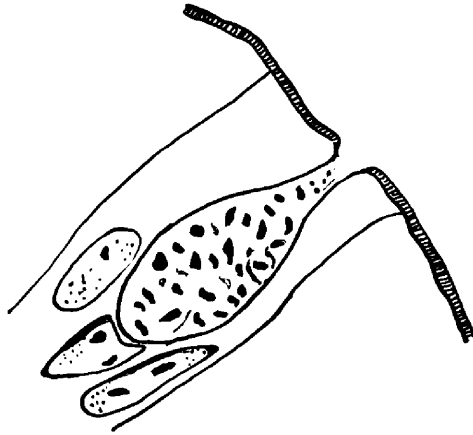
Kittens sacrificed four days after infection.

- Fig. 11. An immature first generation schizont,  
7.5 x 7.5 u, in the first portion of the  
small intestine.
- Fig. 12. A mature first generation schizont,  
7.5 x 15.0 u, in the middle one-third of  
the small intestine.
- Fig. 13. A mature first generation schizont,  
9.0 x 24.5 u, in the distal portion of  
the small intestine.
- Fig. 14. A second generation trophozoite, 6.0 x 10.5 u,  
in the middle one-third of the small in-  
testine.

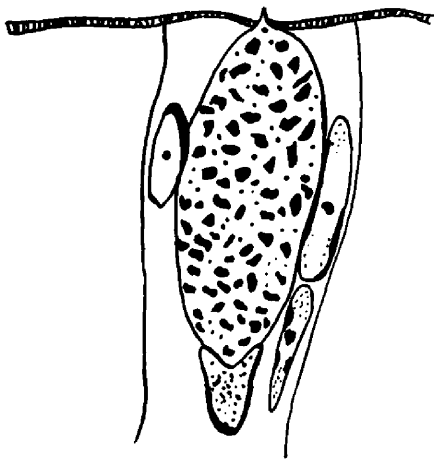
PLATE IV



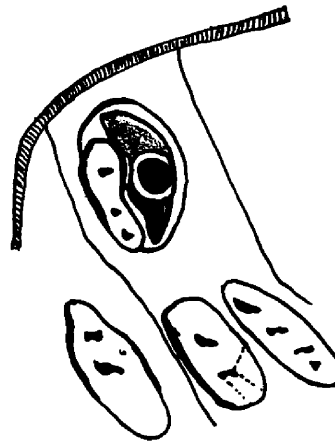
11.



12.



13.



14.

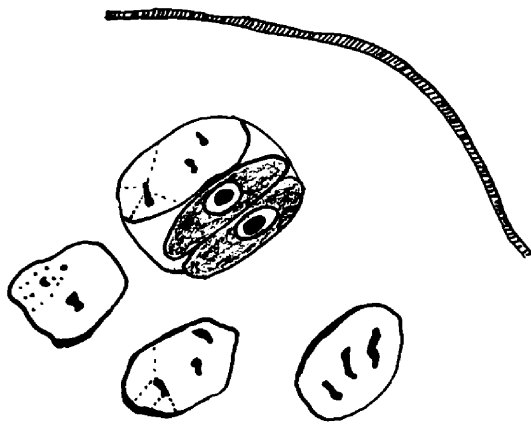
Plate V

Kitten sacrificed four days after infection.

Fig. 15. A second generation schizont, 4.5 x 10.5 u,  
in the middle one-third of the small  
intestine.



## PLATE V



15.

4. Five days following infection. Immature and mature first generation schizonts (Figures 16 through 18) were found in both kittens throughout the small intestine, but not in the caecum or large intestine. These stages appeared similar to those schizonts previously described.

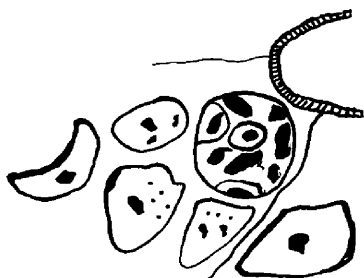
Second generation asexual stages were represented by forms in various degrees of schizogony. The second generation trophozoite (Figure 19) divided forming the immature second generation schizont (Figure 20) containing two adherent, crescent shaped merozoites. Figures 21 through 23 are also second generation schizonts in which the merozoites appeared as cones, the head portion being the nucleus surrounded by a vacuole and the pointed tail portion the blue cytoplasm. Further division took place with the formation of an immature schizont with four merozoites (Figure 24) and then 12-14 merozoites (Figures 25 and 26). Only those merozoites were represented in the drawings which were seen in one plane. No second generation schizonts with more than 16 merozoites were found. Free second generation merozoites were found in the lumen of the small intestine (Figure 27). The second generation asexual stages were found only in the small intestine and predominated over the first generation asexual stages. No sexual stages were observed.

Plate VI

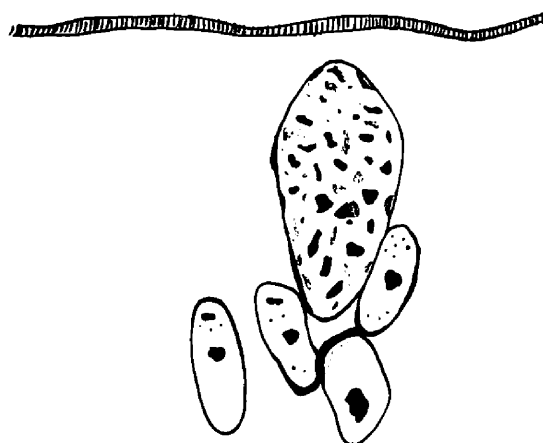
Kittens sacrificed five days after infection.

- Fig. 16. An immature first generation schizont,  
7.5 x 7.5 u, in the middle one-third of  
the small intestine.
- Fig. 17. A mature first generation schizont,  
9.0 x 18.0 u, in the upper part of the  
small intestine.
- Fig. 18. A mature first generation schizont,  
8.0 x 14.5 u, in the upper one-third of  
the small intestine.
- Fig. 19. A second generation trophozoite,  
7.5 x 10.5 u, in the middle one-third of  
the small intestine.

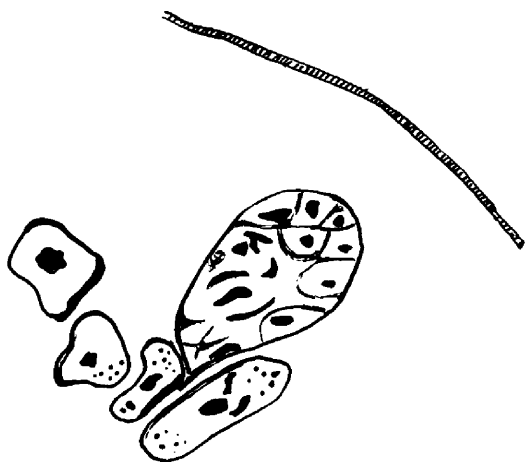
## PLATE VI



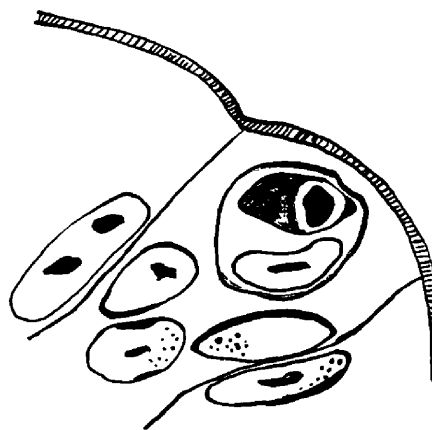
16.



17.



18.




19.

## Plate VII

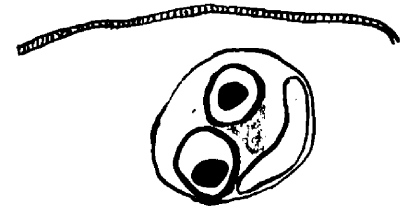
Kitten sacrificed five days after infection.

- Fig. 20. An immature second generation schizont,  
4.5 x 7.5 u, containing two merozoites in  
the middle one-third of the small intestine.
- Fig. 21. An immature second generation schizont,  
10.5 x 10.5 u, containing two merozoites  
in the middle portion of the small intestine.
- Fig. 22. An immature second generation schizont,  
7.5 x 12.0 u, containing two merozoites in  
the upper portion of the small intestine.
- Fig. 23. An immature second generation schizont,  
10.5 x 15.0 u, with four merozoites (only  
those in one plane were drawn) in the  
upper portion of the small intestine.

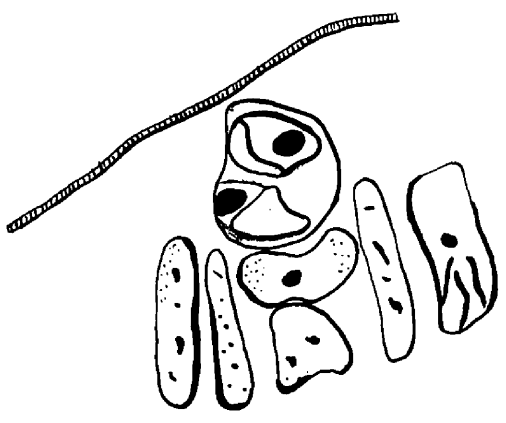
# PLATE VII



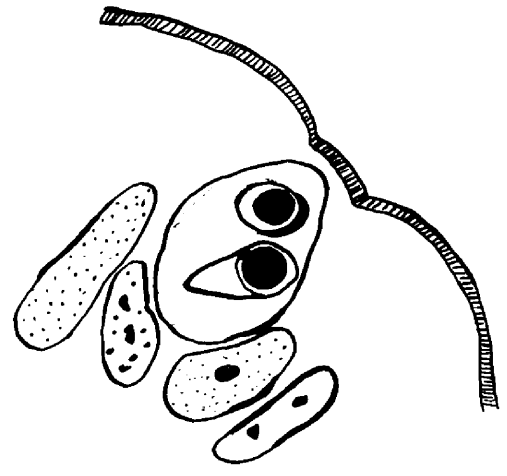
20.



21.



22.



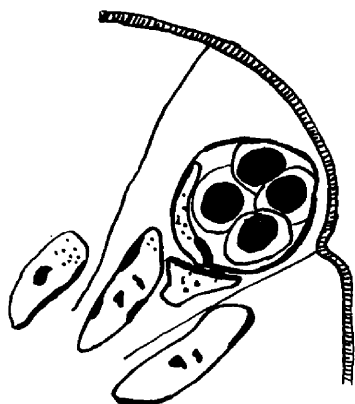
23.

## Plate VIII

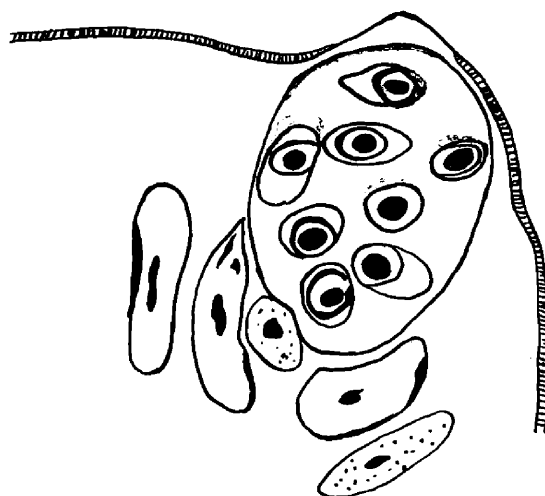
Kittens sacrificed five days after infection.

- Fig. 24. An immature second generation schizont, 9.0 x 10.5 u, with four merozoites in the middle one-third of the small intestine.
- Fig. 25. A second generation schizont, 15.0 x 22.5 u, containing 14 merozoites in the middle one-third of the small intestine.
- Fig. 26. A second generation schizont, 15.0 x 17.0 u, containing 12 merozoites in the middle one-third of the small intestine.
- Fig. 27. A free second generation merozoite, 4.5 x 7.5 u, in the lumen of the small intestine.

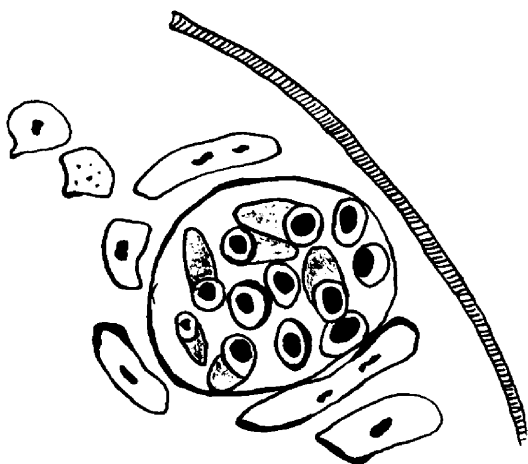
## PLATE VIII



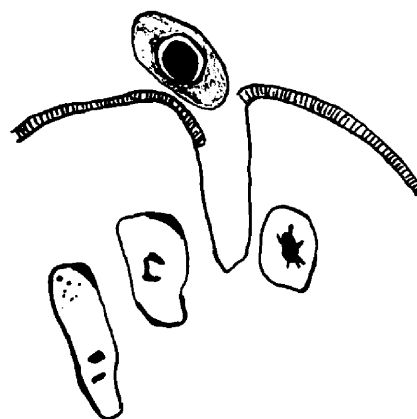
24.



25.



26.



27.



5. Six days following infection. The first generation asexual stages (Figures 28 through 34) were as previously described. These stages were decreasing in number and were superseded by the second generation asexual stages (Figures 35 through 45). The second generation trophozoites (Figures 35 and 36) divided forming an immature second generation schizont (Figure 37) with two merozoites. Each of these merozoites divided and were contiguous (Figure 38). By repeated division immature second generation schizonts containing four and six merozoites were formed (Figures 39 and 40), which matured into second generation schizonts containing 12, 14, 16, and 32 merozoites (Figures 41 through 43). A second generation schizont (Figure 44) and second generation merozoites (Figure 45) were found free in the lumen of the small intestine.

Both asexual generations were found distributed throughout the small intestine, but a few second generation trophozoites and immature schizonts were seen in the caecum and large intestine of one of the kittens.

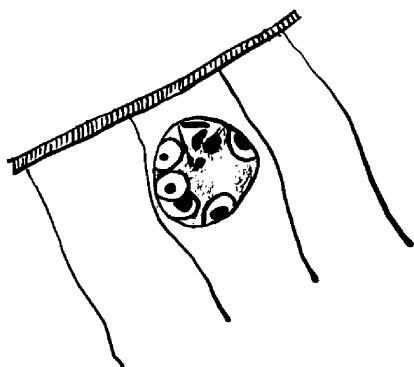
One sexual stage, a mature macrogametocyte (Figure 46) was found in the epithelium of the small intestine, approximately 27 inches from the stomach. This parasite was irregular in shape and contained a large, dark, central nucleus in a vacuole and the cytoplasm stained an uneven pale blue.

## Plate IX

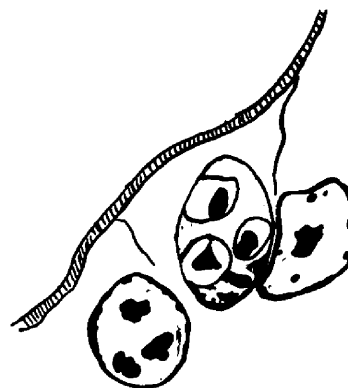
Kittens sacrificed six days after infection.

- Fig. 28. An immature first generation schizont,  
7.5 x 7.5 u, in the middle one-third of  
the small intestine.
- Fig. 29. An immature first generation schizont,  
5.5 x 10.0 u, in the middle one-third of  
the small intestine.
- Fig. 30. An immature first generation schizont,  
10.0 x 12.5 u, in the upper one-third of  
the small intestine.
- Fig. 31. A mature first generation schizont,  
7.5 x 16.5 u, containing over 24 merozoites  
in the middle one-third of the small  
intestine.

## PLATE IX



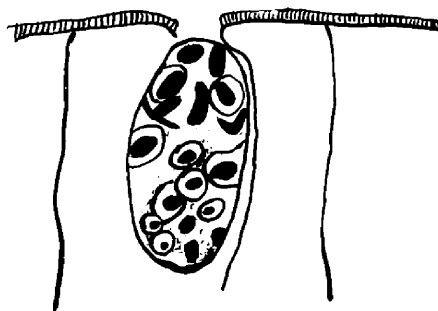
28.



29.



30.



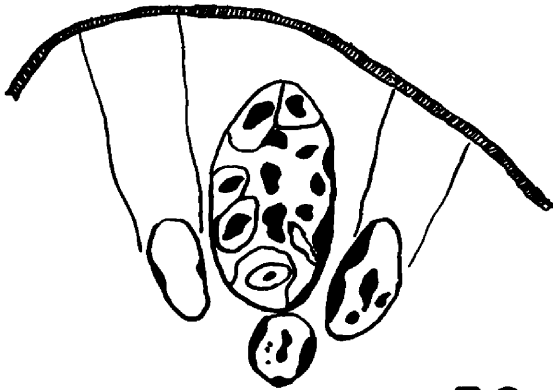31.

## Plate X

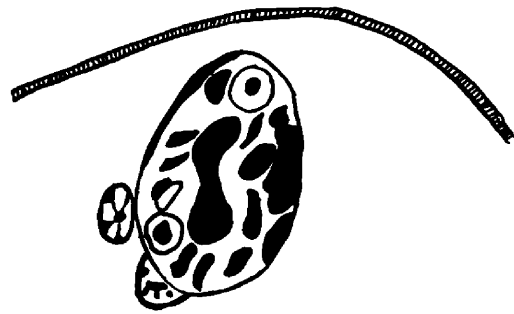
Kittens sacrificed six days after infection.

- Fig. 32. A mature first generation schizont,  
7.5 x 15.0 u, in the upper portion of the  
small intestine.
- Fig. 33. A mature first generation schizont,  
10.0 x 16.0 u, in the upper portion of the  
small intestine.
- Fig. 34. A mature first generation schizont,  
9.0 x 18.0 u, in the last one-third of  
the small intestine.
- Fig. 35. A second generation trophozoite,  
4.5 x 7.5 u, in the upper one-third of  
the small intestine.


# PLATE X



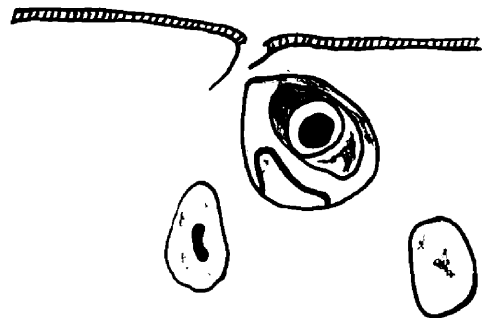
32.



33.



34.



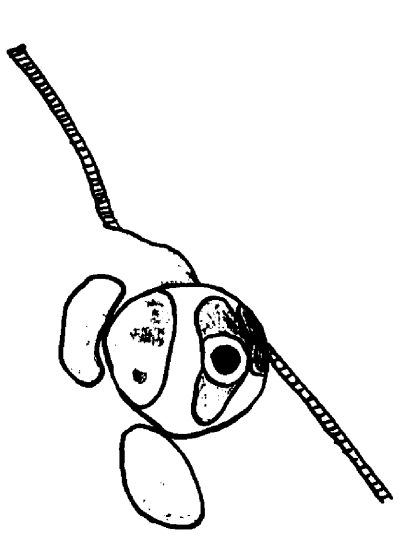
35.

## Plate XI

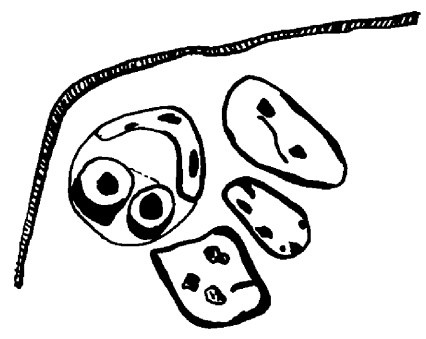
Kittens sacrificed six days after infection.

- Fig. 36. A second generation trophozoite,  
9.5 x 9.5 u, in the middle portion of  
the small intestine.
- Fig. 37. An immature second generation schizont,  
7.5 x 7.5 u, in the middle one-third of  
the small intestine.
- Fig. 38. An immature second generation schizont,  
13.5 x 18.0 u, in the upper one-third of  
the small intestine and containing four  
pair of merozoites, 4.5 x 7.5 u.
- Fig. 39. An immature second generation schizont,  
12.0 x 18.0 u, in the upper portion of  
the small intestine and containing four  
merozoites, 4.5 x 6.0 u.

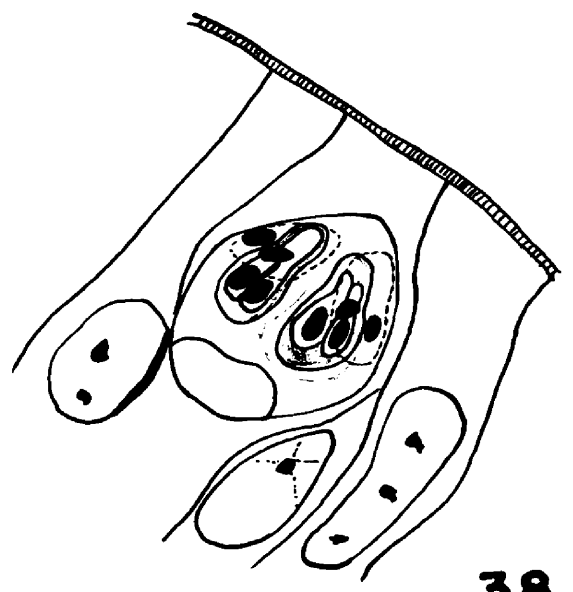
# PLATE XI



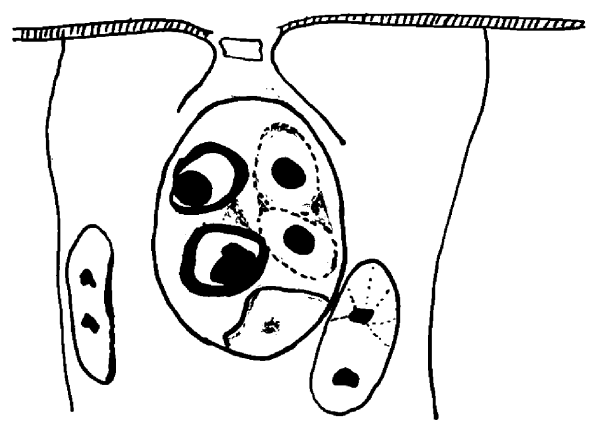
36.



37.



38.



39.

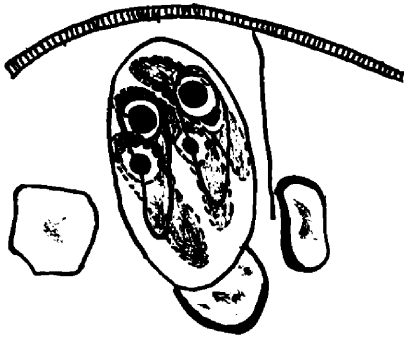
## Plate XII

Kittens sacrificed six days after infection.

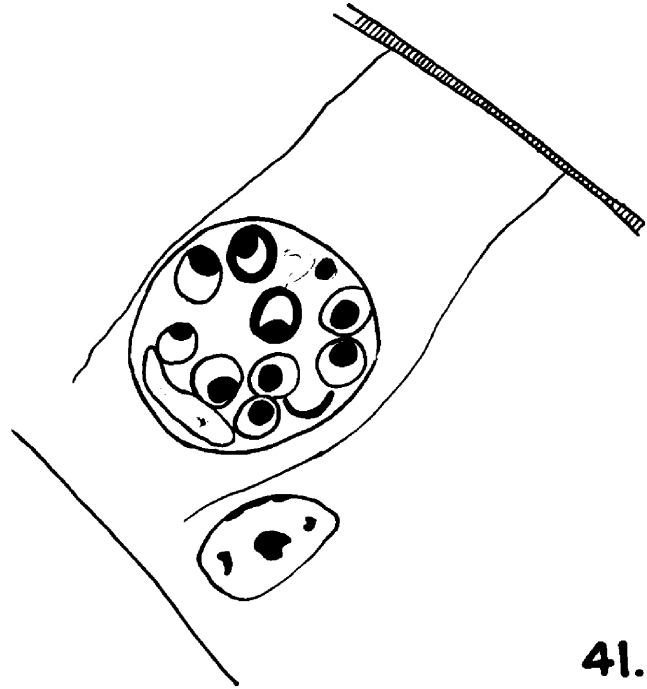
- Fig. 40. A second generation schizont, 9.0 x 18.0 u, in the middle one-third of the small intestine and containing six merozoites, 3.0 x 10.5-13.5 u.
- Fig. 41. A second generation schizont, 16.5 x 16.5 u, in the first portion of the small intestine and containing 14 merozoites, 3 u (only those in one plane were drawn).
- Fig. 42. A second generation schizont, 9.0 x 34.5 u, in the middle one-third of the small intestine and containing 16 merozoites, 3-4 u.
- Fig. 43. A second generation schizont, 15.0 x 27.0 u, in the last portion of the small intestine and containing approximately 22 merozoites.



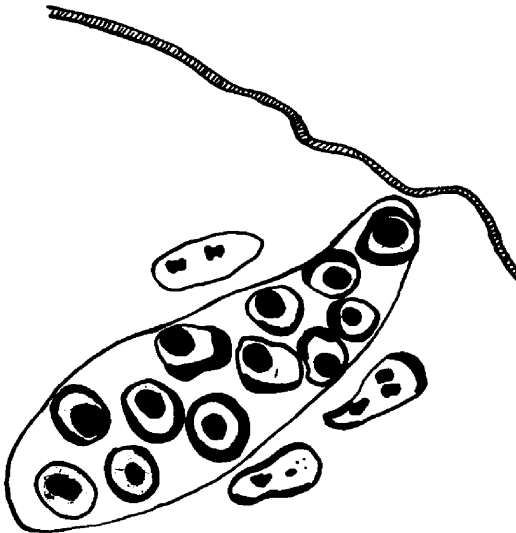
PLATE XII



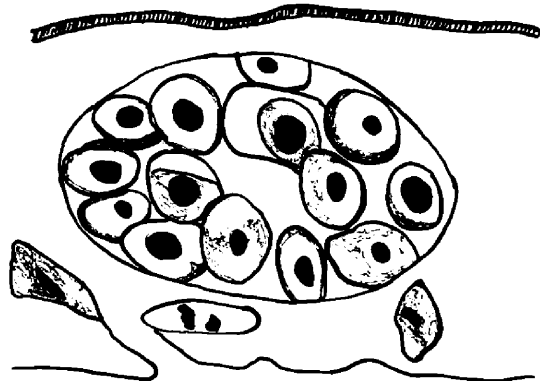
40.



41.



42.



43.

### Plate XIII

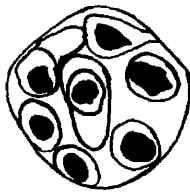
Kittens killed six days after infection.

Fig. 44. A second generation schizont, 12.0 x 13.5 u,  
free in the lumen of the small intestine  
and containing 10 merozoites (only those  
in one plane were drawn).

Fig. 45. A free second generation merozoite,  
4.5 x 10.5 u, in the lumen of the middle  
portion of the small intestine.

Fig. 46. A mature macrogametocyte, 24.0 x 30.0 u,  
in the middle one-third of the small intestine.

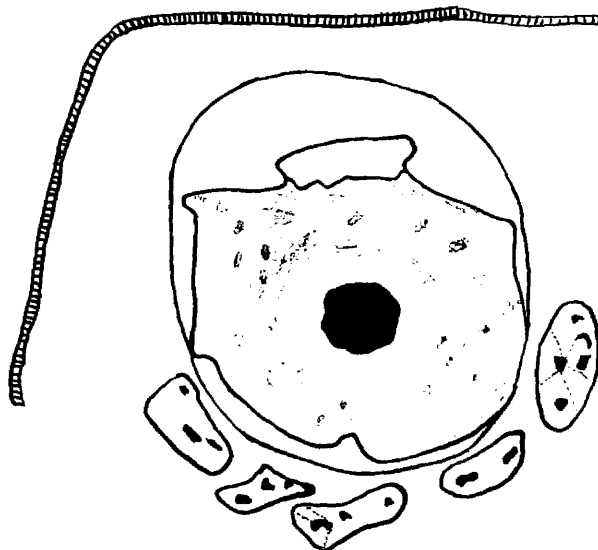
# PLATE XIII



44.



45.



46.

6. Seven days following infection. In the three kittens sacrificed at this time, a few immature and mature first generation schizonts (Figures 47 through 49) were distributed throughout the small intestine, while none were noticed in the caecum and large intestine.

The second generation asexual stages were found in the lower two-thirds of the small intestine in the three animals. In one kitten, two second generation trophozoites were found in the caecum, but no parasites were observed in the large intestine. The second generation trophozoite (Figure 50), as previously mentioned, divided forming the immature schizont (Figures 51 through 55). Many of the mature second generation schizonts (Figure 56) contained 10, 12, 18, 20, and 24 merozoites. The second generation asexual stages predominated over the first generation asexual and sexual stages.

Sexual stages were found in the small intestine of one of the three kittens. This host passed oocysts in the feces on the day of sacrifice and oocysts were found in the fresh mucosal scrapings. The immature macrogametocyte (Figure 57) resembled the second generation trophozoite, but was larger in size. The large, dark nucleus in a clear area was either central or eccentric, and the cytoplasm contained darker staining masses. By a process of maturation, the mature

macrogametocyte (Figure 58) was formed, which was larger in size than the immature stage and possessed a large nucleus in a vacuole and finely stained particles in the cytoplasm.

Only later stages of the development of the microgametocyte were observed at this time. The immature microgametocyte (Figure 59) showed peripheral chromatin masses, invaginations of the cytoplasm, and as it approached maturation there appeared a residual mass of cytoplasm with scattered chromatin, and small, crescent, nucleated bodies, the microgametes (Figure 60). The mature microgametocyte (Figure 61) lost the residual mass and was filled with numerous microgametes. The oocysts in the epithelial tissues (Figure 62) possessed a dark, central nucleus, cytoplasm with darkly stained scattered masses and a thick, unstained hyaline wall.

Many immature macrogametocytes, a few mature macrogametocytes, a very few microgametocytes and intracellular oocysts were noticed on the seventh day.

At the time of autopsy, oocysts were present in the scrapings of the wall of the small intestine of only one of the three kittens.

Plate XIV

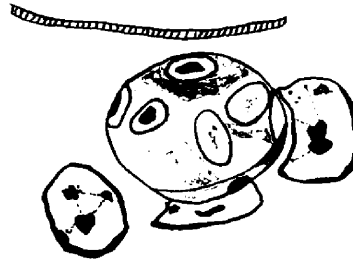
Kittens sacrificed seven days after infection.

- Fig. 47. An immature first generation schizont,  
12.5 x 15.0 u, in the small intestine  
next to the stomach.
- Fig. 48. A mature first generation schizont,  
10.5 x 12.5 u, in the small intestine  
next to the stomach.
- Fig. 49. An immature first generation schizont,  
9.0 x 12.0 u, in the small intestine  
next to the stomach.
- Fig. 50. A second generation trophozoite, 6.0 x 7.5 u,  
in the middle one-third of the small  
intestine.

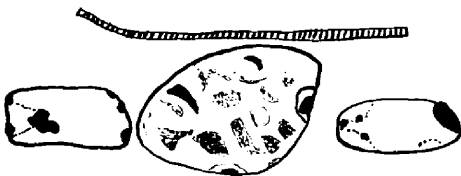## PLATE XIV



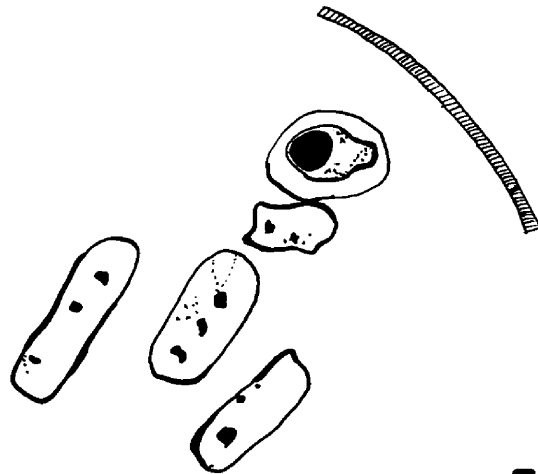
47.



48.



49.



50.

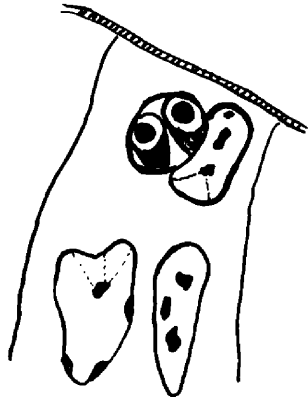
## Plate XV

Kittens sacrificed seven days after infection.


- Fig. 51. A second generation schizont, 4.5 x 6.0 u, in the middle portion of the small intestine and containing two merozoites.
- Fig. 52. A second generation schizont, 7.5 x 12.0 u, in the middle one-third of the small intestine and containing two pair of merozoites, 5.5 u.
- Fig. 53. A second generation schizont, 12.0 x 18.0 u, in the middle one-third of the small intestine and containing four merozoites.
- Fig. 54. A second generation schizont, 10.5 x 13.5 u, in the middle portion of the small intestine and containing four merozoites.




# PLATE XV



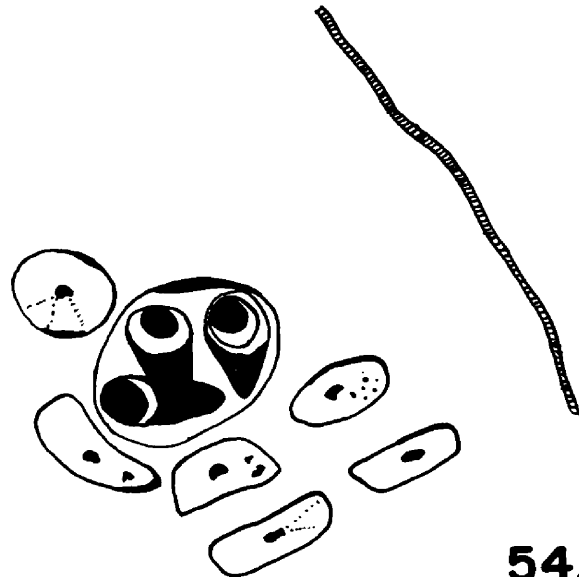
51.



52.



53.



54.

## Plate XVI

Kittens sacrificed seven days after infection.

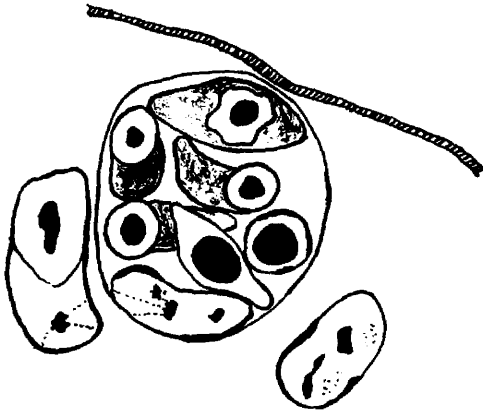
Fig. 55. A second generation schizont, 16.5 x 18.0 u,  
in the middle one-third of the small intestine and containing 8 merozoites.

Fig. 56. A second generation schizont, 18.0 x 27.0 u,  
in the middle portion of the small intestine, and containing ten merozoites, 4.5 u.

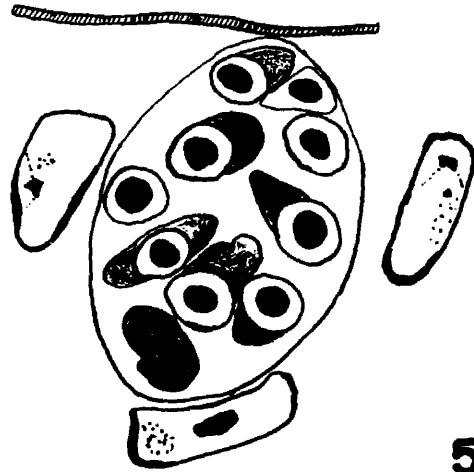
Fig. 57. An immature macrogametocyte, 9.0 x 10.5 u,  
in the middle portion of the small intestine.

Fig. 58. A mature macrogametocyte, 12.0 x 21.0 u,  
in the middle one-third of the small intestine.

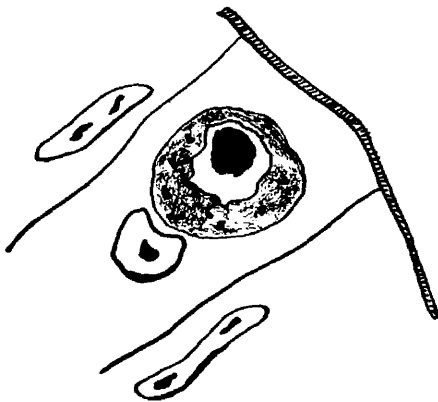
# PLATE XVI



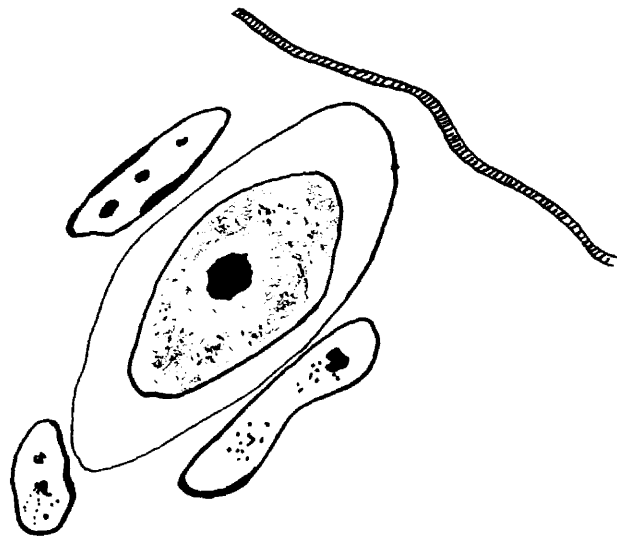
55.



56.



57.



58.

Plate XVII

Kittens sacrificed seven days after infection.

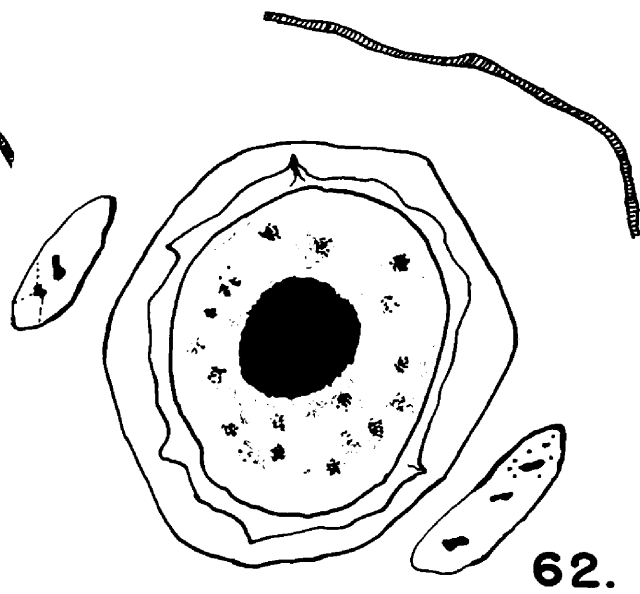
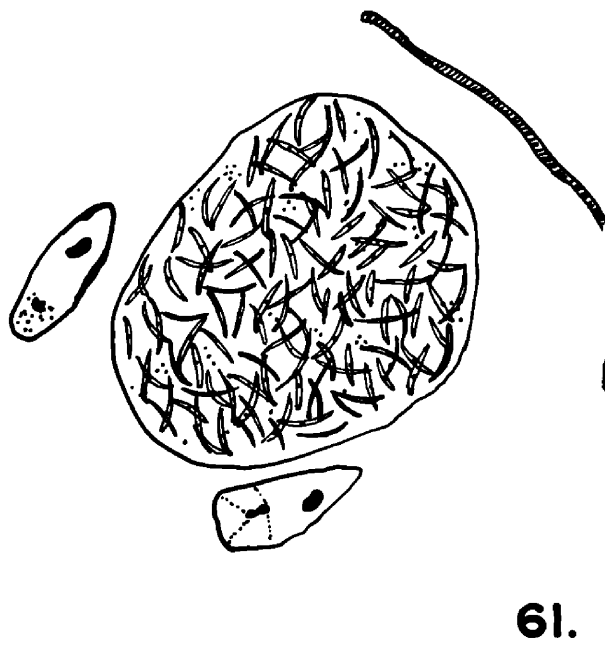
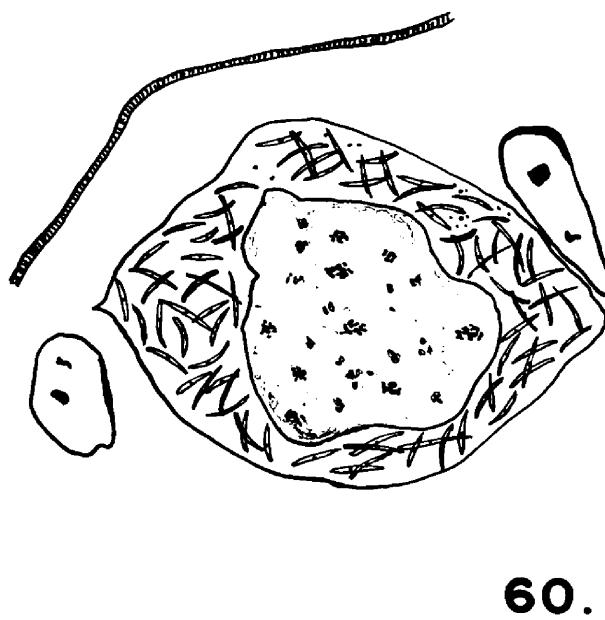
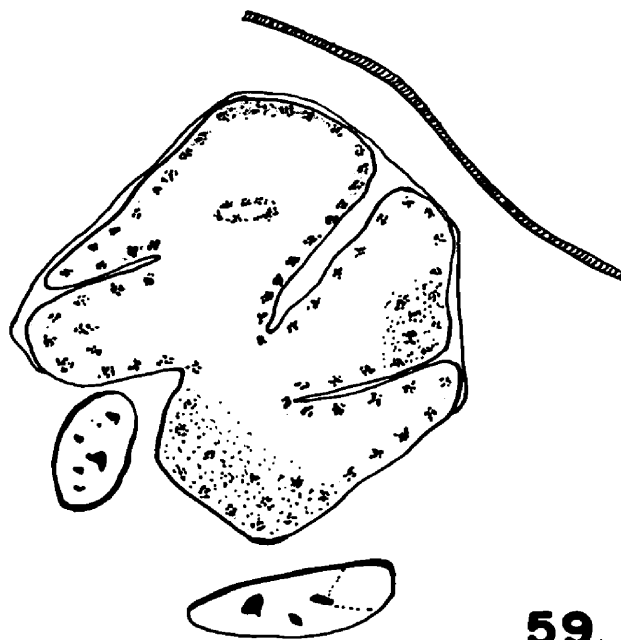
Fig. 59. An immature microgametocyte, 27.0 x 27.0 u,  
in the middle one-third of the small  
intestine.

Fig. 60. An immature microgametocyte, 27.0 x 31.0 u,  
in the middle one-third of the small  
intestine.

Fig. 61. A mature microgametocyte, 23.0 x 29.0 u,  
in the middle portion of the small intestine.

Fig. 62. An intracellular oocyst, 23.0 x 29.0 u,  
in the middle one-third of the small  
intestine.

## PLATE XVII



7. Eight days following infection. Stages of the first generation asexual cycle were not noted in either of these kittens.

The second generation trophozoite (Figure 63) and schizonts (Figures 64 through 68) were found in one kitten throughout the small intestine and in the other in only the lower two-thirds of this organ. In this latter host, second generation schizonts with from two to eight merozoites were found in the caecum and one second generation trophozoite was seen in the large intestine. Many second generation schizonts with more than 20 merozoites were observed in the small intestine of both animals (Figure 68).

Sexual stages were found throughout the small intestine of one kitten and in the lower two-thirds of this organ of the other. One macrogametocyte was found in the caecum of the latter host, although no sexual stages were found in the large intestine. The immature macrogametocytes (Figures 69 through 71) with coarse chromatin masses in the cytoplasm, developed into mature macrogametocytes (Figures 72 and 73) with fine chromatin particles.

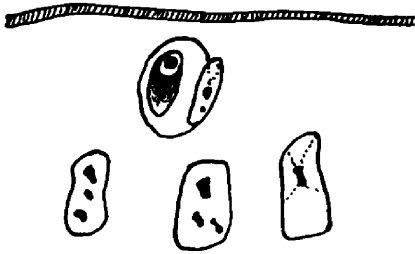
The immature microgametocyte appeared very similar to the early immature macrogametocyte (Figure 69) but the nucleus fragmented further resulting in a more developed microgametocyte (Figure 74). Indentation of the cytoplasm and collection of the chromatin on the periphery of the

## Plate XVIII

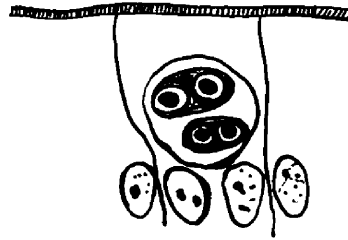
Kittens killed eight days after infection.

- Fig. 63. A second generation trophozoite,  
3.0 x 4.5 u, in the upper portion of the  
small intestine.
- Fig. 64. A second generation schizont, 9.0 x 9.0 u,  
in the last one-third of the small intestine,  
and containing two pair of merozoites.
- Fig. 65. A second generation schizont, 7.5 x 12.0 u,  
in the middle portion of the small intestine  
and containing two merozoites.
- Fig. 66. A second generation schizont, 7.5 x 9.0 u,  
in the middle one-third of the small intestine  
and containing four merozoites.

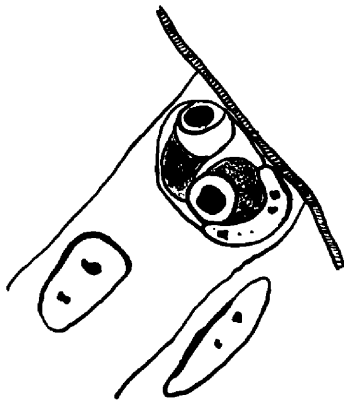
## PLATE XVIII



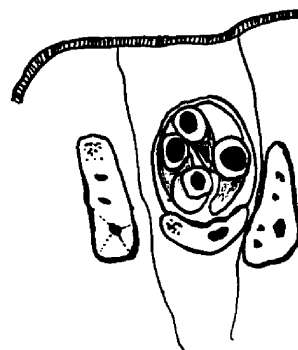
63.



64.



65.



66.

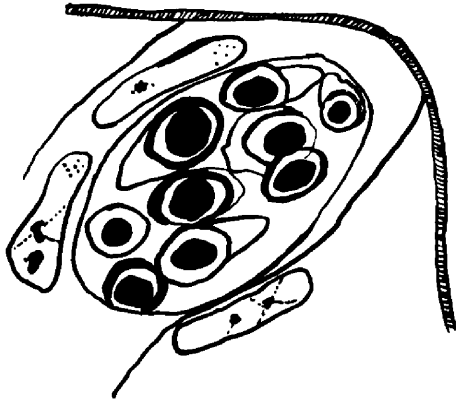


Plate XIX

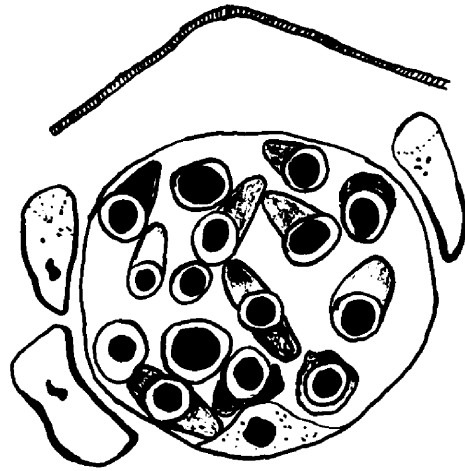
Kittens killed eight days after infection.

- Fig. 67. A second generation schizont, 13.5 x 22.5 u,  
in the middle portion of the small intestine and containing 14 merozoites.
- Fig. 68. A second generation schizont, 22.5 x 22.5 u,  
in the middle one-third of the small intestine and containing 20 merozoites.
- Fig. 69. An immature macrogametocyte, 9.0 x 12.5 u,  
in the middle one-third of the small intestine.
- Fig. 70. An immature macrogametocyte, 19.5 x 24.0 u,  
in the last one-third of the small intestine.

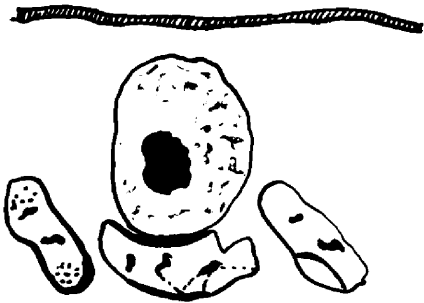
## PLATE XIX




67.



68.



69.



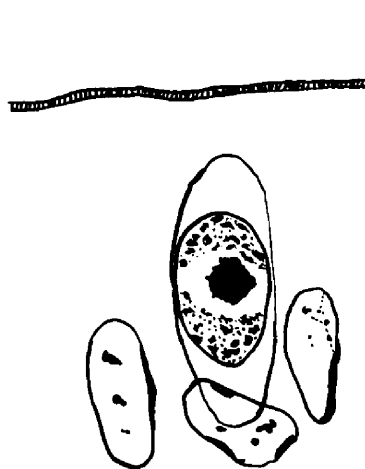
70.

Plate XX

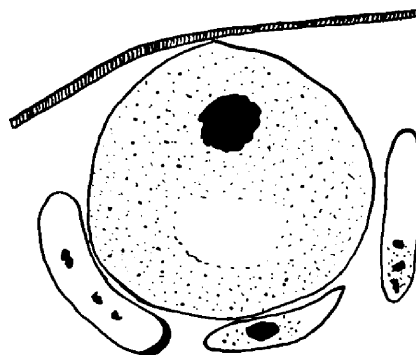
Kittens sacrificed eight days after infection.

- Fig. 71. An immature macrogametocyte,  $7.5 \times 24.0$  u,  
in the first portion of the small intestine.
- Fig. 72. A mature macrogametocyte,  $22.5 \times 22.5$  u,  
in the last one-third of the small intestine.
- Fig. 73. A mature macrogametocyte,  $25.5 \times 27.0$  u,  
in the last one-third of the small intestine.
- Fig. 74. An immature microgametocyte,  $16.5 \times 22.5$  u,  
in the first portion of the small intestine.

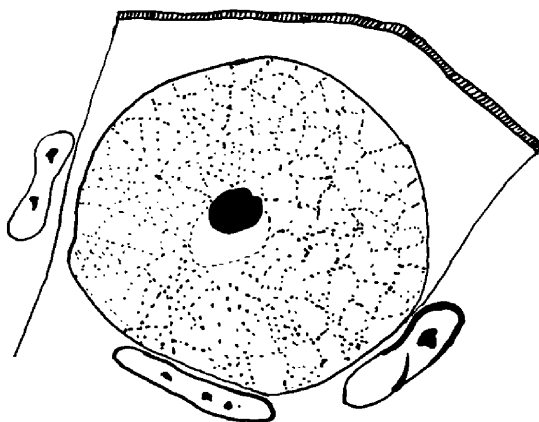
# PLATE XX




71.



72.



73.



74.

parasite occurred (Figure 75). As the parasite enlarged, the cytoplasmic mass was reduced and the microgametes formed (Figure 76). The mature microgametocyte (Figure 77) had no cytoplasmic residual mass and was filled with numerous microgametes which were curved, nucleated structures measuring 1.5 by 6 u, and too numerous to count. Free microgametes in the lumen were not seen.

An oocyst within the epithelial cell is presented in Figure 78. Unsporulated oocysts (Figure 79) were passed in the feces of one of these kittens on the seventh day and the other on the eighth day, thus the prepatent period is 7-8 days. Unsporulated oocysts were found in the fresh mucosal scrapings from the small intestine of both animals.

Plate XXI

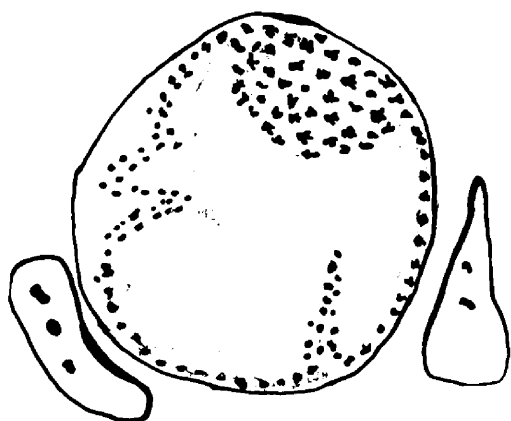
Kittens killed eight days after infection.

Fig. 75. An immature microgametocyte, 24.0 x 27.0 u,  
in the upper one-third of the small  
intestine.

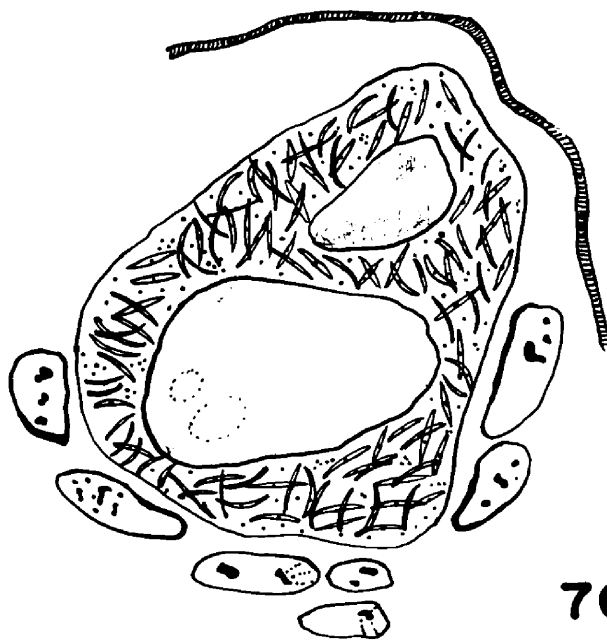
Fig. 76. An immature microgametocyte, 28.5 x 33.0 u,  
in the last portion of the small intestine.

Fig. 77. A mature microgametocyte, 22.5 x 30.0 u,  
in the last one-third of the small intestine.


## PLATE XXI



75.



76.



77.

Plate XXII

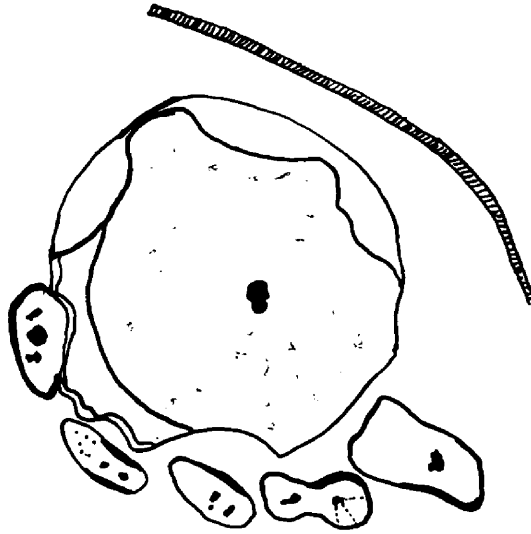
Kittens killed eight days after infection.

Fig. 78. An oocyst, 22.5 x 24.0 u, in an epithelial cell of the middle portion of the small intestine.


Fig. 79. An oocyst, 18.0 x 24.0 u, free in the lumen of the middle portion of the small intestine.



# PLATE XXII



78.



79.

### C. Symptomatology and Pathology

Of the eighteen kittens infected with 100,000 sporulated oocysts, none showed gross or microscopic blood in the feces. Some of them had diarrhea, as did some of the non-infected controls. The animals were alert, playful, ate well and showed no symptoms which were attributed to the infection with I. felis. No gross or microscopic lesions, or deaths, were encountered.

## V. DISCUSSION OF RESULTS

### A. Artificial Infections

Most of the early studies on I. felis were made on natural infections instead of experimentally produced conditions. Grassi (1882) failed in his attempt to infect cats with oocysts of "Coccidium Rivolta" which had "developed a few days". Andrews (1926) produced artificial infections of I. felis in four week old kittens (750 grams or less). He found that if he gave less than 100,000 sporulated oocysts by stomach tube the kittens lived, but if he gave over that number they died within a week.

In the present study, kittens of approximately the same age were infected, pre-infection fecal examinations were done to establish that the hosts were coccidia free, all animals received the same number of oocysts of I. felis, and post-infection fecal examinations were made until the animals were sacrificed. Two control kittens were observed and killed after twelve daily fecal analyses showed no oocysts of coccidia.

## B. Kittens Sacrificed

1. Two days after infection. At this interval, only immature and mature first generation schizonts were observed. Figures 80 and 81 are representative mature first generation schizonts in the epithelial cells of the small intestine. Stages B and C are about ready to release the first generation merozoites into the lumen of the gut. The merozoites appear to be mainly chromatin with no definable cytoplasm. Stages A and D are situated further below the cilia. No trophozoites (stages with a single chromatin mass) were found. The reason for this may be that no kittens were sacrificed earlier than 48 hours after infecting. Since it was difficult to obtain kittens free of natural coccidiosis, and as it was not known if the coccidial stages appeared on the very first day in the epithelial cells, it was considered advisable to utilize the available coccidia-free animals for infection, and kill at time intervals later in the cycle.

The earlier workers, Swellengrebel and Wasielewski, and Wenyon as late as 1923, did not use the term "trophozoite" to designate the stage with only one chromatin mass. The smallest form which Wenyon described in the epithelial cells as the "schizont", would in the light of our present knowledge, be called the second generation trophozoite.

The first generation schizonts were not mentioned by the early investigators. This might have been due to the

fact that most of the earlier observations were made on natural infections late in the cycle, after oocysts were being passed in the excreta, and the first generation asexual cycle would have been completed before this time.

Figures 80 through 93 are unaltered photomicrographs of tissue sections stained with eosin-hematoxylin. They were taken under oil immersion at a final magnification of x1,320.

Plate XXIII

Fig. 80. First generation schizonts, A and B, of Isospora felis in the epithelial cells of the small intestine of a kitten killed on the sixth day of the infection.

## PLATE XXIII

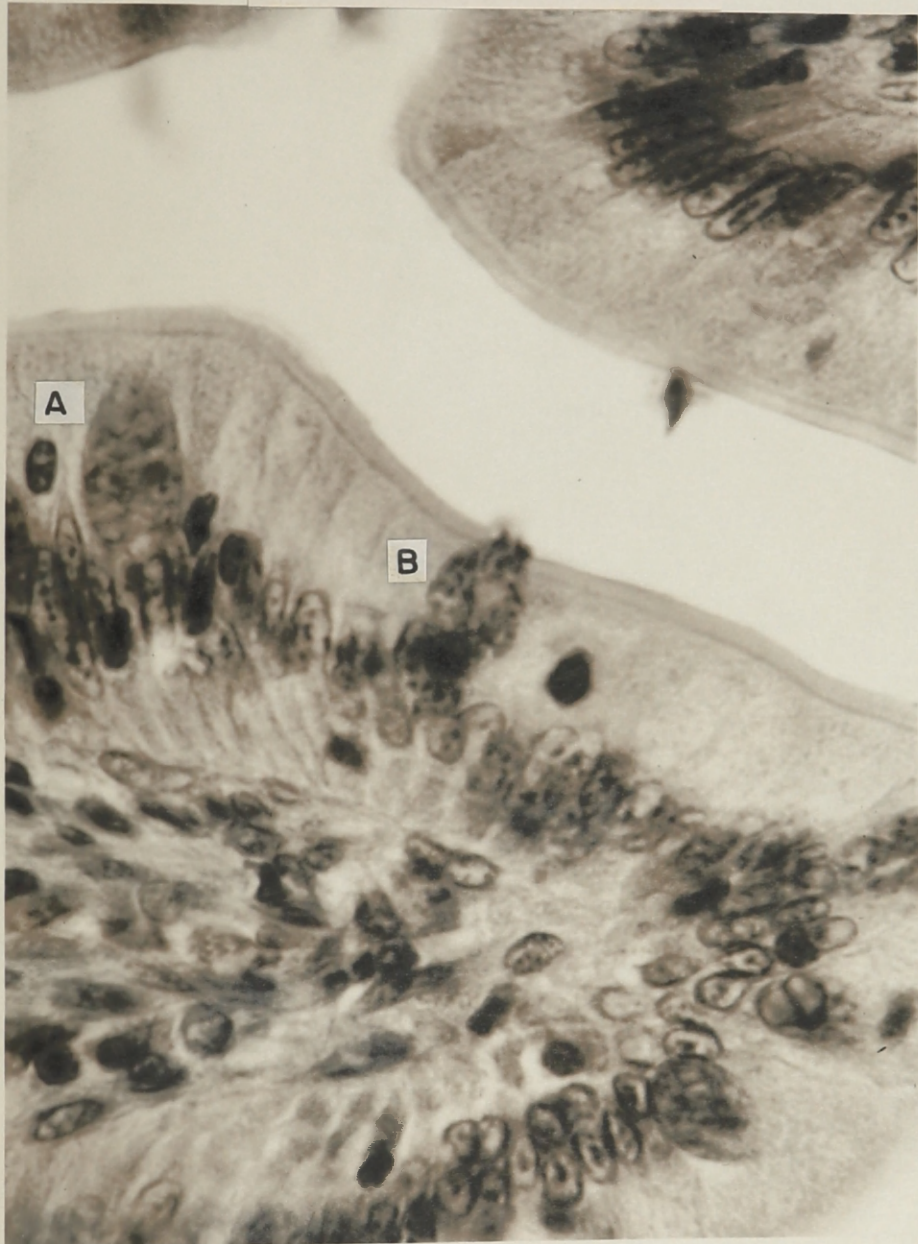
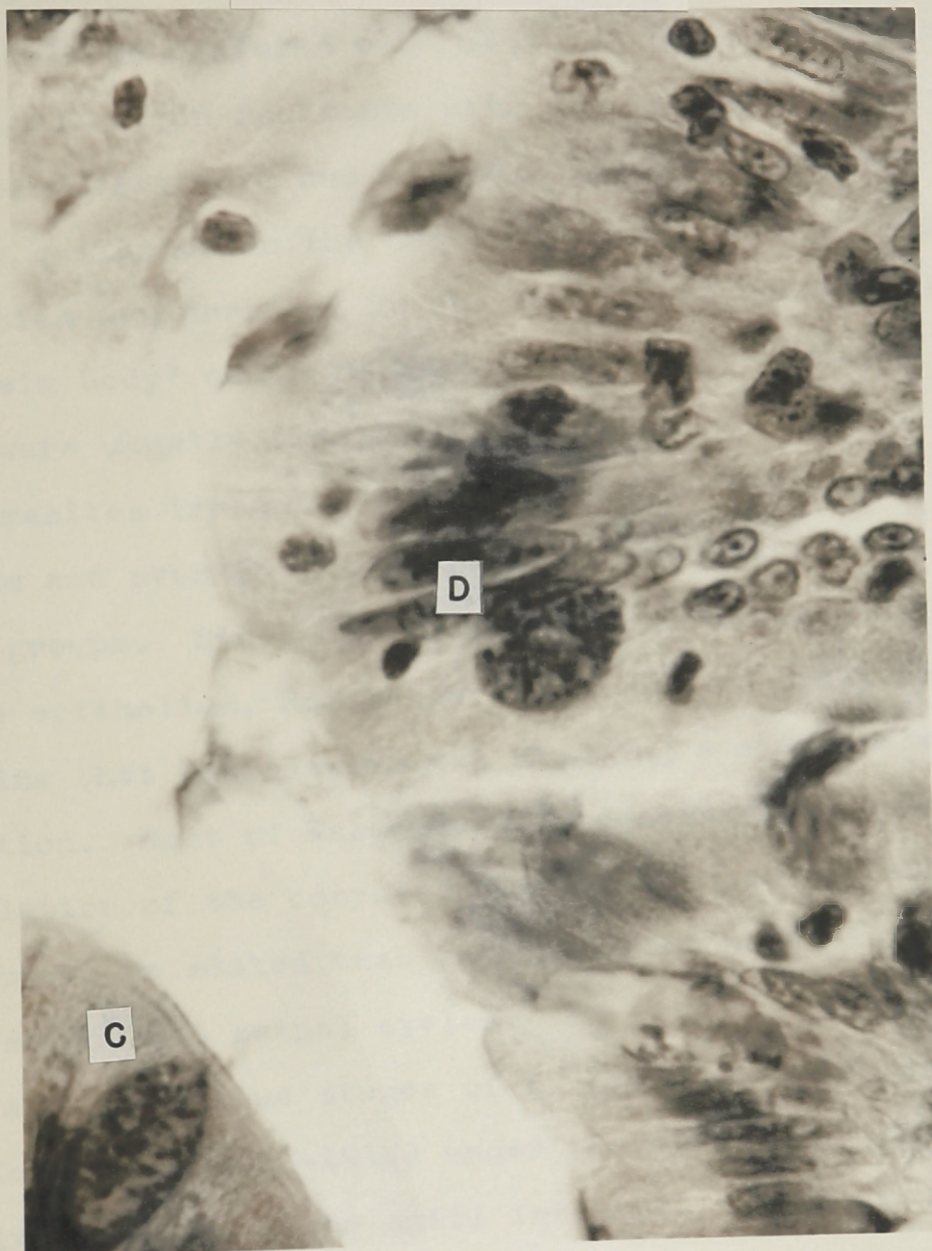


Plate XXIV

Fig. 81. First generation schizonts, C and D, of I. felis in the epithelial cells of the small intestine of a kitten killed on the sixth day of infection.



## PLATE XXIV



2. Three days after infection. Wasielewski (1904) portrayed, under the name of Diplospora bigemina, I. felis as "twin forms", diameter 10 u, average 7-8 u or 9-10 u, which could be confused with fat. He had probably seen second generation schizonts with two merozoites. Their outlines were very dark and marked. The contents were frequently collected in the center and consisted of a granular mass which was arranged in one or several bodies. At times one "twin body" could be surrounded by an envelope, but there were usually two in the membrane. At autopsy he found the parasites irregularly distributed in the intestinal epithelium and even in the depth of the mucosa arranged singly or in groups. Since he found parasitic stages in the depth of the epithelium, Reichenow (1921) was probably correct in assuming that Wasielewski was studying a mixed coccidial infection. Most of Wasielewski's observations were on the sporulation of the oocysts. Realizing that his study was incomplete he stated that he hoped someone would investigate the asexual and sexual cycles.

Asexual tissue stages of I. felis were outlined by Swellengrebel (1913-1914) under the name of I. bigemina. He fixed smears of the small intestine of cats with natural infections in Hg Cl<sub>2</sub>-alcohol and stained with Delafield's hematoxylin, and also embedded tissues in paraffin and cut sections at 10 u. He described stages which, when developed

to the size of 12 u, had nuclear division into two pieces, and became smaller and compact with the clear zone less distinct. The protoplasm was alveolar, homogeneous, divided and light lines appeared between protoplasmic divisions. This stage, in the light of the present work, would now be called the immature second generation schizont. He said that the parasite increased in size, filled the host's cell and pushed the nucleus to the side, but did not rupture the host's cell membrane. The stages which he characterized were uneven in size, 20 x 25 u and 32 x 48 u. This compared with the mature second generation schizont of this work. Merozoites, 8-12 u x 3-4 u, were sketched as free in the lumen of the small intestine. The nucleus was a compact structural, chromatin mass surrounded by a light zone. Thus Swellengrebel was the first to relate the morphological characteristics of the second generation asexual stages.

The second generation trophozoite was described by Wenyon (1923) under the name of "schizont". He sketched these stages, 5 u in length, as being the smallest forms found lying in vacuoles in the epithelial cells. Their nuclei were spherical with a definite membrane, and the parasites were curved with a pointed anterior end and a rounded posterior end. This organism grew until it was about 5 x 10 u and then nuclear division commenced. It was ovoid in shape by the time eight merozoites were

formed in the mature second generation schizont. These merozoites developed into either schizonts or sexual stages. Wenyon related, under the heading "schizont", a discussion of the morphological characteristics of the second generation trophozoite and schizonts, since he did not observe the first generation asexual stages.

The majority of the stages found in the present investigation at this time interval were immature and mature first generation schizonts. A very few second generation schizonts were observed. Not all of the first generation merozoites penetrated the host's cells at the same time, nor did they all grow at the same rate. A very few of the first generation merozoites entered the second asexual cycle before the others, thus accounting for the early second asexual stages on the third day of the life cycle of I. felis.

3. Four days after infection. The first asexual generation stages were still more prevalent than the second asexual generation. There were more of the second generation stages found at this time interval than at the three day period. This finding of a few stages of the next generation before the first cycle is completed is not unusual as it had been observed in the coccidia of other animals (Tyzzer, 1929). The second asexual generation kept increasing in numbers and eventually dominated the scene.

4. Five days after infection. On the fifth day after infection, the second generation asexual predominated over the first. Second generation trophozoites and immature schizonts with two and four merozoites were the most common. The second generation trophozoite (Figure 82-E) is cone-shaped lying in a vacuolated epithelial cell of the small intestine. The host's cell nucleus has been pushed to the right. The nucleus of the parasite is a single, large, dark mass surrounded by a light zone. This trophozoite divided into two merozoites (Figure 83-F) which have pushed the host's cell nucleus to the upper right. Further division of the chromatin and cytoplasm took place with the formation of pairs of merozoites. Figure 84-G is an immature second generation schizont with four such pairs of merozoites; those on the right are the clearest. A few immature schizonts were seen with six, eight and ten merozoites. A very few mature schizonts with 12 and 16 merozoites were observed. A mature schizont was large in size, extended and distorted the host cell pushing the nucleus peripherally, appeared to rupture into the lumen of the gut and contained a number of merozoites.

For the first time in this study, free second generation merozoites were found in the lumen. These stages entered epithelial cells and probably repeated the second generation asexual cycle or initiated the sexual cycle.

Plate XXV

Fig. 82. A second generation trophozoite, E, of I. felis in an epithelial cell of the small intestine of a kitten killed on the fifth day after infection.

## PLATE XXV

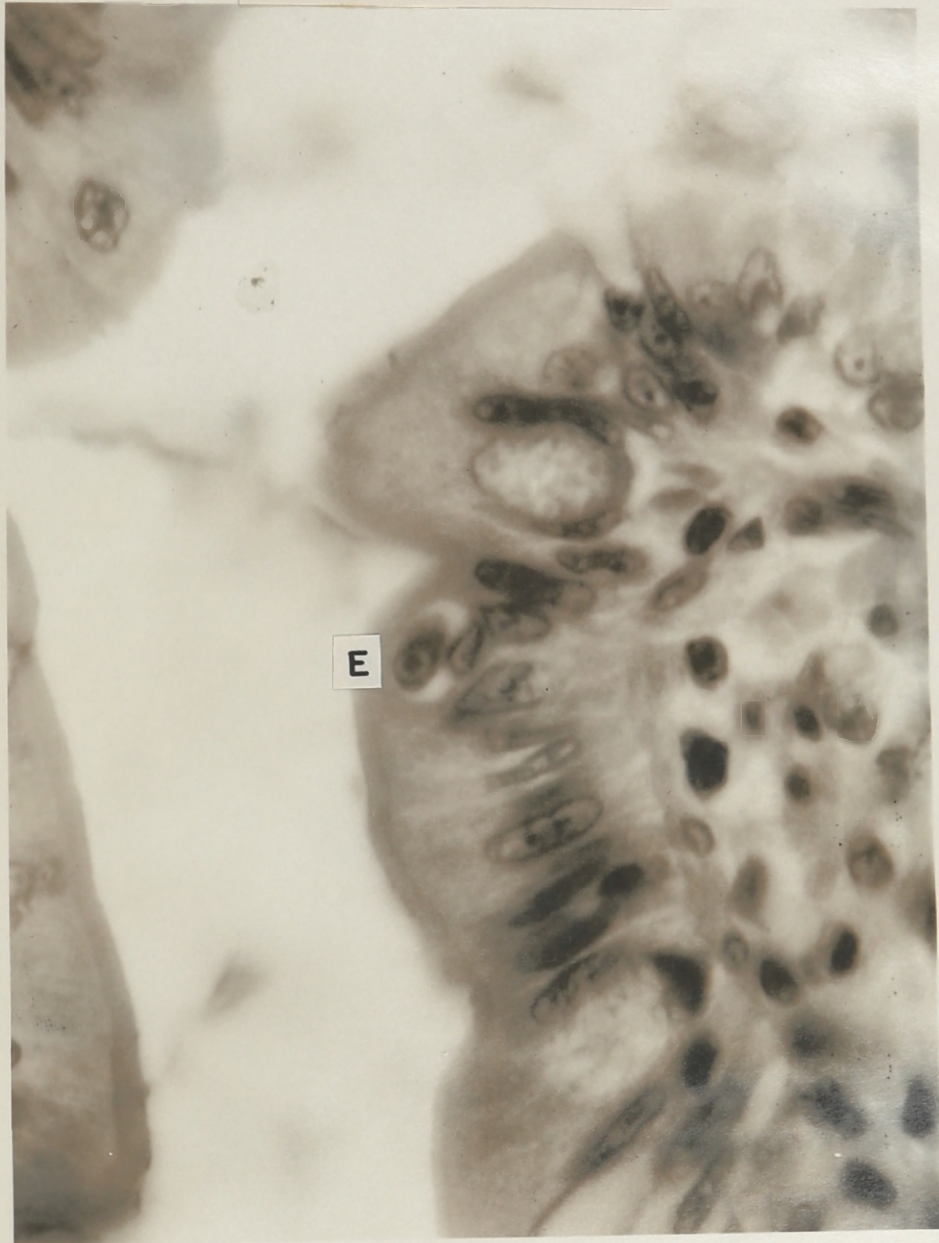




Plate XXVI

Fig. 83. A second generation immature schizont of I. felis with two merozoites, F, in an epithelial cell of the small intestine of a kitten killed on the sixth day after infection.

## PLATE XXVI

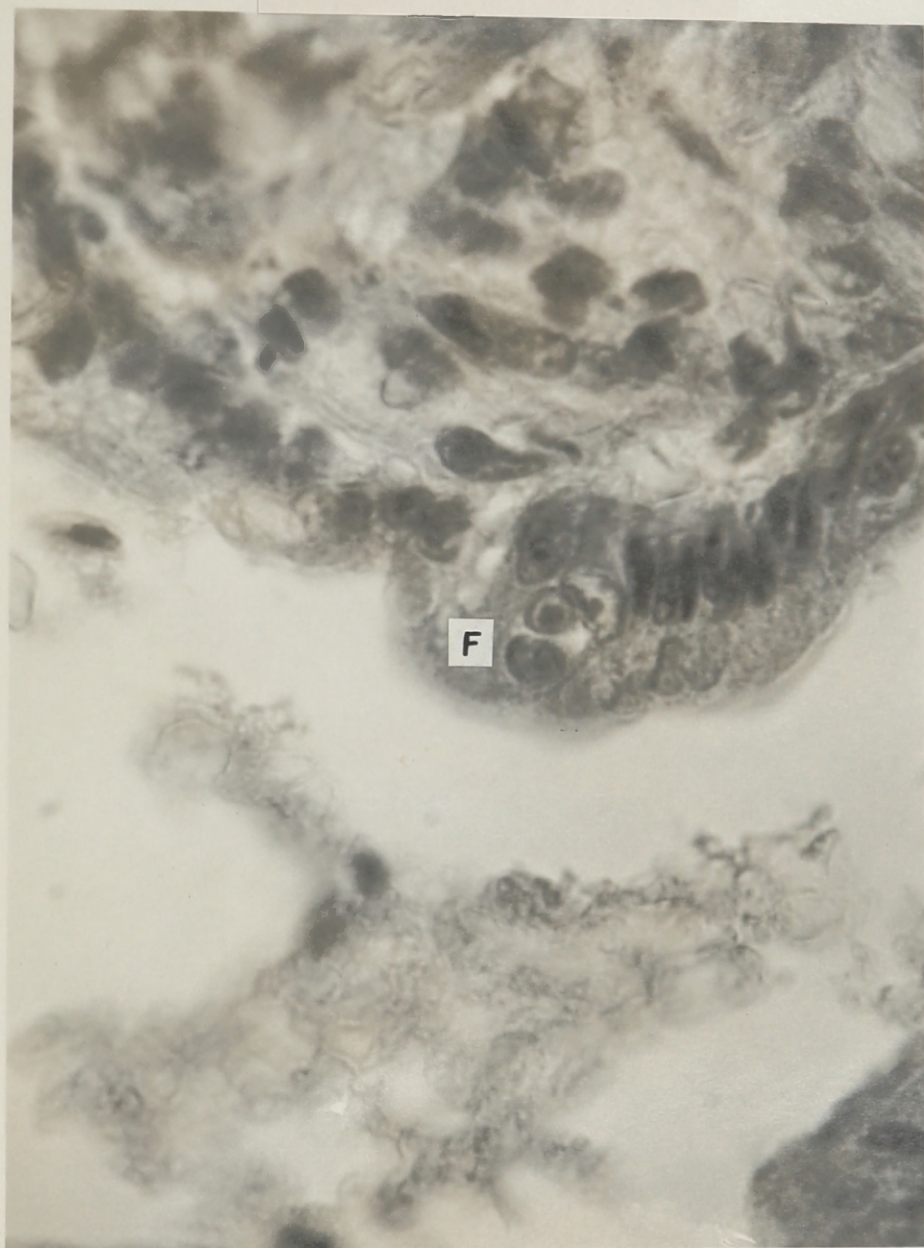
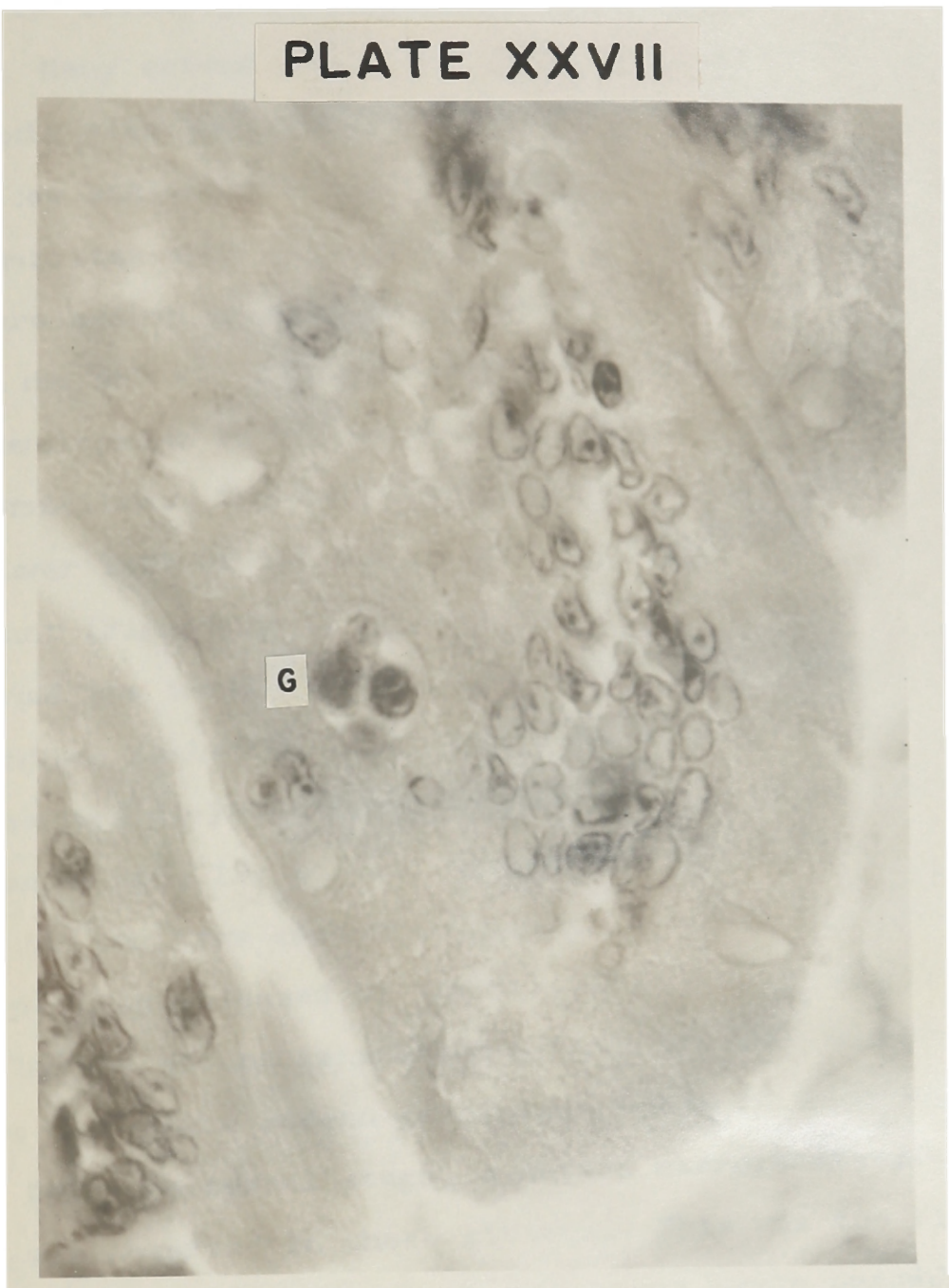


Plate XXVII

Fig. 84. A second generation immature schizont of I. felis with four pair of merozoites, G, in an epithelial cell of the small intestine of a kitten killed on the sixth day after infection.

## PLATE XXVII



5. Six days after infection. At six days after infection, the second generation asexual cycle definitely predominated. Many second generation trophozoites, many immature schizonts with two, four, six, eight, and ten merozoites, and a few schizonts close to maturity with 12, 14, 16, and 24 merozoites were represented. Figure 85-H represents an immature second generation schizont with six merozoites, which are not all in focus in one plane. Further along in the development is Figure 86-I which is larger and contains 14 merozoites. The host's cell nucleus has been pushed to the lower left of the cell. A mature second generation schizont (Figure 87-J) with 24 or more merozoites has greatly enlarged the invaded epithelial cell. Many immature second generation schizonts (Figure 38) were present. These stages represented dividing forms which resulted in maturing schizonts with 12, 14, 16, 24 or more merozoites.

The one free second generation schizont (Figure 44) was probably released by the fragmentation of tissues. Usually the second generation merozoites were discharged after the mature second generation schizont ruptured.

Only one sexual stage, a mature macrogametocyte (Figure 46), was observed in these kittens. This was the first indication that the bulk of the sexual cycle probably would appear on the seventh day. The absence of oocysts in the mucosal scrapings of the small intestine and excreta

furnished evidence that the sexual cycle had not advanced to the stage of oocyst production.

Plate XXVIII

Fig. 85. A second generation immature schizont of I. felis with six merozoites, H, in an epithelial cell of the large intestine of a kitten killed on the eighth day after infection.

## PLATE XXVIII

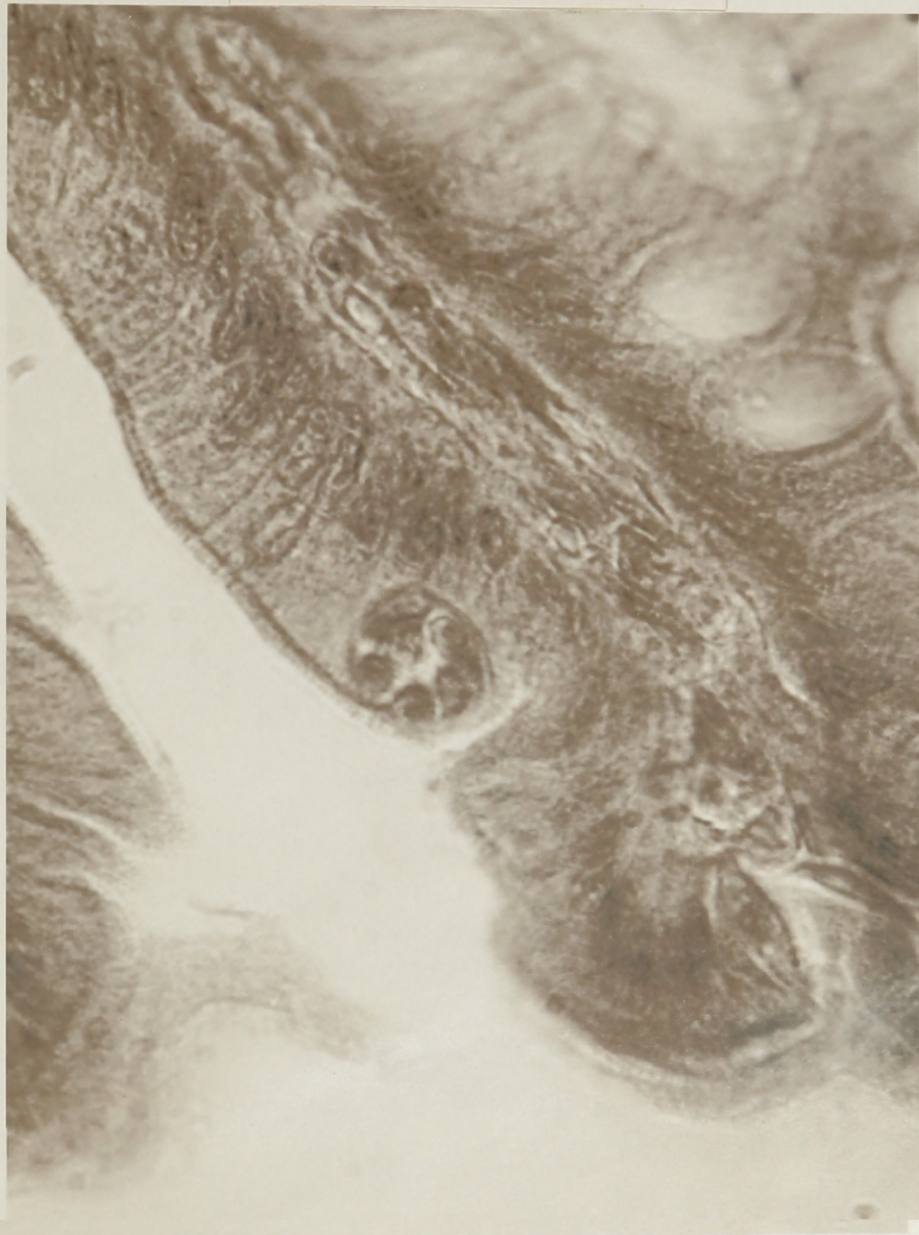




Plate XXIX

Fig. 86. A second generation schizont of I. felis with 14 merozoites, I, in an epithelial cell of the small intestine of a kitten killed on the fifth day after infection.

## PLATE XXIX

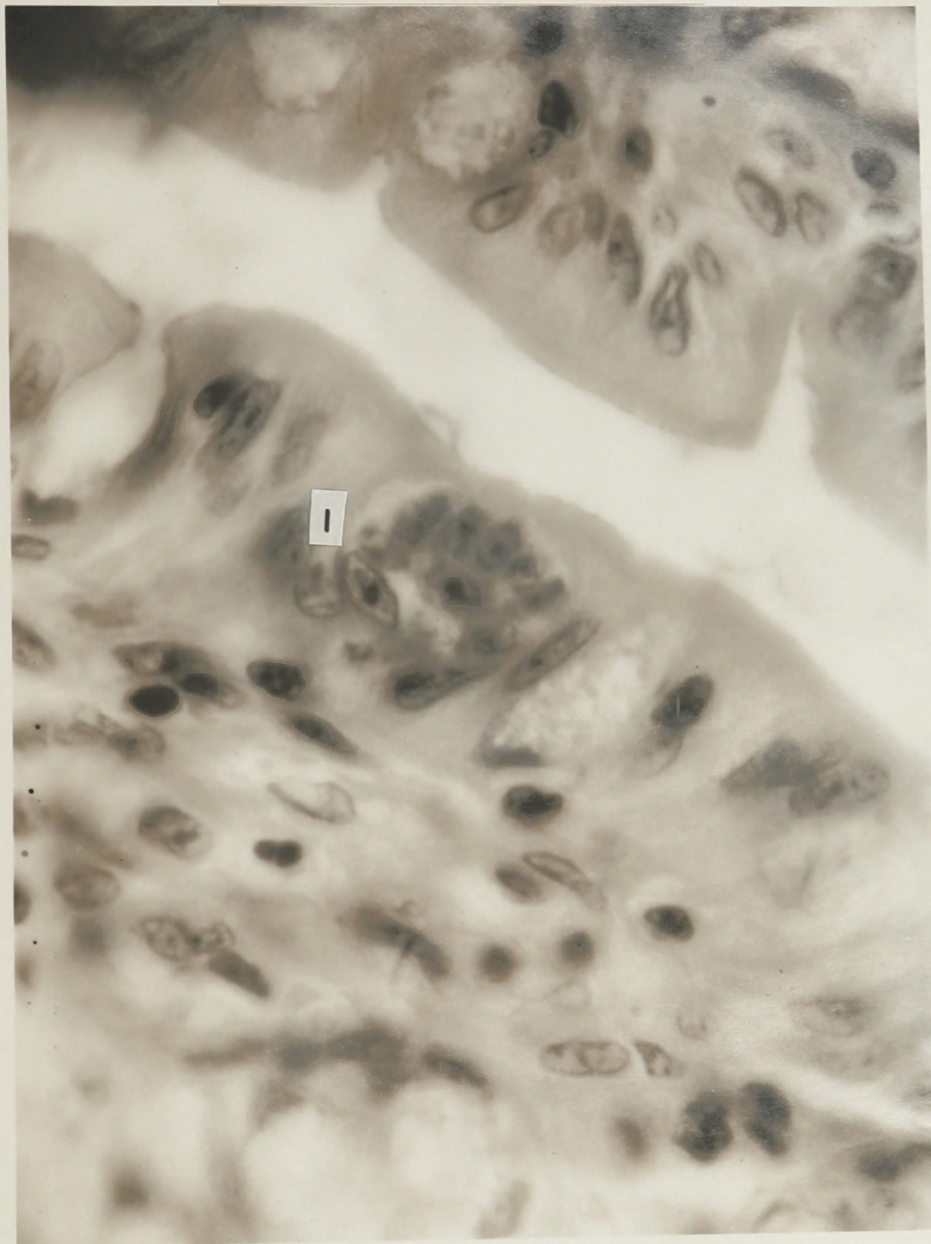
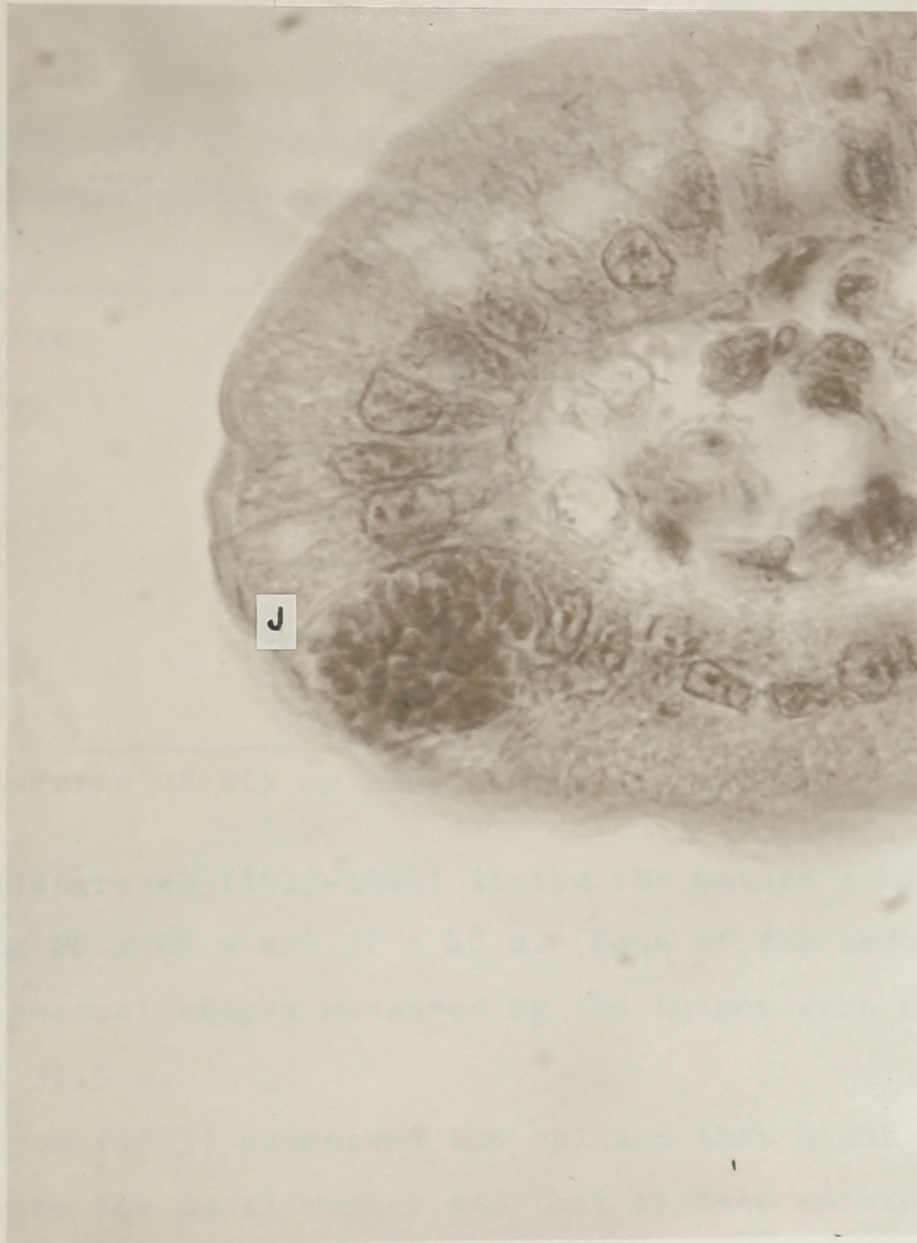


Plate XXX

Fig. 87. A second generation schizont of I. felis with 24 or more merozoites, J, in an epithelial cell of the small intestine of a kitten killed on the eighth day after infection.

## PLATE XXX



6. Seven days after infection. Many second generation asexual stages were observed and their representative measurements listed in the table below.

TABLE  
MEASUREMENTS OF SOME SECOND GENERATION ASEXUAL STAGES

Stage	Number of Merozoites	Measurement*			
Trophozoite	0	5.6	x	7.6	u
Schizont	2	7.5	x	9.3	u
Schizont	4	9.7	x	12.5	u
Schizont	6	12.2	x	16.8	u
Schizont	8	15.8	x	20.7	u
Schizont	10	16.3	x	21.5	u
Schizont	12	13.8	x	18.5	u
Schizont	14	14.5	x	21.8	u
Schizont	16	16.5	x	21.0	u
Schizont	18	18.5	x	23.9	u
Schizont	20	20.8	x	25.8	u
Schizont	24+	18.6	x	23.2	u

\* Average of six or more stages measured.

Swellengrebel (1913-1914) listed the mature schizonts as measuring 20 x 25 u and 32 x 48 u. None of the second generation asexual stages measured by the author were more than 25.5 u x 31.5 u.

Wenyon (1923) expressed the opinion that eight merozoites were the usual number and that sixteen merozoites rarely occurred. In the present study, second generation schizonts with 10, 12, 14, and 16 merozoites were common and those with 20 and 24 were noticed in several instances. Wenyon did not relate the sizes of the immature and mature schizonts.

Three kittens were examined at the seven day interval, since only one sexual stage was found on the sixth day. One of the animals sacrificed after seven days of the infection showed oocysts in the mucosal scrapings and in the excreta. Sexual intracellular stages were found in the small intestine.

7. Eight days after infection. At this late interval in the cycle, the second generation asexual and sexual stages predominated. Second generation schizonts with from 2 to 24 merozoites were seen.

Most of the sexual stages were found in the small intestine. Many immature macrogametocytes, a few mature macrogametocytes and a few microgametocytes were present. Figure 88-K is an immature macrogametocyte located near the row of nuclei of the epithelial cells of the small intestine. This stage appears as a large second generation trophozoite, and developed into the mature macrogametocyte (Figure 89-L). This stage is much larger with finely granular material.

Wasielowski (1904) illustrated the microgametocytes of Eimeria cuniculi. The surface of this stage was occupied by small granules and had a deep involution, similar to Figure 75. The microgametocytes measured in the present work, averaged  $19.1 \times 27.9$  u. Swellengrebel (1913-1914) stated that the microgametocyte measured  $35 \times 47$  u. He described the development of the microgametes. The chromatin of the microgametocyte became blistered, then worm-like or spindle-form and curved. The microgametes, lying parallel in groups, had two flagella. Although two flagella are characteristic of the microgametes of the species of coccidia, the current investigation did not reveal them since special staining procedures were not employed.

Plate XXXI

Fig. 88. An immature macrogametocyte of I. felis,  
K, in an epithelial cell of the small  
intestine of a kitten killed on the  
eighth day after infection.



## PLATE XXXI

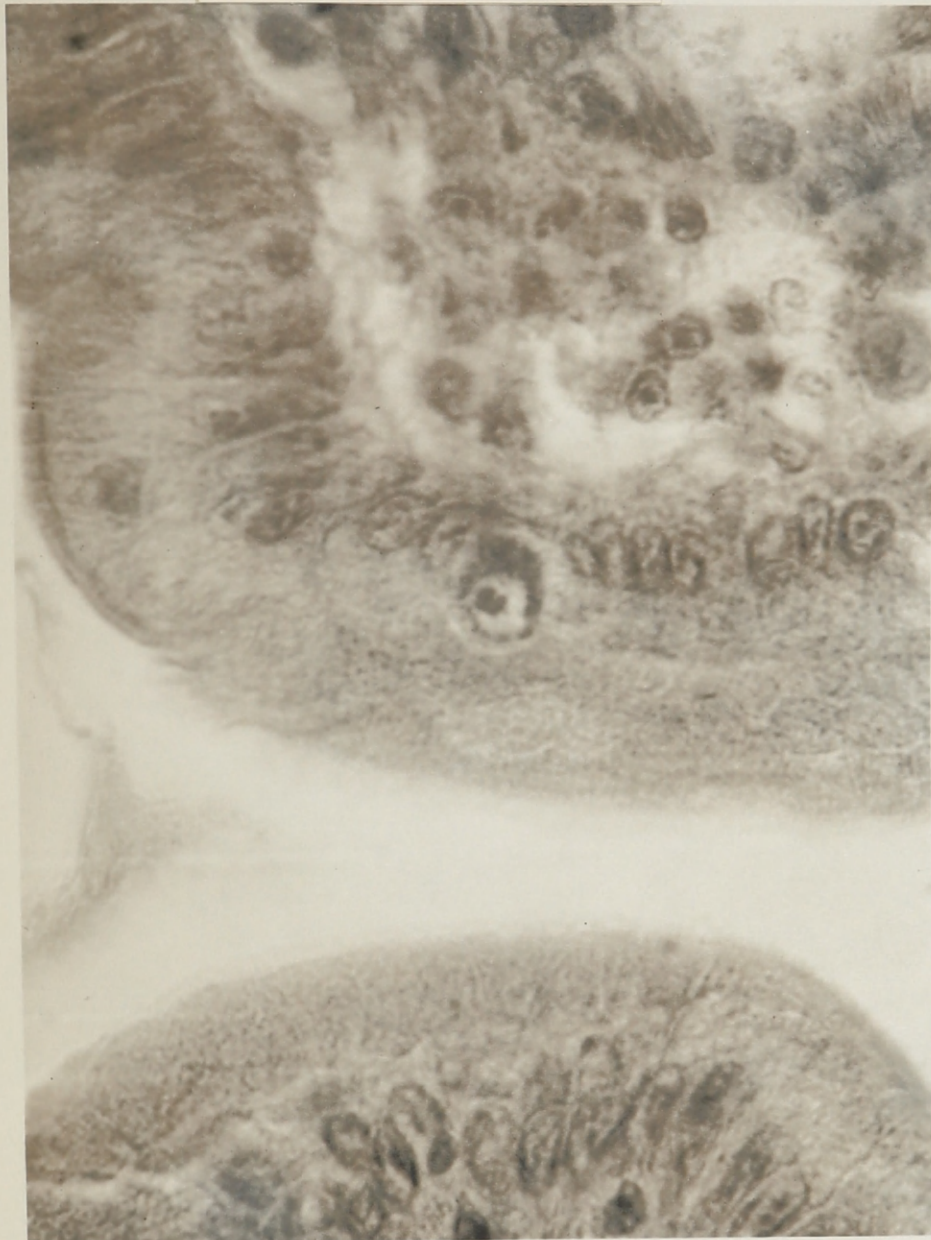
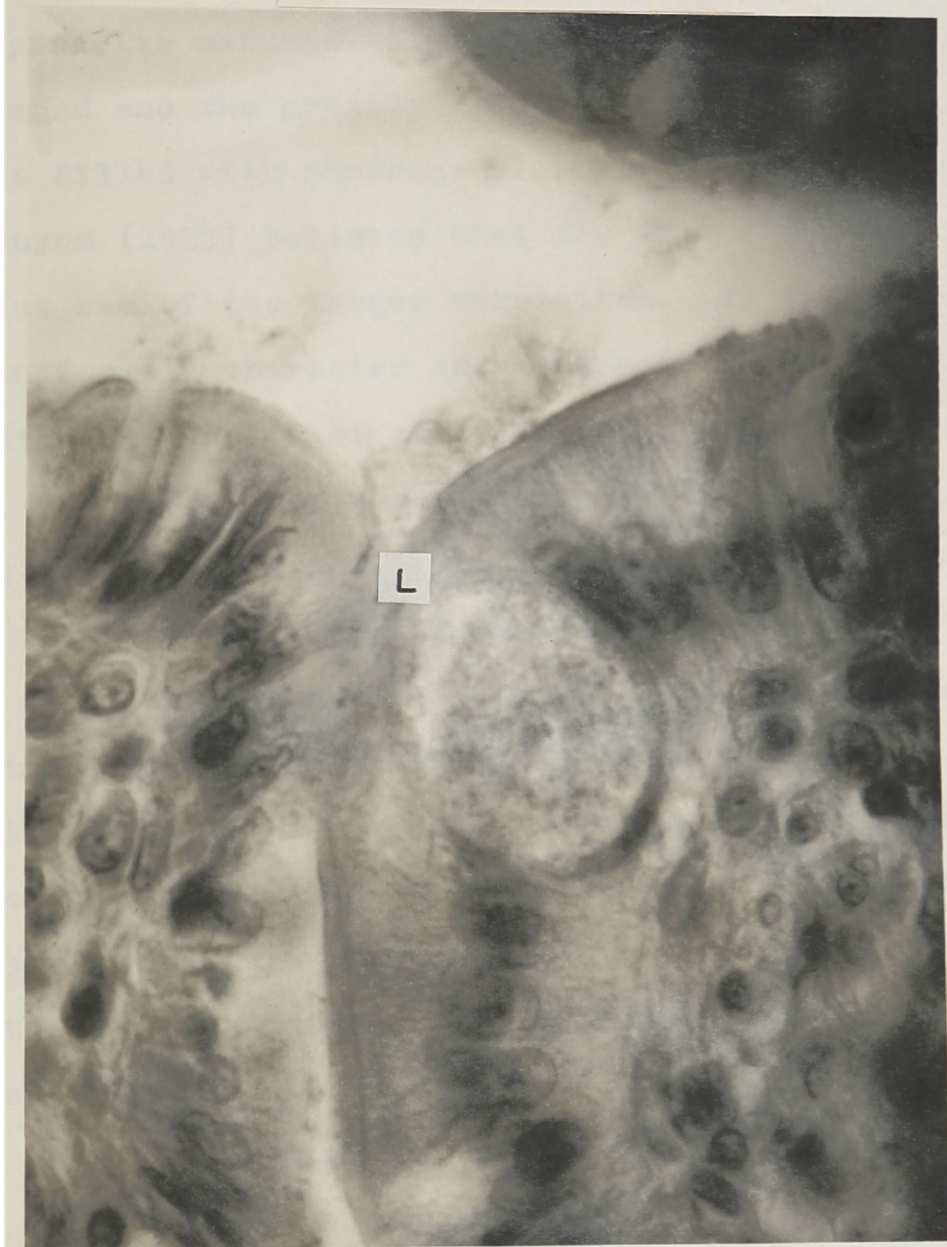


Plate XXXII

Fig. 89. A mature macrogametocyte of I. felis, L,  
in an epithelial cell of the small intestine  
of a kitten killed on the eighth day after  
infection.

## PLATE XXXII



In the present study, the photomicrograph (Figure 90-M) shows an immature microgametocyte with two large residual masses surrounded by slender nucleated units, the microgametes. As the parasite matured (Figure 91-N), the residual masses disappeared and the greatly enlarged and distorted epithelial cell was filled with numerous microgametes.

Wenyon (1923) believed that the microgametocyte commenced as one of the larger merozoites. At first it was gregariniform in character and became irregular in shape until it had a length of about 20 u. The mature microgametocyte, 30 x 50 u, contained well over two thousand microgametes. The microgametes, he stated, were 5 u in length, with pointed anteriors and tapered posterior ends.

A small chromatin mass beside the nucleus of the macrogametocyte was labeled the "nebenkorper" (side body) by Swellengrebel. The light zone which surrounded this mass and the nucleus was larger than in the merozoites. This side body disappeared as the gametocyte matured. In this work, the side body was not observed and the average mature macrogametocyte measured 22.2 x 25.0 u. He gave the size of the same stage as 45-48 x 48-56 u and Wenyon gave the length from 25-35 microns. Perhaps the discrepancy in the size of the macrogametocyte as given by the various workers can be partially explained by the difficulty of measuring these ovoidal stages in tissue sections. The parasite may not be sectioned at its maximum measurements.

Plate XXXIII

Fig. 90. An immature microgametocyte of I. felis,  
M, in an epithelial cell of the small  
intestine of a kitten killed on the  
eighth day after infection.

## PLATE XXXIII

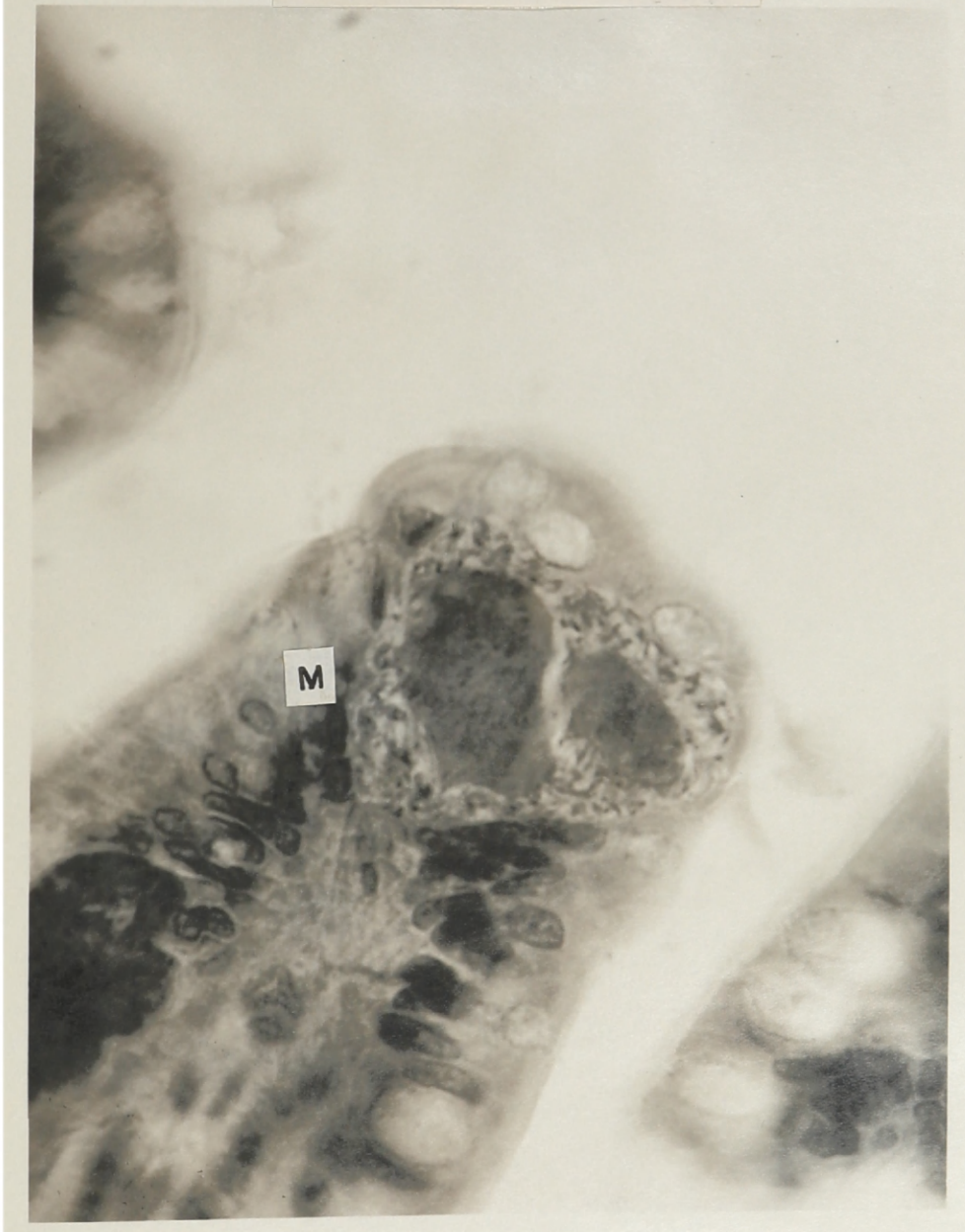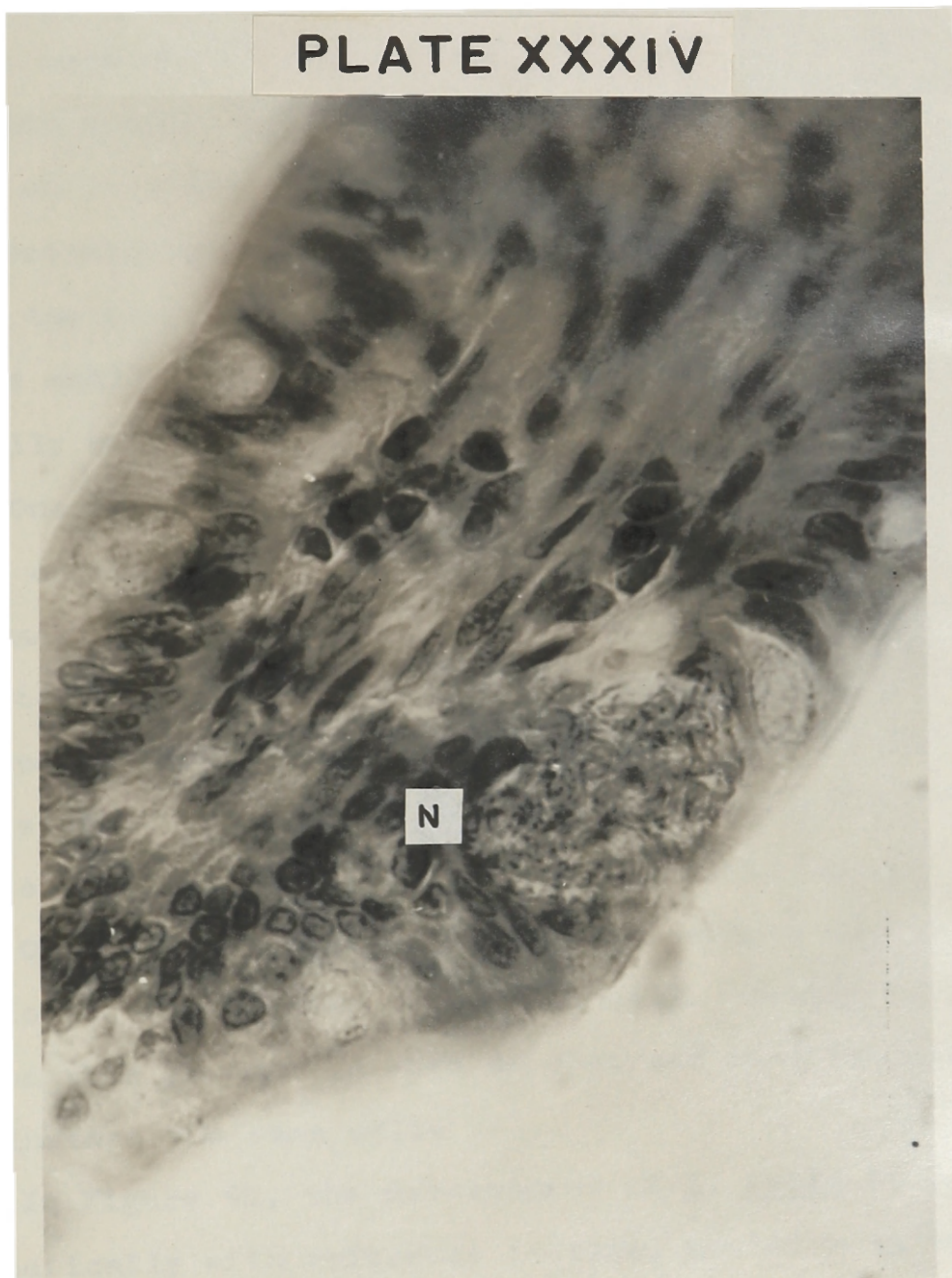


Plate XXXIV

Fig. 91. A mature microgametocyte of I. felis,  
N, in an epithelial cell of the **small**  
intestine of a kitten killed on the  
eighth day after infection.



## PLATE XXXIV





Parthenogenesis of the macrogametocyte was described by Swellengrebel. Wenyon and this author saw nothing comparable to his account.

The oocyst (Figure 78) showing hyaline, unstained walls while still intracellular, averaged  $19.3 \times 24.5$  u. The photomicrograph of oocysts (Figures 92-O and 93-P) presents the oocyst wall while still in the epithelial cells of the small intestine. Stage P illustrates this exceptionally well.

One of the kittens passed unsporulated oocysts in the feces on the seventh day and the other on the eighth day, thus making the prepatent period 7-8 days. Andrews (1926) reported the prepatent period as 5-6 days. Since he did not mention doing pre-infection fecal examinations, there is a possibility that his animals were naturally inoculated with oocysts of I. felis just prior to experimental infection.

On several occasions two asexual stages were found developing in the same epithelial cell. Wenyon (1923) mentioned this phenomenon when he observed that two merozoites had invaded the same cell.

In Figure 94, the development of I. felis is shown schematically with reference to time, position in the tissues, and morphological features. The cycle probably started with the sporozoites entering epithelial cells and forming first generation trophozoites. This stage was not

Plate XXXV

Fig. 92. An oocyst of I. felis, O, in an epithelial cell of the small intestine of a kitten killed on the eighth day after infection.

## PLATE XXXV

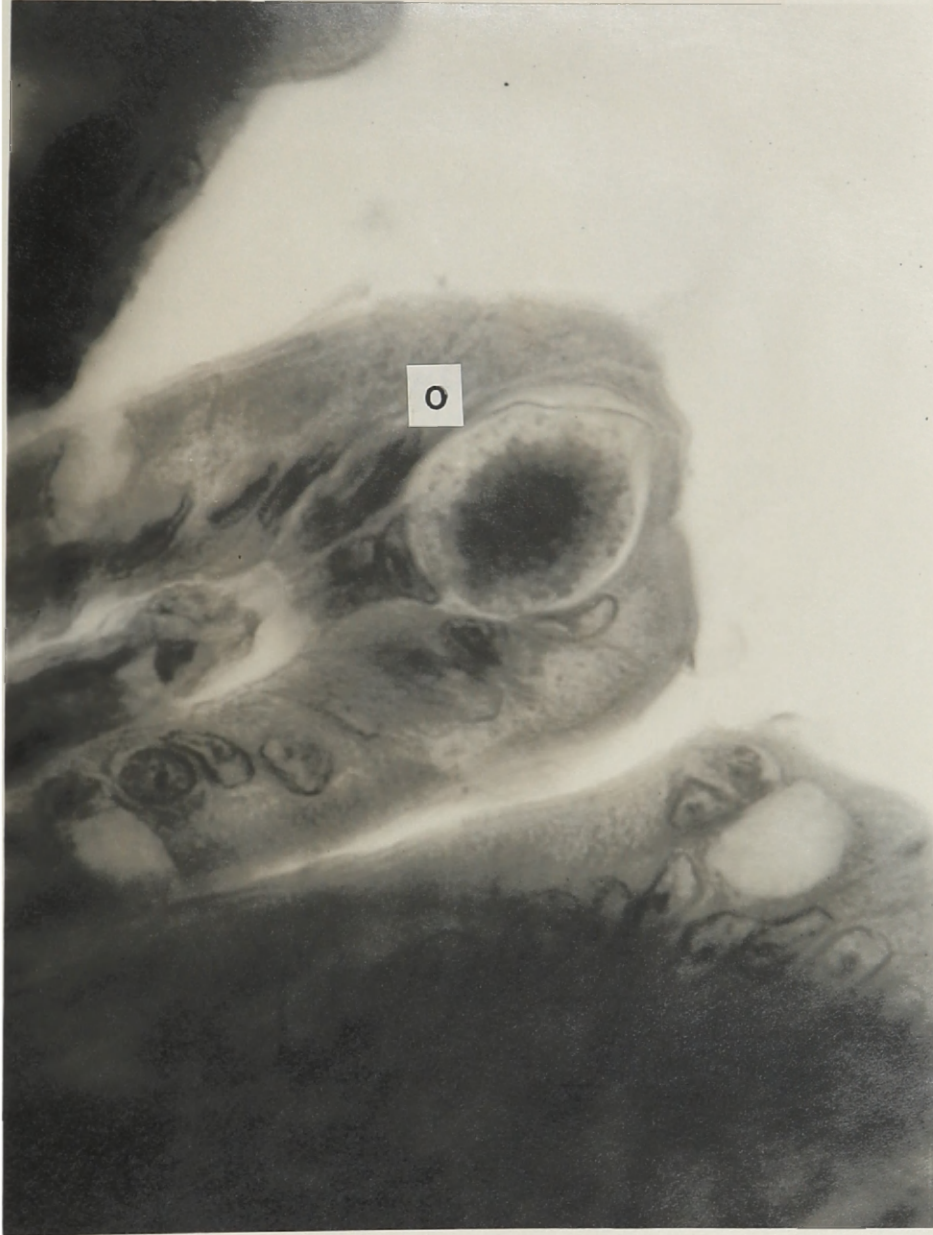
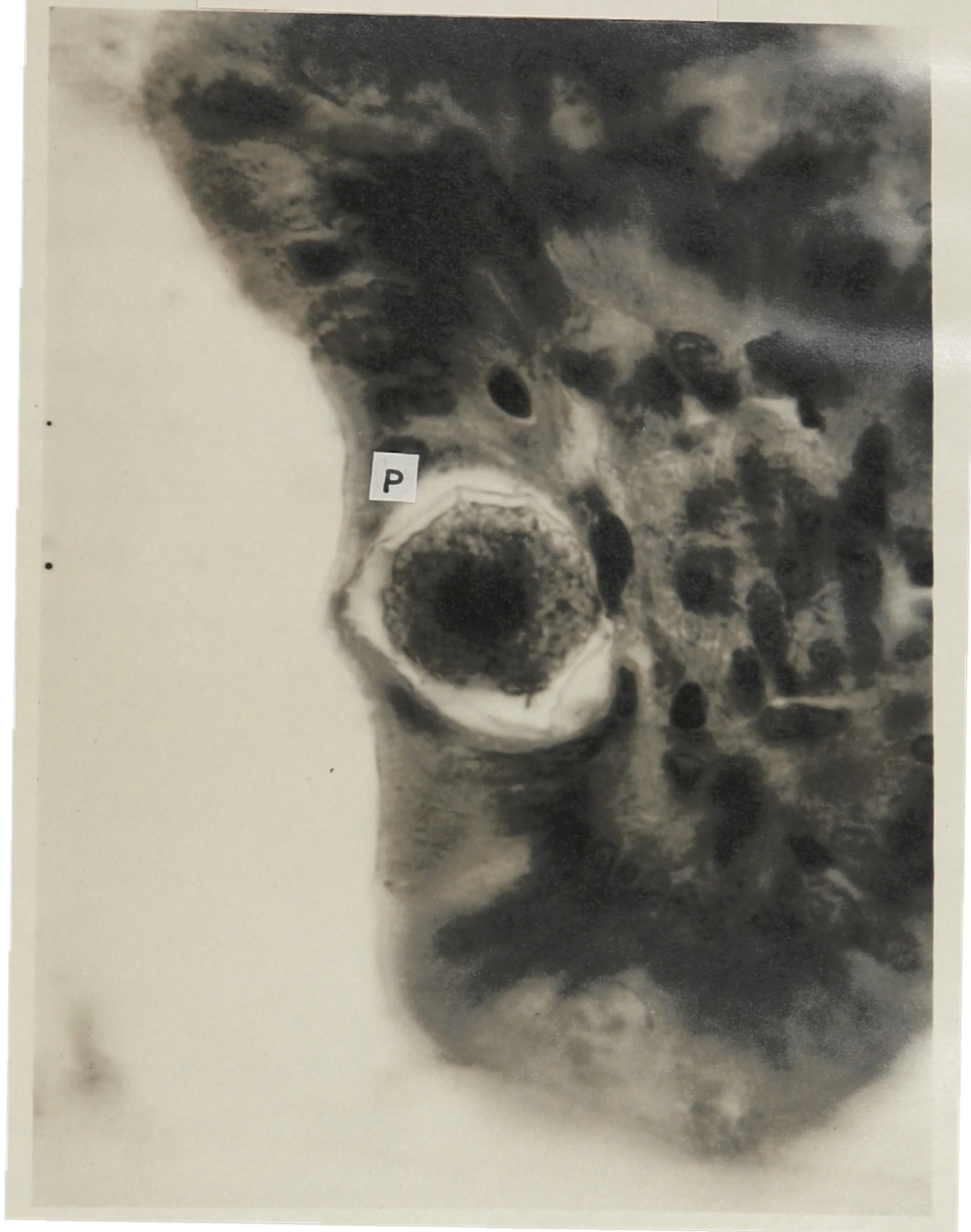
Plate XXXVI

Fig. 93. An oocyst of I. felis, P, in an epithelial cell of the small intestine of a kitten killed on the eighth day after infection.

## PLATE XXXVI



observed in this study nor represented in the figure, but if the behavior of this Isospora parallels that of other coccidia it probably existed. The single chromatin mass fragmented forming stages A and B, the immature first generation schizonts. An increase in size and further chromatin fragmentation resulted in stage C, a mature first generation schizont, which released first generation merozoites into the gut lumen. This first generation asexual cycle was prominent on the second, third, and fourth days. The first generation merozoites released by stage C repeated the first asexual cycle, or as represented on the fifth day, penetrated an epithelial cell, and formed a second generation trophozoite, stage D. As the immature second generation schizont, stage E, became mature, stage F, with more merozoites enclosed was formed. On rupture of the mature second generation schizont, stage G, second generation merozoites were liberated. Some of these free merozoites repeated the second asexual cycle as found on the sixth day, while others initiated the sexual cycles of the seventh and eighth days. The trophozoite, stage D, which began the formation of the microgametocyte or macrogametocyte, resembled that of the second asexual cycle. The immature microgametocyte, stage H, with peripheral chromatin and indented cytoplasm, increased in size and fragmented into the microgametes, stage I. The trophozoite, stage D, which was destined to become the female element,

enlarged, without division of the cytoplasm, to form the immature macrogametocyte, stage J. By a process of maturation, the macrogamete, stage K, developed. After fertilization, union of the macrogamete and microgamete, a wall formed about the resulting structure, the zygote. Contraction of the zygote away from the wall resulted in the oocyst in the epithelial cell, stage L. The oocyst was free in the lumen of the gut, stage M, to be passed out with the feces where sporulation occurred resulting in the formation of two spores each with four sporozoites.

Plate XXXVII

Fig. 94. The life cycle of Isospora felis in the kitten, diagrammatic.

Symbol representations:

- A - Immature first generation schizont
- B - Larger immature first generation schizont
- C - Mature first generation schizont releasing first generation merozoites into the lumen
- D - Second generation trophozoite
- E - Immature second generation schizont
- F - Mature second generation schizont
- G - Mature second generation schizont liberating second generation merozoites into the lumen
- H - Immature microgametocyte
- I - Mature microgametocyte liberating microgametes into the lumen
- J - Immature macrogametocyte
- K - Mature macrogamete
- L - Oocyst in the epithelial cell
- M - Oocyst free in the lumen

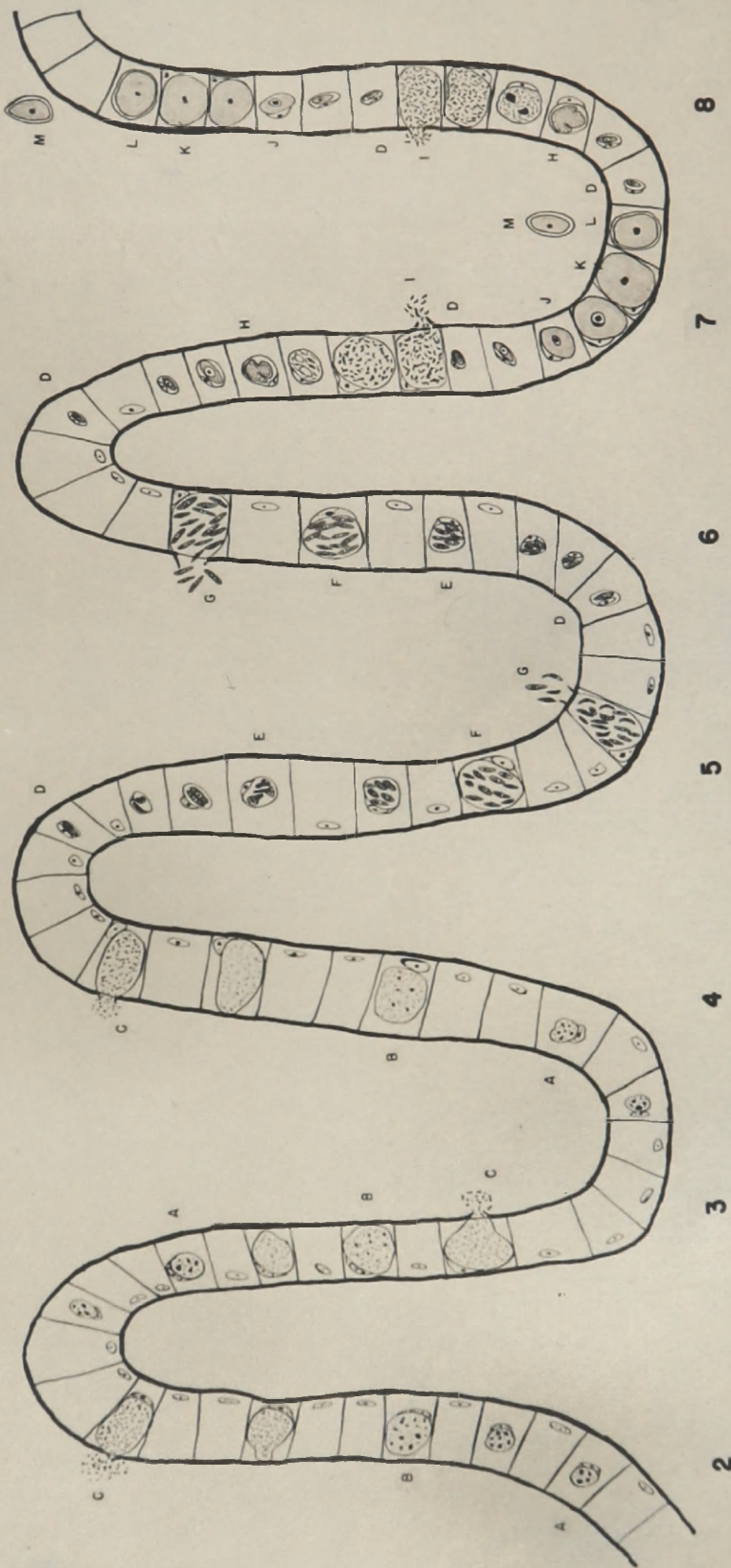


# PLATE XXXVII

## THE LIFE CYCLE OF ISOSPORA FELIS IN THE KITTEN

### DIAGRAMATIC

FIRST ASEQUAL SECOND ASEQUAL SEXUAL



DAYS OF INFECTION

FIG. 94

### C. Location of the Parasite

Intracellular stages of I. felis were found mainly in the small intestine and a few of both the asexual cycles were found also in the caecum and large intestine. Sexual stages were found in small intestine and caecum. The parasitic stages of I. felis were located in the intestinal epithelial cells and did not migrate into the sub-epithelial tissues. The present observations agree with Wenyon (1923) in that the parasites appeared to be limited almost entirely to the epithelium near the distal ends of the villi and seldom spread toward their bases. As the parasite matured, the invaded epithelial cells became enlarged, distorted and the nucleus was crowded to the side.

In the last one-third of the ileum of a young cat, Swellengrebel (1913-1914) found stages of I. felis. Wenyon (1923) presented drawings of developmental stages occurring in the epithelial cells of the villi of the small intestine and caecum. Wasielewski (1904) observed asexual reproduction in the small intestine of the cat. Further evidence that he was working with a mixed infection, probably I. felis and I. bigemina, was substantiated by the statements that he found parasites at autopsy in the depth of the mucosa and sporulation of the oocysts in the villi on sectioning. Workers since Wasielewski have shown these two observations to be characteristics of the life cycle of I. bigemina.

I. felis is not as organ specific as was originally thought as parasitic stages were found in the caecum and for the first time in the large intestine (Figure 85-H).

#### D. Symptomatology and Pathology

Andrews (1926) artificially infected eight kittens (wt. 308-750 gm.) with sporulated oocysts of I. felis, ranging in number from 100 to 100,000 per animal. He stated that the symptoms of coccidiosis in cats and dogs were the same as in other animals with the host rapidly becoming anemic, emaciated, weak and depressed. In the later stages of the infection, some of the kittens became weakened, prostrated, exhausted and died. The two animals to which he gave 100,000 oocysts of I. felis died. He did not state his evidence for the animals being anemic, except to mention the presence of gross and microscopic blood in the stools. Enteritis, emaciation and frequent deaths were enumerated by Wasielewski (1904) as the symptoms of natural infections of I. felis in the cat.

In many animals pathological conditions are ascribed to coccidiosis. In cattle, certain coccidia of the genus Eimeria can cause loss of the surface epithelium, thickening of the mucous membrane, hemorrhage and catarrhal enteritis. Similar species in sheep produce anatomical changes primarily in the small intestine as white or yellowish spots in the

serosa and mucosa. A marked enteritis may occur in the large intestine. Morgan and Hawkins (1948) listed the pathology produced by the Isospora in the cat and dog as hemorrhagic enteritis, frequently with ulceration throughout the small intestine, a thickened mucosa with widespread desquamation of the epithelium, and an extensive amount of connective tissue in the recovered cases and those with repeated infections. This description was well supported with recent investigations of canine coccidiosis; however, their source for the feline description probably emanated from investigations of 1926 or before.

In small birds the disease is similar in many respects to coccidiosis in poultry. An infection with Isospora eventually leads to destruction of the intestinal epithelium with subsequent loss of appetite, emaciation, droopiness, diarrhea and finally death due to acute enteritis (Boughton, 1934).

Since symptoms and pathological changes were commonly associated with coccidiosis in other animals, one might expect to find it in kittens. Such was not the case, as the author found no evidence of gross or microscopic lesions, edema, hemorrhage, or symptoms attributable to the presence of this organism. The symptoms and deaths recorded by Andrews and Wasielewski might well have been due to feline distemper. Their experimental and naturally infected animals were not vaccinated against feline distemper, since

this was not done at that time. Some of the symptoms and pathological conditions stated by them bear a marked similarity to those of this highly contagious, fatal illness of kittens. Perhaps this disease accounted for some of the symptoms and deaths noted by the early investigators.

## VI. SUMMARY

The life cycle of Isospora felis in the kitten was presented with photomicrographs and drawings of the morphological stages in their relative locations in the tissues. Artificial infections were produced and the animals killed at daily intervals. Tissues, for microscopical examination, were removed at definite locations.

This life history consisted of two asexual and one sexual cycle. The first asexual phase, described for the first time, existed from the second to the fourth days, while the second asexual phase lasted during the fifth and sixth days, and the sexual cycle remained the seventh and eighth days.

Since oocysts were passed on the seventh and eighth days, this presents a prepatent period different than previously thought.

All parasitic stages of I. felis found were intracellular in the surface epithelial cells of the intestine as was formerly reported.

Most of the sexual and asexual stages were found in the small intestine, but a few sexual stages were found in the caecum. A few asexual forms were present in the caecum and, for the first time, noted in the large intestine.

The majority of the mature second generation schizonts contained 12, 14, or 16 merozoites.

No pathological conditions or symptoms attributed to this infection were recognized.

## BIBLIOGRAPHY

- Andrews, J. M. 1926 Coccidiosis in mammals. Am. J. Hyg.  
6:784-798.
- Becker, E. R. 1934 Coccidia and Coccidiosis of Domesticated  
Game and Laboratory Animals. First Edition. Collegi-  
ate Press, Publisher, Ames, Iowa.
- Boughton, D. C. 1934 Notes on avian coccidiosis. The Auk  
54:500-509.
- Chauveau, A. 1872 The Comparative Anatomy of Domesticated  
Animals. Trans. and edited by George Fleming. W. R.  
Jenkins, N. Y.
- Finck, H. 1854 Sur la physiologie de l' épithélium  
intestinal. Thesis, Strasbourg.
- Grassi, G. B. 1882 Intorno ad alcuni prostisti endoparas-  
sitici, ed appartenenti alle classi dei Flagellati,  
lobosi, Sporozoi e Ciliati. Atti Soc. Ital. Sci.  
Nat. 24:135-224.
- Hitchcock, D. J. 1953 Incidence of gastrointestinal  
parasites in some Michigan kittens. N. Am. Vet.  
34:428-429.
- Leuckart, R. 1879 Die Parasiten Des Menschen. Second  
Edition. I. Leipzig u. Heidelberg.
- Morgan, B. B. and Hawkins, P. A. 1948 Veterinary Proto-  
zoology. Burgess Publishing Company, Publisher,  
Minneapolis, Minnesota.
- Pachinger, A. 1887 Mittheilung über Sporozoen. Zool.  
Anzeiger 9:471-472,
- Railliet, A. and Lucet, A. 1891 Note sur quelques espèces  
de coccidies encore peu étudiées. Bull. Soc. Zool.  
France 14:246-250.
- Reichenow, E. 1921 Die coccidien. Handbuch der pathogenen  
Protozoen. S. von Prowazek und Nöller, Lief VIII.



- Rivolta, S. 1874 Sopra alcune specie di Tenie delle pecore e sopra speciali cellule oviformi dei villi del cane e del gatto. Pisa.
- Stiles, C. W. 1891 Note préliminaire sur quelques parasites. Bull. Soc. Zool. 14:163-165.
- Swellengrebel, N. H. 1913-1914 Zur Kenntniss der Entwicklungsgeschichte von Isospora bigemina (Stiles). Arch. f. Protist. 32:379-392.
- Titkemeyer, C. W. 1951 The microscopical anatomy of the small intestine of domestic animals. M. S. Thesis, Michigan State College.
- Tyzzer, E. E. 1929 Coccidiosis of gallinaceous birds. Am. J. Hyg. 10:269-383.
- Vever, G. M. 1948 The Book of the Dog. Edited by B. Vesey-Fitzgerald, Nicholson and Watson, London.
- Wasielowski, T. 1904 Studien und Mikrophotogramme zur Kenntniss der Pathogenen Protozoen. I. Untersuchungen über der Bau, die Entwicklung und über die pathogene Bedeutung der Coccidien. Leipzig.
- Wenyon, C. M. 1923 Coccidiosis of cats and dogs and the status of Isospora of man. Ann. of Trop. Med. and Parasit. 17:231-288.